

**Case Report**

# A Case of Paraneoplastic Remitting Seronegative Symmetrical Synovitis with Pitting Edema Syndrome Improved by Chemotherapy

Takahiko Sakamoto Shuji Ota Terunobu Haruyama Masashi Ishihara  
Maika Natsume Yoko Fukasawa Shigeru Tanzawa Ryo Usui  
Takeshi Honda Yasuko Ichikawa Kiyotaka Watanabe Nobuhiko Seki

Division of Medical Oncology, Department of Internal Medicine, Teikyo University School of Medicine, Tokyo, Japan

**Keywords**

Lung cancer · Remitting seronegative symmetrical synovitis with pitting edema · Paraneoplastic syndrome

**Abstract**

The patient was a 69-year-old male who had started experiencing acute-onset pain in both shoulder joints and edema of both hands and feet. His symptoms progressively worsened within 1 month. Laboratory data indicated elevated CRP and erythrocyte sedimentation rate despite the normal range of antinuclear antibodies and rheumatoid factor and normal organ function. Furthermore, imaging data of the hand indicated synovitis without bone erosions. Meanwhile, chest CT revealed a lung tumor, leading to a diagnosis of primary lung adenocarcinoma with EGFR mutation (cT2aN3M0, stage IIIB). Based on these findings, he was diagnosed as suffering from paraneoplastic remitting seronegative symmetrical synovitis with pitting edema (RS3PE) syndrome. Thereafter, his symptoms disappeared as the tumor size was rapidly decreased by gefitinib therapy for lung adenocarcinoma. Currently, RS3PE syndrome can be classified as a vascular endothelial growth factor (VEGF)-associated disorder. Given that his symptoms improved by chemotherapy, the present case further supported the possible hypothesis that paraneoplastic RS3PE syndrome might be caused by tumor-induced

**KARGER**

Nobuhiko Seki, MD, PhD  
Division of Medical Oncology, Department of Internal Medicine  
Teikyo University School of Medicine  
2-11-1, Kaga, Itabashi-ku, Tokyo 173-8606 (Japan)  
E-Mail [nseki@med.teikyo-u.ac.jp](mailto:nseki@med.teikyo-u.ac.jp)

VEGF. Therefore, the present case suggested that the symptoms of acute-onset joint pain accompanied by pitting edema in elderly patients should be considered suspicious for a malignant tumor, thereby warranting a detailed full-body examination.

© 2017 The Author(s)  
Published by S. Karger AG, Basel

## Introduction

Remitting seronegative symmetrical synovitis with pitting edema (RS3PE) syndrome is an acute-onset disorder in the elderly, characterized by symmetrical synovitis with pitting edema of the dorsum of the hands and feet, and is a known paraneoplastic syndrome [1]. Here, we report a case of primary lung adenocarcinoma discovered due to the presence of synovitis with pitting edema resulting from RS3PE syndrome.

## Case Report

The patient was a 69-year-old male who had started experiencing acute-onset pain in both shoulder joints and edema of both hands and feet. Initially, he had visited a nearby clinic, but the cause had been unidentified, and he had been put on analgesic medication. However, the joint pain and edema progressively worsened during the observation period of 1 month. Then, the patient was referred to our hospital and admitted for detailed examination.

Laboratory data at admission indicated that kidney function, liver function, and serum albumin were normal. Thyroid function was normal. Antinuclear antibodies, rheumatoid factor, and anti-CCP antibodies were within the normal range. However, CRP, erythrocyte sedimentation rate, and MMP-3 were elevated, respectively. The echocardiogram indicated that heart function was normal.

In the imaging test of full body, chest CT revealed a 2.8-cm-diameter nodule with irregular borders in the left lung S1 + 2 segment, leading to a diagnosis of primary lung adenocarcinoma (cT2aN3M0, stage IIIB). The tumor was found to have the epidermal growth factor receptor (EGFR) exon 21 L858R mutation. Meanwhile, in the imaging test of the hand, a simple X-ray image showed no signs of joint damage, such as erosions (Fig. 1). However, T1-weighted MRI image after gadolinium contrast showed strong enhancement in the flexor tendon, extensor tendon, and surrounding areas (Fig. 2).

On the basis of these findings, the patient was diagnosed as suffering from paraneoplastic RS3PE syndrome as a complication of lung adenocarcinoma. The patient was started on gefitinib at 250 mg/day for the treatment of lung adenocarcinoma. Following the start of gefitinib therapy, the pain in both shoulder joints and edema of the dorsum of both hands and both feet gradually improved. By 28 days after the start of therapy, the symptoms had disappeared (Fig. 3a, b), and the tumor size was reduced (Fig. 4a, b). Currently, 4 years after the start of gefitinib therapy, a complete response of lung adenocarcinoma has been achieved with no symptoms and signs of RS3PE syndrome.

## Discussion

RS3PE syndrome, described by McCarty et al. [1], is a rheumatic disorder characterized by: (1) good prognosis; (2) absence of rheumatoid factor; (3) bilateral symptoms; (4) pitting

edema of the dorsum of hands and feet; (5) occurrence in the elderly; (6) acute onset; (7) absence of bone erosions; (8) elevated CRP and erythrocyte sedimentation rate. The present case met these criteria and was diagnosed as RS3PE.

RS3PE syndrome could be considered as early signs of malignant tumors. In fact, the incidence of malignant tumor as a complication of RS3PE syndrome is high at 31–54% [2]. Furthermore, the incidence of malignant tumors is 7 times higher in male patients with RS3PE syndrome than in normal elderly men, and it is 4 times higher in female patients than in healthy young women. RS3PE syndrome is often reported as a complication of stomach cancer, colon cancer, prostate cancer, and malignant lymphoma. However, only a few reports of RS3PE syndrome have been published as a complication of lung cancer [3].

To date, the mechanism of pathogenesis of paraneoplastic RS3PE syndrome has not been elucidated. However, it has been known that vascular endothelial growth factor (VEGF) promotes synovial inflammation and vascular permeability in patients with RS3PE syndrome, suggesting that RS3PE syndrome can be classified as a VEGF-associated disorder [4]. Thus, considering that the involvement of VEGF in malignant tumors has also been well recognized, the characteristic synovitis with pitting edema in paraneoplastic RS3PE syndrome could result from enhanced vascular permeability caused by tumor-induced VEGF [5].

In the present case, steroids were not used for his paraneoplastic RS3PE syndrome. However, the symptoms disappeared as the tumor size was rapidly decreased by gefitinib therapy. Especially given that paraneoplastic RS3PE syndrome is refractory to steroids although non-paraneoplastic RS3PE syndrome is normally responsive to steroids [6], the present case further supported the possible hypothesis that paraneoplastic RS3PE syndrome might be caused by tumor-induced VEGF.

In conclusion, the findings for this rare case of RS3PE complicating lung cancer suggest that the symptoms of acute-onset joint pain accompanied by pitting edema in elderly patients should be considered suspicious for a malignant tumor, thereby warranting a detailed full-body examination.

### Statement of Ethics

The authors have no ethical conflicts to disclose.

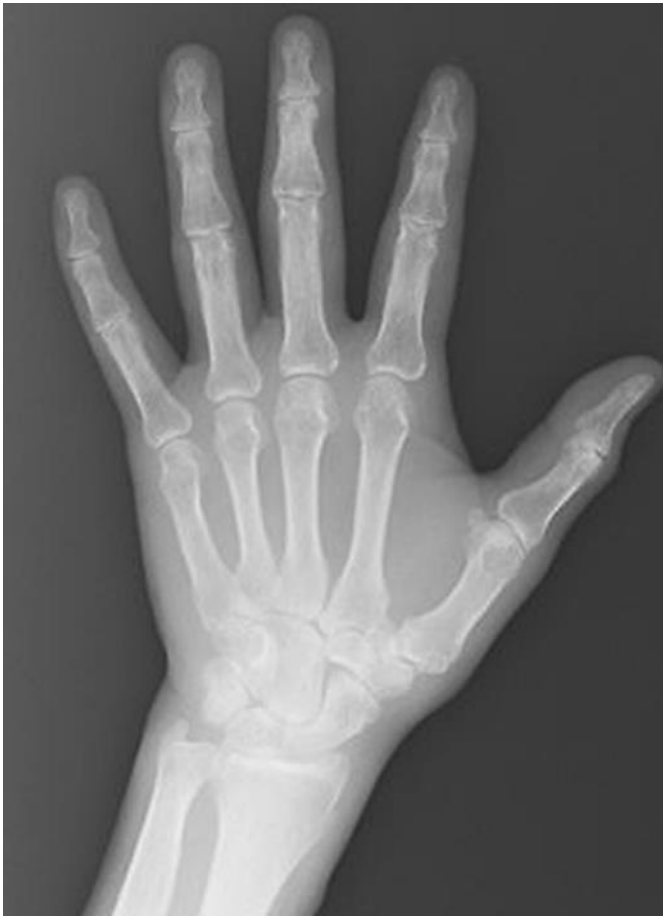### Disclosure Statement

The authors declare that they have no relevant financial interests.

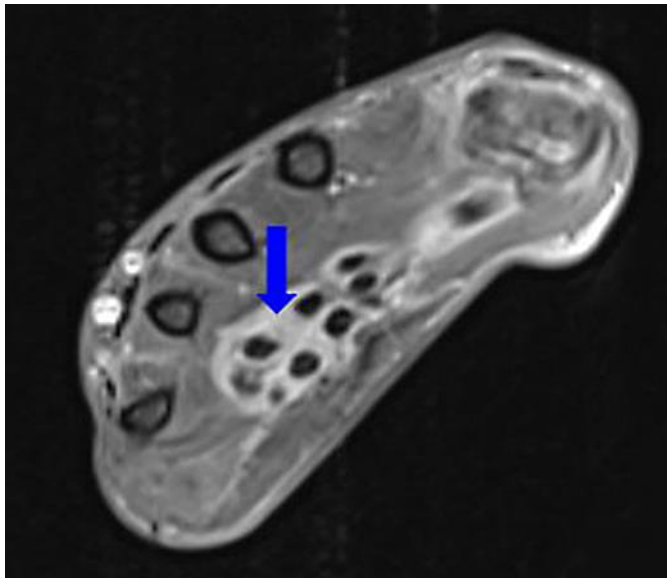
### References

- 1 McCarty DJ, O'Duffy JD, Pearson L, Hunter JB: Remitting seronegative symmetrical synovitis with pitting edema. RS3PE syndrome. *JAMA* 1985;254:2763–2767.
- 2 Yao Q, Su X, Altman RD: Is remitting seronegative symmetrical synovitis with pitting edema (RS3PE) a subset of rheumatoid arthritis? *Semin Arthritis Rheum* 2010;40:89–94.
- 3 Mattace-Raso FU, van der Cammen TJ: Remitting seronegative symmetrical synovitis with pitting oedema associated with lung malignancy. *Age Ageing* 2007;36:470–471.
- 4 Arima K, Origuchi T, Tamai M, et al: RS3PE syndrome presenting as vascular endothelial growth factor associated disorder. *Ann Rheum Dis* 2005;64:1653–1655.

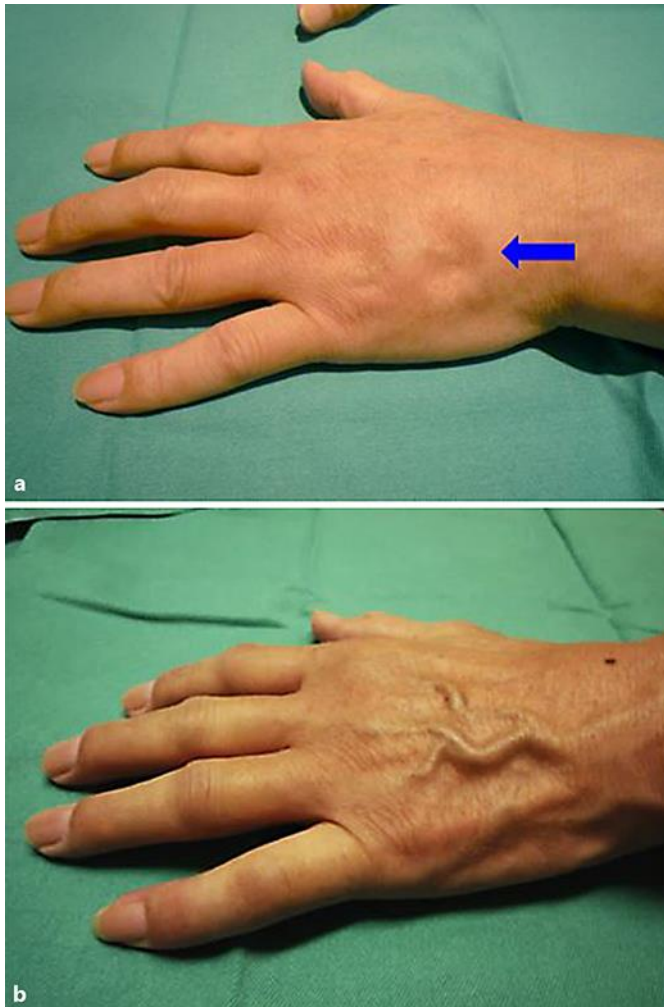
- 5 Appelmann I, Liersch R, Kessler T, Mesters RM, Berdel WE: Angiogenesis inhibition in cancer therapy: platelet-derived growth factor (PDGF) and vascular endothelial growth factor (VEGF) and their receptors: biological functions and role in malignancy. *Recent Results Cancer Res* 2010;180:51–81.
- 6 Origuchi T, Arima K, Kawashiri SY, et al: High serum matrix metalloproteinase 3 is characteristic of patients with paraneoplastic remitting seronegative symmetrical synovitis with pitting edema syndrome. *Mod Rheumatol* 2012;22:584–588.



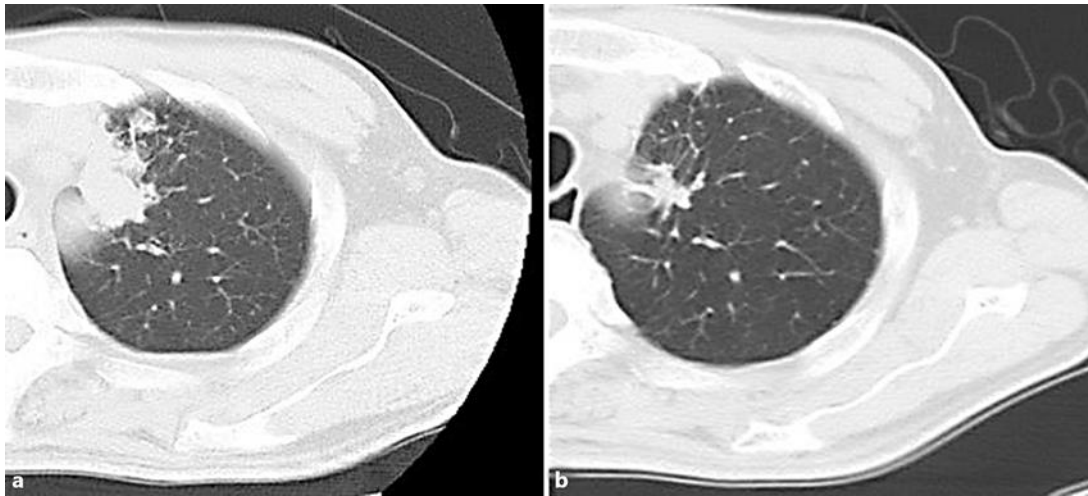
**Fig. 1.** Simple X-ray image of the left hand. No signs of joint damage, such as erosions, and narrowing of joint space were observed.



**Fig. 2.** Cross-sectional MRI image of the left hand. T1-weighted MRI image after gadolinium contrast showed strong enhancement in the flexor tendon, extensor tendon, and surrounding areas (arrow).



**Fig. 3.** Macroscopic photograph of the left hand. **a** Pitting edema of the dorsum of the hand was observed before treatment (arrow). **b** Edema of the dorsum of the hand improved by 28 days after the start of therapy for lung adenocarcinoma.



**Fig. 4.** Chest CT images of the left lung S1 + 2 segment. **a** The primary tumor before treatment. **b** The tumor size was rapidly decreased by 28 days after the start of therapy for lung adenocarcinoma.