

A case of neurosarcoidosis with necrotizing granuloma expressing angiotensin-converting enzyme

著者	Kitajima Shinji, Sakai Norihiko, Furuichi Kengo, Tomokage Miki, Hara Akinori, Kitagawa Kiyoki, Sawada-Kitamura Seiko, Zen Yoh, Nakada Mitsutoshi, Kaneko Shuichi, Wada Takashi
journal or publication title	Modern Rheumatology
volume	20
number	5
page range	506-510
year	2010-10-01
URL	http://hdl.handle.net/2297/25880

doi: 10.1007/s10165-010-0301-y

A case of neurosarcoidosis with necrotizing granuloma expressing angiotensin converting enzyme.

Shinji Kitajima • Norihiko Sakai • Kengo Furuichi, • Miki Tomokage • Akinori Hara • Kiyoki Kitagawa • Seiko Sawada • Kitamura • Yoh Zen • Mitsutoshi Nakada • Shuichi Kaneko • Takashi Wada.

S. Kitajima • N. Sakai • K. Furuichi, • M. Tomokage • A. Hara • K. Kitagawa • S. Kaneko

Department of Disease Control and Homeostasis, Institute of Medical, Pharmaceutical and Health Sciences, Faculty of Medicine, Kanazawa University, 13-1 Takara-machi, Kanazawa 920-8641, Japan

S. Sawada Kitamura • Y. Zen

Department of Human Pathology, Institute of Medical, Pharmaceutical and Health Sciences, Faculty of Medicine, Kanazawa University, Kanazawa, Japan

M. Nakada

Department of Neurosurgery, Institute of Medical, Pharmaceutical and Health Sciences, Faculty of Medicine, Kanazawa University, Kanazawa, Japan

T. Wada (corresponding author)

Department of Laboratory Medicine, Institute of Medical, Pharmaceutical and Health Sciences,

Faculty of Medicine, Kanazawa University, 13-1 Takara-machi, Kanazawa 920-8641, Japan

e-mail: twada@m-kanazawa.jp

tel +81-76-265-2000 (ext 7270)

fax +81-76-234-4250

Keywords necrotizing sarcoid granuloma, neurosarcoidosis

Abstract

We described a case of neurosarcoidosis with necrotizing sarcoid granulomatosis in a 22-year-old man. Contrast-enhanced brain computed tomography scan and magnetic resonance imaging showed intracerebral multiple nodular lesions. Noncaseating and partial necrotizing granulomas were detected in the specimen resected by neurosurgery. In addition, immunohistochemical examination revealed the expression of angiotensin converting enzyme in necrotizing granuloma. Thus, these findings were consistent with neurosarcoidosis. Clinical and pathological presentation, immunological feature and treatment modalities of neurosarcoidosis are discussed.

Introduction

Sarcoidosis is a systemic granulomatous disease of unknown etiology. The manifestation of sarcoidosis in the nervous system have been recognized as neurosarcoidosis. Especially, the involvement of the central nervous system (CNS) develops in about 5% of patients with systemic sarcoidosis [1,2]. However, because of its non-specific clinical presentation and neuroradiological findings, CNS lesion in neurosarcoidosis remains a very difficult diagnosis, particularly patients without systemic signs of the disease [3,4]. In this report, we present a sarcoidosis with epileptic seizure as the first symptom and intracerebral necrotic granulomas.

Case Report

A 18-year-old Japanese man, who had been in good health, presented with generalized convulsion in 2004. He was taken by ambulance and admitted to a hospital nearby. There was no significant finding

in brain by plain computed tomography (CT) scan. He was diagnosed as epilepsy and was began to be treated with antiepileptic drug (carbamazepin 200mg/day). No epileptic attacks occurred after the treatment. In 2005, he noticed photophobia and was diagnosed as uveitis. At the time, chest radiograph and CT scan showed mediastinal lymphadenopathy. The level of serum angiotensin converting enzyme (ACE) were elevated at 28.5 IU/l (normal range, 8.3-21.4 IU/l). Considered together, he was clinically diagnosed as sarcoidosis. Brain CT with no enhancement was performed, however, the obvious abnormality was not detected. After that, he was treated with eye drops of the steroid for sarcoidosis. In 2008, he suffered from nonpulsating headache. Contrast-enhanced CT scan and magnetic resonance imaging (MRI) showed multiple nodular lesions in frontal and temporal lobes, and he was admitted to our hospital for further examination.

On admission, his height was 165.5cm and his weight was 55.4kg. His blood pressure and pulse rate were 116/56 mmHg and 80/min. Examination of skin, conjunctiva, neck, thyroid gland, chest, abdomen and extremities revealed no abnormal signs. On neurological examination, cranial nerves were intact. Muscle strength and deep tendon reflexes were normal and no pathological reflexes were observed.

Laboratory findings on admission are shown in Table 1. Complete blood counts, and lactate dehydrogenase, calcium, and phosphorous were within normal range. The levels of serum ACE were elevated at 28.7 IU/l. Chest radiograph and CT scan revealed mediastinal lymphadenopathy, but no pulmonary infiltrates (Fig.1). Contrast-enhanced brain CT scan showed multiple nodular lesions, which enhanced homogeneously with contrast medium, in the right occipital, frontal, temporal, and left parietal lobe (Fig.2 a,b). Gadolinium enhanced MRI showed lesions more clearly (Fig.2 c,d). Lesions appeared isointense on T2-weighted images. They enhanced homogeneously with intravenous

administration of contrast medium. To obtain the definite diagnosis, the lesion in the left parietal lobe was removed. Histological examination revealed noncaseating and partial necrotizing granulomas (Fig.3). In addition, ACE expression and the infiltration of CD68 positive macrophage were co-localized in the noncaseating granuloma and marginal area of necrotic granuloma (Fig.4). Mycobacterial and fungal organism were not identified on Ziehl-Neelsen and Grocott-Gomori methenamine silver-stained sections. Cultures of granulomatous tissue were negative for acid-fast bacilli, bacteria, and fungi. Collectively, he was diagnosed as neurosarcoidosis, and additional systemic investigations were performed. Electrocardiography, echocardiography and pulmonary function tests showed no significant findings. Whole-body gallium-67 scintigram showed increased uptake in the bilateral hilar and mediastinal regions, but no other accumulation was recognized. Echo-guided liver biopsy revealed noncaseating granulomas which was relevant to sarcoidosis. Furthermore, granulomas from liver biopsy were co-stained by ACE and CD68 (Fig 5). Skin test for tuberculosis and other studies for infections including fungal, viral and bacterial pathogens were negative.

For the treatment of sarcoidosis with brain lesion, methyl-prednisolone pulse therapy was started at the rate of 10 mg/kg/day for consecutive 3 days; following by the oral administration of prednisolone (20 mg/day) according to dosages described in the review and case reports. [3,5,6]. At 6 months after the initiation of glucocorticoid therapy, his symptom disappeared and serum ACE level returned to normal (11.5 IU/l). Contrast-enhanced CT revealed an obvious decrease of the size of intracerebral lesions (Fig 6). The administration of oral steroid is being tapered was slowly.

Discussion

Here, we presented a case of sarcoidosis with multiple intracranial lesions which demonstrate the presence of noncaseating and partial necrotizing granulomas. This case has a history of generalized convulsion, photophobia diagnosed as uveitis, bilateral hilar and mediastinal lymphadenopathy and serum ACE elevation before developing headache. In addition, sarcoid granuloma was shown in not only brain but also liver biopsy. From these findings, this case might not be isolated neurosarcoidosis. Sarcoidosis is an idiopathic systemic disorder that affects almost all organs in the body, including the CNS. Neurological manifestations of sarcoidosis are observed in approximately 5% of patients [1,2]. In today, MRI has displaced contrast enhanced CT as the most useful test for detecting basal sarcoid meningeal disease [7]. In addition, correlation of MRI findings and clinical manifestations was reported [8,9]. The frequency of headache may be increasing in patients with leptomeningeal disease as in our case [9]. However, nonenhancing white matter, dural, and spinal lesions were the least likely to correlate with symptoms. Cranial nerve enhancement and spinal lesions are more likely to resolve with immunosuppressive therapy than others such as dural and parenchymal lesions [9]. Enhancing T2-hypointense lesions may be associated with a suboptimal response to immunosuppressive therapy, but our case had good response to therapy. Further studies remain to be investigated to elucidate correlation of MRI findings and clinical manifestation in neurosarcoidosis. [9]

Histopathology of neurosarcoidosis usually reveals the presence of noncaseating granulomas, giant multinucleated (epithelioid) cells and macrophages surrounded by an inflammatory reaction composed of lymphocytes, plasma cells, and mast cells [10]. Uncommon cases characterized by necrotizing granulomas such as our case have also been described [11,12]. Necrotizing sarcoid granulomatosis (NSG) was first described in 1973 in pulmonary sarcoidosis [13], and has been found in a variety of

extrapulmonary sites such as skin, kidney, and intraorbital contents. The characteristic histological findings have been reported to be the coagulative central necrosis along with noncaseating granulomas accompanied by a moderate to intense inflammatory reaction involving lymphocytes, plasma cells, and macrophages [14]. The pathogenesis of NSG has been reported to be a hypersensitive reaction due to the vascular involvement and granulomatous inflammation [15]. Further studies will be required to make clear the precise mechanism of NSG in future.

Differential diagnosis of NSG includes chronic infections with granuloma formation (e.g.; tuberculosis, histoplasmosis, aspergillosis, and cryptococcosis), foreign body granulomas, Wegener's granulomatosis, and idiopathic pachymeningitis with granuloma formation. Previously, NSG in kidney have been reported to show the expression of ACE in granuloma [6]. In our case, similarly, ACE expression and macrophage infiltration were co-localized in the marginal area of necrotic granuloma. In contrast, weakly stain of ACE was observed at the center of granulomas. These findings suggested that inflammatory cells in sarcoid granuloma might be metabolically active in the synthesis of ACE. Furthermore, immunohistochemical detection of ACE might be useful for the diagnosis of sarcoidosis, which help the differential diagnosis.

Thus far, there exist no controlled studies addressing the treatment of neurosarcoidosis, including extra-axial neurosarcoid granulomas. Corticosteroids are the therapy of choice as they have been reported to improve neurological symptoms and reduce intracranial sarcoid spread confirmed by MRI [16,17,18]. In our case, corticosteroids therapy was effective and revealed an obvious decrease of the lesion size. However, response to steroids has been reported to be variable. Some cases improve rapidly while others do not respond at all. Failure of response to steroid and clinical deterioration during

late reduction after long term administration of oral corticoids warrant additional immunosuppressive agent, such as azathioprine, methotrexate, cyclophosphamide, cyclosporine and mycophenolate mofetil [5,19,20]. In cases resistant to immunosuppressive treatment, the TNF- α antagonists, pentoxifylline and thalidomide are reported to be effective and safe treatment with good steroid sparing effects [21,22,23]. TNF- α is thought to play a role as mediator of inflammation and cellular immune response among numerous cytokines involved. Infliximab (a monoclonal antibody against TNF- α) in particular has a growing body of literature supporting its effectiveness. Further studies remain to be examined for management of this disease and avoidance of severe adverse effects. In summary, a case of neurosarcoidosis with NSG was described. It may be suggested that immunohistochemical detection of ACE in the lesion is useful tool for the diagnosis of neurosarcoidosis with NSG.

Reference

1. Delaney P. Neurologic manifestations in sarcoidosis: Review of the literature with a report of 23 cases. *Ann Intern Med.* 1977;87:336-45.
2. Burns TM. Neurosarcoidosis. *Arch Neurol.* 2003;60:1166-8.
3. Joseph FG, Scolding NJ. Sarcoidosis of the nervous system. *Pract Neurol.* 2007;7:234-44
4. Fels C, Riegel A, Javaheripour-Otto K, Obenauer S. Neurosarcoidosis Findings in MRI. *J Clin Imaging.* 2004;28:166-9.
5. Zajicek JP, Scolding NJ, Foster O, Rovaris M, Evanson J, Mitchell D, et al. Central nervous system sarcoidosis - diagnosis and management. *QJM.* 1999;92:103-17.
6. Ito Y, Suzuki T, Mizuno M, Morita Y, Muto E, Matsuo S, et al. A case of renal sarcoidosis showing

central necrosis and abnormal expression of angiotensin converting enzyme in the granuloma. Clin Nephrol. 1994;42:331-6.

7. Mana J. Magnetic resonance imaging and nuclear imaging in sarcoidosis. Curr Opin Pulm Med. 2002;8:457-63.

8. Christoforidis GA, Spickler EM, Recio MV, Mehta BM. MR of CNS sarcoidosis: correlation of imaging features to clinical symptoms and response to treatment. AJNR Am J Neuroradiol. 1999;20:655-69.

9. Shah R, Roberson GH, Curé JK. Correlation of MR imaging findings and clinical manifestations in neurosarcoidosis. AJNR Am J Neuroradiol. 2009;30:953-61.

10. Leiba H, Siatkowski RM, Culbertson WW, Glaser JS. Neurosarcoidosis presenting as an intracranial mass in childhood. J Neuroophthalmol. 1996;16:269-73.

11. Strickland-Marmol LB, Fessler RG, Rojiani AM. Necrotizing sarcoid granulomatosis mimicking an intracranial neoplasm: Clinicopathologic features and review of the literature. Mod Pathol. 2000;13:909-13.

12. Tobias S, Prayson RA, Lee JH. Necrotizing neurosarcoidosis of the cranial base resembling an en plaque sphenoid wing meningioma. Neurosurgery. 2002;51:1290-4.

13. Liebow AA. Pulmonary angiitis and granulomatosis. Am Rev Respir Dis. 1973;108:1-18.

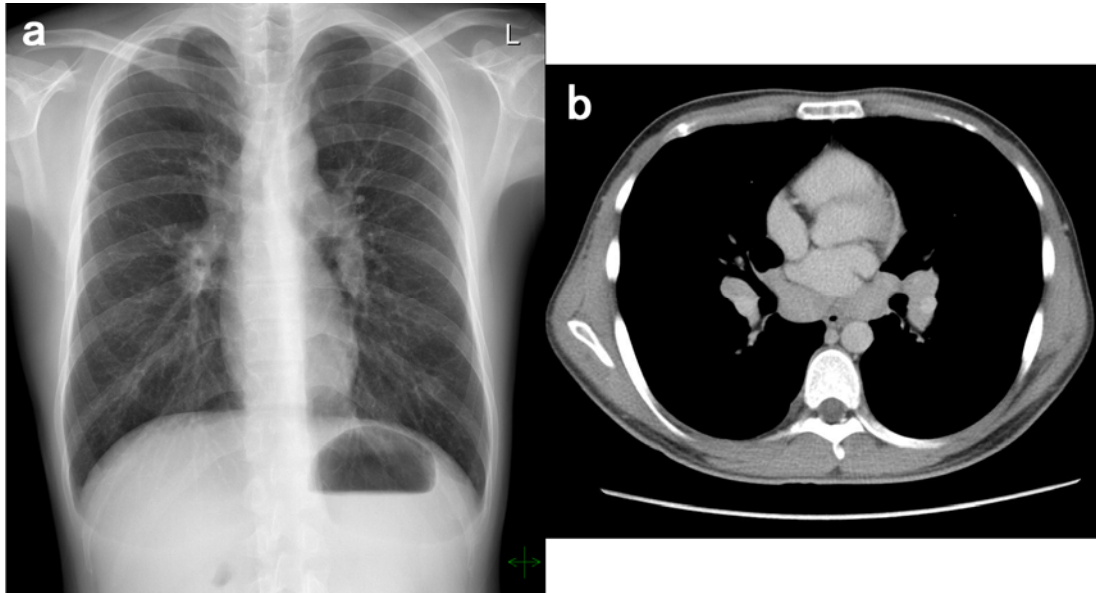
14. Rolfes DB, Weiss MA, Sanders MA. Necrotizing sarcoid granulomatosis with suppurative features. Am J Clin Pathol. 1984;82:602-7.

15. Popper HH, Klemen H, Colby TV, Churg A. Necrotizing sarcoid granulomatosis - is it different from nodular sarcoidosis? Pneumologie. 2003;57:268-71.

16. Krumholz A, Stern BJ, Stern EG. Clinical implications of seizures in neurosarcoidosis. *Arch Neurol.* 1991;48:842-4.
17. Dumas JL, Valeyre D, Chapelon-Abric C, Belin C, Piette JC, Goldlust D, et al. Central nervous system sarcoidosis: follow-up MR imaging during steroid therapy. *Radiology.* 2000;214:411-20.
18. Lexa FJ, Grossman RI. MR of sarcoidosis in the head and spine: spectrum of manifestations and radiographic response to steroid therapy. *AJNR.* 1994;15:973-82.
19. Stern BJ. Neurological complications of sarcoidosis. *Curr Opin Neurol.* 2004;17:311-6.
20. Kouba DJ, Mimouni D, Rencic A, Nousari HC. Mycophenolate mofetil may serve as a steroid-sparing agent for sarcoidosis. *Br J Dermatol.* 2003;148:147-8.
21. Baughman RP, Strohofer SA, Buchsbaum J, Lower EE. Release of tumor necrosis factor by alveolar macrophages of patients with sarcoidosis. *J Lab Clin Med.* 1990;115:36-42.
22. Doty JD, Mazur JE, Judson MA. Treatment of sarcoidosis with infliximab. *Chest.* 2005;127:1064-71.
23. Carter JD, Valeriano J, Vasey FB, Bognar B. Refractory neurosarcoidosis: a dramatic response to infliximab. *Am J Med.* 2004;117:277-9.

Figure

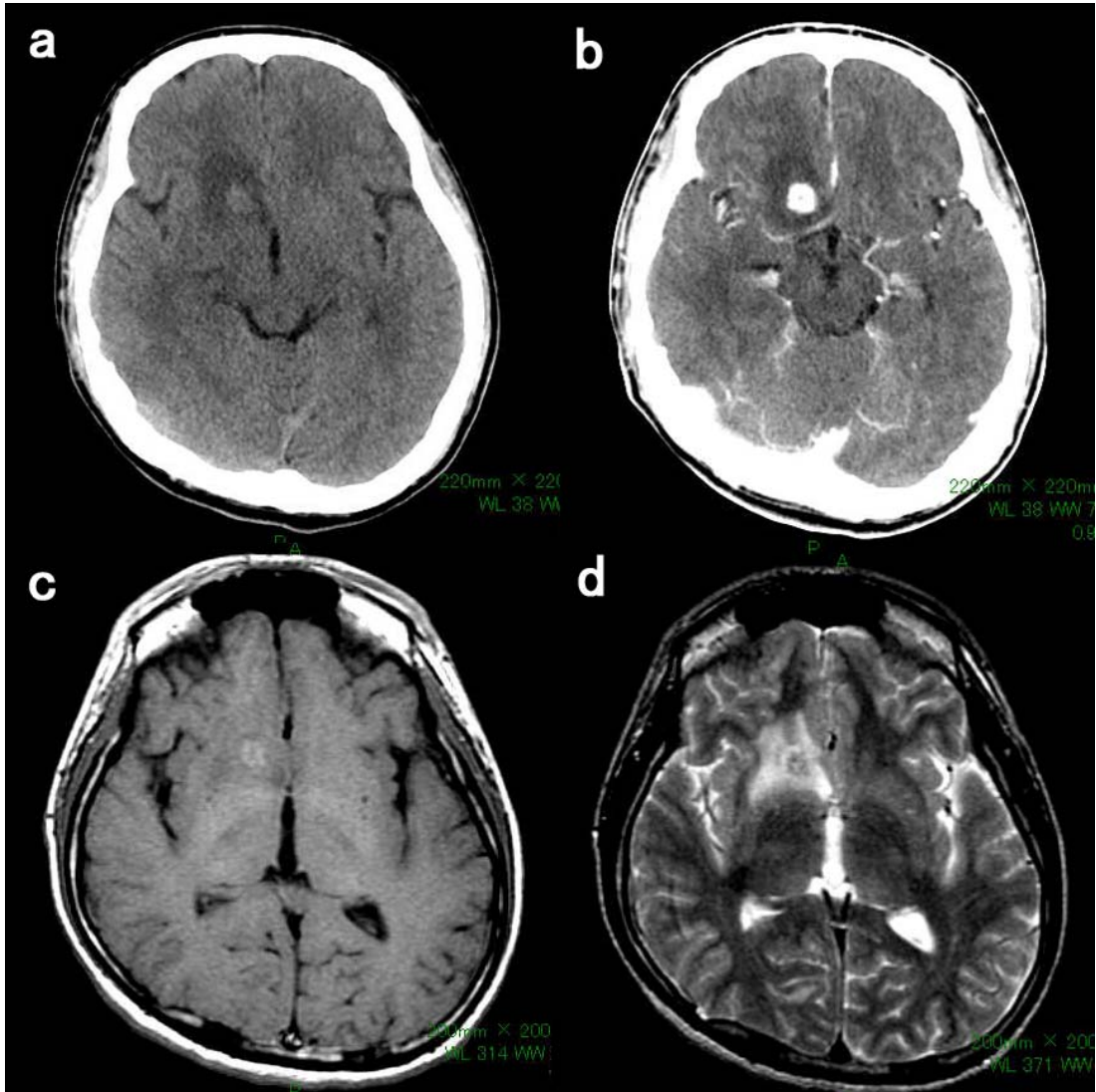
Figure 1.



Chest X ray on the day of admission (a). Bilateral hilar lymphadenopathy is observed.

Computed tomography (CT) of the chest (b). Bilateral hilar and mediastinal lymphadenopathy are observed.

Figure 2.

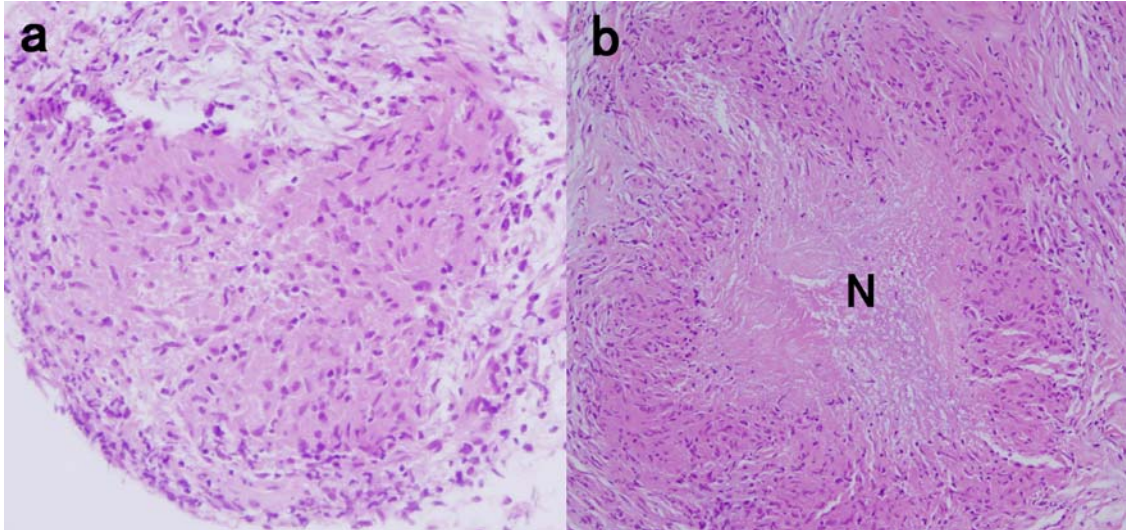


Plane CT (a) and enhanced CT (b) of the brain. Nodular lesion in right frontal lobe is observed. Extensive perifocal edema is present.

Contrast-Enhanced T1-weighted MRI showed hyperintense lesion in right frontal lobe (c).

T2-weighted MRI showed isointense lesion (d).

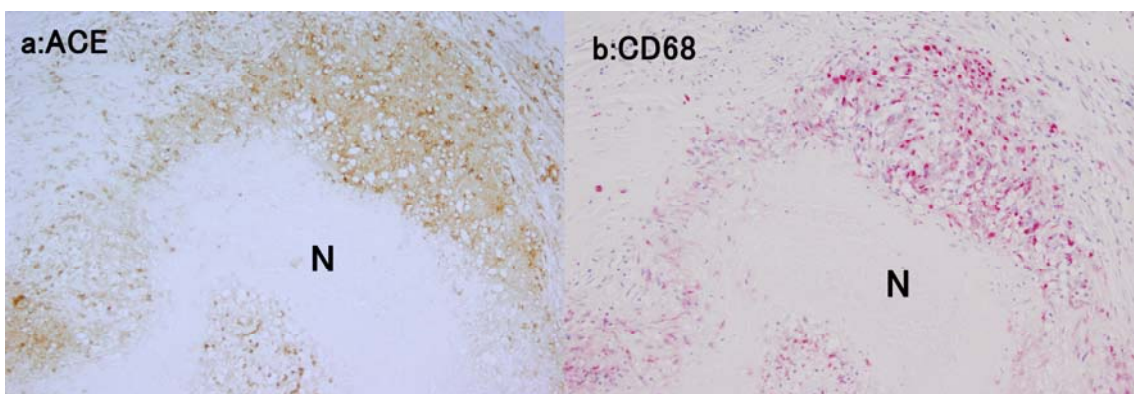
Figure 3.



Removed specimen of brain revealed noncaseating granulomas (a) as well as partial necrotizing granulomas (b). (hematoxylin and eosin; original magnification, a;×200, b; ×100) .

N:necrosis

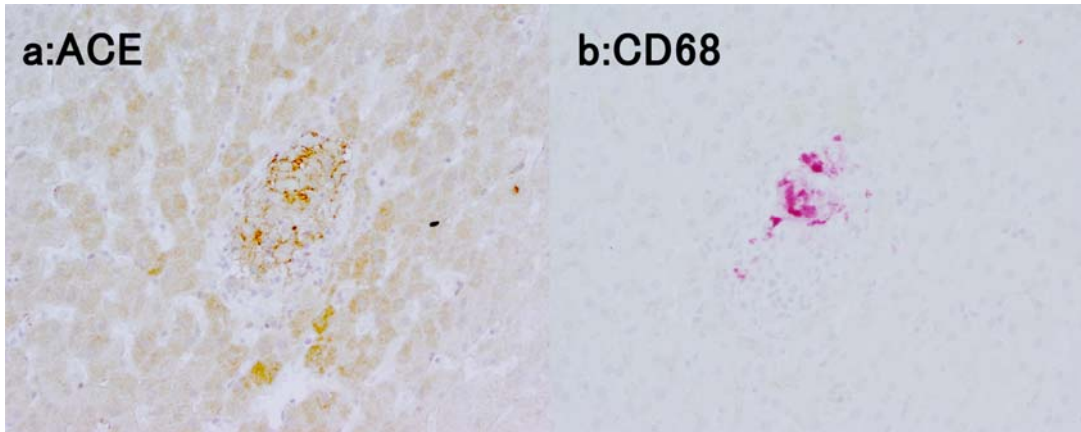
Figure 4.



Localization of ACE (a) and CD68 (b) : ACE and CD68 (macrophage) are co-localized in the marginal area of necrotic granuloma obtained from brain. (a;×200, b; ×200)

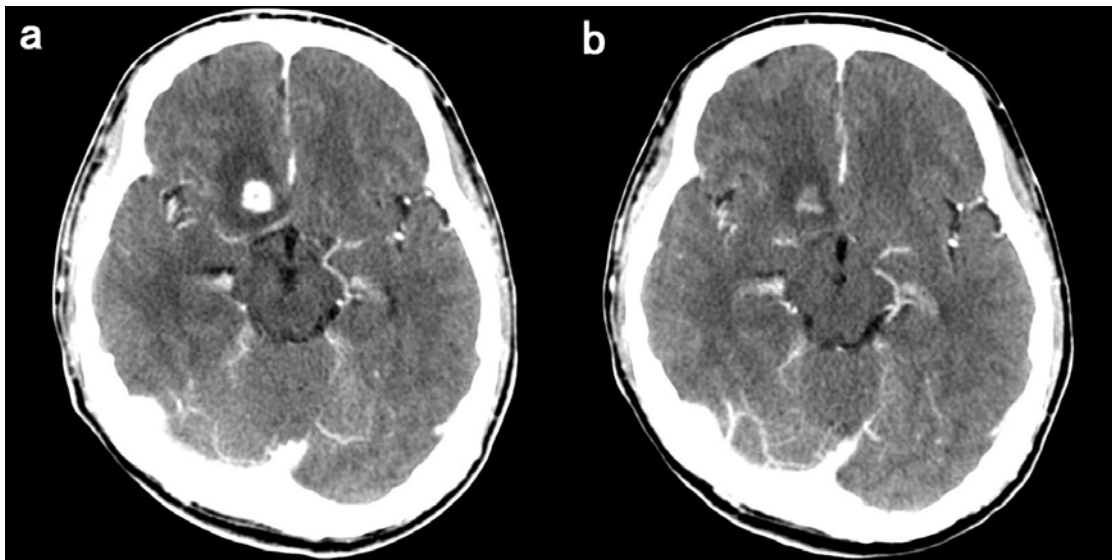
N:necrosis

Figure 5.



Localization of ACE (a) and CD68 (b) : ACE and CD68 (macrophage) are co-localized in noncaseating granuloma obtained from liver. (a;×400, b; ×400)

Figure 6.



Enhanced CT of the head; Before therapy (a) and at the six month after started oral steroid therapy (b) .

Nodular lesion in right frontal lobe is observed decreasing the size of lesions.

Table

Table 1 Laboratory findings on admission

Urinalysis		Complete blood cell count		Blood chemistry	
pH	5.5	WBC	3300/ μ l	Na	140 mEq/l
Glucose	-	Neu	64.5%	K	4.2 mEq/l
Protein	-	Lymph	23.4%	Cl	103 mEq/l
Occult blood	-	Mo	8.2%	Ca	9.5 mg/dl
WBC	1-4/HPF	Eos	3.3%	P	3.7 mg/dl
RBC	1-4/HPF	Baso	0.6%	BUN	13 mg/dl
		RBC	$553 \times 10^4/\mu$ l	Cr	0.82 mg/dl
Ca	10.3 mg/dl	Hb	16.5 g/dl	UA	5.4 mg/dl
NAG	1.25 IU/day	Ht	49.0%	AST	26 IU/l
β_2 MG	462 μ g/day	Plts	$20.3 \times 10^4/\mu$ l	ALT	23 IU/l
α_1 MG	11.4 mg/l			LDH	195 IU/l
24hrCcr	100.4 ml/min	Serology		γ GTP	39 IU/l
		IgG	1040 mg/dl	T-Bil	0.5 mg/dl
		IgA	132 mg/dl	TP	7.3 g/dl
		IgM	53 mg/dl	Alb	4.8 g/dl
		CH50	55 U/ml	T-cho	192 mg/dl
		C3c	129 mg/dl	TG	114 mg/dl
		C4	22 mg/dl	CK	78 IU/l
		RF	<10 IU/ml	CRP	0.1 mg/dl
		ANA	$\times 40$	ESR	3.0 mm/h
			homogeneous		
			speckled,		
		MPO-ANCA	<10 EU		
		PR3-ANCA	<10 EU		
		ACE	28.7 IU/l		

NAG: N-acetyl- β -D-glucosaminidase, β_2 MG: β_2 -microglobulin, α_1 MG: α_1 -microglobulin, Ccr: creatinine clearance, RF: rheumatoid factor, ANA: anti-nuclear antibody, MPO-ANCA: myeloperoxidase anti-neutrophilic cytoplasmic antibody, PR3-ANCA: serine proteinase 3 anti-neutrophilic cytoplasmic antibody, ACE: angiotensin converting enzyme