



REVISTA BRASILEIRA DE ANESTESIOLOGIA

Publicação Oficial da Sociedade Brasileira de Anestesiologia
www.sba.com.br



CLINICAL INFORMATION

Anesthesia for lower extremity vascular bypass with peripheral nerve block



Jordana de Fraga Guimarães^{a,*}, Cristine Formighieri Angonese^{b,c},
Rafael Klein Gomes^b, Vasco Miranda Junior^{a,b}, Carlos Farias^{b,d}

^a Universidade Federal de Ciências da Saúde de Porto Alegre, Porto Alegre, RS, Brazil

^b Complexo Hospitalar da Santa Casa de Misericórdia de Porto Alegre, Serviço de Anestesiologia, Porto Alegre, RS, Brazil

^c Hospital Sírio Libanês, São Paulo, SP, Brazil

^d Hospital Santa Clara, Santa Casa de Misericórdia de Porto Alegre, Porto Alegre, RS, Brazil

Received 30 June 2014; accepted 21 July 2014

Available online 17 September 2016

KEYWORDS

Femoral nerve block;
Sciatic nerve block;
Vascular surgery

Abstract Vascular bypass is a surgical procedure widely used to treat peripheral vascular disease. The intraoperative anesthetic technique and the most appropriate postoperative analgesia for these high-risk patients remain controversial. We present the case of a patient undergoing femoropopliteal-distal bypass in our service, presenting with relevant comorbidities to the choice of anesthetic technique. This patient had several determining factors of difficult airway, especially thoracic kyphoscoliosis, which prevented him from being properly positioned for airway management, and chronic lung disease. This patient was also taken antiplatelet drugs, which is a contraindication for neuraxial block. So, we chose the anesthetic technique of peripheral nerve block, specifically the blockade of femoral and sciatic nerves.

© 2015 Sociedade Brasileira de Anestesiologia. Published by Elsevier Editora Ltda. This is an open access article under the CC BY-NC-ND license (<http://creativecommons.org/licenses/by-nc-nd/4.0/>).

PALAVRAS-CHAVE

Bloqueio de nervo femoral;
Bloqueio de nervo isquiático;
Cirurgia vascular

Anestesia para *bypass* vascular em membro inferior com bloqueio de nervos periféricos

Resumo A cirurgia para *bypass* vascular é um procedimento amplamente usado para o tratamento da insuficiência vascular periférica. A técnica anestésica para o intraoperatório e para analgesia pós-operatória mais apropriada para esses pacientes de alto risco ainda permanece controversa. Apresentaremos o caso de um paciente submetido a *bypass* femoropoplíteo distal no nosso serviço, que apresentava comorbidades relevantes para a escolha da técnica

* Corresponding author.

E-mail: jordana_fguimaraes@yahoo.com.br (J.F. Guimarães).

anestésica. Esse paciente apresentava fatores determinantes de via aérea difícil, principalmente cifoescoliose da coluna torácica, que o impedia de ser posicionado adequadamente para o manejo da via aérea, além de ser portador de patologia pulmonar crônica. Também fazia uso de antiplaquetários que contraindicavam o bloqueio de neuroeixo. Por isso, optou-se como técnica anestésica pelo bloqueio de nervos periféricos, especificamente o bloqueio dos nervos femoral e isquiático.

© 2015 Sociedade Brasileira de Anestesiologia. Publicado por Elsevier Editora Ltda. Este é um artigo Open Access sob uma licença CC BY-NC-ND (<http://creativecommons.org/licenses/by-nc-nd/4.0/>).

Introduction

Chronic occlusive arterial disease of the lower extremities is one of the main forms of atherosclerosis presentation. This pathology, not only for its high prevalence, has a significant morbidity and mortality rate, and many patients undergo vascular bypass surgery for treatment. The anesthetic technique for surgery and more adequate post-operative analgesia in these high-risk patients undergoing femoropopliteal bypass remains controversial. We present the case of a patient with significant comorbidities for the choice of the anesthetic technique who underwent femoropopliteal bypass in our hospital.

Case report

IAB (male patient), 75 years old, white, presenting with congestive heart failure (class II), ischemic heart disease (acute myocardial infarction three years later, with coronary stent implantation), chronic atrial fibrillation, former smoker (quit smoking for 13 years). He also had important scoliosis and thoracolumbar kyphosis. Distal right femoropopliteal bypass for atherosclerotic peripheral vascular disease was proposed. The patient reports not having heart and respiratory symptoms during daily activities, functional capacity of 4 METs, though difficult to assess clinically. Classified as ASA III; denies allergies; taken the following medications: aspirin 200 mg.day⁻¹, clopidogrel 75 mg.day⁻¹, pentoxifylline 400 mg 2×.day⁻¹, simvastatin 40 mg.day⁻¹, furosemide 40 mg.day⁻¹, isosorbide 10 mg 3×.day⁻¹, digoxin 0.25 mg.day⁻¹ and omeprazole 20 mg.day⁻¹.

Account of previous procedures: angioplasty with stenting (2011) with sedation, left popliteal angioplasty (2011) with sedation and amputation of the left forefoot (2011) with regional block, all uneventful. Complete fast for eight hours. The patient and his family were informed about the surgical and anesthetic procedure and possible complications. After accepting the anesthetic protocol, the informed consent form was signed. On physical examination, weight 51 kg, height 1.70 m, blood pressure 150/70 mmHg, heart rate 88 bpm; lucid, oriented, and collaborative; cardiac auscultation with irregular rhythm, normal sounds, without murmurs; respiratory auscultation revealed breath sounds without adventitious sounds. Mallampati 4, limited neck mobility. He had important scoliosis and thoracic spine

kyphosis, which prevents the supine position; claims to be able to sleep only in the lateral position. Preoperative tests: hemoglobin 14 g.dL⁻¹; hematocrit 41%; platelets 22,400 mL; creatinine 1.5 mg.dL⁻¹; urea 53 mg.dL⁻¹; potassium 4.3 mEq.L⁻¹; sodium 141 mEq.L⁻¹; INR 1, APTT 38/2; ECG with ventricular rate of 100 beats.min⁻¹, atrial fibrillation and inferoposterior inactive zone; chest X-ray with increased heart volume and nodular image in the right lung base (Fig. 1).

In the operating room, the patient was placed supine with back and neck supported on cushions, so that the head remained supported (Fig. 2). Monitoring performed with cardioscopy, pulse oximetry, and noninvasive blood pressure. Peripheral vascular access performed with Abbot cath 18G. Oxygen (3 L.min⁻¹) was offered through nasal catheter. Material for difficult airway prepared in the OR. Intravenous cefazolin 1 g was administered. Sedation was performed initially with bolus midazolam 1 mg and fentanyl 75 mcg. Femoral and sciatic nerve block was performed, infragluteal approach (Raj technique) with the aid of neurostimulator and A100 mm needle. Ropivacaine 0.75% (total dose 300 mg)+lidocaine 1% were administered without vasoconstrictor (total dose 50 mg). Intraoperatively, the patient received continuous infusion of propofol, clonidine, and ketamine, maintaining a conscious sedation level. During the procedure, heparin 5000 units was administered before clamping the femoral artery and reversed with protamine 2500 units by the end of surgery. The procedure lasted three hours and 30 min without complications. In the postoperative visit the next day, the patient presented with minimal pain in the right lower limb (3/10 on numerical scale) and without motor blockade; he was receiving analgesia with oral non-opioid analgesics and intravenous anti-inflammatory.

Discussion

Chronic arterial occlusion is a disease that most often results from atherosclerosis. In general, patients are asymptomatic because there is compensatory collateral circulation; however, when multiple vessels are affected, the main symptom appears: intermittent claudication (muscle pain or fatigue in the lower limbs triggered by exertion and relieved by rest). It should be noted that the peripheral vascular disease is a risk factor strongly associated with early death.

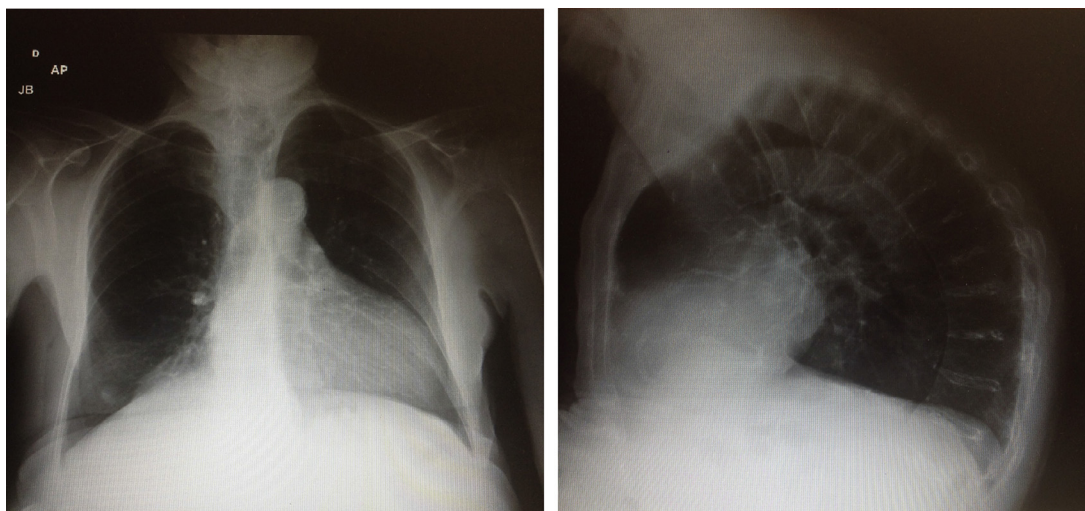


Figure 1 Preoperative chest X-ray.

Nonsurgical treatment includes control of risk factors, exercise, and drug therapy. Surgical treatment options include percutaneous endovascular techniques and surgical repairs. The indications for revascularization or bypass surgery for occlusions below the inguinal ligament include intermittent claudication, ischemic rest pain, or ulceration/gangrene.¹ Usually, the used autologous graft is saphenous vein, and patency rates and with this approach are 59% in 5 years and 38% in 10 years.^{2,3}

In the preoperative evaluation, it is important to know the drugs routinely used by patients. Antiplatelet and/or anticoagulant are very often prescribed and guidance for suspension/maintenance must be evaluated individually

and together with the surgical team. For patients with chronic use of beta-blockers and aspirin, its maintenance is important.³

The intraoperative anesthetic technique and the most appropriate postoperative analgesia for these high-risk patients with chronic peripheral vascular disease undergoing femoropopliteal bypass remains controversial. Several techniques have been successfully used for lower limb vascular reconstruction, such as general anesthesia (balanced or total intravenous), regional anesthesia (spinal or epidural), or combined. Peripheral nerve blocks are an alternative to general anesthesia and regional neuraxial blocks in some infrequent clinical situations.^{2,4}

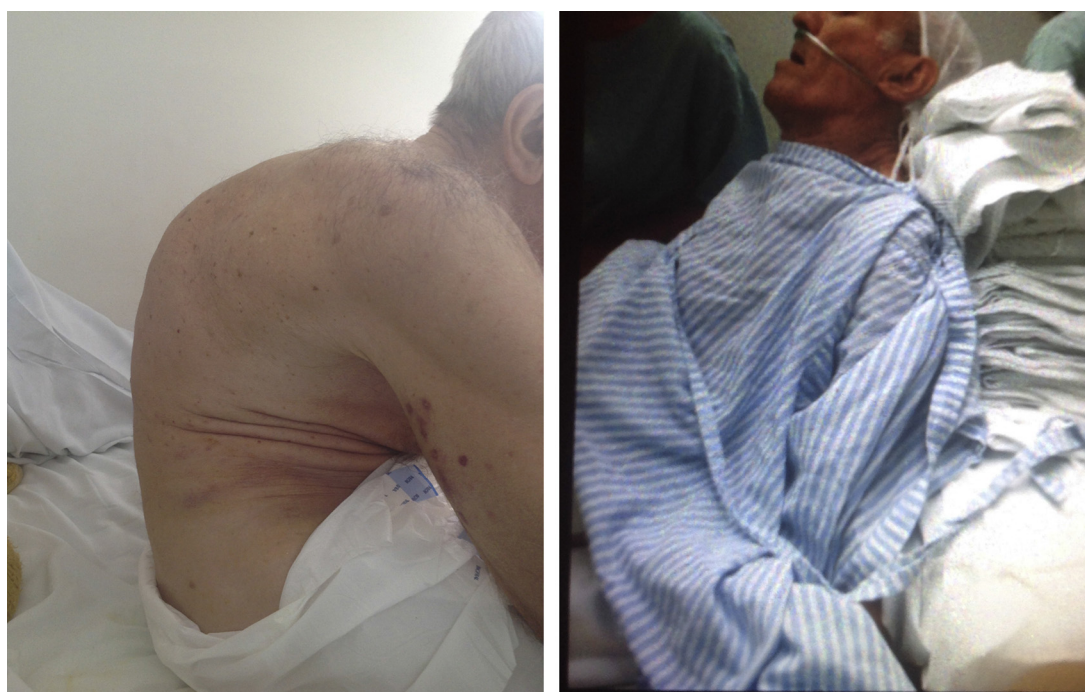

Figure 2 Patient positioning in the operating room.

General anesthesia offers the advantage of easy hemodynamic control during surgery and no patient discomfort in long procedures; however, it does not inhibit postoperative hypercoagulability. On the other hand, regional blockade is effective in blocking the response to surgical stress and in postoperative analgesia; however, it is a difficult technique, particularly in patients who are obese, uncooperative, with kyphoscoliosis or previous spinal instrumentation, in addition to its limited duration for long procedures, such as spinal anesthesia. Another point to be considered is the common use of antiplatelets, anticoagulants, and thrombolytics in this population that contraindicate techniques addressing the neuraxis.^{2,5}

In this context, many authors have considered the use of peripheral nerve block techniques, especially when there is relative contraindication to regional block due to the use of drugs affecting coagulation. Postoperative analgesia induced by peripheral nerve block techniques can be extended for up to 24h. As the airway instrumentation or the use of inhaled agents or neuromuscular blockers is not required, it is a good option for patients with significant pulmonary disease.

The use of this technique, however, must be done with caution in anticoagulated patients, particularly if the nerve to be blocked is close to deep or major vascular structures. One should also be aware of systemic toxicity related to high doses of local anesthetics, usually required for lower limb blockades.² Lower limb peripheral nerve block contraindications are patient refusal, coagulopathy, infection at the puncture site and systemic, hypersensitivity to local anesthetics, and previous neurological damage. Possible adverse effects include neurological damage by intraneural injection, local anesthetic intoxication, local and/or systemic infection, and bruising at the puncture site.^{6,7}

In short, one should opt for the specific anesthetic technique for each patient and more familiar to each institution.² Regardless of the technique used, the overall improvement of perioperative care must be emphasized, as it is the single most important factor related to improved postoperative outcomes.³

Intraoperative monitoring, besides continuous ECG with ST-segment analysis, should include in most cases intra-arterial pressure, in order to improve blood flow to the operated limb and facilitate blood sample collection. The indwelling catheter is routine due to the duration of surgery and to assess intravascular volume. The central venous access should be considered in patients with significant renal or heart failure or those with inappropriate peripheral venous access.^{2,3}

Morbidity and mortality in this kind of surgery is mainly of cardiac origin, often appears in the postoperative period. The incidence of perioperative cardiac events is 10 times higher in patients undergoing vascular surgery than in non-vascular surgical patients. The published studies comparing general versus regional anesthesia for lower limb bypass showed no significant differences in mortality, myocardial infarction, myocardial ischemia, or congestive heart failure. Only some changes in secondary or combined cardiac outcomes were found in some studies.^{2,3}

A secondary but significant clinical finding of these studies is the beneficial effect of regional anesthesia on lower

limb graft patency in the postoperative period. Regional anesthesia was associated with a five-fold reduction of the vascular graft occlusion rate. Most graft occlusions occur between the first and third day after surgery, and this difference in outcome between different anesthetic techniques remained for a longer period (six weeks or more).

One possible explanation for this finding is that general anesthesia is associated with a hypercoagulable state postoperatively (increased levels of fibrinogen and platelet reactivity associated with surgical stress), which is mitigated by regional anesthesia. Another mechanism for increasing lower limb graft patency with regional anesthesia may be the increased blood flow to the limb associated with the sympathectomy.^{2,3}

Postoperative analgesia and anxiety are an important point to be considered, as the response to surgical stress and risk of myocardial ischemia are maximum in that moment. Epidural techniques with local anesthetics and opioids administered by continuous infusion or patient-controlled analgesia and intravenous techniques classically administered by patient-controlled analgesia are both correlated with good pain control.

The intravascular volume should be enhanced with careful control of heart rate and blood pressure. One should be aware of the sympathectomy resolution time, with the intravascular space contraction and the risk of congestive heart failure. Anemia should be avoided by maintaining hemoglobin above 9 g.dL⁻¹. Peripheral pulses should be checked frequently to assess the graft patency.³

Sciatic nerve block – posterior technique (Raj's technique)

Sciatic nerve block is easy and quick to perform when using neurostimulator and/or sonographic techniques. Besides its uncommon complications, it is a good technique for lower limb anesthesia and analgesia. It can be combined with other blocks, such as femoral or saphenous nerve blockade, to virtually any surgical procedure below the knee that require no tourniquet (femorocutaneous, obturator, femoral, 3-1 or saphenous). Associated with femoral nerve block, it provides knee, leg, and foot analgesia. Associated with posterior lumbar plexus block, it provides femur, thigh, knee, leg, and foot analgesia.⁶

The sciatic nerve is formed by the union of the lumbosacral trunk L4–L5 and anterior branches of the S1–S3 roots.^{6,8} This is the largest of the four major peripheral nerves in lower limbs. It emerges from the pelvis through the sacrum sciatic foramen, passes below the piriformis muscle in a deep plane in the gluteal region, then goes down the midline of the back of the thigh, and divide itself in the popliteal fossa in tibial nerve and fibular (or peroneal) common nerve.

The sciatic nerve, through its collateral branches, provides sensory and motor innervation to the muscles of the entire posterior surface of the thigh, leg, and foot, except the anterior-inner leg, whose innervation is made by the saphenous nerve, sensitive terminal branch of femoral nerve. The posterior tibial nerve originates the sural nerve or external saphenous, which is responsible

for sensory and motor innervation throughout the back of the leg and plantar foot (plantar flexion). The common peroneal nerve is responsible for sensory and motor innervation of the entire dorsal surface of the foot (dorsiflexion).^{3,6}

Several approaches have been reported for sciatic nerve block. Due to its great length, it can be blocked at virtually any point. In our patient, we chose Raj's technique (posterior approach). For such, the patient should be placed in the lithotomy position, supported by an assistant. The reference points are the greater trochanter and the ischial tuberosity (ischium), in which a line should be drawn. A 22G, 9 cm needle with the neurostimulator is inserted perpendicular to the skin in the middle of this line and slowly advanced, with an initial current of 2 mA.

The tibial nerve expected motor response is plantar flexion of the foot and toes; and the common peroneal nerve response is dorsiflexion or foot eversion and extension of the toes. The reported local anesthetics are bupivacaine 0.375% with or without vasoconstrictor, lidocaine 1.5% with or without vasoconstrictor, ropivacaine 0.5–0.75% with volumes of approximately 20–30 mL. Local anesthetic should be injected with a minimal evoked muscle response of 0.5 mA. It should be noted that this technique does not block the posterior cutaneous nerve of the thigh and an assistant is required for properly positioning the patient.^{3,6,8,9}

Femoral nerve block

The femoral or crural nerve is also a quick and easy procedure to be performed; it may be combined with other regional blocks (femoral cutaneous, obturator, 3-1). The technique may be applied with or without nerve stimulator aid (doubly guided). Classically, this blockade is used for anesthesia and postoperative analgesia for knee (arthroplasty, reconstruction of the anterior and posterior cruciate ligament, tibial plateau fracture, and patella fracture), hip (arthroplasty, femoral neck fracture), and thigh (transtrochanteric, diaphyseal femoral, and femoral condyle fractures) surgeries. This blockade is also useful to facilitate the transport and placement of patients with hip fracture, early physical therapy rehabilitation, as well as for early mobilization of patients.^{7,8}

Femoral nerve is formed by the roots of L2–L4, enters the thigh posterior to the inguinal ligament and passes laterally to the femoral vessels. It is located in a slightly deeper position (0.5–1.0 cm) and lateral to the femoral artery (about 1.5 cm). There are two fascias: fascia lata, which passes over the nerve and over the vessel, and iliac fascia that passes over the nerve, but below the femoral vessels. This supplies motor innervation to the anterior thigh muscle store and originates the internal saphenous nerve, which is a sensory branch to the internal anterior side of the knee and leg.^{3,7,8}

Femoral nerve block provides analgesia in the anterior side of the thigh skin, most of the hip joint, femoral periosteum, knee joint, quadriceps muscle, and skin of the medial side of the leg and foot (saphenous sensory branch). In a variable percentage of patients, this blockade also extends to the thigh lateral cutaneous (analgesia of the skin on the

lateral side of the thigh) and obturator nerves (medial thigh and adductor muscles of the thigh), and thus contributes to analgesia of hip and knee joints.^{7–9}

The patient should be positioned supine and the leg to be blocked should be slightly rotated externally. Reference points are the anterior superior iliac spine, lateral edge of the pubis, and inguinal ligament. One should palpate the femoral artery pulse, protect it with two fingers — 2 cm below the inguinal ligament and 1 cm lateral to the femoral artery pulse is the intradermal injection point. The neurostimulation needle (22G, 4 cm) should be slowly introduced in cranial direction. The expected motor response is the upward jerk of the patella and quadriceps contraction with 0.3–0.5 mA. The volume of local anesthetic used is 20–30 mL after negative aspiration.^{3,7,8}

The presence of femoral vascular graft is a relative contraindication to this technique. Furthermore, there may be important anatomical variations, such as femoral nerve far from femoral artery or thin and wide femoral nerve, which can hamper the blockade.⁷

Conclusion

There are several possible anesthetic techniques for patients undergoing femoropopliteal bypass. In this case, the patient's condition, associated with the presence of various comorbidities, difficult airway, severe pulmonary disease, spinal deformity, as well as a formal contraindication to neuraxial blockade, led us to choose the regional anesthesia. Thus, after taking all precautions and options to manage a difficult airway if necessary, we chose peripheral nerve block as an anesthetic technique, in this case the blockade of femoral and sciatic nerves. The surgery went safely and uneventful and without discomfort to the patient, in addition to providing a quality and satisfactory postoperative analgesia for the patient.

Conflicts of interest

The authors declare no conflicts of interest.

References

1. Helayel PE, Conceição DB, Feix C, et al. Bloqueio isquiaticofemoral guiado por ultrassom para revisão de coto de amputação. *Relato de caso. Rev Brasil Anestesiol.* 2008;58:480–4.
2. Miller RD, Eriksson LI, Fleisher L, Wiener-Kronish JP, Young WL. *Miller's Anesthesia.* 7th ed. Churchill Livingstone: Londres; 2013.
3. Cangiani LM, Slullitel A, Potério GMB, et al. *Tratado de anestesiologia.* 7th ed. São Paulo: Editora Atheneu; 2011.
4. Yazigi A, Madi-Gebara S, Haddad F, et al. Combined sciatic and femoral nerve blocks for infrainguinal arterial bypass surgery: a case series. *J Cardiothorac Vasc Anesth.* 2005;19:220–1.
5. Noorani R, Rock P. Regional versus general anesthesia for vascular surgery patients. *Am Soc Anesthesiol.* 2009.
6. Hamaji A, Cunha Junior W, Hamaji MWM. Bloqueio do nervo isquiático. In: Luiz Marciano Cangiani, Eduardo Ren Nakashima, et al., editors. *Atlas de técnicas de bloqueios regionais.* 3rd ed.

- Rio de Janeiro: Sociedade Brasileira de Anestesiologia/SBA; 2013. p. 369–82.
7. Ruzi RA. Bloqueio do nervo femoral. In: Luiz Marciano Cangiani, Eduardo Ren Nakashima, et al., editors. Atlas de técnicas de bloqueios regionais. 3rd ed. Rio de Janeiro: Sociedade Brasileira de Anestesiologia/SBA; 2013. p. 391–6.
 8. Jegier MA, Leone FJ, et al. Manual de Anestesiologia: Conceitos e Aplicações para a Prática Diária. 3rd ed. Porto Alegre: Artmed; 2007.
 9. Enneking FK, Chan V, Greger J, et al. Lower-extremity peripheral nerve blockade: essentials of our current understanding. *Reg Anesth Pain Med.* 2005;30:4–35.