

## Vulvar Myiasis

M.R.L. Passos,\* A.V.V. Carvalho, A.L. Dutra, R.A. Goulart Filho,  
N.A. Barreto, R.S. Salles, C.C.C. Santos, A.S. Tibúrcio,  
A.C.S. Monteiro, and R.R. Tavares

*Sexually Transmitted Disease Sector, Fluminense Federal University, Rio de Janeiro, Brazil*

### ABSTRACT

Myiasis is a parasitic infestation caused by larvae of several fly species. Diagnosis and treatment are simple. This infestation is, however, rarely seen in the vulvar area. We present a short review of the disease and the case of a 19-year-old pregnant girl with vulvar myiasis and concomitant syphilis, vaginal trichomoniasis and genital candidiasis. The patient was also positive for human immunodeficiency virus. *Infect. Dis. Obstet. Gynecol.* 6:69–71, 1998. © 1998 Wiley-Liss, Inc.

### KEY WORDS

vulvar myiasis; hygiene; parasitism

### INTRODUCTION: HUMAN MYIASIS

Myiasis is a disease of medical and veterinary importance, particularly in the tropical and subtropical regions where the causative fly species are common.

Human myiasis is produced by fly larvae capable of penetrating healthy or necrotic human tissue and cavities. Those that invade healthy tissue are called biontophage species and are responsible for the cutaneous form (myiasis furunculoides). This group comprises *Dermatobia hominis* (the most frequent), *Cochilomya hominivorax*, and *Oestrus ovis*. The necrotic tissue-invading group includes the genera *Sarcophaga*, *Lucilia*, *Callitroga*, *Musca*, and the *Muscida Fannia* species, which causes cavitory myiasis.

In furunculoid or primary myiasis the maggots penetrate the skin, leading to painful inflammatory nodules with fistulae. The fistulae ooze serum or bloody exudate, and it is possible to see the movements of the larvae. Patients describe an occasional stinging sensation. Secondary bacterial infection and, rarely, tetanus may complicate the primary disease.

Cavitory or secondary myiasis occurs by infestation of cavities or ulcerated mucous membranes. The most affected areas are the nasal sinus, the ear canal, and the ocular globes. The clinical exam frequently shows great numbers of larvae moving inside the ulcer or cavity.

The disease is benign, and treatment consists of removal of the parasites and cleansing of the area. Furunculoid myiasis can be treated by the occlusion of the fistulae with vaseline or nail enamel so that larvae are not allowed to breathe. Being thus immobilized the larvae are removed with tweezers as the nodule is gently pressed. When necessary a small surgical incision is made. After removal of larvae, the area is cleansed and covered with antibiotic ointment.

### OBJECTIVES

We report the case of a pregnant patient with concomitant genital myiasis, syphilis, trichomoniasis, genital candidiasis and human immunodeficiency virus (HIV) infection.

\*Correspondence to: Dr. Mauro Romero Leal Passos, Universidade Federal Fluminense, Campus do Valonguinho, Outeiro de São João Batista, Niterói—Rio de Janeiro—BRASIL 24210-150. E-mail: mipmaur@vm.uff.br

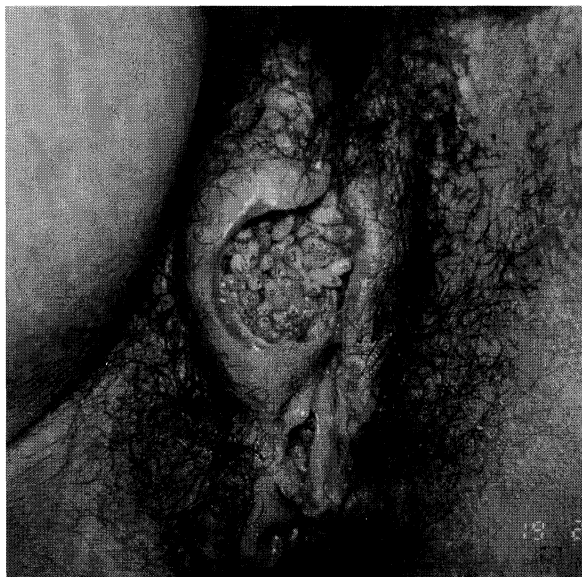


Fig. 1. Large cavitory lesion containing more than a hundred maggots.

#### MATERIALS AND METHODS

A 19-year-old female patient, single, with multiple sexual partners, was examined at the Sexually Transmitted Diseases Sector of the Fluminense Federal University in Niterói, Rio de Janeiro. The intense pain she felt allowed only the exam of the external genitalia. A cavitory lesion with larvae was then seen (Fig. 1).

The patient was taken to the University's hospital, Hospital Antônio Pedro, where under peridural anesthesia more than a hundred maggots were removed. Two weeks after surgical cleaning the patient returned to our STD clinic for follow up. At this time we collected material for both fresh and stained cytopathologic exams. Serologic testing for syphilis and HIV were done as part of our routine procedures.

The patient returned several other times. Complete cicatrization of the wound was achieved (Fig. 2).

#### RESULTS

The larvae were sent to the laboratory, where, after maturation, they were identified as belonging to the genus *Sarcophaga*. Fresh and stained cytopathology revealed candidiasis and trichomoniasis.

Conventional treatment for these diseases was prescribed. The serologic tests for syphilis and HIV were positive. After 30 days the genital lesions

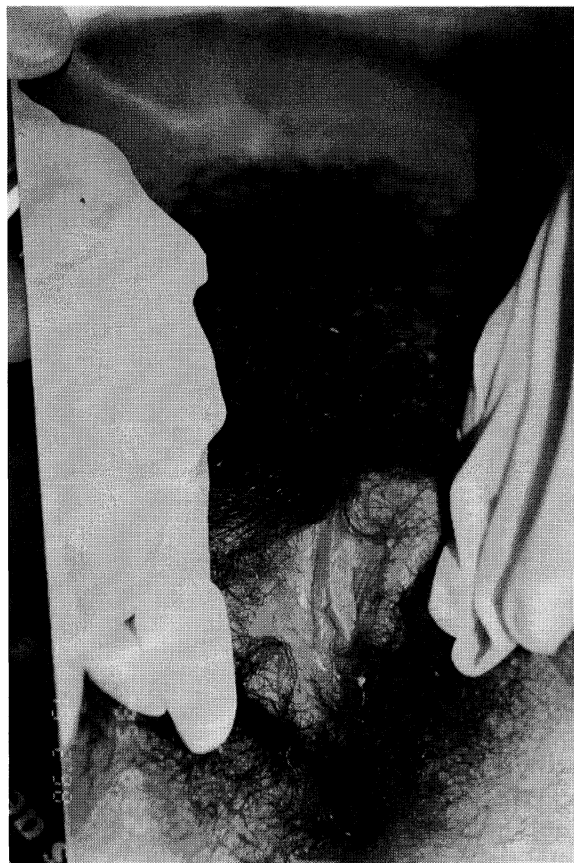

Fig. 2. The area shows complete wound cicatrization. Pregnancy was already evident.

were in an advanced stage of cicatrization. At this point the patient reported her menstrual period was late. Her pregnancy test was positive.

#### DISCUSSION AND CONCLUSIONS

Myiasis is more common in rural areas. In urban areas this pathology is usually found among people with poor hygienic habits and low education level and among children. This disease occurs mostly on uncovered parts of the body, such as the arms and legs (furunculoid myiasis) and head (cavitory myiasis).

Localization at the genital area is rare, with few reports in the literature. This finding is usually associated with promiscuous sexual behavior. Our patient had multiple sexual partners.

Gomes, Cucé and Fukagawa<sup>1</sup> also reported one case of vulvar myiasis in an 18-year-old girl with promiscuous sexual behavior. Picó and colleagues<sup>2</sup> described a case of vulvar myiasis in a diabetic 86-year-old women.

It is interesting to remark that, although the possible causative agents of myiasis are many our patient and two others described in the medical literature were infected by larvae of the same genus, *Sarcophaga*, which only occasionally infest human tissue. Saleh and Sibae<sup>3</sup> described three cases of genital myiasis caused by *Piophilina casei*, another fly.

We emphasize the need for a careful genital exam to identify less common diseases. The doctor's role in educating patients is also important and must include the stimulation of the development of good hygienic habits among all patients. Simple acts such as regular soap-and-water bathing can prevent diseases such as the one we have described. Our patient, although she did not live on the streets, obviously had very poor hygienic habits. It is our opinion that the flies which laid the eggs on these genital lesions were attracted to them by the foul smell caused by multiple infections. Having not been quickly removed by personal hygiene, the larvae grew, which led to an inflammatory process.

We would also like to emphasize the importance of offering serologic testing for syphilis and HIV infection to every patient with genital disease.

#### REFERENCES

1. Gomes PA, Cucé LC, Fukagawa MFN, et al.: Míase vulvar. *Jornal Brasileiro de Medicina* 70(4):106–7, 1996.
2. Picó GCF, et al.: Miiasis genital humana por *Sarcophaga*. *Revista Clínica Española*, pp 189–190, 1992.
3. Saleh MS, Sibae MM: Urogenital myiasis due to *Piophilina casei*. *Egypt Soc Parasitol* 23:737–739, 1993.

#### BIBLIOGRAPHY

- Pessoa SB, Martins AV: *Parasitologia Médica*. 11th ed. Rio de Janeiro, Guanabara Koogan, pp 808–811, 1982.
- Ministério da Saúde, Fundação Nacional de Saúde: *Guia para o diagnóstico e tratamento das principais dermatoses da infância de interesse sanitário*. Brasília, 1994.
- Bakos L: *Zoodermatoses*. In Ducan, BB, Schmidt MI, Giuliani ERJ (eds): *Medicina Ambulatorial. Condutas Clínicas em Atenção Primária*. 3rd ed. Porto Alegre, Srtes Médicas, pp 496, 1992.



**Hindawi**  
Submit your manuscripts at  
<http://www.hindawi.com>

