



UNIVERSITY OF AMSTERDAM

UvA-DARE (Digital Academic Repository)

Intraoperative search for neuroblastoma by MIBG and radioguided surgery with the gamma detector

Heij, H.A.; Rutgers, E.J.T.; de Kraker, J.; Vos, A.

Published in:
Medical and Pediatric Oncology

DOI:
[10.1002/\(SICI\)1096-911X\(199703\)28:3<171::AID-MPO2>3.0.CO;2-G](https://doi.org/10.1002/(SICI)1096-911X(199703)28:3<171::AID-MPO2>3.0.CO;2-G)

[Link to publication](#)

Citation for published version (APA):

Heij, H. A., Rutgers, E. J. T., de Kraker, J., & Vos, A. (1997). Intraoperative search for neuroblastoma by MIBG and radioguided surgery with the gamma detector. *Medical and Pediatric Oncology*, 28, 171-174. 3.0.CO;2-G" class="link">[https://doi.org/10.1002/\(SICI\)1096-911X\(199703\)28:33.0.CO;2-G](https://doi.org/10.1002/(SICI)1096-911X(199703)28:33.0.CO;2-G)

General rights

It is not permitted to download or to forward/distribute the text or part of it without the consent of the author(s) and/or copyright holder(s), other than for strictly personal, individual use, unless the work is under an open content license (like Creative Commons).

Disclaimer/Complaints regulations

If you believe that digital publication of certain material infringes any of your rights or (privacy) interests, please let the Library know, stating your reasons. In case of a legitimate complaint, the Library will make the material inaccessible and/or remove it from the website. Please Ask the Library: <https://uba.uva.nl/en/contact>, or a letter to: Library of the University of Amsterdam, Secretariat, Singel 425, 1012 WP Amsterdam, The Netherlands. You will be contacted as soon as possible.

UvA-DARE is a service provided by the library of the University of Amsterdam (<http://dare.uva.nl>)

Intraoperative Search for Neuroblastoma by MIBG and Radioguided Surgery With the Gamma Detector

Hugo A. Heij, MD, ScD,^{1*} Emiel J.Th Rutgers, MD, PhD,³ Jan de Kraker, MD, PhD,² and Anton Vos, MD, ScD¹

Administration of a tumour-seeking compound labeled with a low-energy isotope and intraoperative screening with the gamma probe (radioguided surgery, RGS) could be useful in reoperations for advanced neuroblastoma when the normal anatomy is altered. A pilot study was performed to test the feasibility of this technique. Five patients underwent six relaparotomies for recurrent stage III or IV neuroblastoma. All had been treated with intensive chemotherapy and/or metaiodobenzylguanidine (MIBG)-I¹³¹ with or without hyperbaric oxygen. Reoperation was performed to achieve near-total (greater than 95%) excision. In all instances, active tumour was seen on the preoperative MIBG scan. Before the operation, a tracer dose of MIBG- I¹²³ was

given. At laparotomy, a search was made with the gamma probe for areas of increased activity.

The gamma probe correctly identified active neuroblastoma tissue that was seen on the preoperative MIBG scan. There appeared to be a relationship between intensity of radioactivity and degree of maturation on histologic examination. This pilot study shows that RGS with MIBG and intraoperative use of the gamma probe is able to identify recurrent neuroblastoma. Whether this method is able to detect occult tumour and whether RGS will result in better outcome are the subjects of ongoing research.

Med. Pediatr. Oncol. 28:171-174

© 1997 Wiley-Liss, Inc.

Key words: neuroblastoma; radioguided surgery; metaiodobenzylguanidine (MIBG); gamma probe

INTRODUCTION

Reoperations for advanced neuroblastoma are indicated when the primary operation was irradical and postoperative chemotherapy has achieved sufficient reduction to allow successful reexcision. Alternatively, recurrence after initial macroscopic complete excision may necessitate reoperation. In these cases, it can be difficult to identify the exact localisation of tumour tissue because of altered anatomy. Administration of a tumour-seeking compound labeled with a low-energy isotope and intraoperative screening with a gamma probe (radioguided surgery, RGS) may be helpful. This technique has been applied successfully in colorectal and breast cancer using radioimmunolabeling [1-3]. In neuroblastoma, vital tumour cells are known to take up metaiodobenzylguanidine (MIBG). Radioactive MIBG, labeled with I¹³¹ or I¹²³, is applied for diagnostic and therapeutic purposes [4,5].

A pilot study was performed to test the feasibility of using MIBG and the gamma probe for intraoperative localisation of neuroblastoma.

PATIENTS AND METHODS

Five patients underwent six relaparotomies for recurrent stage III or IV abdominal neuroblastoma (Table I). All had been treated with intensive chemotherapy and/or MIBG- I¹³¹ with or without hyperbaric oxygen. Reoper-

ation was performed to achieve near-total (greater than 95%) excision. In all instances, active tumour was seen on the preoperative diagnostic MIBG scan. Ultrasound (US), computerized tomography (CT) scan, or magnetic resonance imaging (MRI) interpretations were hampered by the previous operations. Two days before surgery, a tracer dose of MIBG-I¹²³ was given (185 mBeq). After opening of the abdominal cavity and lysis of adhesions, a full exploration was performed, with the careful noting of all visible and/or palpable abnormalities. As a schematic aid, the abdomen was divided into four areas: the liver, the upper abdomen cranially from the transverse mesocolon, the lower abdomen bordered by the colon, and the pelvis below the promontory. Subsequently, the four parts of the abdomen were scanned consecutively with a hand-held gamma probe (Figs. 1 and 2; Neoprobe 1000; Neoprobe Corp., Columbus OH) packed in a sterile cover. In addition, any suspicious area is screened with the gamma probe. Background counts are recorded at the

¹Paediatric Surgical Centre Amsterdam; ²Department of Paediatric Oncology, Emma Kinderziekenhuis/Kinder AMC; ³Department of Surgery, The Netherlands Cancer Institute/Antoni van Leeuwenhoekhuis.

*Correspondence to: A. Vos, MD, Department of Paediatric Surgery, Emma Kinderziekenhuis AMC, Meibergdreef 9, 1105 AZ Amsterdam, The Netherlands.

Received 15 December 1995; accepted 10 May 1996.

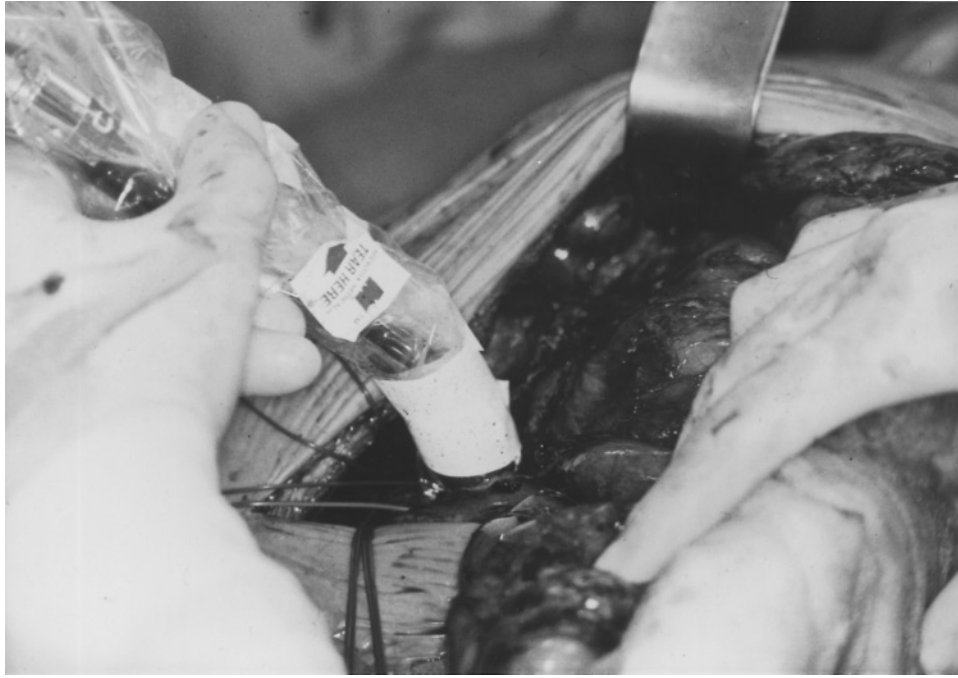


Fig. 1. Protocol form.




Fig. 2. Neoprobe control unit.

standard locations of the mid-ileum, right and left liver lobes, and spleen after surgical exposure. Background activity is determined by the tissue that is scanned; if liver tissue is explored, the probe counts on apparently normal tissue are squelched to zero. All counts higher than the background are recognized by an audible siren produced by the probe. Para-aortal or paracaval tissue is scanned after measuring background activity in the caval

vein. The highest mean counts were recorded. The exact size of the tumour was not always easy to estimate because of surrounding fibrosis.

Any clinically suspicious tissue—with or without elevated gamma counts—was excised. Tissues with elevated gamma counts without clinical suspicion were, whenever visible, biopsied for microscopic examination. After complete excision, the tumour bed was scanned for any residual activity.

The highest tumour counts related to the background normal tissue counts were recorded. Ex vivo tissue counts by a well counter were not performed. The exact amount of tumour-containing tissue was clinically difficult to assess as a result of surrounding fibrosis.

Minimal standard measurements were taken after the study protocol as shown in Figure 1. A tumour to background ratio of 2 or more was considered significant. For maximal reproducibility, it was important that the position of the probe was moved slowly over the examined tissue after squelching of the background radiation. Counts per 2 seconds were taken from the regions of interest and recorded on the protocol form.

RESULTS

The gamma probe correctly identified active neuroblastoma tissue that was seen on the preoperative MIBG scan. In Patient D, a persistent area of increased activity was seen near the right kidney without macroscopic abnormality. No tissue was excised in this area because that

TABLE I. Details of 6 relaparotomies in 5 patients

Patient no.	age (y/m)	localisation prim tumour	previous therapy
A	3/11	Rt adrenal	MIBG → incompl res → CT + ABMT
B	3/8	Rt adrenal	CT → resection2 → MIBG
C	7/2	symp chain	CT → resection → MIBG
D	13/6	Rt symp chain	CT → resection
D	14/3	idem	CT + ABMT
E	7/0	Rt adrenal	CT → resection → re-resection → MIBG + HBO

Legend:

CT = chemotherapy

ABMT = autologous bone marrow transplant

HBO = hyperbaric oxygen

MIBG = metaiodobenzylguanidine labeled with J-131

TABLE II. Intra-operative Tumour Activity and Histology in 4 Patients

Pt no	Counts/2 sec over		T/NT ratio by probe	histology
	tumour	spleen		
A	700	350	2	GN/GNB
B	1800	900	2	GNB
C	10 850	1800	6	GNB
D	4800	600	8	NB

Legend

NG = neuroblastoma

GNB = ganglioneuroblastoma

GN = ganglioneuroma

T/NT = tumour/no tumour.

could have endangered the blood supply to the kidney. After 9 months, tumour relapse in this area was confirmed at reoperation, in which the gamma probe was used. In the same patient, US revealed a mass that was not shown on the MIBG scan. The gamma probe demonstrated no increased activity, and the mass appeared to be a lymphocele. This lymphocele was discovered during the first relaparotomy in which we used the gamma probe. The area with increased activity near the right kidney found at this procedure revealed no macroscopic tumour at that time, but was found to be the site of relapse 9 months later.

The intensity of radioactivity varied considerably (Table II). From these data, there appears to be a correlation between the number of counts in situ and the degree of maturity on histologic examination.

DISCUSSION

This pilot study shows that it is possible to identify recurrent neuroblastoma with RGS with a tracer dose of I^{123} MIBG and intraoperative use of the gamma probe. In one patient, RGS-positive localisation without clinical evidence of tumour appeared to be the site of tumour recurrence, confirmed by relaparotomy 9 months later. During the initial laparotomy, a cyst-like structure in the

right para-iliac region was also found. This cyst was RGS negative and turned out to be a lymphocele on histology after resection. This pilot experience also suggests that the intensity of radioactivity might be related to the degree of maturation of the tumour. Unfortunately, in this pilot study we did not perform ex vivo measurement of counts per gram excised tissue using a well counter. Therefore, no information was available about ex vivo tumour to nontumour counts/ratio, since counts per gram tissue can only be obtained ex vivo. Statistical analysis of the correlation between tumour size and counts was not performed in this study, but should be part of future protocols and related to the histology of the tumour. An inherent problem of recurrent neuroblastoma is distinguishing between fibrotic tissue and tumour. Inevitably, some amount of fibrous tissue will be included during excision, which makes it difficult to explore the correlation between tumour size and radioactivity as measured by the gamma probe. Considering our positive clinical experience with these five patients, further study is warranted. This RGS system with I^{123} MIBG might be helpful.

Concerning the safety of RGS using a tracer dose of I^{123} , it is clear that the use of I^{123} is not a radiation risk. The half-life of I^{123} is 13.2 hours, and this isotope is a low-energy inhibitor of 159 Kev. With the administration of a tracer dose of 185 mBeq, the gamma radiation exposure is extremely low, with minimal hazard for the patient, surgeon, or operating room personnel. Even the use of I^{125} (energy 35 Kev isotope with a half-life of 60.2 days) with larger doses does not produce any significant radiation risk [6].

CONCLUSIONS

From this limited experience, we can conclude that the method is both specific and sensitive for the detection of neuroblastoma. Ongoing research will be needed to analyze the relationship between radioactivity and histol-

ogy. It still has to be demonstrated that this technique has a beneficial effect on outcome.

REFERENCES

1. Nieroda CA, Mojzsisik C, Sardi A, et al.: Staging of carcinoma of the breast using a handheld gamma detecting probe and monoclonal antibody B72.3 *Surg Gynecol Obstet* 169:35–40, 1989.
2. Arnold MW, Schneebaum S, Berens A, Mojzsisik C, Hinkle G, Martin EW: Radioimmunoguided surgery challenges traditional decision making in patients with primary colorectal cancer. *Surgery* 112:624–630, 1992.
3. Arnold MW, Schneebaum S, Berens A, Petty L, Mojzsisik C, Hinkle G, Martin EW: Intraoperative detection of colorectal cancer with radioimmunoguided surgery and CC49, a second-generation monoclonal antibody. *Ann Surg* 216:627–632, 1992.
4. Hoefnagel CA, Vo'te PA, de Kraker J, Marcuse HR: Radionuclide diagnosis and therapy of neural crest tumors using iodine-131 metaiodobenzylguanidine. *J Nucl Med* 28:308–314, 1987.
5. Vo'te PA, Hoefnagel CA, de Kraker J, Valdes Olmos R, Bakker DJ, van de Kleij AJ: Results of treatment with 131 I-metaiodobenzylguanidine (131 I-MIBG) in patients with neuroblastoma. In Evans AE, D'Angio GJ, Knudson AG, Seeger RC (eds): "Advances in Neuroblastoma Research." *Progress in Clinical and Biological Research*. vol. 366. New York: Wiley-Liss, 1991, pp. 439–445.
6. Mojzsisik CM, Cook CH, Schneebaum S: Safety and performance factors in the development and clinical use of the RIGS system. In Martin EW Jr. (ed): "Radioimmunoguided Surgery (RIGS) in the Detection and Treatment of Colorectal Cancer." Austin: R.G. Landes Co., 1994, pp. 81–123.