

University of Dundee

MASTER OF SCIENCE

The quantification of dorsal hand features of interest to assist forensic human identification

Macdonald-McMillan, Briony

Award date:
2011

Awarding institution:
University of Dundee

[Link to publication](#)

General rights

Copyright and moral rights for the publications made accessible in the public portal are retained by the authors and/or other copyright owners and it is a condition of accessing publications that users recognise and abide by the legal requirements associated with these rights.

- Users may download and print one copy of any publication from the public portal for the purpose of private study or research.
- You may not further distribute the material or use it for any profit-making activity or commercial gain
- You may freely distribute the URL identifying the publication in the public portal

Take down policy

If you believe that this document breaches copyright please contact us providing details, and we will remove access to the work immediately and investigate your claim.

Download date: 17. Feb. 2017

The quantification of dorsal hand features of interest to assist forensic human identification

Briony Macdonald-McMillan

2011

University of Dundee

Conditions for Use and Duplication

Copyright of this work belongs to the author unless otherwise identified in the body of the thesis. It is permitted to use and duplicate this work only for personal and non-commercial research, study or criticism/review. You must obtain prior written consent from the author for any other use. Any quotation from this thesis must be acknowledged using the normal academic conventions. It is not permitted to supply the whole or part of this thesis to any other person or to post the same on any website or other online location without the prior written consent of the author. Contact the Discovery team (discovery@dundee.ac.uk) with any queries about the use or acknowledgement of this work.

**The Quantification of Dorsal Hand Features of Interest
to Assist Forensic Human Identification**



Briony Macdonald-McMillan

050005729

Centre for Anatomy and Human Identification

Submitted for the degree of MSc by Research

April 2011

Supervisors: Professor Sue Black and Dr Xanthé Mallet

Abstract

Traditionally, the identification of offenders from photographic or video evidence through physical features has been via facial characteristics. However, criminals are increasingly ensuring that their face does not appear in physical evidence. This has become particularly problematic within investigations related to paedophilic images transmitted via the Internet, where eye-witness and trace evidence are of limited value, and suspects must be identified via offender/suspect comparison. This has led to a requirement to investigate methods by which an individual may be compared via physical features found in areas of the body other than the face. As seen in recent Court cases, the ability to exclude or include an individual based on the comparison of a small anatomical area such as the thumb or fingers can be vital.

Currently, however, there is no empirical data supporting the individuating power of these features, which limits their admissibility as evidence in legal proceedings. The aim of this project is to determine the occurrence rate of the anatomical features seen on the dorsal surface of the hand, in an effort to assist future forensic investigations that require comparison of images between the suspect and the offender in order to exclude or include them for further investigation. These features were quantified within divisions of the dorsal surface of the hand in 260 participants (520 hands), allowing statistical testing of relationships between hand features and their occurrence in these different regions. Biographic information gathered from participants allowed factors including sex, handedness and age to be included in statistical testing. Further to this, intra and inter-observer error were assessed. Subsequent statistical analysis showed that certain features of the hand show significant variation between males and females, and

between age groups. These findings are of importance to the forensic profession, as this variation may be of use in forensic image comparison cases related to disputed identity.

Table of Contents

Abstract.....	2
List of Figures.....	7
List of Tables.....	9
Acknowledgements.....	11
Signed Declaration.....	12
Chapter 1 : Introduction.....	13
Chapter 2 : Review of the Literature.....	17
2.1 The Individuality of the Human Hand.....	17
2.2 Dermatological Conditions.....	22
2.3 Pigmentation Conditions.....	29
2.3.1 Solar Lentigines and Ephelides.....	30
2.3.2 Lentigines (Liver Spots).....	31
2.3.3 Ephelides (Freckles).....	34
2.3.4 Melanocytic Nevi (Moles).....	36
2.3.5 Depigmentation and Hypopigmentation.....	41
2.4 Skin Damage to the Hand.....	43
2.4.1 Incidence of Hand injuries.....	43
2.4.2 Burns.....	47
2.4.3 Surgical Incisions.....	49
2.5 Scars.....	57
2.5.1 Scar Formation.....	58
2.5.2 Scar Characteristics.....	59
2.5.3 Permanence of Scars.....	66
2.6 Body Modifications.....	68
2.7 Hand Image Evidence in the British Court System.....	70
2.7.1 Forensic Image Comparison.....	70
2.7.2 Admissibility of Image Comparison Evidence.....	75
Chapter 3 : Materials and Methods.....	80
3.1 Sample.....	80
3.2 Landmarking.....	81
3.3 Image Enhancement.....	85
3.4 Image Analysis.....	87
3.5 Data Recording.....	90
3.6 Statistical Analysis.....	91
3.7 Analysis of Intra- and Inter-Observer Error.....	93
Chapter 4 : Results and Discussion.....	94
Results.....	94
4.1 Sex Differences.....	94
4.1.1 Female Left Hands (n=61) – Multiple Comparison of Grid-cells.....	94

4.1.2 Female Right Hands ($n=61$): Multiple Comparison of Grid-cells	96
4.1.3 Female Left Hands ($n=61$) vs Female Right Hands ($n=61$).....	97
4.1.4 Male Left Hands ($n=177$): Multiple Comparison of Grid-cells.....	101
4.1.5 Male Right Hands ($n=177$): Multiple Comparison of Grid-cells.....	102
4.1.6 Male Left Hands ($n=177$) vs Male Right Hands ($n=177$).....	103
4.1.7 Female Left Hands ($n=61$) vs Male Left Hands ($n=177$).....	107
4.1.8 Female Right Hands ($n=61$) vs Male Right Hands ($n=177$).....	111
4.2 Hand Dominance Differences.....	114
4.2.1 Dominant Left Hands ($n=26$) Grid-cell Comparison.....	114
4.2.2 Dominant Right Hands ($n=212$) Grid-cell Comparison.....	115
4.2.3 Non-dominant Left Hands ($n=26$) Grid-cell Comparison.....	116
4.2.4 Non-dominant Right Hands ($n=212$) Grid-cell Comparison	117
4.2.5 Left-handed – Dominant Left Hands vs Non-dominant Right Hands	118
4.2.6 Right-handed – Non-dominant Left Hands vs Dominant Right Hands	120
4.2.7 Dominant Left Hands vs Non-dominant Left Hands	124
4.2.8 Dominant Right Hands vs Non-dominant Right Hands.....	128
4.3 Age Differences	130
4.3.1 Multiple Comparison of Grid-cells by Age Groups: Left Hands.....	130
4.3.2 Multiple Comparison of Grid-cells by Age Groups: Right Hands.....	135
4.4 Additional Features.....	141
4.5 Intra- and Inter-observer Error.....	142
4.6 Analysis of Normalised Data	145
Interpretation of Results and Discussion	146
4.7 Sex Differences.....	146
4.7.1 Female Left Hands ($n=61$) – Grid-cell Comparison	146
4.7.2 Female Right Hands ($n=61$) – Grid-cell Comparison.....	148
4.7.3 Summary.....	149
4.7.4 Female Left Hands ($n=61$) vs Female Right Hands ($n=61$).....	151
4.7.5 Male Left Hands ($n=177$) – Grid-cell Comparison.....	153
4.7.6 Male Right Hands ($n=177$) – Grid-cell Comparison	154
4.7.7 Summary	155
4.7.8 Male Left Hands ($n=177$) vs Male Right Hands ($n=177$).....	156
4.7.9 Summary	158
4.7.10 Female left hands ($n=61$) vs Male left hands ($n=177$).....	159
4.7.11 Female right hands ($n=61$) vs Male right hands ($n=177$).....	161
4.7.12 Summary	162
4.8 Hand Dominance Differences.....	163
4.8.1 Dominant Left Hand Grid-cell Comparison ($n=26$).....	163
4.8.2 Non-dominant Left Hand Grid-cell Comparison ($n=212$).....	163
4.8.3 Summary	164
4.8.4 Dominant Right Hand Grid-cell Comparison ($n=212$).....	166

4.8.5 Non-dominant Right Hand grid-cell Comparison (n=26).....	166
4.8.6 Summary	167
4.8.7 Left-handed – Dominant Left Hands vs Non-dominant Right Hands	168
4.8.8 Right-handed – Non-dominant Left Hands vs Dominant Right Hands	169
4.8.9 Summary	170
4.8.10 Dominant Left Hands vs Non-dominant Left Hands	170
4.8.11 Dominant Right Hands vs Non-dominant Right Hands.....	171
4.8.12 Summary	171
4.9 Age Differences	173
4.9.1 Multiple Comparison of Grid-cells by Age Groups: Left Hands.....	173
4.9.2 Multiple Comparison of Grid-cells by Age Groups: Right Hands.....	174
4.9.3 Summary	175
4.9.4 Analysis of Normalised Data	176
4.10 Conclusion	177
Chapter 5 : References	185

List of Figures

Figure 2.1 Atopic Eczema.....	24
Figure 2.2 Psoriasis I.....	25
Figure 2.3 Psoriasis II.....	25
Figure 2.4 Herpes Simplex in a Digit.....	25
Figure 2.5 Actinic Keratinosis.....	26
Figure 2.6 Knuckle Pad I.....	27
Figure 2.7 Knuckle Pad II.....	27
Figure 2.8 Knuckle Pad III.....	27
Figure 2.9 Solar Lentigines I.....	32
Figure 2.10 Solar Lentigines II.....	32
Figure 2.11 Extensive Ephelides.....	36
Figure 2.12 Mild Ephelides.....	36
Figure 2.13 Nevus.....	37
Figure 2.14 Atypical Nevus.....	37
Figure 2.15 Vitiligo I.....	42
Figure 2.16 Vitiligo II.....	42
Figure 2.17 H-shaped, Y-shaped, and Curvilinear Incisions.....	50
Figure 2.18 T-shaped Incision.....	50
Figure 2.19 Dorsal Approach to MCP Joint.....	52
Figure 2.20 Dorsal Approach to Basal Joint of the Thumb.....	52
Figure 2.21 Gamekeeper’s Thumb.....	52
Figure 2.22 Dorsal Approach to Fingers.....	52
Figure 2.23 Paronychium Approach.....	52
Figure 2.24 Dorsal Interosseous Compartment Incisions.....	53
Figure 2.25 T-shaped Incision Scar (Left) and Linear Incision Scar (Right).....	54
Figure 2.26 Burn, Two Years Post-injury.....	64
Figure 2.27 Hypertrophic Scar I.....	65
Figure 2.28 Hypertrophic Scar II.....	65
Figure 2.29 Keloid Scar I.....	66
Figure 2.30 Keloid Scar II.....	66
Figure 2.31 Tattoo on Dorsum of Hand.....	68
Figure 2.32 Hand Piercing.....	69
Figure 2.33 Deep Hand Piercing.....	69
Figure 3.1. Right and Left Hand Grids, Showing the 24 Grid-cells.....	84
Figure 3.2 Features Pre-resolution Change.....	86
Figure 3.3 Features Post-resolution Change.....	86

Figure 3.4. Hand Image Prior to Isolation of Yellow Channel	87
Figure 3.5. Hand Image After Isolation of Yellow Channel.....	87
Figure 3.6. Scar Orientation.....	89
Figure 4.1. Female Left Hands: Grid-cell 1 Multiple Comparisons	95

List of Tables

Table 2.1. Fitzpatrick Skin Phototypes	33
Table 2.2. Mean Full Body Nevus Counts in 12-13 year olds	39
Table 2.3. Mean Face and Neck Counts in 12-13 year olds	39
Table 2.4. Mean Shoulder and Back Nevus Counts in 12-13 year olds.....	39
Table 2.5. Hand Injuries by Anatomical Region.....	46
Table 2.6. Examples of Surgical Procedures of the Hand.....	51
Table 2.7. Manchester Scar Proforma.....	61
Table 2.8. Vancouver Scar Scale	61
Table 2.9. Oliver Image Description Scale	73
Table 3.1. Participant Breakdown by Handedness and Sex.....	81
Table 3.2. Participant Breakdown by Age and Sex	81
Table 3.3. Landmarks for Grid Placement	82
Table 3.4. Hand Cell Descriptors	83
Table 3.5. Information Gathered According to Feature.....	88
Table 3.6. Feature Recording Form	91
Table 3.7. Scar Recording Form	91
Table 4.1. Female Left Hands Correlation Matrix	95
Table 4.2. Female Right Hands Correlation Matrix.....	96
Tables 4.3 – 4.10. Female Left Hands vs Female Right Hands Results	97-100
Table 4.11. Male Left Hands Correlation Matrix	101
Table 4.12. Male Right Hands Correlation Matrix	102
Tables 4.13 – 4.23. Male Left Hands vs Male Right Hands Results	103-106
Tables 4.24 – 4.32. Female Left Hands vs Male Left Hands Results	107-109
Tables 4.33 – 4.39. Female Right Hands vs Male Right Hands Results.....	111-113
Table 4.40. Dominant Left Hands Correlation Matrix.....	114
Table 4.41. Dominant Right Hands Correlation Matrix	115
Table 4.42. Non-dominant Left Hands Correlation Matrix	116
Table 4.43. Non-dominant Right Hands Correlation Matrix	117
Tables 4.44 – 4.46. Dominant Left hands vs Non-dominant Right Hands Results	118-119
Tables 4.47 – 4.56. Non-dominant Left Hands vs Dominant Right Hands Results	120-123
Tables 4.57 – 4.65. Dominant Left Hands vs Non-dominant Left Hands Results.....	124-127
Tables 4.66 – 4.70. Dominant Right Hands vs Non-dominant Right Hands	128-129
Tables 4.71 – 4.96. Multiple Comparison of Grid-cells by Age Groups: Left Hands Results	130-134

Tables 4.97 – 4.126. Multiple Comparison of Grid-cells by Age Groups: Right Hands Results	135-140
Table 4.127. Incidence of Additional Features	141
Table 4.128 – 4.140. Inter-observer Error Results	143-145
Table 4.141. – Analysis of Normalised and Non-normalised Data	145
Table 4.142. – Incidence of Zero Features.....	181

Acknowledgements

I would like to thank my supervisor **Professor Sue Black** for her input and assistance throughout this project. Additional thanks are extended to **Dr. Jan Bikker** for taking the time to assist me with the finer aspects of data organisation. Thanks also to Martin, friends and family for the personal guidance necessary to complete this project.

Signed Declaration

I declare that I am the author of this thesis and that unless otherwise stated; all references have been consulted by me. This thesis details the project carried out by me, and has not been previously accepted for a higher degree.

Signed:

Date:

Chapter 1 : Introduction

Within the last few years, the ease with which people can access the Internet has increased substantially (Hoffman *et al.*, 2004). Stanley (2001) and Jenkins (2001) highlight the increasing recognition that with the Internet revolution has come new opportunities to access and subsequently coerce, harm and abuse young Internet users, due to novel forms of technology becoming available, such as webcams. The Internet provides a means by which digital images and video can be transmitted and viewed easily, resulting in it being used as a conduit for a multitude of nefarious activities, including the dissemination of paedophilic material. With this has come an increasing prevalence of child pornography-related police investigations (Carr, 2003).

There are important differences with regards to the law and the punishments associated with obtaining or possessing child pornography and actively participating in the abuse. The resultant charges carry differing sentences. The maximum prison term for possession of child pornography under UK law is 10 years imprisonment (Akdeniz, 2008), whereas the maximum prison term for sexual assault of a child or a child less than 13-years-old ranges from several years to life imprisonment (Sexual Offences Act, 2003). The age of the victim is an important distinction to make, due to the fact that a child under 13 years cannot legally give their consent to any form of sexual activity. However, in cases involving a victim between 13 and 16 years old, it is possible for the Defence to argue that the suspect genuinely believed the child to be over the age of 16. Therefore, if an individual has participated in child sexual abuse as well as possessing an image of the abuse, it is vital that they can be identified so that they can be charged for the full extent of their crimes.

Two of the most important types of forensic evidence are eye-witness and trace evidence. Neither of these can be relied upon when investigating digital images and video. Therefore, other means by which an individual can be identified beyond reasonable doubt are required. The hands often feature regularly in criminal images, particularly child pornography, as well as ‘trophy shots’ from homicides, and kidnappings (Spaun, 2007). This makes them an ideal anatomical region upon which to base the identification of offenders.

The evidential assessment in these cases often relies on the comparison of two images, those of the offender and suspect, in order to determine if they could be the same individual. The original concept for this project arose as a result of a forensic comparison case that the Centre for Anatomy and Human Identification at the University of Dundee was asked to undertake on behalf of a UK police force. Forensic anthropologists specialising in human identification were asked to compare images of an offender and suspect in an alleged paedophile case. The conclusions reached were limited to exclusionary evidence.

Although a report for this case was produced, it was recognised at the time that no empirical data was available with which to propose a likelihood ratio of a match between offender and suspect, based on physical features of the dorsal surface of the hand. This issue resulted in the investigation being limited to a qualitative visual assessment of the morphological points in both images. In order to provide a quantitative assessment in future cases, it was recognised that a database of images would be required, upon which statistical analyses could be performed to improve the reliability and robusticity of this method of identification, as well as provide empirical evidence on which future decisions could be based.

Further to these issues, the evaluation of likelihood ratios in forensic evidence is another important aspect of evidential assessment. A recent High Court of Appeal case (*Regina v T*, 2010) highlighted this issue, where there was disagreement over likelihood ratios produced by an expert witness brought by the Crown. The issue in question was the use of a likelihood ratio with regards to the most likely source of a footwear mark found at the scene of a murder. However, it was found that the likelihood ratio was not based on a database of information, and was instead, largely based on the expert witnesses' evaluative opinion. This case highlighted the importance of the development of databases of information upon which likelihood ratios and statistical inferences can be made for the purposes of the Courts.

The aim of this research was to evaluate and quantify the physical features seen on the dorsum of the hands of a sample of living individuals. This was achieved through the quantification of physical features observed on the dorsum of the left and right hands of 260 adults aged 23 to 64 years. Further to this, statistical analysis was performed in order to identify those features that showed the greatest variability according to age, sex and handedness.

Firstly, the literature relevant to the aetiology and physical appearance of features commonly seen on the dorsal surface of the hand will be discussed. The review of the literature is divided into seven sections. The first section discusses the variety of ways in which the hand can be used for verification and identification purposes. The next section explores the dermatological conditions that can affect the hands. Subsequently, the pigmentation conditions that are seen in the hands, including ephelides, lentigines, nevi and pigmentation-loss are discussed. The literature pertaining to soft tissue injuries of the hand will then be reviewed. Within this chapter, the incidence of accidental hand

injuries and surgical procedures to the hand will be discussed. The next section discusses the process of scar formation and the physical characteristics of different types of scar tissue. The section following this will contain a brief discussion of body modifications that may be seen in the hand. Finally, the legal aspects of forensic image comparison will be discussed, including the legal admissibility of this type of evidence, and examples of recent cases involving forensic image comparison. In Chapter 3, the data acquisition and quantification methods will be discussed in detail, as well as the source of the data being analysed. The results of the analyses will be detailed in Chapter 4, along with details of all statistical testing carried out on the data and the results of intra- and inter-observer error testing. Finally in Chapter 5, the results and their importance to this field of research will be discussed, as well as a final conclusion as to the ramifications of this project and potential future developments within the field.

Chapter 2 : Review of the Literature

2.1 The Individuality of the Human Hand

Humans use their hands to perform a significant range of tasks. This exposes the hands to a variety of environments, which affect their physical appearance in a number of ways (Lloyd, 1985). Furthermore, our own unique genetic makeup can affect the appearance of our hands as well as other biometric features, whether through congenital defects, moles, or factors such as a predisposition to freckling or solar lentigines (Buettner, 2009). These factors could result in every individual potentially possessing an individual combination of features in their hands.

Although there has been detailed data collection on facial features, far less is known about individual features of the hand relevant to identification. Currently the hand is viewed as sufficiently individuating for *verification* purposes, for example as a controlled access mechanism for secure buildings (a 1:1 match). However, it is thought not to be sufficiently individuating for *identification* purposes (a 1:n match) as similarities between hands are common and their individual features are considered to be insufficiently descriptive (Kizza, 2010; Rosistem, n.d.). Despite this, it has been acknowledged that hands would be an ideal biological characteristic to use for identification as they are often on display and often exhibit potentially unique characteristics including freckles, scars, and tattoos (Spaun, 2007).

Verification involves comparing one individual's identification parameters to a known individual's identification parameters in order to compare specific features of both to confirm or refute that they match and are one and the same. Thus, verification, also known as authentication (Mollin, 2001), requires a 1:1 match. Identification is a more

complex process as it requires a 1: n match. Rather than accepting an assumed identity and investigating whether two individuals match each other, identification requires the comparison of one individual against multiple identities, requiring comparisons to be made between a large number of individuals until a confirmed match, if available, can be found. Additionally, an important aspect of image comparison is the production of a likelihood ratio. This value informs the judiciary on the likelihood of the two images being from the same person or from two different individuals (Lucy, 2010; Steadman *et al.*, 2006).

There are currently a wide variety of ways in which the hand is used to confirm identity. Biometric verification systems frequently use features of the hand due to the ease of access to this anatomical region, their possession of distinctive geometry and features, and the fact that people are more comfortable with having their hands examined than other areas such as the eyes or face (Gregory and Simon, 2008). Bolle *et al.* (2004) state that existing commercial biometric systems do not take advantage of non-geometric features present in the hand, the example given being skin colour. Some examples of areas of the hand currently used for identification purposes include fingerprint ridge patterns, vein patterns and knuckle creases. Other examples include the lines, ridges, wrinkles of the hand, as well as texture patterns (Badrinath and Gupta, 2009). Images being compared may have been taken days, months, or years apart. Thus, the features being used for the purpose of comparison must be stable, as features that can change markedly in appearance over time cannot be relied upon to be directly comparable. Such features would include acute non-recurring skin conditions or minor injuries.

Epidermal Ridges

One of the oldest forms of identification used by UK police forces is fingerprinting. It was recognised in 1893 by the UK Home Ministry Office (Maltoni *et al.*, 2009) that no two individuals have the same fingerprints, though this has not and cannot realistically be proven. Sir Francis Galton calculated that the odds of two individual fingerprints being the same were one in 64 billion (Cole, 2002). The fact that no two fingerprints from two individuals have been found to match is strong evidence of their uniqueness. However, the absence of disproof cannot be taken as proof. Considered to be one of the most reliable methods of identification (Jain *et al.*, 1997; Kondekar *et al.*, 2010), fingerprints are unique to every individual as they are not genetically determined, and so they are also unique between identical twins (Srihari *et al.*, 2008).

The individuating power of fingerprints relies on the pattern of ridges and furrows found on the volar pads of the fingers. Friction ridges serve to provide the hand with greater surface grip under pressure and minimum skin contact under light grip (Salter, 2000). The features observed in a fingerprint are classed into three levels. The first level is comprised of the shape produced by the friction ridges, and can be classed as an arch, loop, whorl, or a composite of two or more of these patterns. The second level of characteristics are those of the individual friction ridges, for example ridge ending and bifurcations, lakes, short independent ridges, spurs, and ridge crossovers. The third and final level involves comparing the edges of ridges and the position and shapes of pores (Maltoni *et al.*, 2009). This method of verification and identification has become widely used by police and the security industry, and is not restricted to the finger pads as ridges in the fingers, palms and soles of the feet can also be examined. Epidermal ridge patterns are formed *in utero* and are influenced by the underlying dermis during development (Galloway and Charlton, 2007). This makes them very resilient to damage as the ridge patterns will 'grow back' even if the epidermis is damaged, as long as the

dermis remains intact. This potentially makes fingerprints even more individuating than DNA, when combined with their variability between identical twins (Galloway and Charlton, 2007).

Palmprint biometric systems utilise the principle lines, wrinkles and minutiae of the hand. The three principle lines are found in the palm of the hand, and are created by flexion of the hand and wrist (Prasad *et al.*, 2009; Zhang, 2000). The endpoints of these lines can also be used for geometric measurements (Kumar *et al.*, 2003). Wrinkle features can be used as well as the points where principle lines intersect with the edge of the palm. Points of bisection on these lines can also be used to determine measurements (Zhang, 2000). Similar to fingerprints, the characteristics of the epidermal ridges and their minutiae can also be used to individuate palmprints.

Vein Patterning

Vascular mapping technology uses near infra-red light to capture the intricate pattern of the venous drainage, usually of the hand and forearm. Its usefulness lies in the fact that the superficial pattern of veins in the limb extremities is believed to be unique to all individuals, including identical twins (Bhattacharyya *et al.*, 2010; Kumar *et al.*, 2009). It is also extremely stable, i.e. it does not change significantly over time, as well as being difficult to spoof due to the features being analysed lying underneath the skin and requiring the flow of deoxygenated blood (Nadort, 2007; Wang *et al.*, 2008).

Hand Geometry

The geometry of the hand is widely used in identity verification systems (Zunkel, 2002) but is currently considered unsuitable for personal identification in a large scale population, as the features of the hand are considered distinctive, but not sufficiently

unique for identification (Kumar *et al.*, 2009; The U.K. Biometric Working Group, 2010). The features assessed in this biometric include area or size of the palm, thickness of the palm, length and width of fingers and aspect ratios of the palm or fingers (Bolle *et al.*, 2004; Kumar *et al.*, 2003). Although hand geometry biometrics tend to have high false acceptance and false rejection rates, this biometric has widespread use. This may be due to the fact that it is widely applicable, as most of the working population has hands, as well as the biometric information required being easy to collect. Hand geometry is also a less intrusive biometric compared to others, for example iris or retina scanning.

Knuckle creases

A more recent development, knuckle crease biometric systems are proposed to be more user-friendly as people associate knuckle creases less with criminality than fingerprints (Kumar and Zhou (2009)). This technique uses the dorsal surface of the digits in order to map the surface of the knuckles, relying on the creases found in the skin over the knuckles. These creases form in the embryo, and allow the skin to fold upon extension of the digits, as well as giving freedom of movement during flexion of the digits. Studies carried out into this method of biometric identification by Choraś and Kozik (2010) and Kumar and Zhou (2009) have suggested that these extension creases show potential to be useful biometric identifiers.

2.2 Dermatological Conditions

Dermatology is an important discipline to consider in terms of distinctive features of the hands. An understanding of the common conditions within a population will give an indication as to which conditions are more likely to be seen and which are rarer. Many of the most common conditions seen within the population are of a chronic nature, such as atopic dermatitis and psoriasis (Naldi and Chalmers, 2008; Sterry *et al.*, 2006). However, acute conditions such as bacterial skin infections are not stable, with most infections quickly treated with antibiotics (Foy and Foreman, 2006). Conditions that are of a chronic nature are likely to be seen in the hands over a long period of time, potentially making them a more distinctive and comparable feature, due to their temporal stability. An important aspect of this however is the fact that dermatological conditions, being pathological, will often be treated in an attempt to improve their symptoms. This may affect the physical manifestations of these conditions to a point where they may not be comparable between different temporal points. Conditions that can disappear with treatment include bacterial and viral infections of the skin, as well as warts. However, in some cases these conditions can recur (Usatine, 2008). This unstable state of existence makes these dermatological conditions less useful when considering features relevant to human identification. For this reason, conditions that are of an acute, non-recurring nature will not be discussed in this section.

The most common skin disorders in the UK population are skin cancer, acne, atopic eczema, psoriasis and viral warts. These are followed by other infective skin disorders, benign tumours and vascular lesions, leg ulcers, and contact dermatitis and other forms of eczema (Weller *et al.*, 2008). Studies from the U.S.A. suggest similar conditions to be the most common. Feldman *et al.* (1998) conducted a study of the most common

dermatological conditions seen by dermatologists and internists. Dermatitis was the most common diagnosis for internists (15.8%), followed by bacterial skin infections (14%), fungal skin infections (4.7%), acne vulgaris (4.7%), and herpes zoster (4.7%). Acne vulgaris was the most common diagnosis for dermatologists (18%), followed by dermatitis (13%), actinic keratinosis (11.5%), skin cancer (7.6%), viral warts (6.7%), and benign tumours (5.8%). Awadalla *et al.* (2008) investigated the most common dermatologic diagnoses made by American family physicians from 2002-2005. Dermatitis was the most common, accounting for 13.58% of diagnoses, followed by pyoderma (pus-forming skin conditions), which accounted for 10.38%, with bacterial skin infections (7.41%), benign neoplasms (4.39%), and fungal skin infections (3.73%).

Atopic Dermatitis (Atopic Eczema)

Atopic dermatitis (atopic eczema) is a chronically relapsing skin disease with a prevalence in adults of approximately 1-3% (Leung *et al.*, 2008). It is the result of genetic susceptibility genes causing a defective skin barrier, defects in the immune system, and increased immunologic responses to allergens and microbial antigens (Leung *et al.*, 2004). Intense pruritus (itching sensation) and cutaneous reactivity are key features of atopic dermatitis. This results in prurigo papules, lichenification, and eczematous skin lesions. In cases of chronic atopic dermatitis, thickened plaques of skin are present, as well as the symptoms mentioned previously. Chronic hand eczema may be the primary manifestation of atopic dermatitis in many adults (Leung *et al.*, 2008). An example of atopic eczema is shown in Figure 2.1.

Atopic hand eczema tends to be more common in young people, with periods of remission appearing more frequently with age. One third of cases of hand eczema occur before 20-years-of-age. The one-year prevalence in 12-16 year-olds is 7.3% (Mortz *et*

al., 2001) and in 16-19 year-olds was reported as 10% by Yngveson *et al.* (1998). Meding and Järholm (2004) found in a Swedish study that 5.5/1000 of the population suffered from atopic hand eczema. More than half of adolescents treated for mild dermatitis may experience a relapse as adults (Leung *et al.*, 2008).

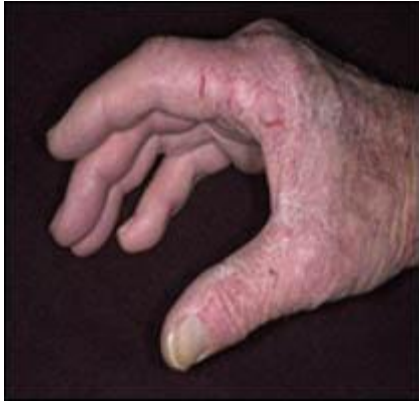

Figure 2.1 Atopic Eczema
(NHS, 2010b)

Psoriasis

Psoriasis is a chronic inflammatory skin disease that affects 2-3% of the UK population and affects males and females equally (Mitchell and Penzer, 2004). It is most likely to appear between the ages of 15 and 30 years and can affect any area of the body, although the hands are one of the most commonly affected regions (Gudjonsson and Elder, 2008). It has a strong genetic basis (Sagoo *et al.*, 2004), although twin studies have suggested that environmental factors also play a role in its development (Krueger and Ellis, 2005). Psoriasis presents with raised, round, well-circumscribed, pink papules and plaques with an overlying silvery scale. Due to the itching and irritation associated with these, the sores can also be cracked and bleeding (Nambudripad, 2008). In cases of involvement of the hands, the nails can also be affected. Nail pitting may occur, as well as splinter haemorrhages, subungual hyperkeratosis, and leukonychia (Craft *et al.*, 2010). The physical appearance of psoriasis is demonstrated in Figures 2.2 and 2.3.

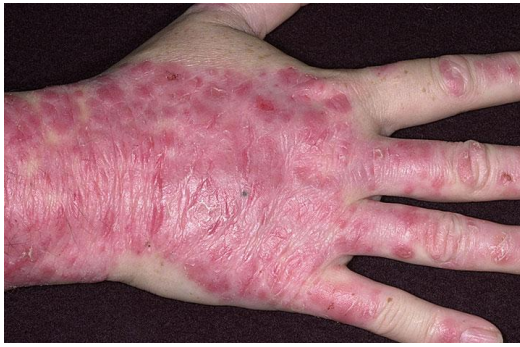

Figure 2.2 Psoriasis I
(DermNet.com, 2010)

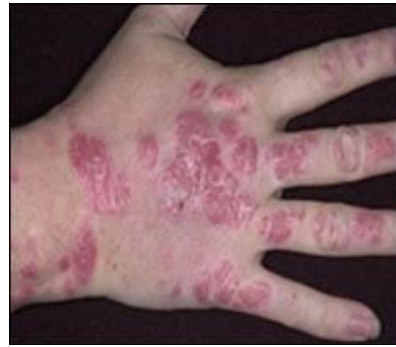

Figure 2.3 Psoriasis II
(NHS, 2010a)

Viral skin infections

Infection by the herpes simplex virus can occur through a break in the skin barrier, which allows infection through contact with people who have shedding herpetic lesions. The lesions caused by herpes simplex are seen in Figure 2.4. Clusters of fluid-filled vesicles, swelling, inflammation and pruritus are seen after infection with Herpes simplex. These lesions usually dry and crust, with the primary episode of Herpes simplex tending to heal within 2-4 weeks. However, the virus tends to remain in the body latently, resulting in frequent secondary recurrence of the lesions, often in the same place (Birnbaumer, 2010; Skinsight, 2008).

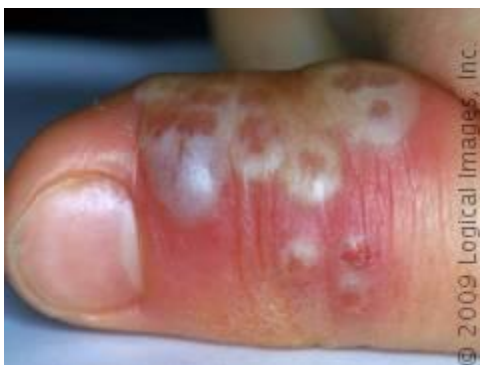

Figure 2.4 Herpes Simplex in a Digit
(Logical Images Inc., 2009a)

Actinic Keratinosis

Actinic keratinosis, shown in Figure 2.5, is a skin condition where precancerous epithelial lesions form on sun-exposed regions of the body such as the face, neck, upper chest, forearms and dorsum of the hands. This condition tends to be seen in elderly individuals and presents as flat, scaly, thickened papules that vary in size and usually begin as rough localised lesions that can be felt but are difficult to see (Craft *et al.*, 2010).

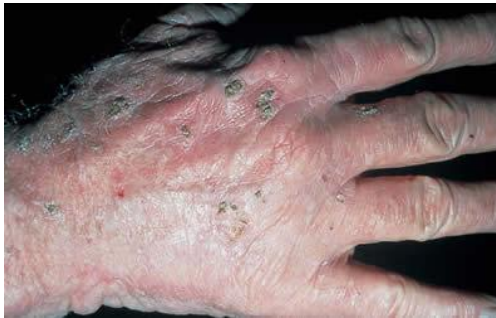

Figure 2.5 Actinic Keratinosis
(American Academy of Dermatology, 2010)

Corns and Calluses

Corns and calluses are localised areas of thickened skin. They form in response to friction and pressure. Repetitive damage results in the skin trying to protect itself. Keratinocytes in the skin increase in number, which results in a thicker outermost layer in the skin (stratum corneum) (Kim *et al.*, 2010). Corns are inflamed and painful and have a soft, damp, peeling surface, whereas calluses are areas of painless, hard skin. Knuckle pads are a particular type of callus found on the hand. The physical appearance of knuckle pads is shown in the circled areas of Figures 2.6, 2.7 and 2.8. They are circumscribed, hyperkeratotic (hypertrophy of the stratum corneum), or fibrous growths

over the dorsal aspect of the interphalangeal or metacarpophalangeal joints (Feasel, 2007).

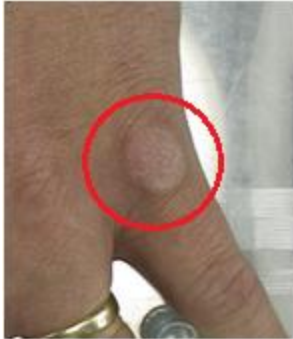

Figure 2.6 Knuckle Pad I
(University of Dundee)

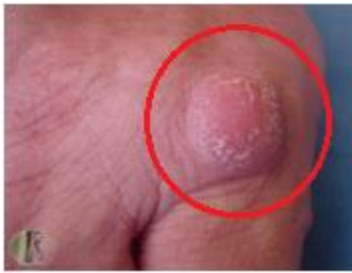

Figure 2.7 Knuckle Pad II
(DermNetNZ, 2010a)

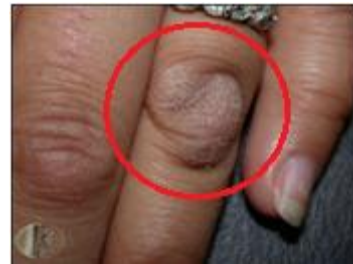

Figure 2.8 Knuckle Pad III
(DermNetNZ, 2010b)

Many dermatological conditions can be easily treated and disappear within a short space of time. Examples of short-term conditions include herpes zoster, carbuncles, furuncles and sweat gland abscesses. Chronic conditions such as psoriasis and atopic dermatitis are likely to be more useful for the purpose of forensic image comparison, due to the fact that they are more likely to be apparent in images taken over a long time period. Viral infections such as herpes simplex and warts heal quickly, but reoccurrence is common and often in the same place as the original infection occurred. On the other hand, acute conditions such as bacterial skin infections are not stable, with most infections quickly treated with antibiotics (Foy and Foreman, 2006). Rarer skin conditions include pyoderma, molluscum contagiosum, and necrotizing fasciitis. The nature of pyoderma

and necrotizing fasciitis are such that they are likely to leave permanent evidence after healing in the form of scar, and/or amputations.

2.3 Pigmentation Conditions

There are a variety of pigmentary features that can be found on the skin surface of the hand. Some are extremely common, as in the case of ephelides (freckles), and some are less common, for example lentigines (liver spots), which tend not to be seen until around 50 or 60 years-of-age.

Although they are useful individuating traits, solar lentigines tend not to be seen in individuals until later life. This may largely limit their use to a specific sub-group of society. However, they are permanent features and do not regress in the absence of solar exposure (Trozak *et al.*, 2006), though they can change shape and increase in size with time. This makes them extremely useful when attempting to identify features that support a match between two images.

By comparison, ephelides are a common feature of the dorsum of the hand from early life. Their frequent occurrence makes them useful as their location and spatial relationship can be used for comparison between images. However, the appearance of ephelides can change depending on what time of year it is, and may also disappear with age (Kane *et al.*, 2002), making lighter ephelides less useful due to their varying appearance.

Although nevi (moles) are a common pigmentary lesion of the skin, it has been suggested that their presence on the hands is less common than their presence in other frequently sun-exposed regions. Although this may result in them being an uncommon skin mark upon which to base a comparison, it may also result in nevi of the hand being a marker shared by a small portion of the population, resulting in their presence being of potentially significant use in image comparison.

It has been noted that red/blond hair and light eye colour appear to have a relationship with freckling, but not with melanocytic or atypical nevi (Pavlotsky *et al.*, 1997). However, there is a close association between the presence of ephelides and the presence of melanocytic and atypical nevi. Pavlotsky *et al.* (1997) found that 17.6% of freckles subjects had multiple melanocytic nevi and 8.5% had atypical nevi compared with 3.6% and 1.8% respectively among non-freckled subjects ($p < 0.01$).

2.3.1 Solar Lentigines and Ephelides

Solar lentigines (liver spots) and ephelides (freckles) are two of the most common pigmentation disorders (Zhou, 2006), and are both considered to be directly related to the photoaging and photo-damage process (Wulf *et al.*, 2004). A major factor in how photoaging proceeds is the pigmentary phenotype of an individual. Asian ethnicities are more prone to developing solar lentigines, whereas lighter skinned individuals tend to manifest solar ageing through wrinkles (Ichihashi *et al.*, 2009; Simandl, 2007). Bastiaens *et al.* (1999) observed a close association between ephelides, red/fair hair and fair skin, which was corroborated by Kawada *et al.* (2002).

Although lentigines and ephelides share some common morphologic features, they are in fact very different. Histologically, ephelides are the result of hyperpigmentation of the dermis by overactive melanocytes (Pray, 2006), whereas lentigines are caused by hyperpigmentation due to hyperplasia of melanocytes in the epidermis (Barnhill, 2004). Despite the histological differences, in terms of physical appearance they can be difficult to differentiate due to their similar pigmentary characteristics and size (Cullen *et al.*, 2006). The greatest distinction in appearance is the shape of their borders, with

ephelides having a more angular border and lentigines possessing a sharply-demarcated, scalloped border. The appearance of freckles tends to occur during childhood, whereas the appearance of lentigines is associated with later life (Monestier *et al.*, 2006). Another important difference between ephelides and lentigines is that lentigines do not darken with sun exposure (Turkington and Dover, 2007).

Cumulative exposure to UV light, as well as the use of certain medications, can be a factor in lentigine and ephelide development (Rendon, 2008). Psoralen photochemotherapy is used to treat skin disorders by a combination of the photosensitizing drug Psoralen and UVA radiation. Small hyperpigmented lesions, called PUVA freckles are seen in up to 70% of high-dose patients (Diffey, 2006). It has been suggested that melanocortin-1-receptor (MC1R) gene plays a part in freckle development as well as solar lentigine development (Bastiaens *et al.*, 2001).

2.3.2 Lentigines (Liver Spots)

Solar lentigines (also known as lentigos or liver spots) are macular hyperpigmented lesions that range in diameter from a few millimetres to over a centimetre, and tend to have an smooth, round border in comparison to ephelides (Figures 2.9 and 2.10). Solar lentigines can be oval, round, or irregular in shape and can vary from a few millimetres up to a few centimetres in diameter. The sharply-demarcated, irregular and/or scalloped border is a key characteristic of lentigines (Wang *et al.*, 2004).

Lentigines tend to occur in groups rather than individually and are more likely to be found on the more visible parts of the body, such as the face, neck, forearms, and hands. The face and the dorsum of the hands are the most common sites for solar lentigines (Trozak *et al.*, 2006), the incidence of which increases with age, with very few people

over 60-years-old having no solar lentigines (Monestier *et al.*, 2006). For this reason, solar lentigines are also known as senile lentigines. However, it is also possible to develop non-solar lentigines, known as lentigo simplex. These usually begin in the first decade of life and are not related to sun exposure or anatomical regions, but have been linked to systemic disorders such as; Peutz-Jeghers syndrome, multiple-lentigine syndrome, Laugier-Hunziker syndrome, Bannayan-Riley-Ruvalcaba syndrome, Addison's disease, Carney complex, familial generalized lentiginosis, and centrofacial lentiginosis (McKee and Calonje, 2009; Trozak *et al.*, 2006). They can be difficult to distinguish from ephelides, but are generally smaller than solar lentigines, and brown or dark brown in colour (Trozak *et al.*, 2006).

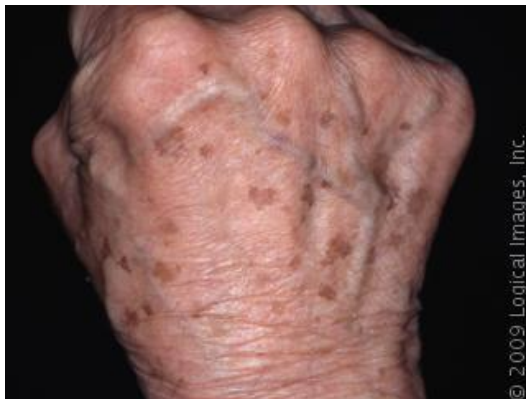

Figure 2.9 Solar Lentigines I
(Logical Images Inc., 2009b)

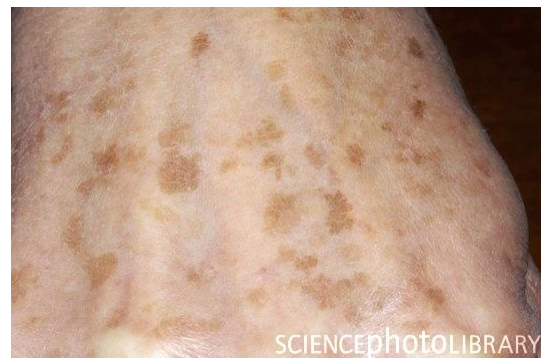

Figure 2.10 Solar Lentigines II
(Science Photo Library, 2010)

Monestier *et al.* (2006) conducted a study of senile lentigines in a French population of 60 to 80 year-olds. The occurrence of skin ageing patterns was analysed, characterised by a high density of senile lentigines on the face. Two populations were compared, one with very high facial lentigine counts ($n=118$) and one with no or very few facial lentigines ($n=118$). These samples were also analysed according to four age groups. It was found that the number of lentigines on the face increases with age, and that higher

lentigine counts are seen in individuals who have received frequent sunburns during the first 20 years of life. They are more common in individuals with higher Fitzpatrick skin types (types III and IV) (see Table 2.1). However, it has also been stated that lentigines are more common in light-skinned individuals, with up to 90% of Caucasians older than 90-years-old possessing them (Turkington and Dover, 2007).

The Fitzpatrick Skin Type (Young and Walker, 2008) classification system is used by medical professionals to classify individuals into groups based on skin colour and reaction to sun exposure, in terms of degree of burning and tanning. The system classifies an individual into one of six groups, ranging from group I (burns easily, never tans) to VI (never burns, tans profusely). Table 2.1 illustrates the diagnostic criteria.

Table 2.1 Fitzpatrick Skin Phototypes
(Keller and Lacombe, 2001; Young and Walker, 2008)

Skin Phototype	Skin colour	Sunburn susceptibility	Tanning ability	Skin cancer risk
I	White	High	None	High
II	White	High	Poor	High
III	White	Moderate	Good	Low
IV	Moderate brown	Low	Very good	Low
V	Dark brown	Very low	Excellent	Very low
VI	Black	Very low	Excellent	Very low

FGFR3 and PIK3CA mutations have been detected in the melanocytes of some solar lentigines, suggesting a possible genetic involvement in their development via mutations caused by UV exposure (Hafner *et al.*, 2009). The melanocortin-1-receptor (MC1R) gene may also play a part in solar lentigines development, through its regulation of relative proportions of pheomelanin and eumelanin (Bastiaens *et al.*, 2001; Valverde *et al.*, 1995). Pheomelanin is the yellow-red pigment found in the skin and hair, and is the pigment predominantly produced by individuals with fair skin and

blonde or red hair colour. Eumelanin is brown-black and is predominantly produced by individuals with darker hair and skin colour (Valverde *et al.*, 1995). Both forms of melanin are produced by melanocytes. Melanocytes are derived from melanoblasts, which develop from cells of neural crest origin (Steingrímsson *et al.*, 2005). They then migrate laterally in the embryonic ectoderm, eventually differentiating into melanocytes within the skin and hair follicles (Blasius *et al.*, 2009), and are located in the basal layer of the epidermis (van den Wijngaard *et al.*, 2000). When irradiated, pheomelanin produces free radicals in large quantities compared to eumelanin (Aravindakshan Menon *et al.*, 1983; Hennessy *et al.*, 2005; Ranadive *et al.*, 1986). It has been suggested that this is the reason people with ‘Celtic’ skin types i.e. fair skin and red hair, are more susceptible to photo-damage (Aravindakshan Menon *et al.*, 1983; Sarna and Plonka, 2005).

2.3.3 Ephelides (Freckles)

Like solar lentigines, ephelides are most commonly seen in body regions that are frequently exposed to the sun, such as the dorsum of the hands, the lateral sides of the forearms, and the face. Ephelides present as small regions of darkened pigmentation. They generally have a typical diameter of 1-3 mm, and an angular or stellate border (Zhou, 2006). Ephelides can become less visible over time, partly disappearing with age (Bastiaens *et al.*, 2004; Grossman and Guzzo, 2000), and tend to become more visible over the summer and fade in the winter (Trozak *et al.*, 2006). They also tend to be seen more commonly in fair-skinned individuals, particularly those with Fitzpatrick Type I skin. Ephelides can be associated with painful sunburns in the first 20 years of life. There is a strong negative association between the prevalence of ephelides and increasing age. However, there is a strong positive correlation between age and solar

lentiginos (Bastiaens *et al.*, 2004). Bastiaens *et al.* (2001) found that the degree of freckling seen in childhood is positively associated with the number of MC1R gene variants. MC1R is expressed on melanocytes, where it plays a role in pigmentation. Variants of MC1R result in fair skin and red hair, and through their transcription pathway, cause the synthesis of the brown/black pigment eumelanin (Healy, 2004).

In Asians, due to the darker skin tone, freckling is less common than in Caucasians (Chung, 2003). Interestingly, Bastiaens *et al.* (2004) found that Fitzpatrick Type II individuals possessed the highest proportion of ephelides, representing 52.9% of the sample possessing ephelides. Type III individuals accounted for 22.7%, Type I participants accounted for 19.3%, and Type IV accounted for 5.0%. Examples of extensive and mild freckling can be seen in Figures 4.3 and 4.4 respectively.

Pavlotsky *et al.* (1997) conducted a study on a random sample of 3040 17-year-old Israeli-born males. The participants were grouped according to their risk of developing a melanoma, based on geographic origin. The highest-risk group (North, West and Central Europe, Anglo-Saxon countries, Balkans, Bulgaria, Greece, USSR, Poland, and Romania) showed the highest prevalence of ephelides (24.8%). The prevalence of ephelides decreased gradually with the decreases in melanoma risk, with the lowest prevalence of ephelides seen in the lowest melanoma risk group (South East Asia and Africa).

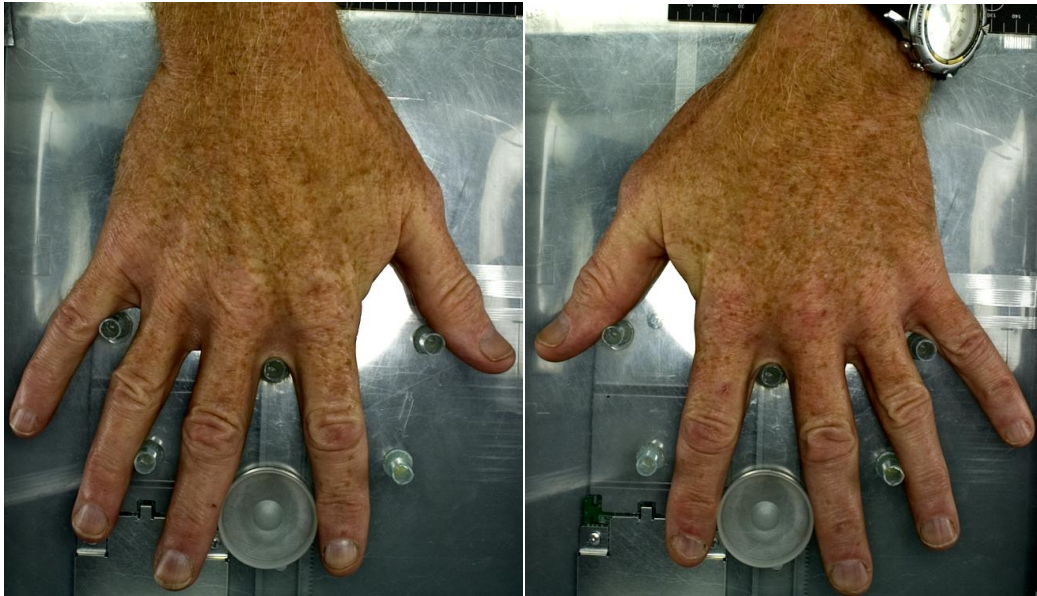


Figure 2.11 Extensive Ephelides
(University of Dundee)

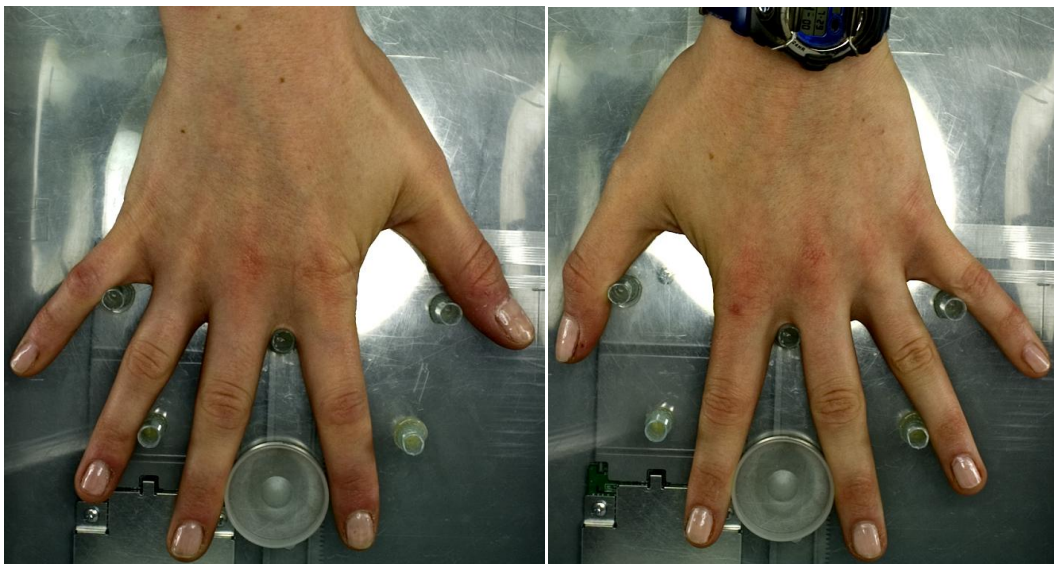


Figure 2.12 Mild Ephelides
(University of Dundee)

2.3.4 Melanocytic Nevi (Moles)

Melanocytic nevi, more commonly known as moles, are present in approximately 1-2% of newborns (Buxton and Morris-Jones, 2009; Krowchuk and Tunnessen Jr., 2006; Tannous *et al.*, 2005). Moles that have been present since birth are called congenital nevi (more commonly known as birth marks), though it is possible for nevi to develop

after birth, which are known as ‘tardive’ congenital nevi (Bauer *et al.*, 2007). It is also possible for nevi to develop later in life, which are known as common acquired melanocytic nevi.

Congenital melanocytic nevi and common acquired nevi can be clinically indistinguishable. Generally they possess a regular, smooth, and well-demarcated border, which tends to be round or oval (Rajendran, 2009) (Figure 2.13). Their colouration tends to be a uniform pale brown to dark brown or black (Buxton and Morris-Jones, 2009), with long, coarse and darkly-pigmented hairs sometimes present. They can also exhibit a papular, rugose, pebbly, verrucous, or cerebriform surface (Tannous *et al.*, 2005). Abnormal (dysplastic) nevi are moles that do not match the normal appearance of nevi (Figure 2.14). An asymmetrical shape, irregular border, varied colouring, and diameter greater than 6mm on their own or in combination are markers for a dysplastic nevus (Tripp and Kopf, 2004).

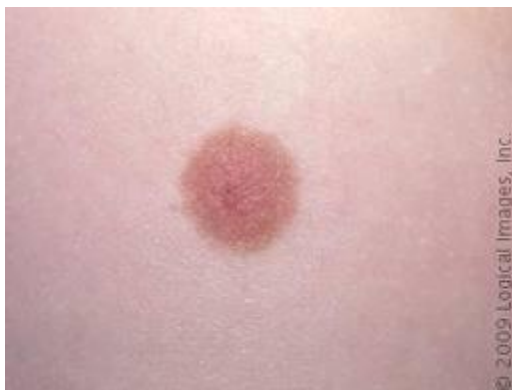

Figure 2.13 Nevus
(Logical Images Inc., 2009e)

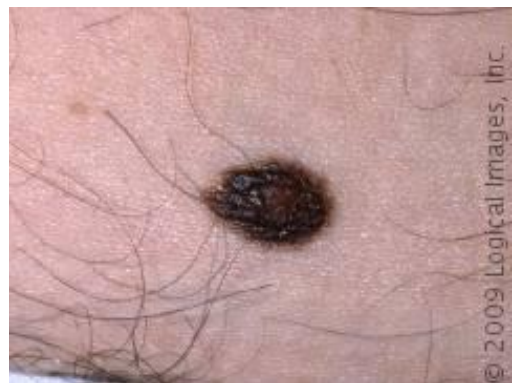

Figure 2.14 Atypical Nevus
(Logical Images Inc., 2009c)

Melanocytic nevi are benign neoplasms composed of melanocytes, which are pigment (melanin) producing cells found in the skin, hair follicles and iris of the eye. The

different pigmentation of areas of skin is not due to the number of melanocytes, but the level of activity of the melanocytes.

Nevi are very common, particularly in the face, neck, upper trunk, and arms. Green and Swerdlow (1989) have suggested that they are more commonly seen in the limbs of lighter-skinned individuals, whereas they are more common on the neck, face, and trunk of darker-skinned individuals. The factors that influence the development of nevi on the skin are debated, with some authors stating that their development has no relationship to sun exposure (Rampen *et al.*, 1988) and some suggesting that there is in fact a significant relationship between the two (Darlington *et al.*, 2002; Harrison *et al.*, 1999). The incidence and prevalence of nevi is highest in younger age groups. Darlington *et al.* (2002) followed a cohort of children over five years and found that the mean number of nevus counts increased year on year from the age of 12-13 to 16-17 years, with males always possessing a higher nevus count than females every year, as shown in Table 2.2. This was the case in full body counts as well as region-specific counts (Tables 2.3 and 2.4). Nevus numbers appear to reach a plateau at around 14 years (Darlington *et al.*, 2002; English and Armstrong, 1994), although Nicholls (1973) suggests a peak age in females of 20-29 years. Bataille *et al.* (2000) found a decreasing number of nevi with increasing age. Habitual sun exposure, rather than acute sun exposure such as that experienced on a summer holiday for example, is also seen to be an important factor in increased nevus counts (Darlington *et al.*, 2002). Darlington *et al.* (2002) also found that freckling on the shoulders and hands were significantly associated with total body nevus count. Increasing age and male sex are also predictive factors for higher body nevus counts (Darlington *et al.*, 2002). Interestingly, those with red hair and highly sun-sensitive skin possess lower nevus counts according to Darlington *et al.* (2002). Possible reasons given for this are that children with this skin colour may be exposed to

sunlight less often, or that the fact that their skin contains the lighter skin pigment pheomelanin, which makes it more difficult to identify nevi. Another possible reason is that light skinned, red-haired individuals are genetically predisposed to forming fewer nevi (English and Armstrong, 1994).

Table 2.2 Mean Full Body Nevus Counts in 12-13 year olds
(Darlington *et al.*, 2002)

Year	Males (n=63)	Females (n=48)
1990	142.7	113.5
1991	172.5	125.9
1992	196.2	153.1
1993	224.4	172.5
1994	240.0	182.9

Table 2.3 Mean Face and Neck Nevus Counts in 12-13 year olds
(Darlington *et al.*, 2002)

Year	Males (n=63)	Females (n=48)
1990	21.4	17.4
1991	29.8	19.8
1992	34.0	27.0
1993	34.4	26.0
1994	36.2	26.2

Table 2.4 Mean Shoulder and Back Nevus Counts in 12-13 year olds
(Darlington *et al.*, 2002)

Year	Males (n=63)	Females (n=48)
1990	34.7	21.7
1991	42.0	26.6
1992	45.7	30.0
1993	51.0	31.9
1994	53.3	34.6

Interestingly, Harrison *et al.* (1999) found that nevi on the hands were less common than on other frequently sun-exposed areas, such as the forearms, upper arms and neck.

This anomaly was also noted in a study of nevus counts in adolescent children by English and Armstrong (1994). Additionally, it was found that nevi were seen more often on the dorsum of the hand than the palmar surface. However, this is true of many pigmentary lesions, including ephelides (Ferri, 2009) and lentigines (Avram *et al.*, 2007; Barnhill, 2004).

Permanence

The clinical appearance of nevi may change with age, with the nevus becoming darker in colour and acquiring long, dark, coarse hairs (Tannous *et al.*, 2005). In cases of dysplastic nevi, the colouration, diameter, symmetry and border shape can change over time.

Numbers of nevi tend to increase from birth to young adulthood, peaking at around 25 years (Green and Swerdlow, 1989; Johr and Schachner, 2002). Johr and Schachner (2002) suggest an average of 43 nevi in males and 27 in females by age 25. They then undergo gradual shrinkage over time, with almost all nevi having disappeared by age 80 (Carton *et al.*, 2007; Johr and Schachner, 2002; Nicholls, 1973). Despite these potential changes in appearance, nevi may still be a useful feature in identification between images, due to their long-lasting presence.

In a study conducted by Kennedy *et al.* (2003), increasing age was the strongest factor determining disappearance of melanocytic and atypical nevi, with chronic sun exposure producing no observable effect. It was also suggested that the decline in observed nevus numbers in the literature may reflect a decline in nevus numbers in birth cohorts. An example given by Kennedy *et al.* (2003) describes how 13-15 year-old children born in 1977 and 1978 had a 5 to 6-fold higher prevalence of nevi than a comparable cohort

born two decades earlier (Green *et al.*, 1995 as cited by; Kennedy *et al.*, 2003). Although many studies have mentioned the phenomenon of nevi disappearance in later life, none have attempted to quantify this change.

2.3.5 Depigmentation and Hypopigmentation

It is possible for areas of the skin to become hypopigmented (decreased pigmentation) or depigmented (complete loss of pigmentation). Hypopigmentation can occur as a result of recent inflammatory processes, such as atopic dermatitis or allergic reaction. Localised loss of pigmentation in the skin is referred to as hypopigmentation. This is a common complaint, and can be the result of hypopituitarism as well as inborn errors of metabolism (Du Vivier, 2002). Loss of pigmentation is also seen in the early stages of vitiligo.

Vitiligo is a condition that begins with hypopigmented patches of skin that then progress to total depigmentation. This condition affects 1% of the population and the hands are one of the most common regions affected (Kahan *et al.*, 2009). Fifty per cent of sufferers develop the condition before 20 years of age (Du Vivier, 2002). Vitiligo is distinguished from albinism by the fact that in vitiligo, it is the loss of melanocytes that causes the depigmentation whereas in albinism, the melanosomes contain no melanin (Sterry *et al.*, 2006). Typical vitiligo macules are oval or round, with sharply circumscribed but irregular borders. Their size can range from a few millimetres up to several centimetres. Vitiligo macules can remain stable, but as it is a progressive disorder, they will often spread (Cassell and Rose, 2003). Examples of the physical appearance of vitiligo are shown in Figure 2.15 and Figure 2.16.

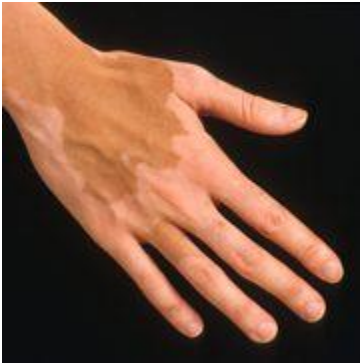

Figure 2.15 Vitiligo I
(Florida Skin Center, 2010)

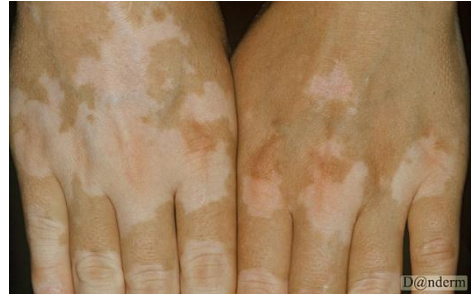

Figure 2.16 Vitiligo II
(Danderm, n.d.)

One of the most useful features of pigmentary conditions appears to be their relationship with age. For example, lentigines tend not to be seen until around 50 to 60 years-of-age. In comparison, ephelides are a very common feature of the dorsum of the hand from early in life. Their common occurrence makes them potentially useful for verification methods involving location and spatial relationships in particular. Nevi are a feature not commonly seen on the dorsum of the hand, according to the current literature. Their rarity in this region of the body is potentially very useful for image comparison purposes however, as their rarity serves to make their presence in an individual hand significant to identity verification.

2.4 Skin Damage to the Hand

In order to assess the relative individuating capacity of scars on the hand, it is necessary to identify which scar types and locations are more or less common and thus more or less individuating. For example, if a scar on the skin surface between the distal and proximal interphalangeal joint is a very common trait among individuals, then an offender and suspect match based on such a feature may be less individuating.

2.4.1 Incidence of Hand injuries

Twenty percent of patients attending Accident and Emergency (A&E) departments in the U.K. each year have a hand injury: this equates to over 1.36 million attendances for hand injuries each year, 71,000 of which will require surgery (Brennen *et al.*, 2007).

The incidence of hand injuries, in particular soft tissue injuries, is a number that varies across several different studies. However, general trends can certainly be extrapolated from the literature available that gives an impression of just how common these injuries are and what are the most important risk factors. Isolated hand and wrist injuries account for 6.6% of all new attendances at A&E departments in Northern Ireland (Hill *et al.*, 1998). Several authors suggest that hand injuries account for between 10 and 20% of all A&E admissions (Dias and Garcia-Elias, 2006; Dickson *et al.*, 2009). During a study of hand injuries in Malmö, Sweden, Rosberg and Dahlin (2004) found that 7/1000 inhabitants per year sustained a hand injury, accounting for 12% of attendances at A&E departments. The injuries studied included fractures, sprains, tendon injuries, superficial wounds, amputations, ligament injuries, dislocations, nerve injuries, burns, contusions and others. Of these injuries, 18% involved soft-tissue damage (superficial wounds, amputations, and burns). A similar study conducted in Denmark found that 12% of hand

and wrist injuries presenting to five Danish A&E departments were wounds (Angermann and Lohmann, 1993). Indeed, Trybus *et al.* (2006) state that hand injuries are considered one of the most frequent injuries to occur to the body.

There are a number of risk factors associated with sustaining a hand injury, including age, sex, occupation, and socioeconomic status (Hill *et al.*, 1998; Horton *et al.*, 2007; Rosberg and Dahlin, 2004). A number of studies have been conducted into the incidence of various types of hand injuries, as will be discussed in the forthcoming chapter. The common occurrence of injuries to the hand and fingers is particularly useful for identification from the hands, as soft tissue injuries often leave permanent evidence of their occurrence, such as a scar or an amputation. These features can then be used to compare the hands of the same individual from images, even when they may have been taken several years apart. Clarkson and Schaefer (2007) state that hand injuries are more commonly a result of trauma, making them particularly useful for the purposes of identification. This is due to the more variable nature of accidental trauma, and therefore, the more variable appearance of the resulting scars.

Rosberg and Dahlin (2004) and Hill *et al.* (1998) suggest that those most at risk from a hand injury are young males, between 11 and 25-years-old. This is further corroborated by Angermann and Lohmann (1993), who found a median age for hand injuries of 27.9 years for males and 30.8 years for females. Men were consistently more frequently injured at home, leisure, work and in traffic accidents, although a much higher proportion were injured specifically in work and traffic accidents. Larsen *et al.* (2004) conducted a study into hand injury epidemiology in Holland and Denmark. In the Dutch and Danish samples, 26% and 34% respectively of hand injuries were open wounds. In the Dutch sample, open wounds to the fingers occurred in 320 inhabitants per 100,000

of the population, accounting for 18% of hand injuries. In Denmark, open wounds to the fingers occurred in 900 per 100,000 inhabitants, accounting for 25% of hand injuries. Open wounds to the hands excluding the fingers affected 270 inhabitants per 100,000, equal to 8% of all hand injuries.

Hill *et al.* (1998) conducted a study of 4873 hand injuries seen in 6 of the 17 A&E departments in Northern Ireland. This sample population was comprised of 3354 (69%) males and 1519 (31%) females. The mean age of male patients was 26.4 years and the mean age for females was 29.2 years, with a combined mean of 27.2 years. It was found that there were two peaks in injury occurrence according to age, one at 11-15 years and one at 21-25 years. Of the injuries documented by Hill *et al.* (1998), 35% involved soft tissue damage to the arm, wrist or hand.

Injuries occur more often to areas at the border of the hand, such as the thumb (31%) or little finger (32%) (Rosberg and Dahlin, 2004). Additionally, the dominant hand appears to be slightly more at risk of injury (Rosberg and Dahlin, 2004), with a statistically significant higher risk level found by Hill *et al.* (1998). Rosberg and Dahlin (2004) found that in a sample of 1528 patients, 54% of injuries occurred to the dominant hand, and 46% occurred to the non-dominant hand. Hill *et al.* (1998) found a significantly higher risk of injury to the dominant hand in both left ($P < 0.01$) and right-handed ($P < 0.001$) individuals. In right-handed individuals the right hand comprised 55% of injuries and the left hand comprised 45%. In left-handed individuals the left hand comprised 58% of injuries and the right hand comprised 42%. However, they also found that the non-dominant hand was more at risk when the injury was caused by a knife. Knife injuries occurred to the non-dominant hand at a ratio of 1:3.4 (dominant to non-dominant). The other most common causes of injury (broken glass, opening a tin, fall on hand, hand caught between objects, hand through window/door, and injury at

work/machinery) showed a higher ratio of injuries to the dominant hand. When only occupational injuries are considered, the non-dominant hand appears to be more at risk of injury than the dominant hand. Sorock *et al.* (2001) found that right-handed people injured their left hand in 55.4% of cases and left-handed people injured their right hand in 57.7% of cases.

Hill *et al.* (1998) also describe the occurrence of injuries (soft tissue injuries and fractures) according to anatomical region of the hand, as shown in Table 2.5. The most commonly injured areas were the thumb, index finger, wrist and little finger. The region of the hand injured was not specified in 11% of cases and in 10% of cases, multiple fingers were injured.

Table 2.5 Hand Injuries by Anatomical Region
(Hill *et al.*, 1998)

Region of the hand	Percentage of injuries
Thumb	17%
Index finger	13%
Wrist	12%
Little finger	11%
Middle finger	10%
Ring finger	9%
Palmar hand surface	4%
Dorsal hand surface	3%

Many soft tissue injuries to the hand occur during sports. A study by Boyce and Quigley (2004) found that 70% of all sports injuries were soft tissue injuries. Of all the injuries to the forearm and wrist, soft tissue injuries of the wrist/hand, thumb, and fingers were among the four most common injuries. Although no figures were given for male and female soft tissue injuries, it was observed that men attended A&E with sports injuries far more frequently than women, at a ratio of 9:1.

Fifty-one per cent of hand injuries seen in an A&E unit in Edinburgh involved damage to the skin (Ross *et al.*, 1985). It was also found that out of 408 cases, 25% occurred at home, 33% at work, 19% in the street, 14% during sport and 9% had no specified cause (infection, swelling, or pain only).

Angermann and Lohmann (1993) found that wounds were the most common injury to occur in the fingers and metacarpal region. Wounds to the hand and wrist most commonly occurred at work or at home, indeed more than half (52%) of all the occupational injuries were wounds. Sorock *et al.* (2001) note that workers with acute hand injuries make up over 1,000,000 emergency department visits every year. Indeed, one of the most common risk factors for a hand injury is an occupation that involves manual work (Rosberg and Dahlin, 2004). In a sample of 1401 individuals, 877 (62.6%) of occupational hand injuries involved a laceration (Sorock *et al.*, 2001).

2.4.2 Burns

Kamolz *et al.* (2009) state that the hand is affected in more than 80% of burn injuries, while Groenevelt and Kreis (1985) states a slightly lower percentage of 71.6%. Cheng *et al.* (1990) found that the upper limb is affected in 39% of paediatric burns and 49% of adult burns. Furthermore, the dorsal surface of the hand tends to sustain burn injuries more frequently due to the fact that the hands are often used to protect the face from burn trauma, leaving only the dorsum exposed (Kamolz *et al.*, 2009).

Barret *et al.* (1999) state that the incidence of burn injuries is similar in all developed countries, around 31.2 per 100000 inhabitants, with the most common causes being flame burns and scalds. Research conducted over a 7-year study in a burns centre in Catalonia analysed both patients treated in the ER and patients admitted to the centre. It

was found that of the 12699 adult patients treated, 64% were male and 36% were female, with a mean age of 40 ± 22 years (Barret *et al.*, 1999).

In 2001, there were 498,507 non-fatal fire and burn injuries recorded by the National Electronic Injury Surveillance Systems All Injury Program (Pruitt Jr. *et al.*, 2007), which records data from 100 American hospital Emergency Departments selected as a probability sample of all U.S. hospitals with emergency departments (U.S. Consumer Product Safety Commission, n.d.). This equated to 174 per 100,000 of the population. No gender difference was apparent in this data with non-fatal fire and burn injuries in men accounting for 1.8% of all non-fatal injuries, and women accounting for 1.9%. The total number of non-fatal burn injuries was highest in the 25-34-year age group, with a total of 91,334, representing 229.4/100,000 of the population. The upper limbs were one of the most commonly affected areas by burns: 45% of non-fatal burns involved the hand or arm.

Ho and Ying (2001) found that when pediatric patients are taken into account, the median age of burn patients drops to 13.1 years. Adults accounted for 48.3% of burns admissions and a burn injury incidence of 1.5 per 1000 of the general population was observed. The most common mechanism of burn injury was domestic (71.1%) or industrial (16.5%), although domestic burns predominantly affected children whereas industrial burns were more common in adults between 30 and 50-years. Cheng *et al.* (1990) found that 63% of adult burns occur in an occupational accident.

2.4.3 Surgical Incisions

The array of surgical incisions that can be performed on the dorsum of the hand is vast. Incisions to the dorsum of the hand tend to be longitudinal, compared to the more common zig-zag incisions seen on the palmar surface due to the problems associated with flexion crease scars (Semer, 2001). Common surgical procedures that require dorsal hand incisions include compartment syndrome fasciotomies, surgical fixation of distal radius fractures and proximal interphalangeal joint surgery.

Scars resulting from surgical procedures tend to be less individuating than scars resulting from accidental injury. This is due to surgical procedures generally having set protocols for where the incision site should be located, resulting in the majority of individuals undergoing that surgery possessing a scar similar in length and in location (Clarkson and Schaefer, 2007). In the hand, incisions are created in similar positions due to the need to avoid creation of motion-restricting scars across flexion and extension creases (Netscher and Gharbaoui, 2007). Conversely, accidental scars can occur anywhere on the body and can be any shape, size or length due to the random nature of their occurrence (Rutty, 2007). It is possible that this results in accidental scars being of greater individuating value due to their more variable appearance. Additionally, there are a wide variety of factors that can affect how a scar heals and thus its final physical appearance. Oedema, infection and rough handling can all cause the re-inflammation of scar tissue, which results in additional collagen deposition to that already present. Mobilisation can also cause a scar to break, creating a new wound, and subsequently new scar tissue (Hardy, 1989).

Surgical incisions are usually made along Langer's lines. These lines are formed by anatomical lines of mechanical tension in the skin, and are the result of collagen fibres

running parallel to each other. When incisions are made perpendicular to Langer's lines, collagen fibres are cut transversely, causing widespread disruption. When incisions are made parallel to Langer's lines, disruption is minimised and less new collagen is required to be formed, and thus scar formation is less extensive (Campbell and Campbell, 2003).

In the fingers, common surgical incision types are 'lazy S' or curvilinear incisions, T-shaped, and H-shaped incisions, as well as longitudinal incisions. T-shaped and H-shaped incisions are particularly common over the distal interphalangeal joint as they allow better visualisation of the extensor mechanism and the joint itself (Rizzo and Cooney, 2009). Y-shaped incisions can also be used in surgery of the distal interphalangeal joint for treatment of mallet deformity and mucous cysts (Diao, 2002). Examples of common finger incisions are shown in Figure 2.17 and Figure 2.18.

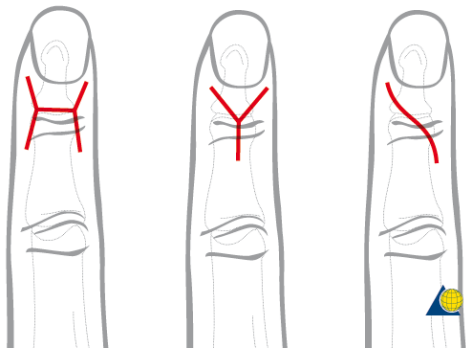


Figure 2.17 H-shaped, Y-shaped, and Curvilinear Incisions (Colton *et al.*, n.d.)

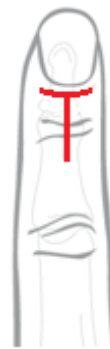

Figure 2.18 T-shaped Incision (Colton *et al.*, n.d.)

There is a wide variety of conditions that require some kind of surgical procedure to the hand, including infection treatment, fracture repair and surgical exploration. Many of the most common hand surgeries described by Narinesingh and Mahmoud (2008) are carried out in order to treat infections of the web space, thenar space, the nail bed and

septic arthritis. As well as treatment of infection, repair of fractures is also often carried out surgically. These treatments result in a variety of incision sizes, types, and locations. Examples of some of these incisions are described in Table 2.6, and images of the raw scars that result from these incisions are shown in Figures 2.19-2.23.

Table 2.6 Examples of Surgical Procedures of the Hand
(Sharpe and Stevanovic, 2000)

Surgery	Incision appearance	Condition
Dorsal approach to metacarpophalangeal (MCP) joint	Transverse incision across distal metacarpals, approximately 1cm distal to prominences of metacarpal heads.	Access to extensor tendons, treatment of pathology of the MCP joint
Dorsal approach to basal joint of the thumb	S-shaped incision or transverse incision centred over the basal joint.	Basal joint arthritis, ligament reconstruction
Gamekeeper's thumb approach to the thumb MCP joint	Curvilinear incision on dorso-ulnar aspect of the thumb.	Repair of the ulnar collateral ligament of the thumb
Dorsal approach to fingers	Zig-zag incision along dorsal aspect of proximal phalanx.	Extensor tendon repairs and fracture repairs
Paronychium approach	Longitudinal incision at corner of the nail, extends proximally for approximately ½ cm.	Injury treatment of nail bed, infection drainage, nail ablation

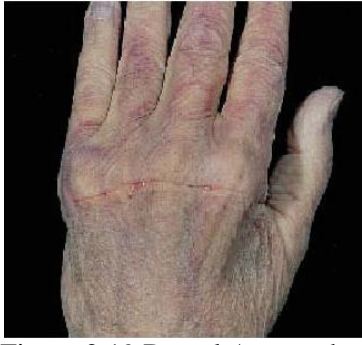

Figure 2.19 Dorsal Approach to MCP Joint (Sharpe and Stevanovic, 2000)

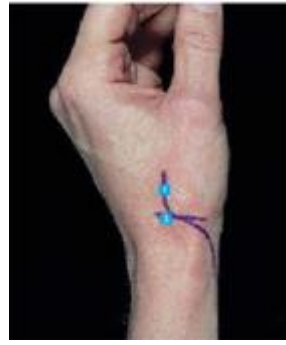

Figure 2.20 Dorsal Approach to Basal Joint of the Thumb (Sharpe and Stevanovic, 2000)

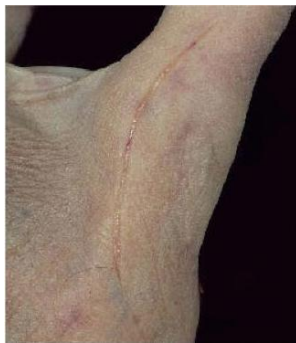

Figure 2.21 Gamekeeper's Thumb Approach to the Thumb MCP Joint (Sharpe and Stevanovic, 2000)

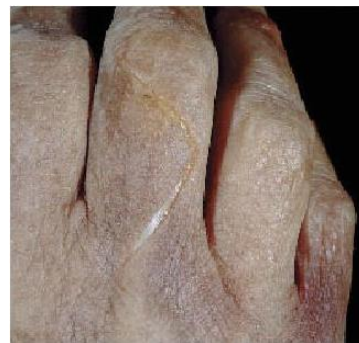

Figure 2.22 Dorsal Approach to Fingers (Sharpe and Stevanovic, 2000)

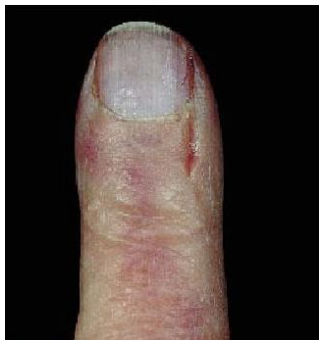

Figure 2.23 Paronychium Approach (Sharpe and Stevanovic, 2000)

In cases of compartment syndrome affecting the hand, a fasciotomy can be performed to release pressure. Incisions are made between the second and third metacarpals and

between the fourth and fifth metacarpals to allow decompression of the dorsal and volar interossei and the adductor compartment (Figure 2.24).

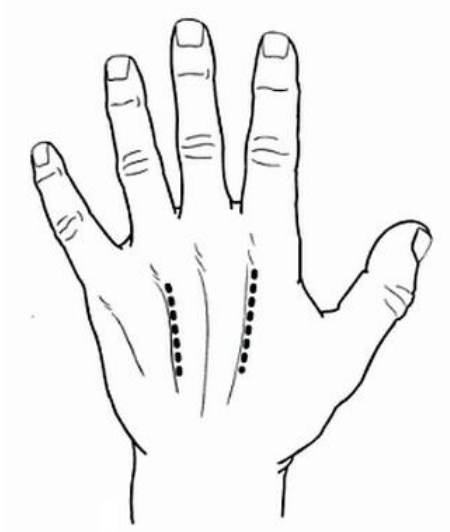


Figure 2.24 Dorsal Interosseous Compartment Incisions for Compartment Syndrome Treatment (Doyle *et al.*, 2006)

Surgery to internally fixate distal radius fractures can result in scarring beyond the wrist that extends into the dorsum of the hand when a longitudinal incision is made, rather than when a T-shaped incision is made. (Figure 2.25).

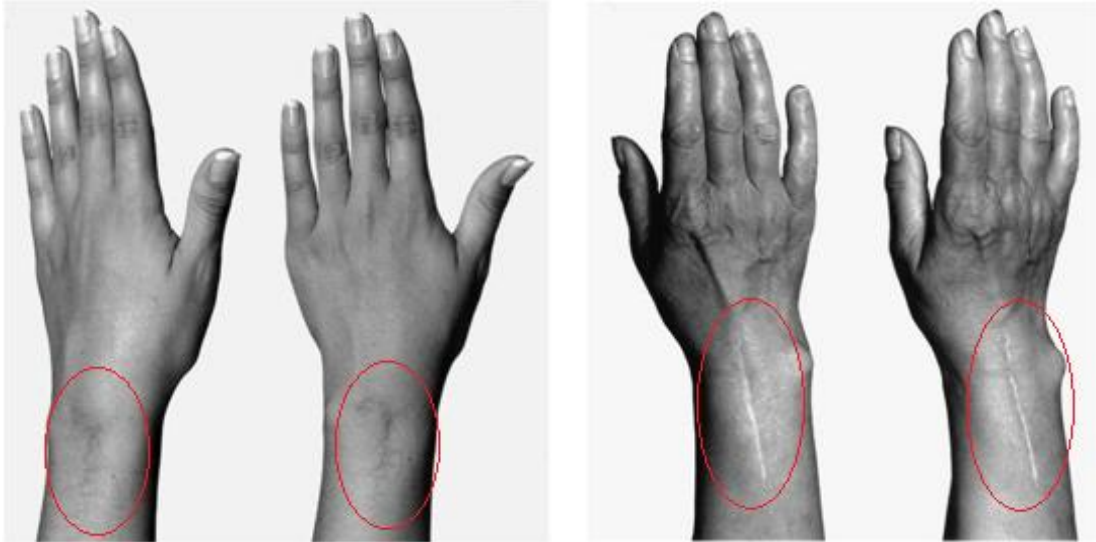


Figure 2.25 T-shaped Incision Scar (Left) and Linear Incision Scar (Right)

(Gangopadhyay and Packer, 2003)

Injuries affecting the hand are a common occurrence, possibly due to their inherent vulnerability as highly tactile regions of the body that are used to manipulate the environment and are generally always exposed. This vulnerability to damage subsequently lends itself to scar formation in the hand, potentially making the skin surface distinctive. Evidence suggests that many people will have sustained some sort of soft tissue injury of the hand by their middle-aged years, particularly males. The most at-risk individuals are young men, particularly those with a manual occupation and those involved in heavy sporting activity.

The proportion of A&E admissions that involve soft tissue damage to the hand varies across several studies, with some stating incidences of between 12 and 18% (Angermann and Lohmann, 1993; Rosberg and Dahlin, 2004), and some stating higher proportions, between 26% and 34% (Hill *et al.*, 1998; Larsen *et al.*, 2004), even as high as 51% (Ross *et al.*, 1985).

In particular, the fingers are more commonly injured than the hand itself. Generally, the dominant hand appears to be at greater risk of injury, with the non-dominant hand only being at greater risk in cases where the object that inflicts the injury is being held in the dominant hand. It has also been suggested that regions at the border of the hand are at greater risk of injury, with the thumbs, little fingers, and index fingers being injured more often than more central digits.

Surgical damage to the hand surface is also important to consider as well as accidental damage. There are a vast number of surgeries that can be performed on the dorsum of the hand and fingers. This will result in a range of associated scars that will be left by the incisions made in the skin. These can vary in size and appearance, depending on the size of incision required and whether the incision crosses tension lines in the skin.

The dorsal surface in particular can be more at risk from certain types of injury, such as in burns. The dorsal surface of the hand sustains burn injuries more often as a result of the hands being used to protect the face from burn trauma, leaving the dorsum exposed (Kamolz *et al.*, 2009). Similarly, it is often the dorsum of the hand that is captured in images, as the palmar surface of the hand is used to grip objects, leaving only the dorsal surface exposed. Burn injuries most commonly occur in domestic, industrial, and occupational environments. Domestic burns commonly affect children, whereas adult burn injuries occur more commonly in an industrial or occupational setting (Cheng *et al.*, 1990; Ho and Ying, 2001).

Ultimately, many people will sustain some sort of soft tissue damage to the dorsal surface of the hand at some stage in their life, whether through accidental injury or through intentional damage from incisions. These insults to the body surface can result

in distinctive features that can be used to rule an individual in or out of a possible identity.

2.5 Scars

In most soft tissue injuries, repair of the damaged tissue results in a region of once functional tissue becoming a region composed mainly of fibroblasts and disorganised collagen, commonly referred to as a scar (Ferguson *et al.*, 1996). Scar tissue is an aspect of skin damage that can provide useful comparative features on the hand. Not only is a scar a distinctive feature, but the physical appearance of that scar can be further individuating, due to its potential for developing a pathological abnormality. Scarring can manifest macroscopically as an alteration in the skin colour or texture, a change in vascularity, or as a depression/elevation of an area of skin, or a combination of these features (Ferguson *et al.*, 1996).

The potential for scars to change in appearance throughout life is also of importance to this research. Scar treatments lessen the pathological aspects of scar tissue, rather than actually healing scar tissue itself. Therefore, after these treatments a scar may still be visible, albeit with a more 'normal' appearance. Pathological scars are particularly prone to physical changes. The growth of a keloid scar beyond the boundary of the original injury can continue for an indeterminate amount of time, resulting in a gradual change in appearance. Normal scar tissue is stable, whereas hypertrophic scars can regress spontaneously.

Scars can result from accidental or surgical damage to the skin. Every year, 100 million people in the developed world acquire scars (Bayat *et al.*, 2003). The British Medical Journal classifies scars into several different groups: 'normal' fine line scars, contracture scars, hypertrophic scars and keloid scars. In order to discuss the origins of the variety of scar types possible, the process of wound healing must first be

understood. Wound healing occurs in three distinct phases: inflammation, proliferation and maturation (Roseborough *et al.*, 2004).

2.5.1 Scar Formation

Inflammation Phase

The first stage of wound repair is the inflammation phase. Ruptured cells and vessels surrounding the wound cause the activation of stress signal pathways almost immediately, promoting cellular processes involved in wound repair. One of the earliest responses to injury is due to blood vessel damage. Platelet activation and aggregation produces an insoluble haemostatic clot. This plugs damaged blood vessels and acts as a matrix that growth factors can bind to and that cells can move through.

Vasoconstriction occurs in the first 5-10 minutes after damage occurs, in order to reduce haemorrhage, promote platelet aggregation, and keep healing factors within the wound (Romo *et al.*, 2008). Vasodilation then follows for a more protracted period of time. This exposes the wound to increased blood flow, carrying inflammatory cells and factors into the wound that will fight infection and allow phagocytosis to proceed. One of the most important cellular groups to migrate into the wounded area during this period are macrophages. These cells phagocytose debris and bacteria in the wound. However, they also stimulate angiogenesis and secrete factors such as collagenases and elastinases that break down injured tissue (Shetty and Bertolami, 2004).

Proliferation Phase

In the second stage of wound repair, a framework of cells is created, upon which new blood vessels and skin cells will form. Granulation tissue forms and replaces the clot

form in the inflammation phase (Sussman, 2006). New capillaries form, supplying the area with oxygen and nutrients required for the growth and multiplication of new cells, as well as supporting collagen production by fibroblasts (Doughty and Sparks-Defriese, 2007). New epithelial cells also begin to grow into the wound (Tillman and Hanks, 2006).

Collagen synthesis will exceed collagen degradation to begin with, allowing the wound to fill with new cells. However, the rates of synthesis and degradation will eventually equalise. This attainment of homeostasis signals the beginning of the final maturation phase. Gradually, fibroblast numbers decrease as they begin to show increasing apoptosis, leaving a collagen-rich environment.

Maturation Phase

In the final stage of wound repair, Type III collagen is replaced by Type I collagen. Water is also absorbed from the scar tissue, allowing the collagen fibres to lie closer together, thereby decreasing the thickness of the scar. Remodelling of collagen continues during this phase through the continual cycle of collagen deposition and lysis. Scars continue to mature for an extensive period after their occurrence, undergoing changes for months or even years, and the process of full scar maturation can take up to 24 months (Clarkson and Schaefer, 2007).

2.5.2 Scar Characteristics

Healthy Scar Tissue

Beausang *et al.* (1998) illustrated the characteristics associated with scar tissue in the Manchester Scar Proforma (Table 2.7). This was developed as a clinical assessment of

skin scar severity (Brown *et al.*, 2010), aimed in particular at surgical incision scars and non-burn scars. Features such as mismatched colour to the surrounding skin, shiny surface tissue, raised contour in comparison to the surrounding unaffected skin, distortion of the tissue and firmer surface texture are all characteristics associated with scar tissue. The Vancouver Scar Scale (Table 2.8) is a commonly used clinical burn scar assessment method and it uses similar characteristics to the Manchester Scar Proforma: Differing pigmentation, increased vascularity, increased firmness and increased height of the affected area are used by this method. Both demonstrate the features used to recognise a scar and its level of severity.

With the Manchester Scar Proforma, an overall visual assessment of the scar of between 0 and 10 (0 indicating an excellent scar and 10 indicating a poor scar) is made initially. This value is then added to the sum of the individual parameter scores in Table 2.7 to give an overall score of between 5 and 28. Low scores represented clinically well healed scars and high scores represent clinically poorly-healed scars. The scores from the Vancouver Scar Scale are summed to give a total score of between 0 and 14, with 0 representing normal skin. No initial overall visual assessment is made with the Vancouver Scar Scale.

Table 2.7 Manchester Scar Proforma
(Beausang *et al.*, 1998)

Colour (cf.) to surrounding skin	Perfect	1
	Slight mismatch	2
	Obvious mismatch	3
	Gross mismatch	4
Surface	Matt	1
	Shiny	2
Contour	Flush with surrounding skin	1
	Slightly proud/indented	2
	Hypertrophic	3
	Keloid	4
Distortion	None	1
	Mild	2
	Moderate	3
	Severe	4
Texture	Normal	1
	Just palpable	2
	Firm	3
	Hard	4

Table 2.8 Vancouver Scar Scale
(Draaijers *et al.*, 2004)

Vascularity	Normal	0
	Pink	1
	Red	2
	Purple	3
Pigmentation	Normal	0
	Hypopigmentation	1
	Mixed	2
	Hyperpigmentation	3
Pliability	Normal	0
	Supple	1
	Yielding	2
	Firm	3
	Ropes	4
	Contracture	5
Height	Flat	0
	<2 mm	1
	2-5 mm	2
	>5 mm	3

Pathological Scars

Scar tissue can become hypertrophic or develop into a keloid. These types of scar are pathological as they differ from the healing pattern and physical appearance of normal scar tissue. Their formation in the region of the hand is less common, with the body regions most commonly affected being the jaw line, upper chest and upper back (Vejjabhinanta *et al.*, 2009). Keloid and hypertrophic scars form as a result of excess Type III collagen production compared to normal skin and normal scar tissue (Niessen *et al.*, 1999). These types of scar tissue never reach the point of equilibrium of collagen deposition and lysis, and instead remain in a state of greater deposition than lysis.

Hypertrophic and keloid scars are often distinguished from normal scar tissue by their nodular, red appearance (Rudolph, 1987). However, they also share several characteristics. They are both the result of increased fibroblast function and excessive accumulation of extracellular matrix. They also share the same common initial inflammatory phase as seen in normal wound healing (Su *et al.*, 2010). The key difference between hypertrophic scars and keloids is that hypertrophic scars do not extend beyond the margin of the original injury, whereas keloids do extend beyond this margin and may well continue to grow for weeks, months, or years (Wiles *et al.*, 2010). Hypertrophic and keloid scars are equally common in males and females, and more likely to affect individuals in their second to third decade (Niessen *et al.*, 1999; Vejjabhinanta *et al.*, 2009). Alster and West (1997) suggest that Caucasians are less susceptible to hypertrophic scars and keloids than Black and Hispanic populations.

Hypertrophic Scars and Burn Scars

Burn scars are recognisable through a number of physical characteristics, particularly their hypertrophic appearance, but they can also exhibit marked excessive or decreased skin pigmentation, as shown in Figure 2.26. Hair loss may be seen in affected areas also (Rutty, 2007). Hypertrophic scar formation is a very common complication for burn survivors, with 30-70% of burn patients developing abnormal scars, depending on skin colour and age (Bombaro *et al.*, 2003). Burn scar hypertrophy usually develops in deeper partial-thickness or full-thickness burns and tends not to be seen in excised or grafted burn wounds (Holmes and Heimbach, 2006; Urioste *et al.*, 1999). A common scar seen in hand burns is in the web space between the fingers, sometimes resulting in syndactyly (Kamolz *et al.*, 2009). This can be due to the formation of new tissue in the web spaces during the healing process, or can also be caused by insufficient dressing and splinting of web spaces after skin grafts are applied (Lapid and Sagi, 2005).

Bombaro *et al.* (2003) investigated the prevalence of hypertrophic scarring in burn patients. Of the white-skinned sample, 60% of patients aged 15-44 suffered from hypertrophic scarring, as did 68% in the 45-65 age group. In the non-white sample, 75% of 15-44 year olds had hypertrophic scarring as did 75% of 45-65 year olds. This increased likelihood of darker-skinned individuals to develop hypertrophic burn scars is also noted by Holmes and Heimbach (2006).

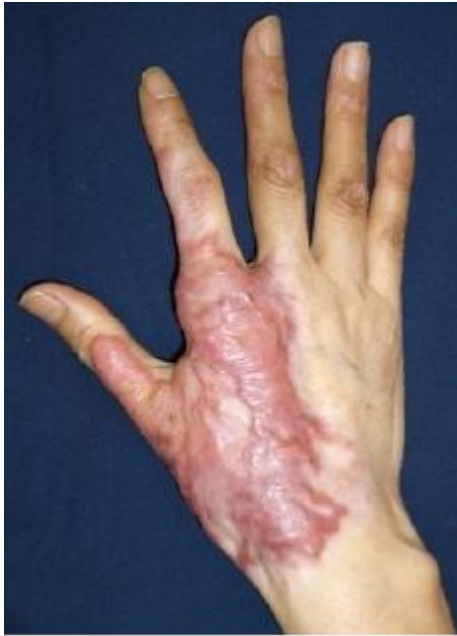

Figure 2.26 Burn, Two Years Post-injury
(Ogawa *et al.*, 2010)

However, it is important to note that hypertrophic scarring can also occur in non-burn scar tissue. Wounds closed under tension and rough handling can increase the risk of developing hypertrophic scarring. Younger skin naturally possesses greater tension, whereas older skin has lost some of its elasticity, so has greater redundancy and a smaller likelihood of developing a hypertrophic scar (Davies, 1985). Inadequate haemostasis and wound debridement as well as foreign bodies can also cause hypertrophic scar formation (Su *et al.*, 2010). Spontaneous regression of hypertrophic scars is common (Avram *et al.*, 2007).

Hypertrophic scars remain within the confines of the skin wound, and usually form within weeks of the injury occurring (Figure 2.27 and Figure 2.28). They can also regress and flatten with time in some cases (Alster and Tanzi, 2003; Brody *et al.*, 1981; Holmes and Heimbach, 2006; Niessen *et al.*, 1999), with some spontaneously regressing within 6 months of the initial injury (Avram *et al.*, 2007).

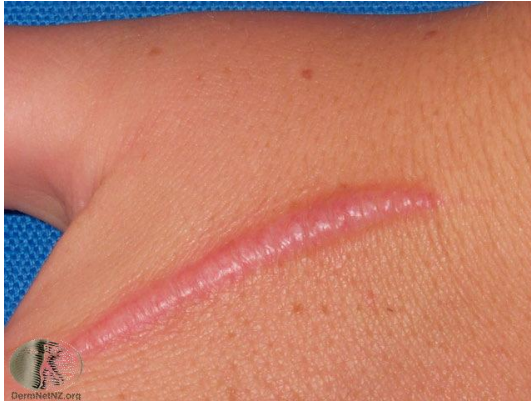

Figure 2.27 Hypertrophic Scar I
(DermNetNZ, 2010c)

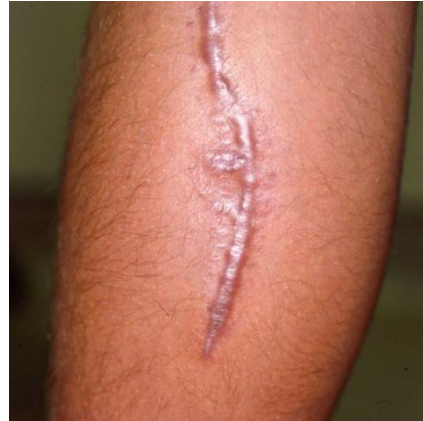

Figure 2.28 Hypertrophic Scar II
(Semchyshyn and Sengelmann, 2009)

Keloid Scars

Keloid scars are identified by scar tissue that extends beyond the original confines of the wound itself (Figure 2.29 and 2.30). Increased collagen production rather than decreased collagen breakdown occurs in keloid scarring (Abergel *et al.*, 1985). The actual root cause of keloid scar formation is relatively unknown. Several theories have been proposed as to its cause, including keratin stimulation (Machesney *et al.*, 1998), wound tension (Stier and Hirsch, 2009) and viral infection (Alonso *et al.*, 2008).

Younger individuals between 10 and 30-years-old appear to be at greater risk of developing keloid and hypertrophic scars (Li *et al.*, 2007; Rusciani *et al.*, 2008). O'Sullivan *et al.* (1996) suggest that this may be a result of the greater collagen content in younger individuals' skin, or due to higher skin tension in the young. They are also more common in those with darker skin colour (Davies, 1985; O'Sullivan *et al.*, 1996).

Keloid scars may manifest months or years after the initial injury occurs (Alster and Tanzi, 2003) and tend not to regress (Niessen *et al.*, 1999). Most keloid scars continue

to grow for weeks to months, others can grow for years (Wiles *et al.*, 2010). Growth is usually slow, but occasionally they can enlarge rapidly in a short space of time. Once growth ceases, keloids tend to remain stable in size and shape (Berman *et al.*, 2010). Keloid scars have a genetic aetiology, hypertrophic scars do not (Roseborough *et al.*, 2004).

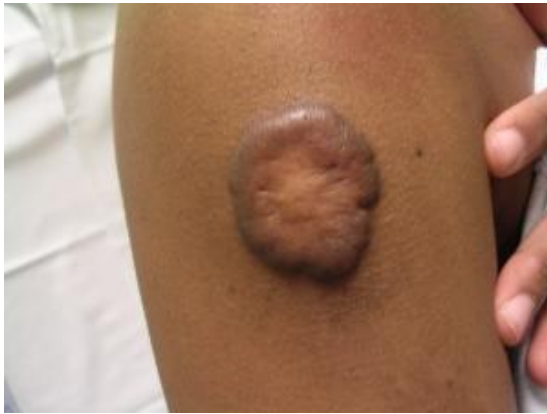

Figure 2.29 Keloid Scar I
(Scar Treatment Blog, 2009)

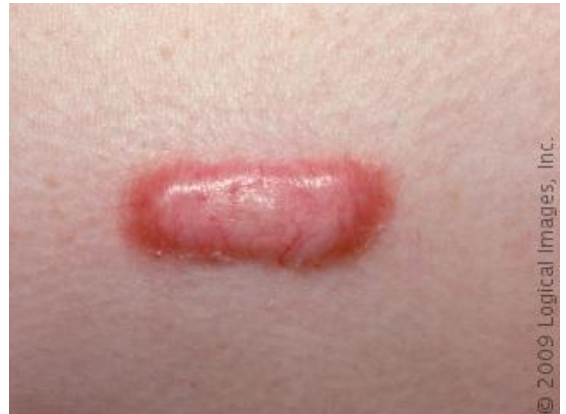

Figure 2.30 Keloid Scar II
(Logical Images Inc., 2009d)

2.5.3 Permanence of Scars

Several treatments are available that can improve the appearance of scars, hypertrophic scars and keloids. The most common effective treatments for hypertrophic scarring are pressure therapy, silicone pressure dressings and injection of corticosteroids (Holmes and Heimbach, 2006).

Pressure bandaging uses custom-made tight wrappings around the affected area. The exact mechanism of how this treatment reduces the severity of hypertrophic scars is not fully understood (Macintyre and Baird, 2006). However, it is believed to be due to a combination of factors:

- The limiting of blood supply, oxygen and nutrients, thereby reducing collagen production.
- Replaces pressure on the underlying tissue previously provided by the destroyed skin, reducing collagen production to more normal levels.
- Encouraging the realignment of collagen bundles.

However, Bombaro *et al.* (2003) suggest that hypertrophic scarring is equally prevalent in burn survivors who undergo pressure treatment and those who do not. The application of topical silicone gel appears to cause hypertrophic scarring to flatten, soften and increase in pliability (Musgrave *et al.*, 2002). The exact mechanisms through which it works are unknown, but it is believed to be related to decreased evaporative water loss compared to normal skin, which leads to reduced blood loss and decreased blood flow into the affected area (Gold *et al.*, 2001). Injection of corticosteroids is believed to decrease collagen synthesis and increase collagen breakdown (Tulli and Diociaiuti, 2008).

Certain types of injury and region of injury are more common depending on sex, age and handedness. Therefore, it is possible that the permanent markers of such injuries, in the form of scars and amputations, may also follow patterns depending on age, sex and handedness. This information can then be used to develop likelihood ratios in relation to potential age, sex or handedness based on the features seen in an image of a hand. This information may then be used in conjunction with any differences present between the two images to develop an assessment as to whether the hand could belong to the suspect beyond all reasonable doubt.

2.6 Body Modifications

It is important to consider deliberate modifications to the dorsum of the hand as well as accidental changes that may occur. Laumann and Derick (2006) conducted a study on an American sample of 500 individuals between 18 and 50-years-old. It was found that 64 (26%) males and 56 (22%) females possessed a tattoo somewhere on their body. Of this group, 9 males (14%) and 1 female (2%) had tattoos on the hand or fingers. This study also found that individuals between 41 and 51 years old were the least likely to possess a tattoo, with 15% (27/180 participants) possessing a tattoo. Individuals between 30 and 40 years old were the second most likely to possess a tattoo, with 24% possessing a tattoo (41/170 participants). The most likely group to possess a tattoo were individuals between 18 and 29 years old. Thirty-six percent of this age group (50/140 participants) possessed a tattoo. An example of a tattoo on the dorsum of the hand is shown in Figure 2.31.



Figure 2.31 Tattoo on Dorsum of Hand
(University of Dundee)

A study carried out by Mayers *et al.* (2002) surveyed 454 undergraduate students at an American university with an average age of 21 years for both males and females. This

study found that 29 males (13%) had a tattoo on the hand or arm, while 3 females (1%) had a tattoo on the hand or arm. This study was repeated 6 years later on a group of 266 male and 384 female students, and found that the prevalence of tattoos in this region had changed very little. Twenty-nine (11%) of male students possessed an hand or arm tattoo and 5 (1.3%) of female students possessed a hand or arm tattoo (Mayers and Chiffrieller, 2008). No literature covering piercings to the hand could be found. However, images of hand piercings can be found, and so this feature of the hand is still important to consider. Some examples of piercings to the dorsum of the hand are shown in Figure 2.32 and Figure 2.33.

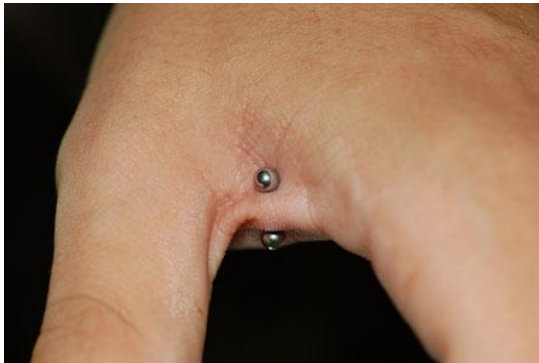

Figure 2.32 Hand Piercing
(Tommy T's Body Piercing, 2006)

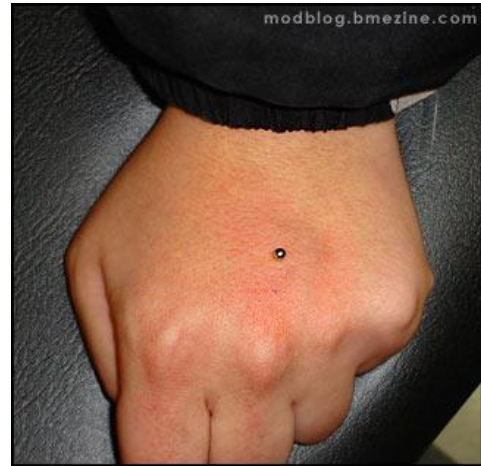

Figure 2.33 Deep Hand Piercing
(BMEzine.com, 2006)

2.7 Hand Image Evidence in the British Court System

2.7.1 Forensic Image Comparison

Harris and Grace (1999) traced the progress of 483 cases of rape in the United Kingdom (U.K.) in 1996. Of this sample, 25% ($n=120$) of the complainants were under the age of 16. More recent statistics from the 43 police forces in England and Wales found that 21,618 sex offences against under-18s were recorded during 2008-2009, including rape, gross indecency and incest (Holden, 2010). The increasing ease of access to the Internet and other forms of technology available to perpetrators of abuse is of concern to the law enforcement profession, due to the natural assumption that committing these crimes may be made easier for the offender by such technology. This increased accessibility of large quantities of offensive material, in a speedy, efficient and anonymous way has resulted in the addition of a significant new dimension to the social problem of child sexual abuse (Taylor and Quayle, 2006). For this reason, the development of new methods of identifying and prosecuting these offenders is imperative.

Guidelines for the forensic comparison of facial images were recently published by the National Policing Improvement Agency (NPIA) (National Policing Improvement Agency, 2009). This document lays out a number of important points in relation to the use of image comparison for the purpose of identification in a legal setting. It is written with reference to the face in particular; however the same protocols could be applied to other areas of the body, including the hands. It states that image comparison depends strongly on the quality of the images being compared (National Policing Improvement Agency, 2009). It is also suggested that identification through comparison of images does not have evidential value unless it demonstrates morphologically comparable features, in a similar way that fingerprint evidence is prepared. It also highlights the

importance that such comparisons must illustrate the significance of points of similarity and difference, and that it must highlight presence and absence of features. Another matter highlighted in this report is the importance of probability factors and likelihood of repetition of features to forensic image comparison evidence. This issue was highlighted in a recent High Court of Appeal case, (*Regina v T*, 2010), where there was disagreement over likelihood ratios produced by an expert witness brought by the Crown. The issue in question was the use of a likelihood ratio with regards to the most likely source of a footwear mark found at the scene of a murder. Evidence brought by the expert witness was found to be based on likelihood ratios and statistical analysis that the expert witness had not disclosed to the court. These likelihood ratios were found to have been formed in the absence of any form of database of information pertaining to the evidence. This therefore led to an appeal on the basis that the evidence submitted had been subjective, and had not been transparent. This case highlighted a potential problem with the use of likelihood ratios in British Courts, whereby expert witnesses could give an evaluative opinion based on likelihood ratios that were in fact based more on experience than on a database of information. Therefore, the development of databases of reliable information is vital to the admissibility of this form of evidence in the British Court system, as it allows the formation of reliable likelihood ratios and statistical inferences.

Another important aspect of forensic image comparison is what can be done to forensic images, in order to improve their evidential worth. Images used in Court can be classified into two categories. Type I images are used largely to illustrate a scene, or to show the location of items in relation to each other. These images are described by a witness, and it is the testimony of the witness that will be scrutinised by the Court rather than the image itself. Type II images are those that are used to highlight something

specific. These images often will have undergone extensive analysis, or will have tone scales distorted and colours changed in order to highlight a specific feature. Thus, these images may not necessarily look similar to the original image, even though it is derived from it. These images will require testimony from an expert witness, in order to explain to the judge and jurors the steps involved in the preparation of the image, and convince them that it is a legitimate extension of the original image (Blitzer *et al.*, 2008).

The images involved in Court cases where comparison of hand images is required will often be Type II images. This is due to the fact that enhancement of colours is often required in order to better show features that are important to the comparison. For instance, regions of darker pigmentation such as freckles and moles are better visualised in the yellow channel of a colour image, rather than in the full colour version of the image. This method of image enhancement involves viewing an image with only the yellow pixels in the image visible, while removing the cyan, magenta and black-coloured pixels from view.

Similarity of features does not necessarily prove identity, but differences lend a strong argument to exclusion. However, as the number of similarities from different aetiological sources increase, the number of individuals who will share that specific set of similarities will likely decrease, strengthening the possibility of a positive identification (National Policing Improvement Agency, 2009). Identification based on different aetiologies is considered more reliable when the features have resulted from different factors. For example scars can be an accidental factor, whereas freckles and moles are the result of an interaction between genetic and environmental influences. This makes a match between two different individuals based on a combination of these features very unlikely (Black *et al.*, 2009).

The recent prosecution of Dean Hardy was the first case of a paedophile confessing on the basis of photographic evidence of an offender's hands (Black *et al.*, 2009). Hardy was arrested in September 2007 after a large number of indecent images of children (levels 1-4) were recovered from equipment in his home. These levels are a reflection of the seriousness of an image's content and are based on a system of assessing the severity of indecent images of children. The current U.K. system, which is shown in Table 2.9, consists of 5 levels, and is derived from the COPINE Project's 10-level image descriptions (Akdeniz, 2008).

Table 2.9 Oliver Image Description Scale
(Akdeniz, 2008)

1	Images depicting erotic posing with no sexual activity
2	Sexual activity between children, or solo masturbation by a child
3	Non-penetrative sexual activity between adults and children
4	Penetrative sexual activity between children and adults
5	Sadism or bestiality

Five of the images retrieved depicted the hand of a white adult touching a pre-pubescent female. The hands possessed a heavily freckled appearance. When the hands in the images were compared with images of Dean Hardy's hands by a team of forensic identification experts, it was concluded that the offender's hands and Hardy's hands were substantially similar and that no differences could be detected (Metropolitan Police, 2009).

In another important case of this type, Neil Strachan was convicted on the basis of evidence that included a nail bed defect seen in his right thumb. In this case, 7000 images of child abuse were found on a computer handed in for repair by Strachan (Carrell, 2009). This resulted in the launch of Operation Algebra, a widespread investigation of Strachan's contacts, ultimately resulting in the arrests of Neil Strachan

and seven other people. Importantly, one of the images of abuse that was seized showed an adult hand. This image came to be known as “the Hogmanay Image” in the Court case due to the date of its taking. This image was sent by Strachan to one of the other offenders, with an accompanying message saying the adult in the image was him. Strachan was known to own a polo shirt that matched that seen in the image, but further evidence was required to prove he was indeed the abuser seen in the image. Along with further corroborating evidence, human identification experts examined the right thumb seen in the image and compared it with photographs of Strachan’s thumbs. It was noted that the lunule of the offender’s nail possessed a developmental abnormality and that the lunule of Strachan’s nail possessed a similar distortion. In addition to this, other similarities were noted between the offender image and Neil Strachan’s hand, as well as the fact that there were no differences between them to suggest that they could not be the same individual. It was stated that there was “strong evidence” to support the proposition that Strachan and the abuser seen in the image were the same person (Robertson, 2009).

2.7.2 Admissibility of Image Comparison Evidence

The comparison of suspects with offenders seen in images or video of a crime taking place is of vital importance. As well as child pornography offenses, criminal cases where such evidence may be required include drug-trafficking, terrorism, and identity fraud and theft. Possession of child pornography is a very different offence to actively participating in the production of images of child pornography, or being the adult who commits the illegal physical act. Both in public and legal opinion, the act of sexually assaulting a child is regarded as a more serious offence than possessing child pornography, not that this detracts from the severity of the latter offence. The distinction between an offender being the possessor of child pornography, or both a possessor and a perpetrator of child sexual abuse is therefore of vital importance. The maximum prison term for possession of child pornography under UK law is 10 years imprisonment (Akdeniz, 2008), whereas the maximum prison term for rape or sexual assault of a child or a child less than 13-years-old ranges from life to several years imprisonment (Sexual Offences Act, 2003). The age of the victim is an important distinction to make, due to the fact that a child under 13 years old cannot legally give their consent to any form of sexual activity. However, in cases involving a victim between 13 and 16 years old, it is possible for the Defence to argue that the suspect genuinely believed the child to be over the age of 16. Therefore, when an individual is found to be in possession of such offensive material, it is imperative that an investigation takes place into whether they are also seen participating in the abuse in the images.

In order for expert evidence to be admissible in a UK Court, the evidence itself is compared against unofficial criteria based on a triad of legal rulings. Digital evidence is no different and must also meet the same criteria of reliability and admissibility. These

rules are based on/are similar to the US Court's admissibility rules. The first of these to come into effect was the Frye standard in 1923. *Frye v. United States*, 293 F. 1013 (1923) is the oldest standard governing the admissibility of scientific evidence, and states that the thing from which the deduction is being made must have gained acceptance within its particular field (Rudin and Inman, 2002).

The Daubert ruling, used in the U.S. legal system, focuses on the testing of a particular piece of evidence or testimony. The Daubert standards are a result of *Daubert v. Merrill Dow Pharmaceuticals, Inc* 509 U.S. 579, (1993) and contain four considerations for evaluating the reliability of scientific evidence, falsifiability, peer review, error rates and acceptability in the scientific community (Cheng and Yoon, 2005). In Daubert, the Supreme Court lists the following factors for judges to use when deciding whether evidence is admissible (Mallett, 2010).

- The evidence must be based on a testable theory or technique.
- The theory or technique can be, or has been, tested using the scientific method.
- The theory or technique has been subjected to peer review and publication
- There is a known or potential error rate and there is existence and maintenance of standards controlling the technique's operation
- The theory or technique is generally accepted within the relevant scientific community

Federal Rule of Evidence 702 (2000) is another test from the U.S. legal system, which is used to decide whether a particular piece of evidence is useful to the Court, and it states that:

“if scientific, technical or other specialised knowledge will assist the trier of fact to understand the evidence or to determine a fact in issue, a witness qualified as an expert by knowledge, skill, experience, training or education may testify thereto in the form of an opinion or otherwise, if (1) the testimony is based upon sufficient facts or data, (2) the testimony is the product of reliable principles and methods, and (3) the witness has applied the principles and methods reliably to the facts of the case.” (Mallett, 2010).

Despite the standards used in the U.S. legal system, scientific techniques do not have to pass any formal tests to be considered admissible before a U.K. Court, although the Frye standards were approved by the English Court of Appeal in a case in 2001 (Cooper and Cooper, 2007). The current legal standard in U.K. Courts regarding quality of scientific evidence is whether it is generally accepted by the scientific community (Cooper and Cooper, 2007). The judge decides whether any piece of evidence can be admitted. However, under U.S. law there are specific standards that evidence must pass before it can be admitted to the Court.

Recently, the U.K. legal system has shown signs of leaning towards the U.S. system of rulings governing evidence admissibility. In a report by the House of Commons Science and Technology Committee (2005), it was described how concerns had been raised with regards to the U.K.’s lack of established protocols for the validation of forensic techniques prior to their admittance in Court.

Further to this, the Law Commission published a consultation paper to address problems with evidence admissibility in the U.K. and proposed an overhaul of the current protocols (The Law Commission, 2009). It was suggested that the U.K. Courts should adopt a system more similar to that seen in the U.S., where the trial judge possesses a

‘gate-keeping’ role. Under this system, a clearly defined test would be used to determine whether proffered evidence was sufficiently reliable.

Improving the methods by which images of suspects are compared to images of offenders for the purpose of identity verification is of vital importance. Recent cases have shown that successful prosecution can arise from image comparison cases. However, in order to improve the strength of this form of evidence in a Court of Law, further improvements are necessary. A greater understanding of the features that can make the dorsal surface of the hand distinctive is one of these improvements required. In addition to this, a greater understanding of the incidence rates and likelihoods of incidence according to factors such as sex, age or handedness would also improve the robusticity of this form of evidence.

The admissibility of any novel technique or expert evidence to be used in the U.K. Court system is extremely important. Currently, the U.K. legal system relies on the trial judge to decide whether tendered evidence is sufficiently reliable to be considered in Court. However, there is significant evidence to suggest that the U.K. legal system may soon adopt protocols similar to the rulings that currently govern evidence admissibility in the U.S. legal system. The U.S. triad of rulings (Daubert, Frye and Federal Rule of Evidence 702) state that any new technique/method must have been tested, published and subjected to peer-review, have standards and a known or potential error rate, and have gained general acceptance within the relevant scientific community. This final point is echoed by the Frye ruling. Further to this, the Federal Rules of Evidence require that evidence or testimony is based on sufficient data, is the product of reliable principles and methods, and that the witness has applied the methods and principles reliably to the facts of the case. These rules ensure that expert evidence and testimony

given to the Court is independently scrutinised and that the evidence is complete, credible, and thorough (Mallett, 2010). It is of great importance that any technique or method relied upon in court meets the triad of rulings set out in this chapter, in order that it is found to be admissible to the Court. The evidence given by an expert must be capable of withstanding or defeating any challenge in Court, and these rulings ensure the authority of the expert and the authority of their knowledge. The authority of the knowledge used is based upon the validation, relevance and currency of the technique or method, whereas the authority of the expert lies in their competence to evaluate that knowledge, and their currency in doing so (Mallett, 2010).

Chapter 3 : Materials and Methods

This chapter details the type and amount of data collected from the images analysed for this research. Protocols used for recognition of relevant features will be detailed and the recording system for the data will be described. An overview of the statistical analysis performed on the data will also be discussed.

3.1 Sample

The sample consisted of 260 individuals whose hand images are held on a database in the Centre for Anatomy and Human Identification at the University of Dundee. This database is largely composed of serving police officers and staff and students from the Centre. Dorsal view images for the left and right hand of every participant were collected at an earlier date prior to commencement of this study. The breakdown of the sample by age, sex and handedness is shown in Tables 3.1 and 3.2. Some participants chose to withhold some personal information, resulting in a small number of people of unknown sex, handedness or age, or a combination of these.

Each participant had previously filled out a consent form for their images to be used for the purposes of academic research, which gives umbrella coverage to this research project. These forms also contained personal information including age, sex and handedness. Every participant was informed of their right to remove themselves from the study at any time, without explanation, and their images and personal data would be destroyed immediately. Each participant was advised that their personal data would be held in accordance with the Data Protection Act 2004 and would only be available to

researchers directly involved with the study. Ethical approval for this research was granted by the Ethics Committee of the University of Dundee.

Table 3.1 Participant Breakdown by Handedness and Sex

Handedness	Male	Female	Unknown sex	Total
Right handed	156	55	1	212
Left handed	21	5	/	26
Ambidextrous	/	1	/	1
Unknown handedness	/	/	21	21
Total	177	61	22	260

Table 3.2 Participant Breakdown by Age and Sex

Age groups	Male	Female	Unknown sex	Total
20-29	0	6	0	6
30-39	32	21	0	53
40-49	113	22	0	135
50-59	22	7	0	29
60-69	0	4	0	4
Unknown age	10	1	22	33
Total	177	61	22	260

3.2 Landmarking

The dorsal surface of each hand was divided into 24 grid-cells by way of a deformation grid, with each cell being assigned a number (1-24). The grid was created via the placement of points on various landmarks seen in the hand. These landmarks allowed a grid to be formed across the hand, thus subdividing the dorsal surface into the 24 individual grid-cells. Landmarking and grid formation was carried out manually in Adobe Photoshop CS3.

The 27 landmarks used to form the grid are listed in Table 3.3, and are partially based on landmarks used in previous studies by Berry (2008) and Huggins (2010). The

landmarks were chosen due to their homogeneity and reproducibility across the entire image database. These landmarks allow the hand to be subdivided into 24 individual grid-cells. A description of each grid-cell's position on the hand is shown in Table 3.4.

Table.3.3. Landmarks for Grid Placement

1	Most medial point on the forearm-hand constriction
2	Most lateral point on the forearm-hand constriction
3	Point where the thumb or its associated interdigital webbing meets the palm
4	Most lateral (prominent) point over the 1 st metacarpophalangeal joint
5	Deepest point in the interdigital webbing between the 2 nd and 3 rd digits
6	Deepest point in the interdigital webbing between the 3 rd and 4 th digits
7	Deepest point in the interdigital webbing between the 4 th and 5 th digits
8	Point reached by extending line from point 7 parallel with knuckle crease to medial edge of hand
9	Point reached by extending line from point 5 in line with knuckle crease to lateral edge of 2 nd digit.
10	Deepest point in the medial aspect of the crease over the interphalangeal joint of the thumb
11	Most lateral (prominant) point in the crease over the interphalangeal joint of the thumb
12	Most medial point in middle of proximal interphalangeal (PIP) joint crease of 5 th digit
13	Most lateral point in middle of PIP joint crease of 5 th digit
14	Most medial point in middle of PIP joint crease of 4 th digit
15	Most lateral point in middle of PIP joint crease of 4 th digit
16	Most medial point in middle of PIP joint crease of 3 rd digit
17	Most lateral point in middle of PIP joint crease of 3 rd digit
18	Most medial point in middle of PIP joint crease of 2 nd digit
19	Most lateral point in middle of PIP joint crease of 2 nd digit
20	Most medial point in middle of distal interphalangeal (DIP) joint crease of 5 th digit
21	Most lateral point in middle of DIP joint crease of 5 th digit
22	Most medial point in middle of DIP joint crease of 4 th digit
23	Most lateral point in middle of DIP joint crease of 4 th digit
24	Most medial point in middle of DIP joint crease of 3 rd digit
25	Most lateral point in middle of DIP joint crease of 3 rd digit
26	Most medial point in middle of DIP joint crease of 2 nd digit
27	Most lateral point in middle of DIP joint crease of 2 nd digit

Table 3.4. Hand Cell Descriptors

Cell letter	Descriptor
1	Most lateral proximal region
2	2 nd lateral proximal region
3	Proximal central region
4	2 nd medial proximal region
5	Most medial proximal region
6	Most lateral distal region
7	2 nd lateral distal region
8	Distal central region
9	2 nd medial distal region
10	Most medial distal region
11	Proximal region, digit 1
12	Proximal region, digit 2
13	Proximal region, digit 3
14	Proximal region, digit 4
15	Proximal region, digit 5
16	Distal region, digit 1
17	Intermediate region, digit 2
18	Intermediate region, digit 3
19	Intermediate region, digit 4
20	Intermediate region, digit 5
21	Distal region, digit 2
22	Distal region, digit 3
23	Distal region, digit 4
24	Distal region, digit 5

Proximal sector of the dorsum (1-5)

Distal sector of the dorsum (6-10)

Digital sector (11-24)

The grid produced by the point placements described in Table 3.3 is shown in Figure 3.1.

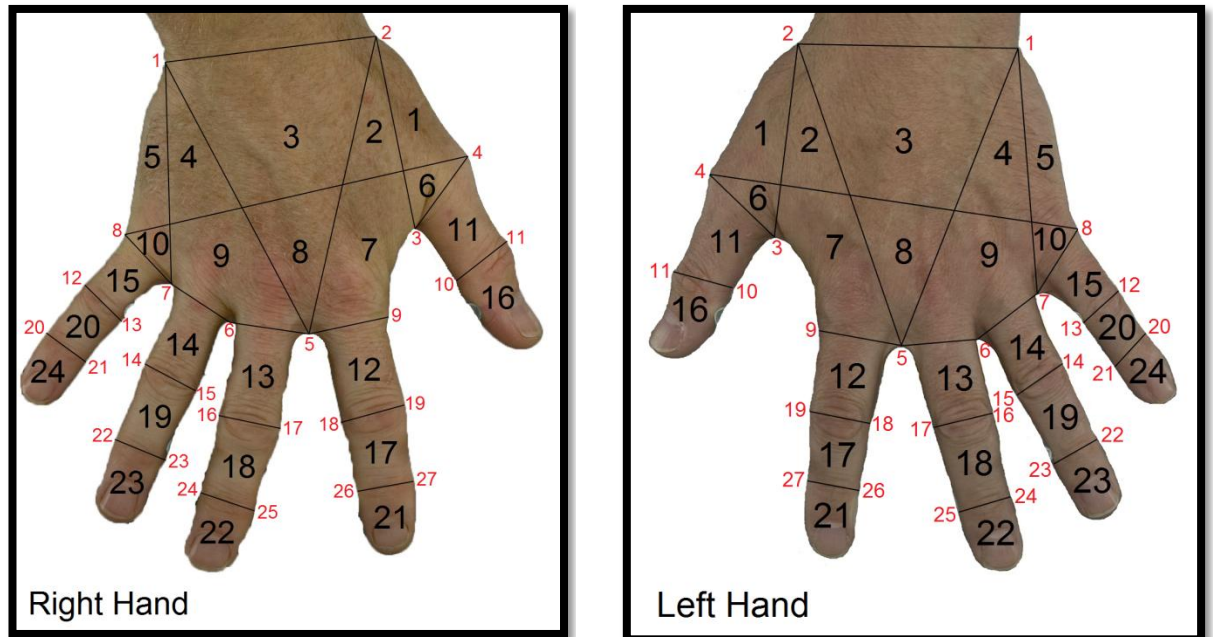


Figure.3.1. Right and Left Hand Grids, Showing the 24 Grid-cells

The most proximal limit of the grid was defined as the constriction between the hand and forearm, at the wrist, as described by Amayeh and colleagues (2009). Lines 7-8 and 5-9 were drawn parallel with knuckle creases due to the lack of a reproducible anatomical point that could be identified in all of the images. Similarly, points 10 and 11 were located at the most medial and lateral points respectively on the interphalangeal joint of the thumb due to a lack of reproducible anatomical landmarks in that region. Lines demarcating the division between proximal and intermediate digit regions and intermediate and distal digit regions were drawn in a position that visually appeared to be central according to the knuckle creases. Again, this was due to the difficulty of identifying a reproducible point on each knuckle.

3.3 Image Enhancement

A reduction of image resolution was required in order to remove tiny blemishes less than 1 mm wide that were created by intersecting wrinkles and creases on the dorsum of the hand. These blemishes were just visible in the original images but were impossible to distinguish reliably from ephelides. This resulted in great difficulty in quantifying the areas of hyperpigmentation that were required, i.e. ephelides, nevi, and lentigines. It was decided that these blemishes would not be visible in most genuine forensic cases due to reduced image quality. Reducing the image resolution removed these blemishes from the images and also reduced the image quality to a level more likely to be seen in a genuine forensic image comparison case (Mallett, X., pers. comm.) which it was hoped would give a more realistic interpretation in terms of how many quantifiable features would be visible in a forensic image.¹

In order to ensure that every image was enhanced in the same way, an action command was set up in Adobe Photoshop CS3. This allows a set of commands to be pre-set, and subsequently uniformly applied to every image. The images were enhanced by reducing the resolution to a width of 1000 pixels and a height of 667 pixels from the original resolution of 2160 pixels by 1440 pixels. This was carried out after the image had been landmarked and had the deformation grid applied to it. The change in resolution did not markedly reduce the clarity of the images, so did not appear to hamper the gathering of data from other feature classes. An example of the features seen in an image before the reduction in resolution are seen in Figure 3.2 and those seen after the reduction in resolution are seen in Figure 3.3.

¹ With hindsight, this was viewed as a flawed decision.

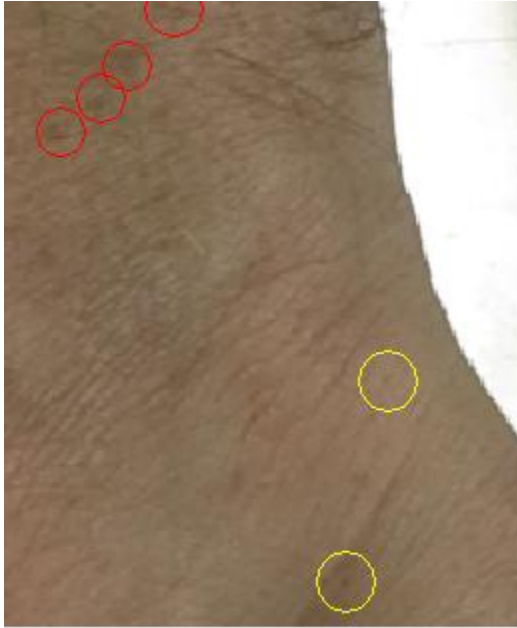

Figure 3.2 Features Pre-resolution Change

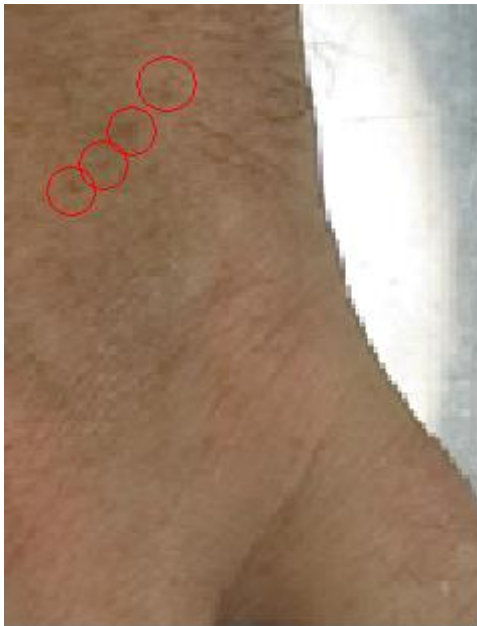

Figure 3.3 Features Post-resolution Change

Each image was viewed in CMYK (Cyan Magenta Yellow Black) colour in order to allow isolation of the yellow channel. The selection of the yellow channel causes yellow colouration within an image to be displayed individually, which allows areas of hyperpigmentation such as lentigines and ephelides to be seen more clearly. An example of a hand image prior to isolation of the yellow is shown in Figure 3.4, with the same image shown in Figure 3.5, but with the yellow channel isolated. Conversion of a full colour image to the yellow channel simply requires the yellow channel to be selected in the Channels toolbox in Adobe Photoshop.



Figure 3.4. Hand Image Prior to Isolation of Yellow Channel

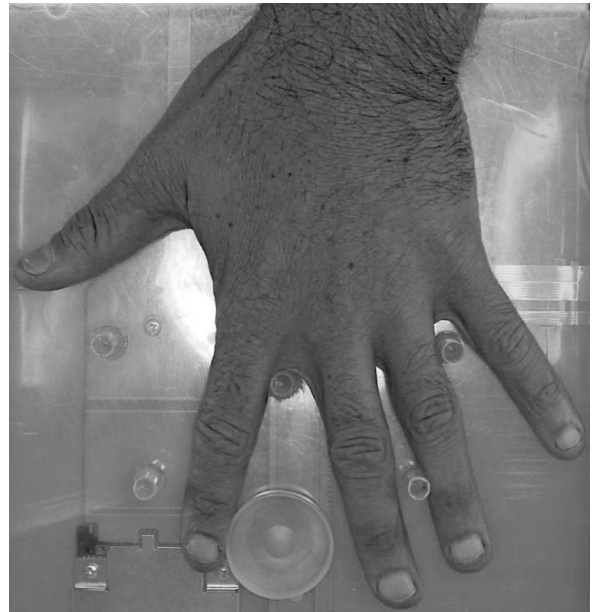

Figure 3.5. Hand Image After Isolation of Yellow Channel

3.4 Image Analysis

Each image was observed once, and the features in each cell were recorded. The data collected on each feature is shown in Table 3.5. No information was gathered on spatial relationships between features and recording was carried out manually, based on a visual observation of each image.

The Count Tool in Adobe Photoshop was used to mark features with a numerical marker, which allowed quantification of features to be carried out in a more accurate and repeatable fashion. The yellow channel of the image was viewed in addition to the full colour image in order to better visualise ephelides. Switching between the full colour image and the yellow channel of the same image can easily be done in Adobe Photoshop via the Channels tab.

Table.3.5. Information Gathered According to Feature

Feature	Information gathered
Ephelides (freckles)	Number
Nevi (moles)	Number
Lentiginos (liver spots)	Number
Depigmentation and hypopigmentation	Number
Dermatological conditions	Number, condition
Scars	Number, type, size, orientation
Hypertrophic scars	Number, size
Keloid scars	Number, size
Amputations	Number
Body modifications (piercings, tattoos)	Number, colours present in tattoo, type of piercing

Features were quantified according to the characteristics described in the review of the literature. A summary of the characteristics used to recognise each feature, and guidelines describing how scar information was recorded can be found in the Observer Information Pack, which is in Appendix A.

Scars

Scars were recorded along with additional information relating to their approximate size and appearance. Scar type was assessed as linear or non-linear. Non-linear scars were characterised by the inability to identify an overall orientation. Assessment of scar orientation was carried out based on a 4-direction scale, which is shown in Figure 3.6. The long axis of the middle finger was used to define the orientation of the proximo-

distal axis, defined as orientation 1, shown in Figure 3.6. The orientation of each scar was then determined by which of the four directions the scar most closely followed. An orientation was not recorded for non-linear scars, as identifying an overall orientation was not possible due to their appearance. Size was assessed via the scale marker at the top of every image. Scars ≤ 5 mm were classed as small, scars that were 6-9 mm were classed as medium, and scars ≥ 10 mm were classed as large. Scars larger than 20mm in length were classed as extra large. These size classifications were based on the range of scar sizes seen in the first 100 images analysed. Non-linear scars were measured at their widest point.

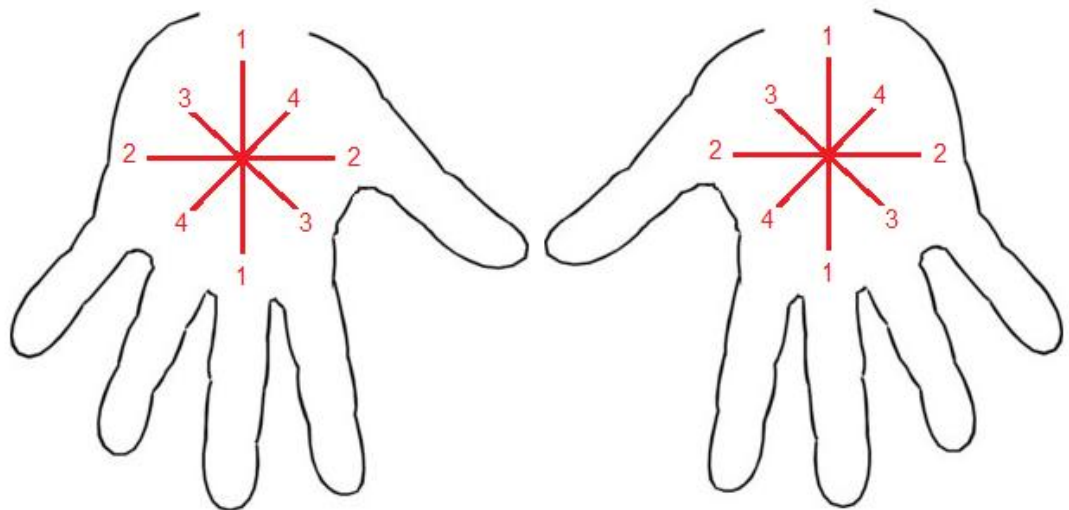


Figure 3.6. Scar Orientation

In cases where a scar crossed a gridline, the scar and its additional information on size, orientation, and type were recorded in the grid-cell in which the majority of the scar was located. Amputation was recorded according to which grid-cells were removed. For example if an amputation had been carried out at the proximal interphalangeal joint of the first finger, grid-cells 17 and 21 were both recorded as amputated.

3.5 Data Recording

Data from the left and right hands were recorded in worksheets created in Microsoft Excel, with one worksheet used for each participant ($n=260$). Each worksheet was titled with the same number as the image to which it applied. Each hand had two tables of information associated with it, one for epheides, lentigines, nevi, tattoos, amputations and hypopigmentation, and one for scar information. Data was recorded for each grid-cell individually.

Ephelides, lentigines, nevi, tattoos, amputations, and hypopigmentation were recorded numerically. Scar type was recorded as L (linear) or NL (non-linear) and size was recorded as small (S), medium (M), large (L), or extra large (XL). Orientation was recorded as 1, 2, 3, or 4. Finally, additional characteristics were recorded under the headings irregular, surgical, degloving, keloid and hypertrophic. Degloving scars were only recorded in one individual and were recorded due to the fact that their consent form stated that this was the nature of this particular injury, and the physical appearance of this scarring made it impossible to categorise under any of the other scar categories.

Irregular scar appearance was characterised by linear scars that were angled or curvilinear, or that divided into multiple scars. Examples of irregular scarring are shown in Figure 7.21, Appendix A. An example of degloving injury scarring is also shown in Figure 7.22, Appendix A.

Dermatological conditions were recorded in a single column in the recording sheets, labelled as "Dermatological conditions". The name of the particular condition was then recorded in the "Notes" column.

An example of the features part of the recording form is shown in Table 3.6, showing the first three lines of the table. In this example, there were 12 freckles in grid-cell 1, 4 freckles in grid-cell 2, and 2 freckles in grid-cell 3. There was 1 mole in grid-cell 2. There was a dermatological condition in grid-cell 3, which was identified as dermatitis.

Table.3.6. Feature Recording Form

Grid ref	Freckles	Moles	Liver spots	Dermatological condition	Tattoo	Knuckle pads and calluses	Amputation	Piercing	Notes
1	12								
2	4	1							
3	2			1					dermatitis

In the example of the scars section of the recording form, shown in Table 3.7, grid-cell 2 has two scars contained within it. The first scar is linear, small in size, has an orientation of 2 and has a hypertrophic appearance. The second scar is linear, large in size and has an orientation of 4. In grid-cell 3, there is a medium sized non-linear scar.

Table.3.7. Scar Recording Form

	Scar			Linear or non-linear			Scar size			Scar orientation			Additional			
	1	2	3	1	2	3	1	2	3	1	2	3	1	2	3	
1																
2	X	X		L	L		S	L		2	4		hypertrophic			
3	X			NL			M									

3.6 Statistical Analysis

Prior to statistical analysis, demographic data was gathered on each participant from consent forms completed at the time of image acquisition. Information on age, sex, and handedness was collected. This information allowed the sample to be organised into

cohorts depending on sex, age group, and handedness, enabling more detailed statistical analysis to be performed.

Basic descriptive statistics were applied to all of the data in order to determine means, medians, modes, maximum and minimum values, ranges, and standard deviations. Non-parametric ANOVA (Holm-Sidak and Tukey tests) was also performed in order to identify significant variation between cohorts. These statistical tests were applied to the whole data collection and also specific groups by age, sex, and handedness.

The grid-cells that subdivided the hand were not all of an equal surface area. During analysis, this was identified as a possible cause of some unexpected results. In order to assess how the differences in surface area affected quantification of features, a study using normalised data was carried out. The surface area of grid-cells 1, 7, 12, 17 and 21 were measured in a sample of ten random hands using Adobe Photoshop. This allowed the relative differences between the surface areas of these grid-cells to be calculated. For each hand, the surface area of each grid-cell compared to the smallest grid-cell was calculated as a ratio. For example, if grid-cell 1 was 2cm^2 , a grid-cell of 4cm^2 the ratio of this grid-cell would be 2. Therefore, the number of ephelides observed inside this larger grid-cell would be divided by 2 to give a normalised value to reflect the likely number of ephelides if both of these grid-cells had been of an equal surface area. This was carried out for each of the ten random hands selected, allowing comparison between the original data and the normalised data to be carried out using ANOVA.

3.7 Analysis of Intra- and Inter-Observer Error

In order to assess intra- and inter-observer error, a subset of images was selected at random from the database of images. This subset was composed of six individual hands, (3 left hands and 3 right hands). These images had already been landmarked by the author during the original study and so already had the grid applied.

Three observers then quantified the features seen in each of these six hand images, and repeated this process a further five times. This gave six repeated observations for each of the six images, by three different observers. The author (observer 1) possessed an undergraduate degree in Forensic Anthropology and had been analysing hand images for a period of approximately three months and observer 2 was a recent graduate in Forensic Anthropology. Observer 3 was a teaching lecturer in Forensic Anthropology with extensive experience in the analysis of this region of the body.

Chapter 4 : Results and Discussion

Due to the extensive amount of data involved in the multiple comparison of grid-cells, the mean values of each individual grid-cell in the left and right hands of the sex, hand dominance and age groups can be found in Appendix B.

Results

4.1 Sex Differences

4.1.1 Female Left Hands (n=61) – Multiple Comparison of Grid-cells

The only variable that differed significantly between grid-cells in female left hands was ephelides. For the purpose of clarity, figures accompany the paragraphs in sections referring to multiple comparison of grid-cells. In these figures, red boxes identify grid-cells that were significantly different from the grid-cell marked by a yellow circle. Grid-cells that were not significantly different from the grid-cell marked by the yellow circle are marked with a yellow square.

Grid-cell 1

Grid-cell 1 was not significantly different in terms of mean values to grid-cells 2-4, 6-9 and 11-14.

Grid-cells 5, 10 and 15-24 were significantly different from grid-cell 1 in terms of mean values.




Figure 4.1. Female Left Hands: Grid-cell 1 Multiple Comparisons

The accompanying data illustrating the patterns of variation in grid-cells 2-24 in detail are shown in Appendix C.

In summary, the dorsum of the hand generally behaved uniformly in female left hands, with few significant differences seen between grid-cells in the hand dorsum. Most significant differences were seen between the dorsum of the hand and the digits. A correlation matrix is shown below (Table 4.1), with cells highlighted red identifying the grid-cells that were significantly different to each other in female left hands.

Table 4.1. Female Left Hands Correlation Matrix

	1	2	3	4	5	6	7	8	9	10	11	12	13	14	15	16	17	18	19	20	21	22	23	24		
1	1																									
2		1																								
3			1																							
4				1																						
5					1																					
6						1																				
7							1																			
8								1																		
9									1																	
10										1																
11											1															
12												1														
13													1													
14														1												
15															1											
16																1										
17																	1									
18																		1								
19																			1							
20																				1						
21																					1					
22																						1				
23																							1			
24																								1		

4.1.3 Female Left Hands (n=61) vs Female Right Hands (n=61)

Ephelides

There were significant differences between female left and right hands with regards to the number of ephelides observed in grid-cells 3 and 7.

Table 4.3. Female Left Hands vs Female Right Hands: Ephelides

Grid-cell	Left Hand Mean	Left Hand Total Count	Right Hand Mean	Right Hand Total Count	Difference in Means	t-value	p-value
3	4.57	279	7.52	459	2.95	5.46	<0.001
7	3.03	185	4.48	273	1.45	2.67	<0.01

Lentigines

There were significant differences between female left and right hands with regards to the number of lentigines observed in grid-cells 3, 7, 8 and 9.

Table 4.4. Female Left Hands vs Female Right Hands: Lentigines

Grid-cell	Left Hand Mean	Left Hand Total Count	Right Hand Mean	Right Hand Total Count	Difference in Means	t-value	p-value
3	0.23	14	0.34	21	0.11	3.37	<0.001
7	0.02	1	0.10	6	0.08	2.41	<0.05
8	0.13	8	0.05	3	0.08	2.41	<0.05
9	0.11	7	0.03	2	0.08	2.41	<0.05

Linear Scars

There were significant differences between female left and right hands with regards to the number of linear scars observed in grid-cells 7, 9 and 17.

Table 4.5. Female Left Hands vs Female Right Hands: Linear Scars

Grid-cell	Left Hand Mean	Left Hand Total Count	Right Hand Mean	Right Hand Total Count	Difference in Means	t-value	p-value
7	0.05	3	0.16	10	0.11	2.49	<0.05
9	0.02	1	0.11	7	0.09	2.13	<0.05
17	0.03	2	0.16	10	0.13	2.84	<0.01

Non-Linear Scars

There were significant differences between female left and right hands with regards to the number of non-linear scars observed in grid-cells 7, 9 and 17.

Table 4.6. Female Left Hands vs Female Right Hands: Non-linear Scars

Grid-cell	Left Hand Mean	Left Hand Total Count	Right Hand Mean	Right Hand Total Count	Difference in Means	t-value	p-value
7	0.00	0	0.07	4	0.07	2.95	<0.01
9	0.08	5	0.02	1	0.06	2.95	<0.01
17	0.02	1	0.07	4	0.05	2.21	<0.05

Small Scars

There were significant differences between female left and right hands with regards to the number of small scars observed in grid-cells 7 and 17.

Table 4.7. Female Left Hands vs Female Right Hands: Small Scars

Grid-cell	Left Hand Mean	Left Hand Total Count	Right Hand Mean	Right Hand Total Count	Difference in Means	t-value	p-value
7	0.02	1	0.16	10	0.14	0.15	<0.001
17	0.03	2	0.15	9	0.12	2.96	<0.01

Medium Scars

There were significant differences between males and females with regards to the number of medium scars observed in grid-cell 1.

Table 4.8. Female Left Hands vs Female Right Hands: Medium Scars

Grid-cell	Left Hand Mean	Left Hand Total Count	Right Hand Mean	Right Hand Total Count	Difference in Means	t-value	p-value
1	0.00	0	0.05	3	0.05	2.29	<0.05

Orientation 1 Scars

There were significant differences between males and females with regards to the number of orientation 1 scars observed in grid-cell 17.

Table 4.9. Female Left Hands vs Female Right Hands: Orientation 1 Scars

Grid-cell	Left Hand Mean	Left Hand Total Count	Right Hand Mean	Right Hand Total Count	Difference in Means	t-value	p-value
17	0.02	1	0.07	4	0.05	2.14	<0.05

Orientation 3 Scars

There were significant differences between males and females with regards to the number of orientation 3 scars observed in grid-cell 17.

Table 4.10. Female Left Hands vs Female Right Hands: Orientation 3 Scars

Grid-cell	Left Hand Mean	Left Hand Total Count	Right Hand Mean	Right Hand Total Count	Difference in Means	t-value	p-value
17	0.00	0	0.05	3	0.05	2.75	<0.01

In summary, epheles were observed in significantly greater numbers in female right hands than left hands in grid-cells 3 and 7. Lentigines did not show a clear pattern, with significantly greater numbers seen in the right hands in grid-cells 3 and 7, but significantly greater numbers in the left hands in grid-cells 8 and 9.

Female right hands possessed a significantly greater number of scars than female left hands in grid-cells 1, 7 and 17, which are all located on the lateral region of the hand. The left hands possessed a significantly greater number of non-linear scars in grid-cell 9, while the right hands possessed a significantly greater number of linear scars in grid-cell 9.

4.1.6 Male Left Hands (n=177) vs Male Right Hands (n=177)

Ephelides

There were significant differences between males and females with regards to the number of ephelides observed in grid-cell 3.

Table 4.13. Male Left Hands vs Male Right Hands: Ephelides

Grid-cell	Left Hand Mean	Left Hand Total Count	Right Hand Mean	Right Hand Total Count	Difference in Means	t-value	p-value
3	5.28	934	6.61	1170	1.33	3.98	<0.001

Nevi

There were significant differences between males and females with regards to the number of nevi observed in grid-cell 3.

Table 4.14. Male Left Hands vs Male Right Hands: Nevi

Grid-cell	Left Hand Mean	Left Hand Total Count	Right Hand Mean	Right Hand Total Count	Difference in Means	t-value	p-value
3	0.01	1	0.02	3	0.01	2.31	<0.05

Lentigines

There were significant differences between males and females with regards to the number of lentigines observed in grid-cell 2.

Table 4.15. Male Left Hands vs Male Right Hands: Lentigines

Grid-cell	Left Hand Mean	Left Hand Total Count	Right Hand Mean	Right Hand Total Count	Difference in Means	t-value	p-value
2	0.02	4	0.13	23	0.11	5.10	<0.001

Knuckle Pads

There were significant differences between male left and right hands with regards to the number of knuckle pads observed in grid-cells 12 and 17.

Table 4.16. Male Left Hands vs Male Right Hands: Knuckle Pads

Grid-cell	Left Hand Mean	Left Hand Total Count	Right Hand Mean	Right Hand Total Count	Difference in Means	t-value	p-value
12	0.03	5	0.01	1	0.02	2.55	<0.05
17	0.04	7	0.02	3	0.02	2.55	<0.05

Linear Scars

There were significant differences between male left and right hands with regards to the number of linear scars observed in grid-cells 1, 7 and 17.

Table 4.17. Male Left Hands vs Male Right Hands: Linear Scars

Grid-cell	Left Hand Mean	Left Hand Total Count	Right Hand Mean	Right Hand Total Count	Difference in Means	t-value	p-value
1	0.11	20	0.02	4	0.09	2.77	<0.01
7	0.17	30	0.10	18	0.07	2.08	<0.05
17	0.19	34	0.10	17	0.09	2.94	<0.01

Non-Linear Scars

There were significant differences between male left and right hands with regards to the number of non-linear scars observed in grid-cells 1, 17 and 23.

Table 4.18. Male Left Hands vs Male Right Hands: Non-linear Scars

Grid-cell	Left Hand Mean	Left Hand Total Count	Right Hand Mean	Right Hand Total Count	Difference in Means	t-value	p-value
1	0.05	8	0.00	0	0.05	2.82	<0.01
17	0.03	2	0.06	11	0.03	3.18	<0.01
23	0.00	0	0.04	7	0.04	2.47	<0.05

Small Scars

There were significant differences between male left and right hands with regards to the number of small scars observed in grid-cells 7, 18 and 24.

Table 4.19. Male Left Hands vs Male Right Hands: Small Scars

Grid-cell	Left Hand Mean	Left Hand Total Count	Right Hand Mean	Right Hand Total Count	Difference in Means	t-value	p-value
7	0.08	15	0.02	4	0.06	2.19	<0.05
18	0.15	26	0.08	14	0.07	2.39	<0.05
24	0.07	12	0.01	2	0.06	1.99	<0.05

Medium Scars

There were significant differences between male left and right hands with regards to the number of medium scars observed in grid-cells 7 and 22.

Table 4.20. Male Left Hands vs Male Right Hands: Medium Scars

Grid-cell	Left Hand Mean	Left Hand Total Count	Right Hand Mean	Right Hand Total Count	Difference in Means	t-value	p-value
7	0.07	12	0.03	5	0.04	2.66	<0.01
22	0.03	6	0.00	0	0.03	2.28	<0.05

Orientation 2 Scars

There were significant differences between male left and right hands with regards to the number of orientation 2 scars observed in grid-cells 17 and 22.

Table 4.21. Male Left Hands vs Male Right Hands: Orientation 2 Scars

Grid-cell	Left Hand Mean	Left Hand Total Count	Right Hand Mean	Right Hand Total Count	Difference in Means	t-value	p-value
17	0.06	10	0.01	2	0.05	3.66	<0.001
22	0.03	5	0.00	0	0.03	2.29	<0.05

Orientation 3 Scars

There were significant differences between male left and right hands with regards to the number of orientation 3 scars observed in grid-cells 7, 9, 17 and 23.

Table 4.22. Male Left Hands vs Male Right Hands: Orientation 3

Grid-cell	Left Hand Mean	Left Hand Total Count	Right Hand Mean	Right Hand Total Count	Difference in Means	t-value	p-value
7	0.05	8	0.02	3	0.03	2.13	<0.05
9	0.03	5	0.06	11	0.03	2.55	<0.05
17	0.05	9	0.01	4	0.04	2.13	<0.05
23	0.03	5	0.00	0	0.03	2.13	<0.05

Orientation 4 Scars

There were significant differences between male left and right hands with regards to the number of orientation 4 scars observed in the grid-cells 1, 11 and 16.

Table 4.23. Male Left Hands vs Male Right Hands: Orientation 4 Scars

Grid-cell	Left Hand Mean	Left Hand Total Count	Right Hand Mean	Right Hand Total Count	Difference in Means	t-value	p-value
1	0.04	7	0.01	1	0.03	2.62	<0.01
11	0.05	9	0.01	2	0.04	3.06	<0.01
16	0.03	5	0.00	0	0.03	2.18	<0.05

In summary, epheles and nevi occurred significantly more often in grid-cell 3 in the male right hand than in the male left hand. Lentigines occurred significantly more often in the male right hand than in the male left hand in grid-cell 2. Overall, the left hands possessed significantly more scars than the right hands, and these scars were mostly seen down the lateral region of the hand, in the thumb and index finger.

4.1.7 Female Left Hands (n=61) vs Male Left Hands (n=177)

Ephelides

There were significant differences between males and females with regards to the number of ephelides observed in grid-cell 7.

Table 4.24. Female Left Hands vs Male Left Hands: Ephelides

Grid-cell	Female Mean	Female Total Count	Male Mean	Male Total Count	Difference in Means	t-value	p-value
7	3.03	185	4.02	713	1.0	2.27	<0.05

Nevi

There were significant differences between males and females with regards to the number of nevi observed in grid-cells 1, 2, 3 and 16.

Table 4.25. Female Left Hands vs Male Left Hands: Nevi

Grid-cell	Female Mean	Female Total Count	Male Mean	Male Total Count	Difference in Means	t-value	p-value
1	0.02	1	0.00	0	0.02	2.32	<0.05
2	0.02	1	0.00	0	0.02	2.32	<0.05
3	0.03	2	0.01	1	0.02	3.84	<0.001
16	0.02	1	0.00	0	0.02	2.32	<0.05

Lentigines

There were significant differences between males and females with regards to the number of lentigines observed in grid-cells 8 and 9.

Table 4.26. Female Left Hands vs Male Left Hands: Lentigines

Grid-cell	Female Mean	Female Total Count	Male Mean	Male Total Count	Difference in Means	t-value	p-value
8	0.13	8	0.03	6	0.10	3.47	<0.01
9	0.11	7	0.06	10	0.05	2.08	<0.05

Knuckle Pads

There were significant differences between males and females with regards to the number of knuckle pads observed in grid-cells 12, 17 and 18.

Table 4.27. Female Left Hands vs Male Left Hands: Knuckle Pads

Grid-cell	Female Mean	Female Total Count	Male Mean	Male Total Count	Difference in Means	t-value	p-value
12	0.00	0	0.03	5	0.03	2.60	<0.01
17	0.00	0	0.04	7	0.04	3.65	<0.001
18	0.00	0	0.03	5	0.03	2.60	<0.01

Linear Scars

There were significant differences between males and females with regards to the number of linear scars observed in grid-cells 1, 7, 12 and 17.

Table 4.28. Female Left Hands vs Male Left Hands: Linear Scars

Grid-cell	Female Mean	Female Total Count	Male Mean	Male Total Count	Difference in Means	t-value	p-value
1	0.02	1	0.11	20	0.09	2.07	<0.05
7	0.05	3	0.17	30	0.12	2.58	=0.01
12	0.03	2	0.15	26	0.12	2.45	<0.05
17	0.03	2	0.19	34	0.16	3.41	<0.001

Small Scars

There were significant differences between males and females with regards to the number of small scars observed in grid-cells 17 and 18.

Table 4.29. Female Left Hands vs Male Left Hands: Small Scars

Grid-cell	Female Mean	Female Total Count	Male Mean	Male Total Count	Difference in Means	t-value	p-value
17	0.03	2	0.15	27	0.12	2.95	<0.01
18	0.05	3	0.15	26	0.10	2.41	<0.05

Orientation 2 Scars

There were significant differences between males and females with regards to the number of orientation 2 scars observed in grid-cell 17.

Table 4.30. Female Left Hands vs Male Left Hands: Orientation 2 Scars

Grid-cell	Female Mean	Female Total Count	Male Mean	Male Total Count	Difference in Means	t-value	p-value
17	0.02	1	0.06	10	0.04	2.16	<0.05

Orientation 3 Scars

There were significant differences between males and females with regards to the number of orientation 3 scars in grid-cells 7, 12 and 17.

Table 4.31. Female Left Hands vs Male Left Hands: Orientation 3 Scars

Grid-cell	Female Mean	Female Total Count	Male Mean	Male Total Count	Difference in Means	t-value	p-value
7	0.00	0	0.05	8	0.05	2.49	<0.05
12	0.00	0	0.04	7	0.04	2.18	<0.05
17	0.00	0	0.05	9	0.05	2.80	<0.01

Orientation 4 Scars

There were significant differences between males and females with regards to the number of orientation 4 scars observed in grid-cell 1.

Table 4.32. Female Left Hands vs Male Left Hands: Orientation 4 Scars

Grid-cell	Female Mean	Female Total Count	Male Mean	Male Total Count	Difference in Means	t-value	p-value
1	0.00	0	0.04	7	0.04	2.02	<0.05

In summary, nevi and lentigines were seen in significantly greater numbers in the dorsal surface of the female left hands than the male left hands. Conversely, ephelides were significantly more common in grid-cell 7 in the male left hands.

Males possessed significantly more scars in their left hands than females. A majority of these significant differences were observed down the lateral border of the hand, in grid-cells 1, 7, 12, 17 and 18.

4.1.8 Female Right Hands (n=61) vs Male Right Hands (n=177)

Nevi

There were significant differences between males and females with regards to the number of nevi observed in grid-cells 2 and 7.

Table 4.33. Female Right Hands vs Male Right Hands: Nevi

Grid-cell	Female Mean	Female Total Count	Male Mean	Male Total Count	Difference in Means	t-value	p-value
2	0.03	2	0.00	0	0.03	3.35	<0.001
7	0.03	2	0.01	2	0.02	2.19	=0.05

Lentigines

There were significant differences between males and females with regards to the number of lentigines observed in grid-cells 2 and 3.

Table 4.34. Female Right Hands vs Male Right Hands: Lentigines

Grid-cell	Female Mean	Female Total Count	Male Mean	Male Total Count	Difference in Means	t-value	p-value
2	0.03	2	0.13	23	0.10	3.23	=0.001
3	0.34	21	0.17	30	0.17	5.81	<0.001

Non-linear Scars

There were significant differences between males and females with regards to the number of non-linear scars observed in grid-cell 7.

Table 4.35. Female Right Hands vs Male Right Hands: Non-linear Scars

Grid-cell	Female Mean	Female Total Count	Male Mean	Male Total Count	Difference in Means	t-value	p-value
7	0.07	4	0.01	1	0.06	2.86	<0.01

Small Scars

There were significant differences between males and females with regards to the number of small scars observed in grid-cell 7.

Table 4.36. Female Right Hands vs Male Right Hands: Small Scars

Grid-cell	Female Mean	Female Total Count	Male Mean	Male Total Count	Difference in Means	t-value	p-value
7	0.16	10	0.02	4	0.14	4.07	<0.001

Medium Scars

There were significant differences between males and females with regards to the number of medium scars observed in grid-cells 9 and 17.

Table 4.37. Female Right Hands vs Male Right Hands: Medium Scars

Grid-cell	Female Mean	Female Total Count	Male Mean	Male Total Count	Difference in Means	t-value	p-value
9	0.00	0	0.05	8	0.05	2.35	<0.05
17	0.05	3	0.01	2	0.04	1.97	<0.05

Orientation 1 Scars

There were significant differences between males and females with regards to the number of orientation 1 scars observed in grid-cell 17.

Table 4.38. Female Right Hands vs Male Right Hands: Orientation 1 Scars

Grid-cell	Female Mean	Female Total Count	Male Mean	Male Total Count	Difference in Means	t-value	p-value
17	0.07	4	0.02	4	0.05	2.15	<0.05

Irregular Scars

There were significant differences between males and females with regards to the number of irregular scars observed in grid-cells 7, 12 and 18.

Table 4.39. Female Right Hands vs Male Right Hands: Irregular Scars

Grid-cell	Female Mean	Female Total Count	Male Mean	Male Total Count	Difference in Means	t-value	p-value
7	0.02	1	0.00	0	0.02	2.32	<0.05
12	0.02	1	0.00	0	0.02	2.32	<0.05
18	0.03	2	0.01	1	0.02	3.84	<0.001

In summary, significantly more nevi were observed in grid-cells 2 and 7 in the female right hands than in the male right hands. Significantly more lentigines were observed in grid-cell 3 in female left hands, whereas significantly more lentigines were observed in grid-cell 2 in male left hands. Overall, females possessed significantly more scars than males in the lateral region of the right hand, in grid-cells 7, 12, 17 and 18.

4.2.5 Left-handed – Dominant Left Hands vs Non-dominant Right Hands

Lentigines

There were significant differences between dominant left hands and non-dominant right hands with regards to the number of lentigines observed in grid-cell 3.

Table 4.44. Dominant Left Hands vs Non-dominant Right Hands: Lentigines

Grid-cell	Left Hand Mean	Left Hand Total Count	Right Hand Mean	Right Hand Total Count	Difference in Means	t-value	p-value
3	0.00	0	0.12	3	0.12	4.97	<0.001

Linear Scars

There were significant differences between dominant left hands and non-dominant right hands with regards to the number of linear scars observed in grid-cell 21.

Table 4.45. Dominant Left Hands vs Non-dominant Right Hands: Linear Scars

Grid-cell	Left Hand Mean	Left Hand Total Count	Right Hand Mean	Right Hand Total Count	Difference in Means	t-value	p-value
21	0.00	0	0.15	4	0.15	2.10	<0.05

Small Scars

There were significant differences between dominant left hands and non-dominant right hands with regards to the number of small scars observed in grid-cells 2, 17, 18 and 21.

Table 4.46. Dominant Left Hands vs Non-dominant Right Hands: Small Scars

Grid-cell	Left Hand Mean	Left Hand Total Count	Right Hand Mean	Right Hand Total Count	Difference in Means	t-value	p-value
2	0.15	4	0.00	0	0.15	2.22	<0.05
17	0.00	0	0.15	4	0.15	2.22	<0.05
18	0.23	6	0.04	1	0.19	2.77	<0.01
21	0.00	0	0.19	5	0.19	2.77	<0.01

In summary, lentigines were significantly more common in grid-cell 3 in the non-dominant right hands than in the dominant left hands. Significantly more linear scars were observed in grid-cell 21 in non-dominant right hands than in the dominant left hands. Significantly more small scars were observed grid-cells 2 and 18 in dominant left hands than in the non-dominant right hands, whereas non-dominant right hands possessed significantly more small scars in grid-cells 17 and 21 than dominant left hands.

4.2.6 Right-handed – Non-dominant Left Hands vs Dominant Right Hands

Ephelides

There were significant differences between dominant right hands and non-dominant left hands with regards to the number of ephelides observed in grid-cells 3, 4 and 7.

Table 4.47. Non-dominant Left Hands vs Dominant Right Hands: Ephelides

Grid-cell	Left Hand Mean	Left Hand Total Count	Right Hand Mean	Right Hand Total Count	Difference in Means	t-value	p-value
3	4.98	1056	6.78	1438	1.80	6.34	<0.001
4	1.38	293	1.98	420	0.60	2.11	<0.05
7	3.73	791	4.31	914	0.60	2.04	<0.05

Lentigines

There were significant differences between dominant right hands and non-dominant left hands with regards to the number of lentigines observed in grid-cells 2, 4, 7 and 9.

Table 4.48. Non-dominant Left Hands vs Dominant Right Hands: Lentigines

Grid-cell	Left Hand Mean	Left Hand Total Count	Right Hand Mean	Right Hand Total Count	Difference in Means	t-value	p-value
2	0.03	6	0.11	24	0.08	4.25	<0.001
4	0.04	9	0.08	18	0.04	2.13	<0.05
7	0.02	4	0.07	14	0.05	2.36	<0.05
9	0.08	18	0.03	7	0.05	2.60	<0.01

Amputation

There were significant differences between dominant right hands and non-dominant left hands with regards to the number of amputations observed in grid-cell 22.

Table 4.49. Non-dominant Left Hands vs Dominant Right Hands: Amputations

Grid-cell	Left Hand Mean	Left Hand Total Count	Right Hand Mean	Right Hand Total Count	Difference in Means	t-value	p-value
22	0.0047	1	0.01	2	0.01	2.19	<0.05

Linear Scars

There were significant differences between dominant right hands and non-dominant left hands with regards to the number of linear scars observed in grid-cell 9.

Table 4.50. Non-dominant Left Hands vs Dominant Right Hands: Linear Scars

Grid-cell	Left Hand Mean	Left Hand Total Count	Right Hand Mean	Right Hand Total Count	Difference in Means	t-value	p-value
9	0.03	7	0.09	20	0.06	2.29	<0.05

Non-Linear Scars

There were significant differences between dominant right hands and non-dominant left hands with regards to the number of non-linear scars observed in grid-cells 1, 17, 22 and 23.

Table 4.51. Non-dominant Left Hands vs Dominant Right Hands: Non-linear Scars

Grid-cell	Left Hand Mean	Left Hand Total Count	Right Hand Mean	Right Hand Total Count	Difference in Means	t-value	p-value
1	0.04	8	0.00	0	0.04	2.76	<0.01
17	0.01	3	0.07	14	0.06	3.79	<0.001
22	0.0047	1	0.03	7	0.03	2.07	<0.05
23	0.00	0	0.03	7	0.03	2.41	<0.05

Medium Scars

There were significant differences between dominant right hands and non-dominant left hands with regards to the number of medium scars observed in grid-cells 3, 7 and 22.

Table 4.52. Non-dominant Left Hands vs Dominant Right Hands: Medium Scars

Grid-cell	Left Hand Mean	Left Hand Total Count	Right Hand Mean	Right Hand Total Count	Difference in Means	t-value	p-value
3	0.01	3	0.05	10	0.04	2.57	<0.05
7	0.06	12	0.02	5	0.04	2.57	<0.05
22	0.04	8	0.01	2	0.03	2.21	<0.05

Large Scars

There were significant differences between dominant right hands and non-dominant left hands with regards to the number of large scars observed in grid-cell 1.

Table 4.53. Non-dominant Left Hands vs Dominant Right Hands: Large Scars

Grid-cell	Left Hand Mean	Left Hand Total Count	Right Hand Mean	Right Hand Total Count	Difference in Means	t-value	p-value
1	0.02	5	0.005	1	0.02	2.56	<0.05

Orientation 2 Scars

There were significant differences between right-handed right hands (dominant) and right-handed left hands (non-dominant) with regards to the number of orientation 2 scars observed in grid-cells 17 and 22.

Table 4.54. Non-dominant Left Hands vs Dominant Right Hands: Orientation 2 Scars

Grid-cell	Left Hand Mean	Left Hand Total Count	Right Hand Mean	Right Hand Total Count	Difference in Means	t-value	p-value
17	0.05	11	0.02	4	0.03	3.03	<0.01
22	0.03	6	0.00	0	0.03	2.59	<0.05

Orientation 3 Scars

There were significant differences between dominant right hands and non-dominant left hands with regards to the number of orientation 3 scars observed in grid-cells 9 and 23.

Table 4.55. Non-dominant Left Hands vs Dominant Right Hands: Orientation 3 Scars

Grid-cell	Left Hand Mean	Left Hand Total Count	Right Hand Mean	Right Hand Total Count	Difference in Means	t-value	p-value
9	0.01	2	0.05	11	0.04	3.73	<0.001
23	0.02	5	0.00	0	0.02	2.07	<0.05

Orientation 4 Scars

There were significant differences between dominant right hands and non-dominant left hands with regards to the number of orientation 4 scars observed in grid-cells 2, 11 and 16.

Table 4.56. Non-dominant Left Hands vs Dominant Right Hands: Orientation 4 Scars

Grid-cell	Left Hand Mean	Left Hand Total Count	Right Hand Mean	Right Hand Total Count	Difference in Means	t-value	p-value
2	0.03	6	0.0047	1	0.03	2.15	<0.05
11	0.04	9	0.02	4	0.02	2.15	<0.05
16	0.03	6	0.00	0	0.03	2.58	<0.05

In summary, dominant right hands possessed significantly more ephelides and lentigines than non-dominant left hands. These significant differences were all seen in grid-cells located in the dorsum of the hand. Significant differences in scar numbers were seen in several grid-cells, with both the left and right hands possessing significantly more scars in different scar categories. Most of these significant differences were in the lateral border of the hand, including the index and middle fingers.

4.2.7 Dominant Left Hands vs Non-dominant Left Hands

Ephelides

There were significant differences between dominant and non-dominant left hands with regards to the number of ephelides observed in grid-cell 9.

Table 4.57. Dominant Left Hands vs Non-dominant Left Hands: Ephelides

Grid-cell	Right-handed Mean	Right-handed Total Count	Left-handed Mean	Left-handed Total Count	Difference in Means	t-value	p-value
9	2.58	548	4.08	106	1.50	2.43	<0.05

Lentigines

There were significant differences between dominant and non-dominant left hands with regards to the number of lentigines observed in grid-cells 3 and 9.

Table 4.58. Dominant Left Hands vs Non-dominant Left Hands: Lentigines

Grid-cell	Right-handed Mean	Right-handed Total Count	Left-handed Mean	Left-handed Total Count	Difference in Means	t-value	p-value
3	0.23	48	0.00	0	0.23	5.75	<0.001
9	0.08	18	0.00	0	0.08	2.16	<0.05

Knuckle pads

There were significant differences between dominant and non-dominant left hands with regards to the number of knuckle pads observed in grid-cells 12, 13, 17 and 18.

Table 4.59. Dominant Left Hands vs Non-dominant Left Hands: Knuckle Pads

Grid-cell	Right-handed Mean	Right-handed Total Count	Left-handed Mean	Left-handed Total Count	Difference in Means	t-value	p-value
12	0.01	3	0.08	2	0.07	4.15	<0.001
13	0.00	0	0.08	2	0.08	5.08	<0.001
17	0.02	5	0.08	2	0.06	3.52	<0.001
18	0.01	3	0.08	2	0.07	4.15	<0.001

Linear Scars

There were significant differences between dominant and non-dominant left hands with regards to the number of linear scars observed in grid-cells 9 and 17.

Table 4.60. Dominant Left Hands vs Non-dominant Left Hands: Linear Scars

Grid-cell	Right-handed Mean	Right-handed Total Count	Left-handed Mean	Left-handed Total Count	Difference in Means	t-value	p-value
9	0.03	7	0.23	6	0.20	3.49	<0.001
17	0.17	36	0.00	0	0.17	2.67	<0.01

Non-Linear Scars

There were significant differences between dominant and non-dominant left hands with regards to the number of non-linear scars observed in grid-cells 2, 8, 9, 18 and 22.

Table 4.61. Dominant Left Hands vs Non-dominant Left Hands: Non-linear Scars

Grid-cell	Right-handed Mean	Right-handed Total Count	Left-handed Mean	Left-handed Total Count	Difference in Means	t-value	p-value
2	0.01	212	0.08	2	0.07	2.22	<0.05
8	0.01	2	0.08	2	0.07	2.22	<0.05
9	0.03	7	0.12	3	0.09	2.71	<0.01
18	0.02	5	0.12	3	0.10	3.02	<0.01
22	0.00	1	0.08	2	0.08	2.38	<0.05

Small Scars

There were significant differences between dominant and non-dominant left hands with regards to the number of small scars observed in grid-cells 2, 9, 17 and 18.

Table 4.62. Dominant Left Hands vs Non-dominant Left Hands: Small Scars

Grid-cell	Right-handed Mean	Right-handed Total Count	Left-handed Mean	Left-handed Total Count	Difference in Means	t-value	p-value
2	0.02	5	0.15	4	0.13	2.30	<0.05
9	0.05	11	0.27	7	0.22	3.84	<0.001
17	0.14	29	0.00	0	0.14	2.42	<0.05
18	0.11	23	0.23	6	0.12	2.16	<0.05

Medium Scars

There were significant differences between dominant and non-dominant left hands with regards to the number of medium scars observed in grid-cells 9 and 15.

Table 4.63. Dominant Left Hands vs Non-dominant Left Hands: Medium Scars

Grid-cell	Right-handed Mean	Right-handed Total Count	Left-handed Mean	Left-handed Total Count	Difference in Means	t-value	p-value
9	0.01	3	0.08	2	0.07	2.17	<0.05
15	0.02	4	0.08	2	0.06	2.01	<0.05

Large Scars

There were significant differences between dominant and non-dominant left hands with regards to the number of large scars observed in grid-cells 1 and 10.

Table 4.64. Dominant Left Hands vs Non-dominant Left Hands: Large Scars

Grid-cell	Right-handed Mean	Right-handed Total Count	Left-handed Mean	Left-handed Total Count	Difference in Means	t-value	p-value
1	0.02	5	0.08	2	0.06	3.08	<0.01
10	0.00	0	0.04	1	0.04	2.22	<0.05

Orientation 3 Scars

There were significant differences between dominant and non-dominant left hands with regards to the number of orientation 3 scars observed in grid-cell 9.

Table 4.65. Dominant Left Hands vs Non-dominant Left Hands: Orientation 3 Scars

Grid-cell	Right-handed Mean	Right-handed Total Count	Left-handed Mean	Left-handed Total Count	Difference in Means	t-value	p-value
9	0.01	2	0.12	3	0.11	4.17	<0.001

In summary, dominant left hands possessed significantly more epheles than non-dominant left hands in grid-cell 9. Non-dominant left hands possessed significantly more lentiginos than dominant left hands in grid-cells 3 and 9. Knuckle pads were significantly more common in the index and middle fingers in dominant left hands than in non-dominant left hands. Overall, scars were significantly more common in the dominant left hands than in the non-dominant left hands. The grid-cells containing these significant differences did not appear to be localised to one region, with some being located on the lateral part of the hand and some on the medial part of the hand.

4.2.8 Dominant Right Hands vs Non-dominant Right Hands

Ephelides

There were significant differences between dominant and non-dominant right hands with regards to the number of ephelides observed in grid-cells 8 and 9.

Table 4.66. Dominant Right Hands vs Non-dominant Right Hands: Ephelides

Grid-cell	Right-handed Mean	Right-handed Total Count	Left-handed Mean	Left-handed Total Count	Difference in Means	t-value	p-value
8	3.23	685	4.96	129	1.73	2.56	<0.05
9	3.05	646	4.50	117	1.45	2.15	<0.05

Lentigines

There were significant differences between dominant and non-dominant right hands with regards to the number of lentigines observed in grid-cells 3 and 4.

Table 4.67. Dominant Right Hands vs Non-dominant Right Hands: Lentigines

Grid-cell	Right-handed Mean	Right-handed Total Count	Left-handed Mean	Left-handed Total Count	Difference in Means	t-value	p-value
3	0.22	47	0.12	3	0.10	2.52	<0.05
4	0.08	18	0.00	0	0.08	2.02	<0.05

Small Scars

There were significant differences between dominant and non-dominant right hands with regards to the number of small scars observed in grid-cell 21.

Table 4.68. Dominant Right Hands vs Non-dominant Right Hands: Small Scars

Grid-cell	Right-handed Mean	Right-handed Total Count	Left-handed Mean	Left-handed Total Count	Difference in Means	t-value	p-value
21	0.07	15	0.19	5	0.12	2.51	<0.05

Medium Scars

There were significant differences between dominant and non-dominant right hands with regards to the number of medium scars observed in grid-cells 1 and 7.

Table 4.69. Dominant Right Hands vs Non-dominant Right Hands: Medium Scars

Grid-cell	Right-handed Mean	Right-handed Total Count	Left-handed Mean	Left-handed Total Count	Difference in Means	t-value	p-value
1	0.02	4	0.12	3	0.10	3.62	<0.001
7	0.02	5	0.08	2	0.06	2.00	<0.05

Large Scars

There were significant differences between dominant and non-dominant right hands with regards to the number of large scars observed in grid-cells 3 and 9.

Table 4.70. Dominant Right Hands vs Non-dominant Right Hands: Large Scars

Grid-cell	Right-handed Mean	Right-handed Total Count	Left-handed Mean	Left-handed Total Count	Difference in Means	t-value	p-value
3	0.01	2	0.08	2	0.07	4.43	<0.001
9	0.005	1	0.04	1	0.04	2.21	<0.05

In summary, non-dominant right hands possessed significantly more ephelides in grid-cells 8 and 9 than dominant right hands. Dominant right hands possessed significantly more lentiginos in grid-cells 3 and 4 than non-dominant right hands. Small and medium scars were found to be significantly more common in the lateral region of non-dominant right hands than dominant right hands. Large scars were significantly more common in grid-cells 3 and 9 in the non-dominant right hands than in the dominant right hands.

4.3 Age Differences

Due to the biased nature of the age groups analysed (illustrated previously in Table 3.2), only a general summary is provided here with regards to the significant observations seen in these groups. Age groups 30-39 and 40-49 are highlighted in bold as their larger sample sizes may allow for more reliable statistical interpretation.

4.3.1 Multiple Comparison of Grid-cells by Age Groups: Left Hands

Ephelides, nevi, lentigines, linear scars, non-linear scars, small scars, medium scars, large scars, orientation 1 scars, orientation 4 scars and irregular scars displayed significant variation in the left hands of several age groups. These results are shown in Tables 4.71 to 4.96.

Ephelides

Table 4.71. Grid-cell 1 Multiple Comparisons of Ephelide Numbers

Comparison	Diff of Means	t	p-value	p<0.05
50-59 vs. 30-39	3.41	5.18	<0.001	Yes
50-59 vs. 40-49	2.35	4.02	<0.001	Yes

Table 4.72. Grid-cell 2 Multiple Comparisons of Ephelide Numbers

Comparison	Diff of Means	t	p-value	p<0.05
50-59 vs. 30-39	2.83	4.30	<0.001	Yes
40-49 vs. 30-39	1.29	2.79	<0.05	Yes

Table 4.73. Grid-cell 3 Multiple Comparisons of Ephelide Numbers

Comparison	Diff of Means	t	p-value	p<0.05
50-59 vs. 30-39	7.75	11.76	<0.001	Yes
50-59 vs. 40-49	5.67	9.69	<0.001	Yes
50-59 vs. 60-69	7.16	4.70	<0.001	Yes
40-49 vs. 30-39	2.09	4.51	<0.001	Yes
20-29 vs. 30-39	4.84	3.93	<0.001	Yes

Table 4.74. Grid- cell 4 Multiple Comparisons of Ephelide Numbers

Comparison	Diff of Means	t	p-value	p<0.05
50-59 vs. 40-49	2.80	4.80	<0.001	Yes
50-59 vs. 30-39	2.98	4.51	<0.001	Yes

Table 4.75. Grid-cell 7 Multiple Comparisons of Ephelide Numbers

Comparison	Diff of Means	t	p-value	p<0.05
50-59 vs. 30-39	6.06	9.18	<0.001	Yes
50-59 vs. 40-49	4.46	7.63	<0.001	Yes
50-59 vs. 20-29	6.50	5.08	<0.001	Yes
40-49 vs. 30-39	1.60	3.45	<0.01	Yes
50-59 vs. 60-69	5.25	3.45	<0.01	Yes

Table 4.76. Grid-cell 8 Multiple Comparisons of Ephelide Numbers

Comparison	Diff of Means	t	p-value	p<0.05
50-59 vs. 30-39	5.37	8.14	<0.001	Yes
50-59 vs. 40-49	4.12	7.05	<0.001	Yes
50-59 vs. 20-29	5.36	4.19	<0.001	Yes
50-59 vs. 60-69	6.36	4.18	<0.001	Yes
40-49 vs. 30-39	1.25	2.70	<0.05	Yes

Table 4.77. Grid-cell 9 Multiple Comparisons of Ephelide Numbers

Comparison	Diff of Means	t	p-value	p<0.05
50-59 vs. 30-39	3.80	5.76	<0.001	Yes
50-59 vs. 40-49	2.40	4.10	<0.001	Yes
40-49 vs. 30-39	1.40	3.03	<0.05	Yes
50-59 vs. 20-29	3.47	2.71	<0.05	Yes

Nevi

Table 4.78. Grid-cell 3 Multiple Comparisons of Nevi Numbers

Comparison	Diff of Means	t	p-value	p<0.05
60-69 vs. 30-39	0.25	10.55	<0.001	Yes
60-69 vs. 40-49	0.24	10.46	<0.001	Yes
60-69 vs. 50-59	0.25	10.25	<0.001	Yes
60-69 vs. 20-29	0.25	8.47	<0.001	Yes

Table 4.79. Grid-cell 11 Multiple Comparisons of Nevi Numbers

Comparison	Diff of Means	t	p-value	p<0.05
20-29 vs. 30-39	0.17	8.46	<0.001	Yes
20-29 vs. 40-49	0.16	8.35	<0.001	Yes
20-29 vs. 50-59	0.17	8.13	<0.001	Yes
20-29 vs. 60-69	0.17	5.65	<0.001	Yes

Table 4.80. Grid-cell 14 Multiple Comparisons of Nevi Numbers

Comparison	Diff of Means	t	p-value	p<0.05
20-29 vs. 40-49	0.17	8.74	<0.001	Yes
20-29 vs. 30-39	0.17	8.46	<0.001	Yes
20-29 vs. 50-59	0.13	6.45	<0.001	Yes
20-29 vs. 60-69	0.17	5.65	<0.001	Yes
50-59 vs. 40-49	0.035	3.69	=0.001	Yes
50-59 vs. 30-39	0.035	3.27	<0.01	Yes

Table 4.81. Grid-cell 16 Multiple Comparisons of Nevi Numbers

Comparison	Diff of Means	t	p-value	p<0.05
20-29 vs. 40-49	0.17	8.74	<0.001	Yes
20-29 vs. 30-39	0.17	8.46	<0.001	Yes
20-29 vs. 50-59	0.17	8.13	<0.001	Yes
20-29 vs. 60-69	0.17	5.65	<0.001	Yes

Lentiginos

Table 4.82. Grid-cell 3 Multiple Comparisons of Lentigine Numbers

Comparison	Diff of Means	t	p-value	p<0.05
60-69 vs. 30-39	1.25	12.83	<0.001	Yes
50-59 vs. 30-39	0.52	11.92	<0.001	Yes
60-69 vs. 40-49	1.05	11.02	<0.001	Yes
60-69 vs. 20-29	1.25	10.31	<0.001	Yes
50-59 vs. 40-49	0.32	8.25	<0.001	Yes
60-69 vs. 50-59	0.73	7.31	<0.001	Yes
40-49 vs. 30-39	0.20	6.57	<0.001	Yes
50-59 vs. 20-29	0.52	6.14	<0.001	Yes
40-49 vs. 20-29	0.20	2.55	<0.05	Yes

Linear scars

Table 4.83. Grid-cell 21 Multiple Comparisons of Linear Scar Numbers

Comparison	Diff of Means	t	p-value	p<0.05
50-59 vs. 40-49	0.22	3.84	=0.001	Yes

Table 4.84. Grid-cell 22 Multiple Comparisons of Linear Scar Numbers

Comparison	Diff of Means	t	p-value	p<0.05
50-59 vs. 40-49	0.18	3.07	<0.05	Yes
50-59 vs. 30-39	0.19	2.87	<0.05	Yes

Small scars

Table 4.85. Grid-cell 9 Multiple Comparisons of Small Scar Numbers

Comparison	Diff of Means	t	p-value	p<0.05
30-39 vs. 40-49	0.16	3.65	<0.01	Yes

Table 4.86. Grid-cell 11 Multiple Comparisons of Small Scar Numbers

Comparison	Diff of Means	t	p-value	p<0.05
50-59 vs. 40-49	0.20	3.54	<0.01	Yes
50-59 vs. 30-39	0.19	2.96	<0.05	Yes

Table 4.87. Grid-cell 12 Multiple Comparisons of Small Scar Numbers

Comparison	Diff of Means	t	p-value	p<0.05
30-39 vs. 40-49	0.14	3.23	<0.05	Yes

Table 4.88. Grid-cell 21 Multiple Comparisons of Small Scar Numbers

Comparison	Diff of Means	t	p-value	p<0.05
50-59 vs. 40-49	0.19	3.41	<0.01	Yes

Medium scars

Table 4.89. Grid-cell 7 Multiple Comparisons of Medium Scar Numbers

Comparison	Diff of Means	t	p-value	p<0.05
50-59 vs. 40-49	0.10	3.49	<0.01	Yes

Table 4.90. Grid-cell 15 Multiple Comparisons of Medium Scar Numbers

Comparison	Diff of Means	t	p-value	p<0.05
60-69 vs. 30-39	0.25	3.41	<0.01	Yes
60-69 vs. 50-59	0.25	3.32	<0.01	Yes
60-69 vs. 40-49	0.21	2.97	<0.05	Yes
60-69 vs. 20-29	0.25	2.74	<0.05	Yes

Table 4.91. Grid-cell 22 Multiple Comparisons of Medium Scar Numbers

Comparison	Diff of Means	t	p-value	p<0.05
50-59 vs. 40-49	0.11	3.74	<0.01	Yes
50-59 vs. 30-39	0.12	3.65	<0.01	Yes

Orientation 1 scars

Table 4.92. Grid-cell 7 Multiple Comparisons of Orientation 1 Scar Numbers

Comparison	Diff of Means	t	p-value	p<0.05
50-59 vs. 40-49	0.10	3.48	<0.01	Yes
50-59 vs. 30-39	0.10	3.07	<0.05	Yes

Table 4.93. Grid-cell 21 Multiple Comparisons of Orientation 1 Scar Numbers

Comparison	Diff of Means	t	p-value	p<0.05
50-59 vs. 40-49	0.14	4.76	<0.001	Yes

Table 4.94. Grid-cell 22 Multiple Comparisons of Orientation 1 Scar Numbers

Comparison	Diff of Means	t	p-value	p<0.05
50-59 vs. 30-39	0.10	3.17	<0.05	Yes
50-59 vs. 40-49	0.089	3.06	<0.05	Yes

Orientation 4

Table 4.95. Grid-cell 11 Multiple Comparisons of Orientation 4 Scar Numbers

Comparison	Diff of Means	t	p-value	p<0.05
50-59 vs. 40-49	0.15	5.51	<0.001	Yes
50-59 vs. 30-39	0.14	4.38	<0.001	Yes
50-59 vs. 20-29	0.17	2.89	<0.05	Yes

Table 4.96. Grid-cell 17 Multiple Comparisons of Orientation 4 Scar Numbers

Comparison	Diff of Means	t	p-value	p<0.05
50-59 vs. 40-49	0.089	3.25	<0.05	Yes

4.3.2 Multiple Comparison of Grid-cells by Age Groups: Right Hands

Ephelides, lentigines, linear scars, non-linear scars, small scars, medium scars, large scars, orientation 1 scars and irregular scars displayed significant variation in the right hands of several age groups. These results are shown in Tables 4.97 to 4.126.

Ephelides

Table 4.97. Grid-cell 2 Multiple Comparisons of Ephelide Numbers

Comparison	Diff of Means	t	p-value
50-59 vs. 30-39	3.14	4.29	<0.001

Table 4.98. Grid-cell 3 Multiple Comparisons of Ephelide Numbers

Comparison	Diff of Means	t	p-value
50-59 vs. 30-39	7.30	9.96	<0.001
50-59 vs. 40-49	5.06	7.79	<0.001
60-69 vs. 30-39	7.22	4.39	<0.001
40-49 vs. 30-39	2.24	4.36	<0.001
50-59 vs. 20-29	4.92	3.46	<0.01
60-69 vs. 40-49	4.97	3.09	=0.01

Table 4.99. Grid-cell 4 Multiple Comparisons of Ephelide Numbers

Comparison	Diff of Means	t	p-value
50-59 vs. 30-39	2.78	3.79	<0.01
50-59 vs. 40-49	2.41	3.71	<0.01

Table 4.100. Grid-cell 7 Multiple Comparisons of Ephelide Numbers

Comparison	Diff of Means	t	p-value
50-59 vs. 30-39	6.89	9.39	<0.001
50-59 vs. 40-49	5.23	8.05	<0.001
50-59 vs. 60-69	6.91	4.09	<0.001
40-49 vs. 30-39	1.66	3.22	<0.01
20-29 vs. 30-39	4.31	3.15	=0.01

Table 4.101. Grid-cell 8 Multiple Comparisons of Ephelide Numbers

Comparison	Diff of Means	t	p-value
50-59 vs. 30-39	5.31	7.24	<0.001
50-59 vs. 40-49	4.27	6.58	<0.001
50-59 vs. 60-69	6.35	3.75	=0.001

Table 4.102. Grid-cell 9 Multiple Comparisons of Ephelide Numbers

Comparison	Diff of Means	t	p-value
50-59 vs. 30-39	4.93	6.73	<0.001
50-59 vs. 40-49	2.97	4.57	<0.001
40-49 vs. 30-39	1.96	3.82	=0.001

Lentiginos

Table 4.103. Grid-cell 2 Multiple Comparisons of Lentigine Numbers

Comparison	Diff of Means	t	p-value
50-59 vs. 30-39	0.38	8.09	<0.001
50-59 vs. 40-49	0.28	6.81	<0.001
50-59 vs. 20-29	0.38	4.17	<0.001
40-49 vs. 30-39	0.096	2.93	<0.05

Table 4.104. Grid-cell 3 Multiple Comparisons of Lentigine Numbers

Comparison	Diff of Means	t	p-value
60-69 vs. 30-39	0.85	8.07	<0.001
60-69 vs. 50-59	0.86	7.96	<0.001
60-69 vs. 40-49	0.76	7.34	<0.001
60-69 vs. 20-29	0.83	6.36	<0.001
40-49 vs. 30-39	0.09	2.84	<0.05

Table 4.105. Grid-cell 4 Multiple Comparisons of Lentigine Numbers

Comparison	Diff of Means	t	p-value
50-59 vs. 30-39	0.15	3.27	<0.05

Table 4.106. Grid-cell 8 Multiple Comparisons of Lentigine Numbers

Comparison	Diff of Means	t	p-value
50-59 vs. 30-39	0.14	2.94	<0.05

Linear Scars

Table 4.107. Grid-cell 1 Multiple Comparisons of Linear Scar Numbers

Comparison	Diff of Means	t	p-value
60-69 vs. 40-49	0.48	3.92	<0.001
60-69 vs. 50-59	0.47	3.63	<0.01
60-69 vs. 30-39	0.44	3.56	<0.01
60-69 vs. 20-29	0.50	3.22	<0.01

Table 4.108. Grid-cell 3 Multiple Comparisons of Linear Scar Numbers

Comparison	Diff of Means	t	p-value
60-69 vs. 40-49	0.43	3.55	<0.01
60-69 vs. 30-39	0.43	3.40	<0.01
60-69 vs. 50-59	0.43	3.36	<0.01
60-69 vs. 20-29	0.50	3.22	<0.01

Table 4.109. Grid-cell 21 Multiple Comparisons of Linear Scar Numbers

Comparison	Diff of Means	t	p-value
20-29 vs. 50-59	0.33	3.09	<0.05

Non-linear Scars

Table 4.110. Grid-cell 7 Multiple Comparisons of Non-linear Scar Numbers

Comparison	Diff of Means	t	p-value
60-69 vs. 40-49	0.49	6.79	<0.001
60-69 vs. 50-59	0.50	6.55	<0.001
60-69 vs. 30-39	0.46	6.23	<0.001
60-69 vs. 20-29	0.50	5.42	<0.001

Table 4.111. Grid-cell 9 Multiple Comparisons of Non-linear Scar Numbers

Comparison	Diff of Means	t	p-value
60-69 vs. 40-49	0.21	2.93	<0.05
60-69 vs. 50-59	0.22	2.83	<0.05

Small Scars

Table 4.112. Grid-cell 7 Multiple Comparisons of Small Scar Numbers

Comparison	Diff of Means	t	p-value
60-69 vs. 40-49	0.72	5.98	<0.001
60-69 vs. 50-59	0.72	5.65	<0.001
60-69 vs. 30-39	0.66	5.33	<0.001
60-69 vs. 20-29	0.58	3.81	<0.001

Table 4.113. Grid-cell 21 Multiple Comparisons of Small Scar Numbers

Comparison	Diff of Means	t	p-value
20-29 vs. 50-59	0.33	3.13	<0.05

Medium Scars

Table 4.114. Grid-cell 1 Multiple Comparisons of Medium Scar Numbers

Comparison	Diff of Means	t	p-value
60-69 vs. 40-49	0.24	3.60	<0.01
60-69 vs. 50-59	0.22	3.14	<0.05
60-69 vs. 20-29	0.25	3.01	<0.05
60-69 vs. 30-39	0.19	2.90	<0.05

Table 4.115. Grid-cell 2 Multiple Comparisons of Medium Scar Numbers

Comparison	Diff of Means	t	p-value
20-29 vs. 40-49	0.17	3.11	<0.05
20-29 vs. 30-39	0.17	3.01	<0.05

Table 4.116. Grid-cell 3 Multiple Comparisons of Medium Scar Numbers

Comparison	Diff of Means	t	p-value
60-69 vs. 40-49	0.21	3.26	<0.05
60-69 vs. 20-29	0.25	3.01	<0.05
60-69 vs. 30-39	0.19	2.90	<0.05

Table 4.117. Grid-cell 17 Multiple Comparisons of Medium Scar Numbers

Comparison	Diff of Means	t	p-value
60-69 vs. 30-39	0.25	3.75	<0.01
60-69 vs. 40-49	0.24	3.72	<0.01
50-59 vs. 40-49	0.10	3.65	<0.01
50-59 vs. 30-39	0.10	3.48	<0.01
60-69 vs. 20-29	0.25	3.01	<0.05

Table 4.118. Grid-cell 22 Multiple Comparisons of Medium Scar Numbers

Comparison	Diff of Means	t	p-value
60-69 vs. 30-39	0.25	3.75	<0.01
60-69 vs. 40-49	0.24	3.72	<0.01
60-69 vs. 50-59	0.25	3.64	<0.01
60-69 vs. 20-29	0.25	3.01	<0.05

Large Scars

Table 4.119. Grid-cell 1 Multiple Comparisons of Large Scar Numbers

Comparison	Diff of Means	t	p-value
60-69 vs. 40-49	0.25	6.57	<0.001
60-69 vs. 30-39	0.25	6.43	<0.001
60-69 vs. 50-59	0.25	6.25	<0.001
60-69 vs. 20-29	0.25	5.16	<0.001

Table 4.120. Grid-cell 3 Multiple Comparisons of Large Scar Numbers

Comparison	Diff of Means	t	p-value
60-69 vs. 30-39	0.25	6.43	<0.001
60-69 vs. 50-59	0.25	6.25	<0.001
60-69 vs. 40-49	0.23	5.98	<0.001
60-69 vs. 20-29	0.25	5.16	<0.001

Orientation 1 Scars

Table 4.121. Grid-cell 1 Multiple Comparisons of Orientation 1 Scar Numbers

Comparison	Diff of Means	t	p-value
60-69 vs. 40-49	0.50	7.48	<0.001
60-69 vs. 50-59	0.50	7.12	<0.001
60-69 vs. 30-39	0.46	6.77	<0.001
60-69 vs. 20-29	0.50	5.88	<0.001

Table 4.122. Grid-cell 3 Multiple Comparisons of Orientation 1 Scar Numbers

Comparison	Diff of Means	t	p-value
60-69 vs. 30-39	0.23	3.38	<0.01
60-69 vs. 40-49	0.22	3.30	<0.01
60-69 vs. 50-59	0.22	3.07	<0.05
60-69 vs. 20-29	0.25	2.94	<0.05

Table 4.123. Grid-cell 17 Multiple Comparisons of Orientation 1 Scar Numbers

Comparison	Diff of Means	t	p-value
60-69 vs. 30-39	0.23	3.38	<0.01
60-69 vs. 40-49	0.22	3.30	<0.01
60-69 vs. 50-59	0.22	3.07	<0.05

Table 4.124. Grid-cell 18 Multiple Comparisons of Orientation 1 Scar Numbers

Comparison	Diff of Means	t	p-value
20-29 vs. 30-39	0.33	5.88	<0.001
20-29 vs. 40-49	0.30	5.39	<0.001
20-29 vs. 50-59	0.30	5.06	<0.001
20-29 vs. 60-69	0.33	3.92	<0.001

Table 4.125. Grid-cell 21 Multiple Comparisons of Orientation 1 Scar Numbers

Comparison	Diff of Means	t	p-value
20-29 vs. 50-59	0.33	5.64	<0.001
20-29 vs. 30-39	0.31	5.54	<0.001
20-29 vs. 40-49	0.30	5.53	<0.001
20-29 vs. 60-69	0.33	3.92	<0.001

Irregular Scars

Table 4.126. Grid-cell 18 Multiple Comparisons of Irregular Scar Numbers

Comparison	Diff of Means	t	p-value
20-29 vs. 40-49	0.33	16.68	<0.001
20-29 vs. 50-59	0.33	15.52	<0.001
20-29 vs. 30-39	0.31	15.24	<0.001
20-29 vs. 60-69	0.33	10.78	<0.001

4.4 Additional Features

Some features were not discussed in the results section due to their very low incidence across the sample. This incidence data is included below in Table 4.127.

Table 4.127. Incidence of Additional Features

Group	Incidence of Dermatitis	Incidence of Hypopigmentation	Incidence of Tattoos	Incidence of Piercings
Female left hands	1	1	0	0
Female right hands	0	0	0	0
Male left hands	1	0	1	0
Male right hands	10	2	0	0
20-29 left hands	0	0	0	0
20-29 right hands	0	0	0	0
30-39 left hands	0	0	0	0
30-39 right hands	0	0	0	0
40-49 left hands	1	0	1	0
40-49 right hands	4	1	0	0
50-59 left hands	0	0	0	0
50-59 right hands	0	0	0	0
60-69 left hands	5	1	0	0
60-69 right hands	0	0	0	0
Left-handed left hands	1	0	0	0
Left-handed right hands	0	0	0	0
Right-handed left hands	1	1	1	0
Right-handed right hands	12	2	0	0

Some participants whose images are held in the database did not provide full personal details, resulting in some individuals without a known sex, age or dominant hand, or a combination of these.

4.5 Intra- and Inter-observer Error

Intra-observer Error

Assessment of the variation in the observations of each observer showed little variation within observers. The number of ephelides observed by Observer 1 varied significantly in two of the observed images and the number of orientation 1 scars observed significantly in one image. The number of ephelides observed by Observer 3 varied significantly in two of the observed images.

Inter-observer Error

There was significant variation between observers in terms of the observed frequencies of features. Much of this significant variation was between observer 3 and observer 1 and between observer 3 and observer 2. Tables 4.128 to 4.140 show these significant differences, with a 'Y' identifying the hand and observers where significant differences between observations were seen. Blank cells identify observations where no significant difference was observed.

A possible explanation for this is that Observer 3 possessed several years' experience of assessing hand images for identifiable features. In contrast, observers 1 and 2 were both within 1-2 years of graduating from an undergraduate degree in Forensic Anthropology. Observer 1 possessed approximately three months' experience of assessing hand images, whereas observer 2 possessed no previous experience of hand image assessment. The most significant differences in quantification were seen in ephelides. A possible reason for this is that this feature occurred in very large numbers in some individuals, which may have resulted in errors in quantification due to difficulty in identification of individual ephelides when they were present in large numbers.

Table 4.128. Ephelides Inter-observer Error

	1	2	3	4	5	6
Observer 1 vs. Observer 2		Y		Y	Y	
Observer 1 vs. Observer 3	Y		Y	Y	Y	Y
Observer 2 vs. Observer 3	Y		Y	Y	Y	Y

Table 4.129. Nevi Inter-observer Error

	1	2	3	4	5	6
Observer 1 vs. Observer 2						
Observer 1 vs. Observer 3		Y			Y	
Observer 2 vs. Observer 3		Y			Y	

Table 4.130. Knuckle Pads Inter-observer Error

	1	2	3	4	5	6
Observer 1 vs. Observer 2						
Observer 1 vs. Observer 3			Y			
Observer 2 vs. Observer 3			Y			

Table 4.131. Total Scars Inter-observer Error

	1	2	3	4	5	6
Observer 1 vs. Observer 2						Y
Observer 1 vs. Observer 3					Y	
Observer 2 vs. Observer 3						Y

Table 4.132. Linear Scars Inter-observer Error

	1	2	3	4	5	6
Observer 1 vs. Observer 2		Y				Y
Observer 1 vs. Observer 3	Y		Y	Y		
Observer 2 vs. Observer 3	Y		Y	Y		

Table 4.133. Non-linear Scars Inter-observer Error

	1	2	3	4	5	6
Observer 1 vs. Observer 2			Y		Y	
Observer 1 vs. Observer 3	Y			Y	Y	
Observer 2 vs. Observer 3	Y		Y	Y		Y

Table 4.134. Small Scars Inter-observer Error

	1	2	3	4	5	6
Observer 1 vs. Observer 2						
Observer 1 vs. Observer 3	Y				Y	
Observer 2 vs. Observer 3	Y				Y	

Table 4.135. Medium Scars Inter-observer Error

	1	2	3	4	5	6
Observer 1 vs. Observer 2			Y			Y
Observer 1 vs. Observer 3			Y			
Observer 2 vs. Observer 3						Y

Table 4.136. Orientation 1 Scars Inter-observer Error

	1	2	3	4	5	6
Observer 1 vs. Observer 2						Y
Observer 1 vs. Observer 3						
Observer 2 vs. Observer 3				Y		

Table 4.137. Orientation 2 Scars Inter-observer Error

	1	2	3	4	5	6
Observer 1 vs. Observer 2				Y		
Observer 1 vs. Observer 3						
Observer 2 vs. Observer 3				Y		

Table 4.138. Orientation 3 Scars Inter-observer Error

	1	2	3	4	5	6
Observer 1 vs. Observer 2		Y				
Observer 1 vs. Observer 3	Y		Y			
Observer 2 vs. Observer 3		Y	Y	Y	Y	

Table 4.139. Orientation 4 Scars Inter-observer Error

	1	2	3	4	5	6
Observer 1 vs. Observer 2		Y		Y		
Observer 1 vs. Observer 3					Y	
Observer 2 vs. Observer 3		Y		Y		

Table 4.140. Irregular Scars Inter-observer Error

	1	2	3	4	5	6
Observer 1 vs. Observer 2						
Observer 1 vs. Observer 3	Y			Y		Y
Observer 2 vs. Observer 3	Y			Y		Y

4.6 Analysis of Normalised Data

Analysis of the variance between the original non-normalised data and the normalised data showed that there was no significant variation between the values from the non-normalised data and the normalised data for each of the grid-cells analysed. The p-values resulting from the analysis of variance between the normalised and non-normalised data are shown below in Table 4.141.

Table 4.141. Analysis of Normalised and Non-normalised Data

Grid-cell	1	7	12	17	21
p-value	0.852	0.675	0.942	0.942	1.000

Interpretation of Results and Discussion

The following section provides an interpretation and discussion of the results seen in this project. Each section is discussed in the same order as the results appear in the Results section.

4.7 Sex Differences

4.7.1 Female Left Hands (n=61) – Grid-cell Comparison

Although the dorsal hand grid-cells were generally similar and did not show significant differences between cells, some exceptions to this rule were observed. In particular, grid-cells 1, 5, 6 and 10 were often significantly different to the other dorsal hand grid-cells. This was contrary to the pattern seen in the other grid-cells in the dorsum of the hand, which generally were not significantly different to each other. It is possible that the smaller surface area of grid-cells 1, 5, 6 and 10 in comparison to the other grid-cells on the dorsum of the hand may have contributed to this. Therefore, it is possible that the distribution of ephelides in grid-cells 1, 5, 6 and 10 does not actually differ significantly from the other dorsal-hand grid-cells, and the significant differences observed here are a result of differing relative surface areas in grid-cells. It is unlikely that the regions of skin at the most lateral and medial edges of the hand are exposed to less sunlight and so genuinely develop lower numbers of ephelides, as these areas are orientated in the same way as the central region of the dorsum of the hand and so should theoretically be exposed to the same amount of sunlight.

The remainder of the grid-cells on the dorsal surface of the hand showed significant differences to grid-cells in the digits, with greater average numbers of ephelides observed on the dorsum of the hand than on the digits. The greatest differences were observed between the dorsal hand grid-cells and the most distal regions of the digits, with the differences decreasing between more proximal grid-cells and the dorsum of the hands. This is suggestive of a proximal-distal gradient in the hand with regards to the number of ephelides observed. The greatest differences in ephelide numbers are seen when proximal grid-cells (dorsum of hand) are compared to the most distal grid-cells, at the ends of the digits. Upon progressing proximally, these differences become smaller, though still statistically significant.

The presence of the fingernails reduced the total surface area of each distal digit grid-cell. This is important to take into account, considering the most significant differences were observed between the dorsum of the hand and the terminal regions of the digits. The smaller surface area in these grid-cells compared to the other digital grid-cells may have been responsible for the greater significance of the differences observed. However, regardless of this potential problem, the differences between the dorsum of the hand and the middle regions of the digits were greater than the differences between the dorsum of the hand and the proximal regions of the digits, and so the gradual increase in similarity between the hand dorsum with proximal progression up the digits is still present.

Grid-cells 11 to 24, which represent the digits, showed significant differences to the grid-cells in the dorsum of the hand. The number of dorsal hand grid-cells showing significant differences to digital grid-cells increased in number as the location of the digital grid-cells grew more distal. For example, grid-cell 11 was significantly different to grid-cell 3, but grid-cell 16 was significantly different to grid-cells 1, 2, 3, 4, 7, 8 and

9. This suggests that, in terms of the number of ephelides, the proximal regions of the digits and the dorsum of the hand are similar, while the distal regions of the digits and the dorsum of the hand are dissimilar. Based on the mean values in these grid-cells, the number of ephelides observed in the dorsum of the hand and the proximal regions of the digits are greater than in the more distal regions of the digits. Although the literature on bodily coverage of ephelides is extensive, no detailed study has taken place into regional differences in occurrence with single anatomical locations. Ephelides are strongly linked to UV exposure (McKee and Calonje, 2009; Wulf *et al.*, 2004), and so these findings suggest that the dorsum of the hand and the regions of the digits closest to the dorsum are exposed to a greater amount of UV light than are the middle and distal regions of the digits. A possible explanation for this may be that the middle and distal digits are protected from sun exposure when the hand is in a grasping position, leaving the dorsal hand and proximal digits exposed.

4.7.2 Female Right Hands (n=61) – Grid-cell Comparison

Female right hands were found to be very similar to female left hands in terms of their patterns of significant differences. Generally, the dorsal hand grid-cells were not significantly different to each other. Similar to female left hands, grid-cells 1, 5, 6 and 10 showed unexpected significant differences when compared to their neighbouring grid-cells on the dorsum of the hand. The greatest significant differences in ephelide numbers were observed between the dorsal hand grid-cells and the grid-cells in the distal regions of the fingers, with greater mean numbers of ephelides observed in the dorsum of the hand than in the digits. This is again suggestive of a difference in sun

exposure between the dorsum of the hand and proximal digits, and the middle and distal digits, as discussed in female left hand section previously.

A similar pattern was seen in female right hands with regards to the increasing significant differences in ephelide numbers seen between digital grid-cells and dorsal-hand grid cells. However, grid-cell 10 also fell into this pattern despite it being located in the dorsum of the hand. Again, similar to female left hands, the significant differences became smaller between the more proximal digital grid-cells and the dorsal surface of the hand.

4.7.3 Summary

Overall, there are significant differences in the number of ephelides present on the dorsal hand compared to the digits in both female left and right hands. The greatest differences were seen between the most distal regions of the digits and the dorsal hand. Upon progressing towards the more proximal regions of the digits, the differences between these regions and the dorsal hand became smaller, but were still statistically significant. The presence of fingernails in the most distal regions of the digits reduced the surface area of the distal digit grid-cells relative to the middle and proximal digit grid-cells. This may have resulted in the distal grid-cell frequencies of ephelides being falsely reduced in comparison to the other digital grid-cells. However, this does not detract from the fact that a gradient is present in the middle and proximal digits, with the middle digits being more significantly different to the dorsum of the hand than the proximal digits are to the dorsum of the hand. No explanation for this gradient effect could be located in the literature, however the author hypothesises that when the hand is in a grasping position, the middle and distal regions of the digits are better

protected from sunlight, while the hand dorsum and the proximal digits are left exposed. This may have the effect of increased sunlight-related features, for example ephelides, in the latter and reduced numbers of these features in the less exposed middle and distal digits.

No significant differences between grid-cells on the lateral and medial edges of the left and right hands were observed, so no medio-lateral gradient could be detected in terms of ephelide numbers in female left or right hands.

Generally, individual regions of the dorsal surface of the hand itself are not significantly different to each other. The grid-cells that did not fit this pattern are of a smaller surface area than the other grid-cells in the dorsum of the hand, which may explain their frequent significant differences in ephelide numbers when compared to other dorsal hand grid-cells.

No significant differences were detected between grid-cells for any other features observed. This was also seen in female left hands and is suggestive of uniformity between the different regions of both the female left hand and the female right hand in terms of nevi, lentigines and trauma-related features such as knuckle pads, amputations and scars. The current literature often focuses on the differences between the hands of different cohorts, however little investigation has been carried out into the differences within the hand itself in different sex, age and handedness cohorts. A possible explanation for this finding is the predominance in the sample for individuals to possess no instances of some features. As this pattern was seen in several groups when comparison was made within the hand, this pattern will be discussed overall in the conclusion.

4.7.4 Female Left Hands (n=61) vs Female Right Hands (n=61)

Overall, significantly larger numbers of ephelides were observed in female right hands than in female left hands. Ephelides are related to environmental exposure to sunlight (Trozak *et al.*, 2006) and it is possible that dominant hands experience greater environmental exposure. It is possible that the greater number of right-handed individuals than left-handed individuals in the sample population may have contributed to a raised level of significance in these values.

No significant differences were observed in nevi numbers between female left hands and female right hands, which was an expected result as nevi are believed to be strongly controlled by genetics (Bauer *et al.*, 2007), though an environmental effect also exists. A strong environmental effect, i.e. sunlight exposure, would possibly be expected to manifest in a similar way as with ephelides, with the right hands possessing greater numbers of nevi due to the sample bias toward right-handed individuals.

No pattern was observed in terms of lentigine numbers. Female right hands showed significantly larger mean totals in two grid-cells, but the left hands showed significantly larger mean totals in two other grid-cells. This is a similarly conflicting result as that seen when female right hands were compared to male right hands, and is difficult to explain. It is possible that incorrect classification of ephelides as lentigines may have contributed to this confusing result.

Significant differences in linear scar numbers were observed in grid-cells 7, 9 and 17. Grid-cells 7 and 17 are found on the lateral border of the hand in the “index corridor”. The right hands possessed larger mean numbers of linear scars in all three of these grid-

cells. This may be suggestive of a propensity to damage the ‘index corridor’ region of the hand. A greater risk of injury to the borders of the hand, in particular the thumb and index finger, has been suggested previously by Rosberg and Dahlin (2004). Grid-cell 9 however, is not located at the lateral border of the hand, and is instead located in a central-medial position on the dorsum of the hand. The observation of a significant difference between the left and right female hands in this grid-cell suggests that females are at greater risk of injuring this area on the right hand than the left, as well as being more likely to injure the ‘index corridor’ region.

Grid-cells 7 and 17 in the right hand also showed significantly larger mean values of non-linear scars than in the left hand. Again, this suggests a higher risk of trauma to the lateral border of the right hand in females. This greater likelihood of trauma-related features in this region is potentially very useful for forensic image comparison as it gives an indication of which areas of the hand are more or less likely to contain these features.

Grid-cells 7 and 17 showed significantly larger mean values of small scars in the right hand, which is the same pattern of variation as seen in linear and non-linear scars. Orientation 1 and orientation 3 scars also showed significant variation in grid-cell 17, with right hands possessing larger mean values of these scars than left hands. This is further evidence of the ‘index corridor’, a region down the lateral border of the hand where trauma appears to be more common. Additionally, this supports the pattern of significantly more trauma occurring to the female right hands than the female left hands, which was seen in linear scars.

4.7.5 Male Left Hands (n=177) – Grid-cell Comparison

The patterns of variation observed in male left hands were less clear than those seen in female left hands and female right hands. Generally the more centrally-located dorsal hand grid-cells, such as 2, 3, 4, 7, 8 and 9 showed a greater degree of similarity in total ephelide numbers. Grid-cells 4, 5 and 6 were significantly different to a large number of dorsal hand grid-cells however, which did not fit with the pattern seen thus far of similarity between dorsal hand grid-cells. This is similar to what was seen in female left and right hands, where grid-cells 1, 5, 6 and 10 were frequently significantly different to the other dorsal hand grid-cells. Again, it is possible that the smaller surface area of grid-cells 4, 5 and 6 relative to most of the other dorsal hand grid-cells may have contributed to the significant differences observed. Therefore, it is possible that the overall distribution of ephelides in these grid-cells does not differ significantly from the rest of the hand dorsum and the significant differences observed here are a result of differing relative surface areas in grid-cells.

The grid-cells located in the digits were significantly different to the dorsal hand grid-cells, with the greatest differences seen between the most distal regions in the digits and the proximally-located dorsal hand regions. This gradient of decreasing differences in ephelide numbers between the hand dorsum and the digits with proximal progression was also seen in female left and right hands. As discussed previously, the presence of the fingernails in the most distal grid-cells potentially poses a problem in the fact that they reduce the surface area of these cells, decreasing the number of ephelides observed. However, as also discussed previously, there still exists a decrease in significant differences between the middle digits and hand dorsum and the proximal digits and hand dorsum. Again, this is suggestive of an increasing difference in sun exposure

towards the distal ends of the digits. It was hypothesised previously that this may be due to the middle and distal digits being better protected from sun exposure than the dorsum of the hand and the proximal digits, due to the grasping motion of the hand.

Grid-cells 16 and 20-24 were significantly different to grid-cells 11-13 in terms of the number of ephelides observed. Grid-cells 11-13 are located at the most proximal regions of the digits, while grid-cells 16 and 21-24 are located at the most distal regions of the digits. It is possible that the significant differences seen between these regions are a result of the proximo-distal gradient, resulting in a high number of ephelides in grid-cells 11, 12 and 13 as they are adjacent to the dorsum of the hand. Additionally, the presence of fingernails reduced the surface area of grid-cells 21-24, which may have contributed to lower ephelide numbers in these grid-cells, and resulting in a significant difference between them and grid-cells 11-13.

No significant differences were detected between grid-cells for any other features observed. This was also seen in female left and right hands. This is suggestive of uniformity between the different regions of both the male left hand in terms of nevi, lentiginos and trauma-related features such as knuckle pads, amputations and scars.

4.7.6 Male Right Hands (n=177) – Grid-cell Comparison

Most grid-cells on the dorsum of male right hands did not differ significantly from each other in terms of ephelides. However, grid-cells 6 and 10 were significantly different to their neighbouring dorsal hand grid-cells but not significantly different to the grid-cells in the digits. This is converse to the behaviour seen in other dorsal hand grid-cells, which tend to be similar to other dorsal hand grid-cells, but significantly different to the

digital grid-cells. Grid-cells 6 and 10 may have contradicted this pattern due to their small surface area in comparison to other dorsal hand grid-cells, which may have caused them to possess lower total ephelide numbers.

Similar to male left hands and female left and right hands, a proximo-distal gradient was observed, with the most distal grid-cells at the ends of the fingers being significantly different from the grid-cells in the dorsal surface of the hand.

No significant differences were detected between grid-cells for any other features observed. This was also seen in female left and right hands, and male left hands. This is suggestive of uniformity between the different regions of both the male right hand in terms of nevi, lentigines and trauma-related features such as knuckle pads, amputations and scars.

4.7.7 Summary

Generally, the grid-cells in the dorsum of the hand did not differ significantly from each other with regards to the number of ephelides. The dorsal hand grid-cells that did not follow this rule were 1, 5, 6 and 10. Grid-cells 1, 5, 6 and 10 are similar in size, and have a small surface area compared to the other dorsal hand grid-cells. This reduced surface area in comparison to the other dorsal hand grid-cells may have contributed to smaller ephelide counts in these regions relative to the other, large dorsal hand grid-cells.

Significant differences in ephelide numbers exist between the dorsal hand grid-cells and the digital grid-cells, with the greatest differences being found between the most proximal regions of the hand and the most distal regions of the hand, as has been seen in female left and right hands and male left hands. This is suggestive of a gradation in ephelide numbers in the hand, with the greatest number of ephelides seen in the dorsum of the hand itself, and a gradual decrease in ephelides as more distal regions of the digits are observed. The presence of fingernails in the distal digit grid-cells reduced the surface area in those grid-cells. This may have caused a reduced number of ephelides in these grid-cells, resulting in the significant difference seen between these regions of the hand.

No significant differences in ephelide numbers between grid-cells on the lateral and medial edges of the left and right hands were observed, so no medio-lateral gradient exists in terms of ephelide numbers in male left or right hands. This suggests that UV exposure is uniform across the hand from medial to lateral, contrary to the gradient in sun exposure-related features from the dorsum of the hand to the distal digits.

4.7.8 Male Left Hands (n=177) vs Male Right Hands (n=177)

Male hands followed the same pattern as seen in females in terms of mean ephelides observed. Right hands possessed a significantly larger number of ephelides in grid-cell 3, and larger means in most other grid-cells, though not at a significant level. This suggests that the male right hand is exposed to a greater amount of sunlight than the male left hand. It is possible that the dominant hand is exposed to more sunlight than the non-dominant hand due to its more regular use in manipulating objects. The sample was biased towards right-handed individuals, so it is possible that the greater number of

right-hand dominant individuals resulted in a significantly greater amount of ephelides in the right hands. Differences between dominant and non-dominant hands will be further discussed later in this chapter.

Significantly greater numbers of knuckle pads were observed in male left hands than male right hands. This compliments the pattern of significantly more knuckle pads observed in male left hands than female left hands.

Linear scars were significantly more common in grid-cells 1, 7 and 17, and non-linear were significantly more common in grid-cell 1. Small scars were significantly more common in grid-cells 7 and 18. Medium and orientation 3 scars were significantly more common in grid-cell 7 in left hands, and orientation 2 and 3 scars were significantly more common in grid-cell 17 in the left hand. This is suggestive of the existence of the 'index corridor' as seen when female left and right hands were compared. This corridor of grid-cells begins on the lateral side of the dorsum of the hands and runs down the index finger, and appears to be at greater risk of injury due to the observation of significant number of scars in this region in female right hands and male left hands.

Grid-cells 22 and 23 showed significantly larger numbers of medium, orientation 2 and orientation 3 scars in the left hand. This may suggest a greater risk of injury to the tips of the fingers. This was not seen when female left and right hands were compared, suggesting that while females are more likely to injure their right hands in the region of the 'index corridor', males are more likely to injure their left hands in region of the 'index corridor', but also at the tips of the third and fourth digits.

4.7.9 Summary

In summary, ephelides are significantly more common in the right hands of both females and males. This may be due to greater environmental exposure of the dominant hand. This study found that right-handed individuals possessed significantly more ephelides in their dominant hand than in their non-dominant hand, which would support the theory that the dominant hand is exposed to more UV light, as sunlight plays an important role in ephelide appearance. However, the sample was also biased towards right-handed individuals, so it is possible that a greater number of ephelides were present in the dominant hands due to greater sun exposure, and this has resulted in significantly greater numbers of ephelides in comparison to the left hands of females and males.

Although there were significant differences observed in male and female groups and between male and female groups in terms of lentigine numbers, it is possible that these results may have been affected by incorrect identification of ephelides as lentigines. The similarity of these two features can make them very difficult to differentiate, and so the numbers of lentigines observed may have been falsely inflated. The confusing results seen in lentigines when female left hands were compared to female right hands, with significantly more seen in different grid-cells in different hands is evidence towards this, making results from this feature potentially unreliable.

Females demonstrated a significantly larger number of scars in their right hands than in their left hands. Conversely, males demonstrated a significantly larger number of scars in their left hands than in their right hands. This further evidences the greater likelihood of trauma to the right hand in females, and to the left hand in males. In both males and females, grid-cells 1, 7, 17 and 18 are most likely to contain scars. This “corridor” of

greater trauma risk runs down the lateral border of the hand and down the index and middle fingers. Females are more likely to possess these scars in their right hands, whereas males are more likely to possess scars in their left hands. Males are also more likely to possess scars in the distal end of the third and fourth digits in their right hands. Ultimately, this is suggestive of a sex difference that results in females being more at risk of trauma to the right hand, and males at more risk of trauma to the left hand. Rosberg and Dahlin (2004) and Hill *et al.* (1998) both state that males are at greater risk of hand injury than females. However, neither of these studies discusses whether this is the case for both left and right hands, which is important as this study has found that there is in fact a difference between the left and right hands in terms of whether males or females possess significantly more scars.

Knuckle pads were more common in male left hands than male right hands. The most common location that knuckle pads were observed was in the proximal and middle regions of the index finger, over the proximal interphalangeal joint and the metacarpophalangeal joint. This is located within the corridor of trauma seen with scar locations, further corroborating the greater risk of trauma to this region and therefore its potential value for identification purposes.

4.7.10 Female left hands (n=61) vs Male left hands (n=177)

Males possessed a significantly larger number of ephelides than females for left hands compared to right hands. Males possess larger hands than females, which may have contributed to this. These ephelides were mainly concentrated on the hand itself, with less ephelides observed in the digits.

Significantly larger mean numbers of nevi and lentigines were observed in several grid-cells in females compared to males. It is possible that these values and those for ephelides were falsely inflated due to male hands being hairier, and thus concealing these features in male participants. However, a similar effect would also be expected in ephelides, which is not seen. This suggests that the hairiness of male hands may not have contributed to the higher numbers of nevi and lentigines observed in female hands. It is possible therefore, that females are more likely to possess nevi and lentigines due to a genetic or environmental influence that does not affect males as strongly. Although an explanation for this could not be located in the literature, Bevona *et al.* (2003) found that females were slightly more likely, though not significantly, to develop melanomas in association with nevi than males were in the trunk, upper and lower extremities and the head neck. Development of a nevus into a melanoma is known to be related to exposure to UV light (Gershenwald and Hwu, 2010), and so it may be the case that females experience more exposure to the sun in their lifetime, or as possibly more vulnerable to the damaging effects of UV light on nevi.

In the left hands, males always possessed larger mean numbers of scars when a significant difference was present. Linear, small, orientation 2, orientation 3 and orientation 4 scars all occurred at significantly different levels between female and male left hands, and all showed a greater incidence in males. Knuckle pads were also observed in grid-cells 12, 17 and 18 in significant numbers in male left hands compared to female left hands, presenting a similar pattern of trauma to the lateral edge of the left hand in males as is seen in other trauma-related features, such as scars. This suggests that the lateral border of the male left hand is more commonly damaged through both acute and chronic trauma, than other regions of the left or right hand.

4.7.11 Female right hands (n=61) vs Male right hands (n=177)

There was no significant difference between the sexes for ephelides in the right hand. Males possessed a larger mean number of lentigines in grid-cell 2, whereas females possessed a significantly larger mean number of lentigines in grid-cell 3. This unexplainable result may suggest that identifying between lentigines and ephelides may have been flawed, and that in some cases lentigines may have been classified as ephelides and vice versa. Future studies of this nature would benefit from the opinion of an expert in dermatology, or possibly combining pigmentary skin features such as ephelides and lentigines together in order to avoid incorrect classification.

The most notable results when comparing female right hands and male right hands were the significant differences in scar numbers observed. Females possessed significantly greater mean numbers of scars than males in non-linear, small, medium, orientation 1 and irregular scars.

Non-linear, small, medium, orientation 1 and irregular scars all occurred at significantly different levels between female and male right hands, and all showed a larger average in females, bar medium scars in grid-cell 9. These features occurred in 7, 12, 17 and 18. This suggests that trauma, and therefore trauma-related features are more likely to be seen in the female right hand than in the male right hand. It is also further evidence of the “index corridor”, running from the dorsum of the hand down the index finger, where trauma is more likely to occur on the lateral border of the hand.

4.7.12 Summary

The greater number of scars in the female right hands is converse to the pattern seen in the left hands, where males always possessed larger mean values than females where a significant difference was observed. This is possibly suggestive of some behavioural difference that puts females at greater risk of injury to their right hands, but males at greater risk of injury to their left hands. Knuckle pads were also significantly more common in male left hands than in female left hands, lending further weight to the argument that males appear to sustain greater trauma to their left hands.

4.8 Hand Dominance Differences

4.8.1 Dominant Left Hand Grid-cell Comparison (n=26)

Grid-cells 3 and 8 were significantly different from the grid-cells in the digits in terms of the number of ephelides observed. These were the only significant differences observed in left-handed left hands. Grid-cells 3 and 8 are the most central grid-cells in the dorsum of the hand and also have the greatest surface area of the dorsal hand grid-cells. There was no significant variation between the grid-cells in the dorsum of the hand, suggesting that all regions of the hand dorsum behave in a similar way in terms of the numbers of ephelides present.

No significant differences were observed between grid-cells in dominant left hands for any other features. This is the same as was seen in the left and right hands of males and females. This suggests that the surface of the dominant left hand behaves uniformly, with no area possessing a significantly greater number of nevi or lentigines, or trauma-related features.

4.8.2 Non-dominant Left Hand Grid-cell Comparison (n=212)

Grid-cells 3, 7 and 8 were all similar to each other with regards to the number of ephelides observed. Grid-cells 4, 5, 6 and 10 were significantly different from the other grid-cells on the dorsal surface of the hand. These four grid-cells were previously observed to differ from the pattern of similarity between dorsal hand grid-cells

previously, and it is likely that this is due to the smaller surface area in these grid-cells compared to the other grid-cells on the dorsum of the hand.

The dorsal surface of the hand possessed a significantly different number of ephelides compared to the fingers, as was observed in the dominant right hands. Again, the dorsal hand surface grid-cells possessed greater average ephelide counts than the digits. Grid-cell 10, which is found on the medial edge of the hand also fell into the pattern exhibited by the grid-cells in the digits, and was significantly different to the other grid-cells on the dorsum of the hand. This is most likely due to its smaller surface area, as has been discussed previously, causing it to behave like a digital grid-cell rather than a dorsal hand grid-cell.

Non-dominant left hands did not show any significant differences between grid-cells in any other features. This pattern of uniformity within the hand in terms of nevi, lentigines and trauma-related features is the same pattern as seen in dominant left hands, as well as the left and right hands of males and females. This pattern was seen throughout the sample in both sex groups and both handedness groups, and may be due to the large number of individuals within cohorts that did not possess any instances of a given feature. Further conclusions drawn from this can be found in the Conclusion section, along with Table 5.1, which demonstrates the number of individuals possessing zero values for each feature.

4.8.3 Summary

Overall, the grid-cells on the dorsum of both the dominant left hands and non-dominant left hands do not differ significantly. However, the medial and lateral borders of the

hand dorsum (grid-cells 4, 5, 6 and 10) tend to differ significantly from the other dorsal hand grid-cells in terms of the number of ephelides present in right-handed right hands and right-handed left hands. This is possibly due to the smaller surface area in these grid-cells compared to the other grid-cells on the dorsum of the hand. It is unlikely that the lateral and medial borders of the hand are exposed to different amounts of sunlight than the central regions of the dorsum of the hand, so the differing surface area of the grid-cells is more likely to be the reason for this difference.

The digits differed significantly from the dorsal surface of the hand in terms of the number of ephelides observed. This is the same pattern as was observed in the left and right hands of males and females.

Again, no significant differences were detected within the dominant or non-dominant left hands. This follows the pattern already observed in the different sex group and suggests uniformity between the different regions within the hand in terms of the number of nevi, lentigines and trauma-related features contained within them.

4.8.4 Dominant Right Hand Grid-cell Comparison (n=212)

The central dorsal hand grid-cells were similar to each other in terms of the number of ephelides observed. However, the grid-cells located on the lateral and medial edges of the hand (grid-cells 1, 5, 6 and 10) were frequently significantly different to the grid-cells located in the centre of the hand (grid-cells 2, 3, 4, 7, 8 and 9). This may have been due to several reasons. The grid-cells at the lateral and medial borders of the dorsum of the hand have a smaller surface area, which may have caused a smaller number of ephelides relative to the slightly larger central grid-cells on the dorsum of the hand. However, grid-cells 11 to 24 (digital grid-cells) were significantly different to the grid-cells on the dorsum of the hand.

Grid-cells 11, 12 and 13 were significantly different to grid-cells 16, 19, 20, 21, 22, 23 and 24. This is a similar pattern to that seen in male left hands, and again may be the result of grid-cells 11, 12 and 13 being adjacent to the dorsum of the hand, and so behaving in a similar way to the hand dorsum in terms of the number of ephelides observed.

4.8.5 Non-dominant Right Hand grid-cell Comparison (n=26)

The same pattern of significant differences was seen in non-dominant right hands as was seen in dominant right hands. Again, grid-cells 3 and 8 were significantly different to several digital grid-cells in terms of the number of ephelides observed. There was no significant variation between the grid-cells in the dorsum of the hand, suggesting that all regions of the non-dominant right hand dorsum behave in a similar way in terms of the numbers of ephelides present. There was also no significant variation between grid-cells in terms of nevi, lentigines or trauma-related features, again suggesting a uniform nature

to these features within the non-dominant right hand, with no feature appearing significantly more often in one particular region of the hand than in any other.

4.8.6 Summary

The pattern of significant differences seen in the left-handed cohort differed from the right-handed cohort in that less dorsal hand grid cells showed significant differences in ephelide numbers with each other. No significant variation was observed between dorsal hand grid-cells, suggesting that all regions of the dorsum of the hand behave in a similar way with regards to the number of ephelides present. This suggests that the individual regions of the dorsum of the hand do not differ significantly in the amount of sunlight they are exposed to, as ephelide appearance is believed to be related to exposure to UV light (Bastiaens *et al.*, 1999).

Again, no significant variation was observed between grid-cells in terms of nevi, lentigines or trauma-related features. It is hypothesised that the small number of individuals that actually possessed these features compared to the number of individuals that had no instances may be responsible for this. Table 5.1 in the Conclusion illustrates the incidence of individuals with zero values for each feature.

4.8.7 Left-handed – Dominant Left Hands vs Non-dominant Right Hands

Left-handed individuals possessed more lentigines in their non-dominant (right) hand than in their dominant (left) hand. This pattern would suggest that greater sun exposure occurs in the non-dominant hand. No literature investigating differences in UV light exposure between dominant and non-dominant hands could be located. However, this result is possibly opposite to what would be expected. The dominant hand would be expected to sustain greater sunlight exposure than the non-dominant hand due to its more regular use.

Sorock (2001) suggests that left-handed individuals are more likely to injure their right hand, however no clear pattern was apparent in scars observed in the left-handed individuals, with both the left and right hands showing significantly greater numbers of different types of scar. Significant differences were observed in linear and small scars, but an equal number of linear and small scars were greater in dominant hands as were observed in non-dominant hands.

The 'index corridor' of trauma was also observed in both of the left and right hands, as it was in the male and female cohorts. Grid-cells 2, 17, 18 and 21 all possessed significantly higher numbers of scars than other grid-cells. However, significantly greater numbers of linear scars and small scars were seen in the left hands in grid-cells 2 and 18, while significantly greater numbers of these scars were seen in the right hands in grid-cells 17 and 21. Therefore, although the 'index corridor' showed greater trauma-related features in both the dominant and non-dominant hands of the left-handed cohort,

it did not appear to demonstrate a clear pattern in terms of being more common in the left or right hand.

4.8.8 Right-handed – Non-dominant Left Hands vs Dominant Right Hands

Right-hand dominant individuals possessed significantly greater numbers of features related to sun-exposure in their right hands. This was opposite to the pattern seen when the left and right hands of the left-handed cohort were compared, which showed that lentigines were significantly more common in the non-dominant hand than in the dominant hand. The dominant hand would be expected to sustain greater sunlight exposure due to its more regular use, and therefore features related to sunlight exposure would be expected to be more common in the dominant hand than in the non-dominant hand. Therefore, the greater numbers of ephelides and lentigines observed in the right-handed cohort is a result that would be expected.

Sorock (2001) also states that right-handed individuals are more likely to injure their left hand. However, similar to the left-handed cohort, there was no clear pattern in trauma-related features, with some showing significantly higher numbers in right hands, but some showing significantly higher numbers in left hands.

The ‘index corridor’ of trauma was again observed in grid-cells 1, 7, 17, 22 and 23. Similar to the left-handed cohort, there was not a clear pattern of significance between the left and right hands. Significantly greater numbers of non-linear, medium, large, orientation 2 and orientation 3 scars were observed in grid-cells 1, 7, 17, 22, 23.

However, significantly greater numbers of non-linear and medium scars were observed in grid-cells 3, 17, 22 and 23.

4.8.9 Summary

There did not appear to be prevalence for injuries to occur more significantly to either the dominant hands or non-dominant hands. The 'index corridor' observed in the male and female cohorts was again observed in the right-handed and left-handed cohorts and occurred irrespective of dominance. This region down the lateral part of the hand appears to sustain greater trauma than the rest of the hand, as evidenced by the tendency of these grid-cells to possess significantly larger numbers of scars when different cohorts are compared.

4.8.10 Dominant Left Hands vs Non-dominant Left Hands

Although dominant left hands possessed larger numbers of ephelides, non-dominant left hands possessed larger numbers of lentigines. These features are both linked to sunlight exposure, so it would be expected that they would exhibit a similar pattern of variation. As discussed previously, it is possible that lentigines were wrongly classified and were in fact ephelides, meaning that conclusions drawn from lentigine numbers may be unreliable.

Rosberg and Dahlin (2004) and Hill (1998) have suggested that the dominant hand is more at risk of injury than the non-dominant hand. A majority of trauma-related features (knuckle pads and scars) were significantly higher in the dominant hands than in the

non-dominant hands in this study also, corroborating the evidence of Rosberg and Dahlin (2004) and Hill (1998).

4.8.11 Dominant Right Hands vs Non-dominant Right Hands

The opposite pattern of variation was seen in features related to sun-exposure in the right hands compared to that seen in the left hands. Ephelides were more common in the non-dominant hands, whereas lentigines were more common in the dominant hands. The number of scars was significantly higher in the non-dominant hands, which was also converse to the pattern observed in the left hands, as well as to the suggestion of Rosberg and Dahlin (2004) and Hill (1998) that injuries to the hand occur more commonly to the dominant hand. This suggests that left-handed individuals are more likely to injure their non-dominant hand. It is possible that left-handed individuals are at greater risk of injuring the non-dominant hand due to using tools and objects that are designed predominantly for right-handed use (Pekkarinen *et al.*, 2003), making them more likely to have an accident and injure the non-dominant hand.

4.8.12 Summary

The patterns of variation in sunlight-related features and trauma-related features were opposite to each other in the left hands and right hands. Left-hand dominant individuals possessed more ephelides in both their right and left hands than right-hand dominant individuals. Conversely, right-hand dominant individuals possessed more lentigines in their left and right hands than left-hand dominant individuals. Due to the fact that these patterns are contradictory, it is difficult to draw conclusions from them.

Individuals who are left-hand dominant appear to be more likely to injure their left hand than people who are right-hand dominant. Left-hand dominant people also appear to be more likely to injure their right hand than right-hand dominant people. This ultimately suggests that left-handed individuals are more likely to suffer trauma to both their left and right hands than are right-hand dominant individuals. It is possible that the greater likelihood for left-handed individuals to sustain injuries to both their right and left hands may be due to greater difficulty with handling objects that are often designed for right-handed use. Pekkarinen *et al.* (2003) investigated whether left-handed individuals were more likely to sustain injury to anywhere on the body than right-handed individuals, and found no significant difference in relative injury risk by hand preference. However, this study does suggest that left-handed individuals can struggle to work with surroundings and tools that are designed mainly for right-handed individuals. Mackenzie and Peters (2000) also identified that emergency controls on industrial equipment very often favour right-handed operation.

4.9 Age Differences

Conclusions made from the age-group cohorts are of less value than the other cohorts, due to the extremely biased nature of the age cohorts in this sample. While the 40-49 age cohort contained 135 individuals, the 30-39 age cohort contained 53 individuals, the 50-59 cohort contained 29 individuals, and the 60-69 and 20-29 age cohorts both contained less than 10 individuals each.

4.9.1 Multiple Comparison of Grid-cells by Age Groups: Left Hands

As expected, features related to sun exposure were seen in significantly higher numbers in older age-groups than younger age-groups. Whenever a significant difference was observed in lentigines, it was always the older age group that possessed the greater average number. This was to be expected, as lentigine numbers have been documented to increase with age (Monestier *et al.*, 2006).

In cases where there was a significant difference between age-groups with regards to the number of ephelides present, it was almost always the older age-groups that possessed the greater average number. This finding was interesting as Bastiaens *et al.* (2004) and Grossman and Guzzo (2000) state that ephelide numbers decrease with age, and so it would be expected that younger age-groups would possess greater numbers of ephelides than older age-groups. The most likely explanation for this finding is that the biased nature of the age-groups resulted in skewed results.

In cases where there was a significant difference between age-groups with regards to the number of nevi present, it was often the younger age-cohort that possessed the greater

number of nevi. This is converse to the pattern seen in ephelides and lentigines. However, it has been suggested that nevi reach a peak in early adulthood (Darlington *et al.*, 2002; English and Armstrong, 1994; Nicholls, 1973) and then decrease in number with increasing age (Bataille *et al.*, 2000), and so this result was expected.

In all scar categories that showed a significant difference between age cohorts (linear, small, medium, orientation 1 and orientation 4), older age cohorts possessed the greater average total number. This would be expected as scars are cumulative over time, thus older individuals would be expected to possess a greater number of scars than younger individuals.

4.9.2 Multiple Comparison of Grid-cells by Age Groups: Right Hands

Features related to sun exposure were seen in significantly higher numbers in older age-groups than younger age-groups. When a significant difference was observed in ephelide numbers, it was almost always the older age-group that possessed significantly more ephelides than the younger age-group. This was the same pattern as was seen in the left hand age group comparisons, and as was discussed in that section, this result was unexpected due to the statements of Bastiaens *et al.* (2004) and Grossman and Guzzo (2000) that ephelide numbers decrease with age. That should have resulted in younger age-groups possessing significantly greater numbers of ephelides than older age-groups rather than the result seen here. Again, the most likely explanation for this finding is that the biased nature of the age cohorts affected the results.

No significant differences were observed between age-groups in terms of the number of nevi observed. Whenever a significant difference in lentigines was observed, it was

always the older age group that possessed the greater average number. Again, as discussed in the previous section, this result was expected as Monestier *et al.* (2006) have stated that lentigine numbers increase with age.

In a majority of scar categories that showed a significant difference, older age cohorts possessed the greater average total number. Younger age groups possessed more orientation 1 and irregular scars than older age groups in grid-cells 17, 18 and 21. This result was also expected as scars are cumulative over time, so it would be expected that older individuals would possess a greater number than younger individuals.

4.9.3 Summary

In summary, older individuals possess greater numbers of lentigines. This would be expected, as older individuals are documented to possess a greater number of lentigines than younger individuals (Monestier *et al.*, 2006).

No clear pattern emerged in nevi, with this feature being more common in younger age-groups than older age-groups in the left hand, but no significant differences being observed between age-cohorts in the right hands. Nevi are documented to be more common in younger individuals, with a peak number reached in the 20s before a gradual decrease in numbers with age (Carton *et al.*, 2007; Green and Swerdlow, 1989; Johr and Schachner, 2002). Therefore, it would be expected to find significant differences with younger age-groups possessing greater numbers than older age-groups. The lack of significant differences seen in the right hand cohort may have been due to the biased nature of the age cohorts causing skewed results.

Older individuals possessed a significantly greater number of scars than younger individuals. Although no references in the literature to greater scar numbers in older individuals could be located, this result would be expected as scars are cumulative over time and older individuals have a greater amount of time in which to have sustained trauma to the hand than younger individuals.

4.9.4 Analysis of Normalised Data

Comparison of the number of ephelides quantified in the original non-normalised cell surface areas with the normalised number of ephelides showed that there was no significant variance between the original values and the normalised values. This suggests that collecting and comparing data from grid-cells of unequal surface area will not have resulted in skewed data, which strengthens the validity of the data collected in the course of this research.

4.10 Conclusion

Ultimately, several patterns can be identified from this data. When the differences in ephelide numbers within the left or right hands were observed, there was always a gradient effect in terms of how significant the differences were, with the most distal digit grid-cells being the most significantly different to the dorsum of the hand, followed by the middle digit grid-cells and the proximal digit grid-cells being least significantly different to the hand dorsum. It is possible that the reason for the greatest significant difference being between the dorsum of the hand and the most distal digit grid-cells is that the fingernails are present in the distal digits. This had the effect of reducing the surface area in these grid-cells relative to the other digital grid-cells, thus reducing the number of ephelides observed. This reduced number of ephelides in comparison to the dorsal hand grid-cells may then have led to the strong significant differences observed.

Very little variation is seen overall between the different regions in the dorsal surface of the hand itself, suggesting that the dorsum of the hand is uniformly affected by genetic and environmental influences. However, the grid-cells at the lateral and medial borders of the hand surface (grid-cells 1, 5, 6 and 10) often do not fit with the patterns of variation seen in the rest of the dorsum of the hand, i.e. no significant variation with other dorsal hand grid-cells but significant variation with digital grid-cells. This may have been the result of their smaller surface area in comparison with the other dorsal hand grid-cells. Similarly, there is very little significant variation between different regions of the digits.

The greatest amount of significant variation is seen between the dorsum of the hand and the dorsum of the digits. Generally, the most significant differences are seen between the hand dorsum and the most distal regions of the digits, with the next most significant differences observed between the hand dorsum and the intermediate regions of the digits, with the differences becoming less significant as more proximal regions of the digits are compared with the hand dorsum. This is suggestive of a proximo-distal gradient of variation between the hand dorsum and the digits. No significant differences were observed between lateral and medial borders of the hand dorsum or the digits, suggesting that there is no medio-lateral gradient of variation in the hand dorsum or in the digits.

Significant differences between the dorsum of the hand and the most distal regions of the digits may have been at least partially influenced by the fact that the fingernails are located in the distal regions of the digits. This resulted in the surface area in these grid-cells being smaller relative to the other grid-cells.

This study has compared left hands with right hands, and has compared these hands within and between sex, handedness and age groups, which is something many previous studies into hand feature variation have failed to do. This has allowed interesting differences to be identified that have not been discussed in the literature before, which are discussed below.

An interesting pattern was observed in terms of differences in trauma to the hands in males and females. Females possessed significantly greater numbers of scars in their right hands than in their left hands, whereas males possess greater numbers of scars in their left hands than in their right hands. This pattern was corroborated when males and

females were compared, with females possessing a significantly greater number of scars than males in the right hand and males possessing a significantly greater number of scars than females in the left hand. Males also possessed a significantly greater number of knuckle pads in their left hands than in their right hands, as well as a significantly greater number in their left hands than in female left hands. Knuckle pads were most often located over the five metacarpophalangeal joints and the proximal interphalangeal joints of the second and third digits. This shows that not only are males more likely to possess a knuckle pad in their left hand than in their right hand, they are also more likely to possess a knuckle pad in their left hand than a female is. Knuckle pads usually arise from repetitive friction at the skin surface, where the skin thickens in order to protect itself. It is well known that males carry a greater risk of injury, due to pursuing more risky occupations, indulging in risk-taking behaviour and participating in more dangerous sports more than women do (Mooney *et al.*, 2010; Scambler, 2008). This may also suggest that males are at greater risk of suffering chronic trauma to their hands than females. An explanation for the more frequent occurrence of knuckle pads in male left hands than male right hands is more difficult to interpret from a review of the literature. When dominant and non-dominant hands were compared, no significant differences were found in knuckle pads except for when dominant left hands were compared with non-dominant left hands. The dominant left hands possessed a significantly greater number of knuckle pads than the non-dominant left hands, suggesting that left-handed individuals suffer more repetitive abrasive trauma to their left hands than right-handed individuals do.

One of the most interesting observations to come from this data is the presence of the so-called 'index corridor'. This corridor running through grid-cells 1, 7, 12 and 17 possesses a large amount of significant variation in a number of features, in particular,

features related to trauma. This has the potential to be extremely useful for forensic image comparison. The thumb and fingers are vital in grasping and manipulating objects (Lese and Kulkarni, 2008), which makes it more likely that this area will be captured in photographic or video evidence. Ultimately, this means that the area of the hand that shows the greatest amount of variation between individuals is also the area of the hand that is most likely to be captured in evidence. This finding partially corroborates Rosberg and Dahlin (2004), who state that the borders of the hand, such as the index and little fingers, are more likely to sustain trauma. It also agrees with research carried out by Hill *et al.* (1998), who found that the most commonly injured areas of the hand and wrist are the thumb and index finger. No evidence of significantly greater amounts of trauma occurring to the medial border of the hand (little finger) was observed however. No literature to date has discussed such a pattern of trauma, and many previous studies fail to compare specific regions of the hand, and so this finding is potentially extremely important to this field of study.

The lack of significant variation seen in nevi, lentigines and trauma-related features when grid-cells were compared within the hand was another interesting finding in this study. This was seen within both the left and right hands of males and females, and the left and right hands of right- and left-handed individuals. This finding suggests that these features do not show significant variation between different regions within the hand itself, and that their occurrence is uniform. A possible explanation for this is that, in some cases, a large number of individuals possessed no instances of a feature anywhere in one or both hands. It can be seen in Table 4.142 that the number of individuals out of the sample of 260 people possessing zero ephelides in the left or right hand is far lower than the number of individuals possessing zero of any other feature. Ephelides were the only feature that showed significant differences within the hand, and

very few people possessed zero ephelides in the left or right hand. Therefore, the greater number of people possessing zero instances of nevi, lentigines and trauma-related features may have resulted in there being very little variation between grid-cells for these features.

Table 4.142. Incidence of Zero Features

Feature	Left hands	Right hands
Ephelides	9	9
Nevi	249	245
Lentigines	204	190
Tattoos	259	260
Knuckle pads	245	249
Amputation	259	258
Linear scars	133	140
Non-linear scars	207	202
Small scars	147	152
Medium scars	187	195
Large scars	260	260
Extra large scars	260	260
Orientation 1 scars	196	201
Orientation 2 scars	216	223
Orientation 3 scars	209	201
Orientation 4 scars	207	221
Irregular scars	249	250
Surgical scars	259	258
Degloving scars	260	260
Hypertrophic scars	259	260

This study had some limitations. When the sample was subdivided into age cohorts, it was found that there was a bias towards the 30-39 and 40-49 age groups, with less individuals in the 50-59 cohort and very few individuals in the 20-29 and 60-69 cohorts. This was problematic when interpreting the results of statistical analysis on these groups as the sample sizes were so small that it was unreliable to base interpretations of results on them. Additionally, as discussed previously, the reduction of image resolution before data collection was a flawed decision, as it may have resulted in features that were to be

quantified being less visible. This may have impacted on the quality of data gathered, and future studies should avoid this enhancement technique. Additionally, the grid-cells used to separate the hand dorsum were not all of an equal surface area. This difference in relative surface area was not problematic in terms of data collection as the purpose of these cells was to break up large regions into smaller, more manageable zones, in order to allow general patterns in features across the hand to be identified. Another issue that emerged was that some male participants had extensive hair cover on the dorsum of their hands, which sometimes masked pigmentation features, causing their omission from quantification. A solution to this problem in the future may be to ask participants to remove any hair cover before image acquisition, in order to allow clear visualisation of features.

Additionally, the grid-cells that subdivided the hand were not all of an equal surface area. During analysis, this was identified as a possible cause of some unexpected results. In order to assess how the differences in surface area affected quantification of features, a study using normalised data was carried out. The surface area of grid-cells 1, 7, 12, 17 and 21 were measured in a sample of ten random hands. This allowed the relative differences between the surface area of these grid-cells to be calculated. The values of ephelides observed in these grid-cells were then normalised, based on the surface area ratios calculated previously.

Analysis of the variance between the original non-normalised data and the normalised data showed that there was no significant variation in the values seen in the two groups of data. This showed that comparing data from grid-cells of different surface areas did not make any difference to the patterns observed, as even when the data from these grid-

cells was normalised, the values observed did not differ significantly from the original data.

Future work in this field would benefit from a more substantial and unbiased sample population. The database at the University of Dundee is largely composed of serving police officers, with a small number of staff and students from the Centre for Anatomy and Human Identification. Due to a majority of individuals on the database being in the same career, it is possible that certain features and injuries may be more or less common in this population, so it is imperative that a more varied sample from the general population be brought into the image database in order to provide a more realistic sample of the general population. Another important improvement to future work would be changing the way in which lentigines and ephelides are classified. Due to their similar appearance, it is possible that some ephelides were wrongly classified as lentigines, and vice versa. Future studies could solve this problem by having a dermatologist view unclear features, or possibly by simply combining ephelides and lentigines into the same feature category, due to their similar appearance and aetiology. Additionally, the development of a grid that subdivides the hand into grid-cells of approximately equal surface area would also be beneficial to future extensions of this study. Although no significant differences were found when a sample of normalised data was compared to the original data, the author believes that equal grid-cell surface areas would make this data more reliable in future studies.

Ultimately, this study has found that the features seen in the dorsum of the hand can be highly variable, particularly between males and females. Regardless of sex, age or hand dominance, the fingers are significantly different from the dorsal surface of the hand itself. The finding that a corridor exists on the lateral region of the hand where trauma is

more common is of particular interest to forensic investigators, as this suggests a particularly useful area of the hand for forensic identification purposes.

Chapter 5 : References

- Abergel, R. P., Pizzurro, D., Meeker, C. A., Lask, G., Matsuoka, L. Y., Minor, R. R., Chu, M. L. & Uitto, J. (1985) Biochemical composition of the connective tissue in keloids and analysis of collagen metabolism in keloid fibroblast cultures. *Journal of Investigative Dermatology*, 84, (5): 384-390.
- Akdeniz, Y. (2008) *Internet Child Pornography and the Law: National and International Responses*, Surrey: Ashgate Publishing Limited.
- Alonso, P. E., Rioja, L. F. & Pera, C. (2008) Keloids: A viral hypothesis. *Medical Hypotheses*, 70, (1): 156-166.
- Alster, T. S. & Tanzi, E. L. (2003) Hypertrophic scars and keloids: Etiology and management. *American Journal of Clinical Dermatology*, 4, (4): 235-243.
- Alster, T. S. & West, T. B. (1997) Treatment of scars: A review. *Annals of Plastic Surgery*, 39, (4): 418-432.
- Amayeh, G., Bebis, G., Erol, A. & Nicolescu, M. (2009) Hand-based verification and identification using palm–finger segmentation and fusion. *Computer Vision and Image Understanding*, 113, (4): 477-501.
- American Academy of Dermatology (2010) Actinic Keratinosis on Back of Hand [Photograph] Available at: http://www.aad.org/public/publications/pamphlets/sun_actinic.html [Accessed 16/11/2010].
- Angermann, P. & Lohmann, M. (1993) Injuries to the hand and wrist. A study of 50,272 injuries. *Journal of Hand Surgery*, 18, (5): 642-644.
- Aravindakshan Menon, I., Persad, S., Ranadive, N. S. & Haberman, H. F. (1983) Effects of ultraviolet-visible irradiation in the presence of melanin isolated from

human black or red hair upon Ehrlich ascites carcinoma cells. *Cancer Research*, 43, (7): 3165-3169.

Avram, M. R., Tsao, S., Tannous, Z. & Avram, M. M. (2007) *Color Atlas of Cosmetic Dermatology*, China: The McGraw-Hill Companies, Inc.

Awadalla, F., Rosenbaum, D. A., Camacho, F., Fleischer Jr., A. B. & Feldman, S. R. (2008) Dermatologic disease in family medicine. *Family Medicine*, 40, (7): 507-511.

Badrinath, G. S. & Gupta, P. (2009) Robust Biometric System Using Palmprint for Personal Verification. In Tistarelli, M. & Nixon, M. S. (Eds.) *Advances in Biometrics: Third International Conference, ICB 2009*, Berlin: Springer-Verlag. pp 554-565.

Barnhill, R. L. (2004) Circumscribed Pigmented Lesions Composed of Basilar Melanocytes. In Barnhill, R. L., Piepkorn, M. & Busam, K. J. (Eds.) *Pathology of Melanocytic Nevi and Malignant Melanoma*, 2nd edition. Canada: Springer Science+Business Media Inc. pp 37-50.

Barret, J. P., Gomez, P., Solano, I., Gonzalez-Dorrego, M. & Crisol, F. J. (1999) Epidemiology and mortality of adult burns in Catalonia. *Burns*, 25, (4): 325-329.

Bastiaens, M., Hoefnagel, J., Westendorp, R., Vermeer, B. J. & Bouwes Bavinck, J. N. (2004) Solar lentigines are strongly related to sun exposure in contrast to ephelides. *Pigment Cell Research*, 17, (3): 225-229.

Bastiaens, M., ter Huurne, J., Gruis, N., Bergman, W., Westendorp, R., Vermeer, B. J. & Bouwes Bavinck, J. N. (2001) The melanocortin-1-receptor gene is the major freckle gene. *Human Molecular Genetics*, 10, (6): 1701-1708.

Bastiaens, M., Westendorp, R., Vermeer, B. J. & Bouwes Bavinck, J. N. (1999) Ephelides are more related to pigmentary constitutional host factors than solar lentigines. *Pigment Cell Research*, 12, (5): 316-322.

- Bataille, V., Snieder, H., MacGregor, A. J., Sasieni, P. & Spector, T. D. (2000) Genetics of risk factors for melanoma: an adult twin study of nevi and freckles. *Journal of the National Cancer Institute*, 92, (6): 457-463.
- Bauer, J., Curtin, J. A., Pinkel, D. & Bastian, B. C. (2007) Congenital melanocytic nevi frequently harbor NRAS mutations but no BRAF mutations. *Journal of Investigative Dermatology*, 127, (1): 179-182.
- Bayat, A., McGrouther, D. A. & Ferguson, M. W. J. (2003) Skin scarring. *British Medical Journal*, 326, (7380): 88-92.
- Beausang, E., Floyd, H., Dunn, K. W., Orton, C. I. & Ferguson, M. W. J. (1998) A new quantitative scale for clinical scar assessment. *Plastic and Reconstructive Surgery*, 102, (6): 1954-1961.
- Berman, B., Valins, W., Amini, S. & Viera, M. H. (2010) *Keloid and Hypertrophic Scar*. [Online] eMedicine. Available from: <http://emedicine.medscape.com/article/1057599-overview> [Last accessed: 15/06/10]
- Berry, R. (2008) Dissertation: The Potential of Hand Geometry to Reliably Identify Individuals in Forensic Investigations. *Centre for Anatomy and Human Identification*, Dundee, University of Dundee.
- Bevona, C., Goggins, W., Quinn, T., Fullerton, J. & Tsao, H. (2003) Cutaneous melanomas associated with nevi. *Archives of Dermatology*, 139, (12): 1620-1624.
- Bhattacharyya, D., Shrotri, A., Rethrekar, S. C., Patil, M. H., Alisherov, F. A. & Kim, T. (2010) Biometric Authentication Using Infrared Imaging of Hand Vein Patterns. In Bandyopadhyay, S. K., Adi, W., Kim, T. & Xiao, Y. (Eds.) *Information Security and Assurance: 4th International Conference, ISA 2010*, Berlin: Springer-Verlag. pp 108-115.

- Birnbaumer, D. M. (2010) Sexually Transmitted Diseases. In Wolfson, A. B., Hendey, G. W., Ling, L. J., Rosen, C. L., J., S. & Sharieff, G. Q. (Eds.) *Harwood-Nuss' Clinical Practice of Emergency Medicine*, 5th edition. Philadelphia: Lippincott Williams & Wilkins. pp 892-898.
- Black, S., Mallett, X., Rynn, C. & Duffield, N. (2009) Forensic hand image comparison as an aid for paedophile investigations. *Police Professional*, 184, 21-24.
- Blasius, A. L., Brandl, K., Crozat, K., Xia, Y., Khovananth, K., Krebs, P., Smart, N. G., Zampolli, A., Ruggeri, Z. M. & Beutler, B. A. (2009) Mice with mutations of Dock7 have generalized hypopigmentation and white-spotting but show normal neurological function. *Proceedings of the National Academy of Sciences of the United States of America*, 106, (8): 2706-2711.
- Blitzer, H., Stein-Ferguson, K., Huang, J. & Jacobia, J. (2008) *Understanding Forensic Digital Imaging*, London: Elsevier Inc.
- BMEzine.com (2006) Deep Hand Piercing [Photograph] Available at: <http://news.bmezone.com/wp-content/uploads/200601282230-pix1.jpg> [Accessed 04/12/2010].
- Bolle, R. M., Connell, J. H., Pankanti, S., Ratha, N. K. & Senior, A. W. (2004) *Guide to Biometrics*, New York: Springer-Verlag New York, Inc.
- Bombaro, K. M., Engrav, L. H., Carrougher, G. J., Wiechman, S. A., Faucher, L., Costa, B. A., Heimbach, D. M., Rivara, F. P. & Honari, S. (2003) What is the prevalence of hypertrophic scarring following burns? *Burns*, 29, (4): 299-302.
- Boyce, S. & Quigley, M. (2004) Review of sports injuries presenting to an accident and emergency department. *Emergency Medicine Journal*, 21, (6): 704-706.
- Brennen, M., Burge, P., Burke, F., Dias, J., Elliot, D., Hobby, J., Matthewson, M., Savage, R. & Watson, S. (2007) *Hand Surgery in the UK: Manpower*,

resources, standards and training. Report of a working party. The British Society for Surgery of the Hand.

- Brody, G. S., Peng, S. T. J. & Landel, R. F. (1981) The etiology of hypertrophic scar contracture: Another view. *Plastic and Reconstructive Surgery*, 67, (5): 673-684.
- Brown, B. C., Moss, T. P., McGrouther, D. A. & Bayat, A. (2010) Skin scar preconceptions must be challenged: Importance of self-perception in skin scarring. *Journal of Plastic, Reconstructive & Aesthetic Surgery*, 63, (6): 1022-1029.
- Buettner, D. J. (2009) Biometric Sample Synthesis. In Li, S. Z. & Jain, A. K. (Eds.) *Encyclopedia of Biometrics*, New York: Springer Science+Business Media, LLC. pp 116-122.
- Buxton, P. K. & Morris-Jones, R. (2009) *ABC of Dermatology*, 5th edition. Chichester: Blackwell Publishing Ltd.
- Campbell, B. J. & Campbell, D. J. (2003) Care of Acute Lacerations. In Taylor, R. B., David, A. K., Fields, S. A., Phillips, D. M. & Scherger, J. E. (Eds.) *Family Medicine: Principles and Practice*, 6th edition. New York: Springer-Verlag New York, Inc. pp 416-428.
- Carr, J. (2003) Child Abuse, Child Pornography and the Internet. Action for Children.
- Carrell, S. (2009) *Scottish paedophile ring found guilty of more than 50 charges.*
[Online] The Guardian. Available from:
<http://www.guardian.co.uk/uk/2009/may/07/scottish-paedophile-ring-guilty-child-abuse> [Last accessed: 26/10/2010]
- Carton, J., Daly, R. & Ramani, P. (2007) *Clinical Pathology*, Oxford: Oxford University Press.
- Cassell, D. & Rose, N. (2003) *The Encyclopedia of Autoimmune Diseases*, New York: Facts on File, Inc.

- Cheng, E. K. & Yoon, A. H. (2005) Does Frye or Daubert Matter? A Study of Scientific Admissibility Standards. *Virginia Law Review*, 91, 471-514.
- Cheng, J. C. Y., Lam, Z. C. L., Leung, P. C. & Mak, D., P. (1990) An epidemiological study on burn injuries in Hong Kong. *Journal of the Hong Kong Medical Association*, 42, (1): 26-28.
- Choraś, M. & Kozik, R. (2010) Knuckle biometrics for human identification. *Image Processing and Communications Challenges 2: Advances in Soft Computing*, 84, 91-98.
- Chung, J. H. (2003) Photoaging in Asians. *Photodermatology, Photoimmunology & Photomedicine*, 19, (3): 109-121.
- Clarkson, J. & Schaefer, M. (2007) Surgical Intervention. In Thompson, T. & Black, S. (Eds.) *Forensic Human Identification: An Introduction*, Boca Raton: CRC Press. pp 127-146.
- Cole, S. A. (2002) *Suspect Identities: A History of Fingerprinting and Criminal Identification*, 2nd edition. Harvard: First Harvard University Press.
- Colton, C., Nuñez, F., Fricker, R. & Kastelec, M. (n.d.) Hand phalanges [Image]
Available at:
<http://da01ti10.aofoundation.org/wps/portal/surgery?showPage=approach&contentUrl=srg/78/04-Approaches/01-phalanges/07-appr-dorsal-dip.jsp&bone=Hand&segment=Phalanges&approach=Dorsal%20to%20the%20DIP%20joint&Language=en> [Accessed 27/10/2010].
- Cooper, J. E. & Cooper, M. E. (2007) *Introduction to Veterinary and Comparative Forensic Medicine*, Oxford: Blackwell Publishing Ltd.
- Craft, N., Fox, L. P., Goldsmith, L. A., Papier, A., Birnbaum, R., Mercurio, M. G., Miller, D., Rajendran, R., Rosenblum, M., Taylor, E. & Tumeh, P. C. (2010)

VisualDx: Essential Adult Dermatology, Philadelphia: Lippincott Williams & Wilkins.

Cullen, M. K., Boissy, R. E., Hearing, V. J., King, R. A., Oetting, W. S. & Ortonne, J.-P. (2006) Genetic Epidermal Pigmentation with Lentigines. In Nordlund, J. J. (Ed.) *The Pigmentary System*, 2nd edition. Massachusetts: Blackwell Publishing Ltd. pp 824-872.

Danderm (n.d.) Vitiligo [Photograph] Available at: <http://www.danderm-pdv.is.kkh.dk/atlas/pics/4/4-162-1.jpg> [Accessed 04/12/2010].

Darlington, S., Siskind, V., Green, L. & Green, A. (2002) Longitudinal study of melanocytic nevi in adolescents. *Journal of the American Academy of Dermatology*, 46, (5): 715-722.

Daubert v. Merrel Dow Pharmaceuticals [1993] (92-102), 509 U.S. 579.

Davies, D. M. (1985) Scars, hypertrophic scars, and keloids. *Plastic and Reconstructive Surgery*, 290, 1056-1058.

Dermatology Associates of Plymouth Meeting, P. C. (2010) Atypical Mole [Photograph] Available at: <http://www.daopm.com/moles.htm> [Accessed 16/11/2010].

DermNet.com (2010) Psoriasis - Hand, fingers Available at: <http://www.lib.uiowa.edu/hardin/md/dermnet/psoriasis45.html> [Accessed 16/11/2010].

DermNetNZ (2010a) Knuckle1 [Photograph] Available at: <http://dermnetnz.org/common/image.php?path=/scaly/img/knuckle1.jpg> [Accessed 02/08/2010].

DermNetNZ (2010b) Knuckle3 [Photograph] Available at: <http://dermnetnz.org/common/image.php?path=/scaly/img/knuckle3.jpg> [Accessed 02/08/2010].

DermNetNZ (2010c) Hypertrophic scar 2 [Photograph] Available at:

<http://dermnetnz.org/common/image.php?path=/dermal-infiltrative/img/hypertrophic-scar2.jpg> [Accessed 04/08/2010].

Diao, E. (2002) Arthrodesis. In Fitzgerald, R. H., Kaufer, H. & Malkani, A. L. (Eds.) *Orthopaedics*, St. Louis: Mosby, Inc. pp 1848-1858.

Dias, J. J. & Garcia-Elias, M. (2006) Hand injury costs. *Injury*, 37, (11): 1071-1077.

Dickson, J. K., Morris, G. & Heron, M. (2009) The importance of hand anatomy in the accident and emergency department: Assessment of hand anatomy knowledge in doctors in training. *The Journal of Hand Surgery: European Volume*, 34, (5): 682-684.

Diffey, B. (2006) The contribution of medical physics to the development of psoralen photochemotherapy (PUVA) in the UK: A personal reminiscence. *Physics in Medicine and Biology*, 51, (13): 229-244.

Doughty, D. B. & Sparks-Defriese, B. (2007) Wound-Healing Physiology. In Bryant, R. A. & Nix, D. P. (Eds.) *Acute & Chronic Wounds: Current Management Concepts*, 3rd edition. St. Louis: Mosby, Inc. pp 56-81.

Doyle, J. R., Tornetta, P. & Einhorn, T. A. (2006) *Hand and Wrist*, Philadelphia: Lippincott Williams & Wilkins.

Dr. P Marazzi/Science Photo Library (2010) Solar Lentigine [Photograph] Available at: <http://www.sciencephoto.com/images/imagePopUpDetails.html?pop=1&id=772000274&pviewid=&country=67&search=age+AND+spot&matchtype=FUZZY> [Accessed 30/07/2010].

Draaijers, L. J., Tempelman, F. R., Botman, Y. A., Tuinebreijer, W. E., Middelkoop, E., Kreis, R. W. & van Zuijlen, P. P. (2004) The patient and observer scar assessment scale: a reliable and feasible tool for scar evaluation. *Plastic and Reconstructive Surgery*, 113, (7): 1960-1965.

- Du Vivier, A. (2002) *Atlas of Clinical Dermatology*, 3rd edition. Philadelphia: Churchill Livingstone.
- English, D. R. & Armstrong, B. K. (1994) Melanocytic nevi in children. I. Anatomic sites and demographic and host factors. *American Journal of Epidemiology*, 139, (4): 390-401.
- Feasel, A. M. (2007) Corns and Calluses. In Arndt, K. A. & Hsu, J. T. S. (Eds.) *Manual of Dermatologic Therapeutics*, 7th edition. Philadelphia: Lippincott Williams & Wilkins. pp 46-48.
- Federal Rule of Evidence 702* [2000]
- Feldman, S. R., Fleischer Jr., A. B. & McConnell, R. C. (1998) Most common dermatologic problems identified by internists, 1990-1994. *Archives of Internal Medicine*, 158, (7): 726-730.
- Ferguson, M. W., Whitby, D. J., Shah, M., Armstrong, J., Siebert, J. W. & Longaker, M. T. (1996) Scar formation: The spectral nature of fetal and adult wound repair. *Plastic & Reconstructive Surgery*, 97, (4): 854-860.
- Ferri, F. F. (2009) *Ferri's Color Atlas and Text of Clinical Medicine*, Philadelphia: Saunders.
- Florida Skin Center (2010) Vitiligo [Photograph] Available at: http://www.floridaskincenter.com/images/vitiligo_hands.jpg [Accessed 04/12/2010].
- Foy, M. & Foreman, L. C. (2006) Bacterial Infections of the Skin. In Arcangelo, V. P. & Peterson, A. M. (Eds.) *Pharmacotherapeutics for Advanced Practice: A Practical Approach*, 2nd edition. Philadelphia: Lippincott Williams & Wilkins. pp 130-142.
- Frye v. United States* [1923] 293 F. 1013.

- Galloway, V. & Charlton, D. (2007) Fingerprints. In Thompson, T. & Black, S. (Eds.) *Forensic Human Identification: An Introduction*, Boca Raton: CRC Press. pp 57-72.
- Gangopadhyay, S. & Packer, G. (2003) A comparative study between longitudinal and "T" incisions for dorsal plating of the distal radius. *Journal of Hand Surgery*, 28, (6): 568-570.
- Gershenwald, J. E. & Hwu, P. (2010) Melanoma. In Hong, W. K., Bast, R. C., Hait, W. N., Kufe, D. W., Pollock, R. E., Weichselbaum, R. R., Holland, J. F. & Frei, E. (Eds.) *Holland-Frei Cancer Medicine*, 8th edition. Shelton: People's Medical Publishing House-USA. pp 1459-1486.
- Gold, M. H., Foster, T. D., Adair, M. A., Burlison, K. & Lewis, T. (2001) Prevention of hypertrophic scars and keloids by the prophylactic use of topical silicone gel sheets following a surgical procedure in an office setting. *Dermatologic Surgery*, 27, (7): 641-644.
- Green, A., Siskind, V. & Green, A. (1995) The incidence of melanocytic naevi in adolescent children in Queensland, Australia. *Melanoma Research*, 5, (3): 155-160.
- Green, A. & Swerdlow, A. J. (1989) Epidemiology of melanocytic nevi. *Epidemiologic Review*, 11, 204-221.
- Gregory, P. & Simon, M. A. (2008) *Biometrics for Dummies*, Indianapolis: Wiley Publishing, Inc.
- Groenevelt, F. & Kreis, R. W. (1985) Burns of the hand. *Netherlands Journal of Surgery*, 37, (6): 167-173.
- Grossman, D. & Guzzo, C. (2000) The Skin. In Mangione, S. (Ed.) *Physical Diagnosis Secrets*, Philadelphia: Henley & Belfus, Inc. pp 35-68.

- Gudjonsson, J. E. & Elder, J. T. (2008) Psoriasis. In Wolff, K., Goldsmith, L. A., Katz, S. I., Gilchrist, B. A., Paller, A. S. & Leffell, D. J. (Eds.) *Fitzpatrick's Dermatology in General Medicine*, 7th edition. London: The McGraw-Hill Companies, Inc. pp 169-193.
- Hafner, C., Stoehr, R., van Oers, J. M., Zwarthoff, E. C., Hofstaedter, F., Landthaler, M., Hartmann, A. & Vogt, T. (2009) FGFR3 and PIK3CA mutations are involved in the molecular pathogenesis of solar lentigo. *British Journal of Dermatology*, 160, (3): 546-551.
- Hardy, M. A. (1989) The biology of scar formation. *Physical Therapy*, 69, (12): 1014-1024.
- Harris, J. & Grace, S. (1999) A question of evidence? Investigating and prosecuting rape in the 1990s. Home Office Research Study 196, Home Office.
- Harrison, S. L., Buettner, P. G. & MacLennan, R. (1999) Body-site distribution of melanocytic nevi in young Australian children. *Archives of Dermatology*, 135, (1): 47-52.
- Healy, E. (2004) Melanocortin 1 receptor variants, pigmentation, and skin cancer susceptibility. *Photodermatology, Photoimmunology & Photomedicine*, 20, (6): 283-288.
- Hennessy, A., Oh, C., Diffey, B., Wakamatsu, K., Ito, S. & Rees, J. (2005) Eumelanin and pheomelanin concentrations in human epidermis before and after UVB irradiation. *Pigment Cell Research*, 18, (3): 220-223.
- Hill, C., Riaz, M., Mozzam, A. & Brennen, M. D. (1998) A regional audit of hand and wrist injuries: A study of 4873 injuries. *Journal of Hand Surgery*, 23, (2): 196-200.
- Ho, W. S. & Ying, S. Y. (2001) An epidemiological study of 1063 hospitalized burn patients in a tertiary burns centre in Hong Kong. *Burns*, 27, (2): 119-123.

- Hoffman, D. L., Novak, T. P. & Venkatesh, A. (2004) Has the internet become indispensable? *Communications of the ACM*, 47, (7): 37-42.
- Holden, M. (2010) *NSPCC says extent of child sex offences "shocking"*. [Online] Reuters. Available from:
<http://uk.reuters.com/article/idUKTRE60O1WF20100125> [Last accessed: 30/06/10]
- Holmes, J. H. & Heimbach, D. M. (2006) Burns. In Brunnicardi, F. C., Billiar, T. R., Dunn, D. L., Hunter, J. G. & Pollock, R. E. (Eds.) *Schwartz's Manual of Surgery*, 8th edition. USA: The McGraw-Hill Companies, Inc. pp 138-164.
- Horton, T. C., Dias, J. J. & Burke, F. D. (2007) Social deprivation and hand injury. *Journal of Hand Surgery*, 32, (3): 256-261.
- House of Commons Science and Technology Committee (2005) Forensic Science on Trial: Seventh Report of Session 2004-5.
- Huggins, I. D. (2010) Thesis: The Quantification of Familial Variation in Hand Morphology. *Centre for Anatomy and Human Identification*, Dundee, University of Dundee.
- Ichihashi, M., Ando, H., Yoshida, M., Niki, Y. & Matsui, M. (2009) Photoaging of the skin. *Journal of Anti-Aging Medicine*, 6, (6): 46-59.
- Jain, A., Hong, L. & Bolle, R. (1997) On-line fingerprint verification. *IEEE Transactions on Pattern Analysis and Machine Intelligence*, 19, (4): 302-314.
- Jenkins, P. (2001) *Beyond Tolerance: Child Pornography on the Internet*, New York: New York University Press.
- Johr, R. H. & Schachner, L. A. (2002) Nevocellular (Melanocytic) Nevi. In Finberg, L. & Kleinman, R. E. (Eds.) *Saunders Manual of Pediatric Practice*, 2nd edition. Philadelphia: W. B. Saunders Company. pp 1067-1068.

- Kahan, S., Miller, R. & Smith, E. G. (2009) *In A Page: Signs and Symptoms*, 2nd edition. Baltimore: Lippincott Williams & Wilkins.
- Kamolz, L. P., Kitzinger, H. B., Karle, B. & Frey, M. (2009) The treatment of hand burns. *Burns*, 35, (3): 327-337.
- Kane, K. S., Ryder, J. B., Johnson, R. A., Baden, H. P. & Stratigos, A. (2002) *Color Atlas & Synopsis of Pediatric Dermatology*, U.S.A.: McGraw-Hill Companies, Inc.
- Kawada, A., Shiraishi, H., Asai, M., Kameyama, H., Sangen, Y., Aragane, Y. & Tezuka, T. (2002) Clinical improvement of solar lentigines and ephelides with an intense pulsed light source. *Dermatologic Surgery*, 28, (6): 504-508.
- Keller, G. S. & Lacombe, V. G. (2001) Laser Resurfacing: An Overview. In Keller, G. S., Lacombe, V. G., Lee, P. K. & Watson, J. P. (Eds.) *Lasers in Aesthetic Surgery*, New York: Thieme. pp 41-66.
- Kennedy, C., Bajdik, C. D., Willemze, R., De Gruijl, F. R. & Bouwes Bavinck, J. N. (2003) The influence of painful sunburns and lifetime sun exposure on the risk of actinic keratoses, seborrheic warts, melanocytic nevi, atypical nevi, and skin cancer. *Journal of Investigative Dermatology*, 120, (6): 1087-1093.
- Kim, S. H., Kim, S., Choi, H. I., Choi, Y. J., Lee, Y. S., Sohn, K. C., Lee, Y., Kim, C. D., Yoon, T. J., Lee, J. H. & Lee, Y. H. (2010) Callus formation is associated with hyperproliferation and incomplete differentiation of keratinocytes, and increased expression of adhesion molecules. *British Journal of Dermatology*, 163, (3): 495-501.
- Kizza, J. M. (2010) *Ethical and Social Issues in the Information Age*, 4th edition. London: Springer-Verlag London Limited.
- Kondekar, M. H., Chowhan, S. S. & Kulkarni, U. V. (2010) Bayesian Regularization BPTA for Fingerprint Authentication. In Kale, K. V., Mehrotra, S. C. & Manza,

- R. R. (Eds.) *Computer Vision and Information Technology: Advances and Applications*, New Delhi: I. K. International Publishing House Pvt. Ltd. pp 334-341.
- Krowchuk, D. P. & Tunnessen Jr., W. W. (2006) Pediatric Dermatology. In McMillan, J. A., Feigin, R. D., DeAngelis, C. D. & Jones Jr., M. D. (Eds.) *Oski's Pediatrics: Principles and Practice*, 4th edition. Philadelphia: Lippincott Williams & Wilkins. pp 827-878.
- Krueger, G. & Ellis, C. N. (2005) Psoriasis--recent advances in understanding its pathogenesis and treatment. *Journal of the American Academy of Dermatology*, 53, (1): 94-100.
- Kumar, A., Mundra, T. S. & Kumar, A. (2009) Anatomy of Hand. In Li, S. Z. & Jain, A. K. (Eds.) *Encyclopedia of Biometrics*, New York: Springer Science+Business Media, LLC. pp 28-35.
- Kumar, A., Wong, D. C. M., Shen, H. C. & Jain, A. K. (2003) Personal verification using palmprint and hand geometry biometric. *Lecture Notes in Computer Science: International Conference on Audio- and Video-Based Biometric Person Authentication*, 2688, 668-678.
- Kumar, A. & Zhou, Y. (2009) Personal identification using finger knuckle orientation features. *Electronics Letters*, 45, (20): 1023-1025.
- L'Oréal (n.d.) Freckles [Image] Available at: http://www.loreal.com/en/ww/loreal-skin-science/desordres_cutanes/desordres_epidermiques.aspx [Accessed 16/11/2010].
- Lapid, O. & Sagi, A. (2005) Three-square-flip-flap reconstruction for post burn syndactyly. *British Journal of Plastic Surgery*, 58, (6): 826-829.

- Larsen, C. F., Mulder, S., Johansen, A. M. & Stam, C. (2004) The epidemiology of hand injuries in The Netherlands and Denmark. *European Journal of Epidemiology*, 19, (4): 323-327.
- Laumann, A. E. & Derick, A. J. (2006) Tattoos and body piercings in the United States: a national data set. *Journal of the American Academy of Dermatology*, 55, (3): 413-421.
- Lese, A. B. & Kulkarni, R. (2008) *Soft Tissue Hand Injury*. [Online] eMedicine. Available from: <http://emedicine.medscape.com/article/826498-overview#a0104> [Last accessed: 14/04/2011]
- Leung, D. Y., Boguniewicz, M., Howell, M. D., Nomura, I. & Hamid, Q. A. (2004) New insights into atopic dermatitis. *The Journal of Clinical Investigation*, 113, (5): 651-657.
- Leung, D. Y. M., Eichenfield, L. F. & Boguniewicz, M. (2008) Atopic Dermatitis (Atopic Eczema). In Wolff, K., Goldsmith, L. A., Katz, S. I., Gilchrist, B. A., Paller, A. S. & Leffell, D. J. (Eds.) *Fitzpatrick's Dermatology in General Medicine*, 7th edition. London: The McGraw-Hill Companies, Inc. pp 146-158.
- Li, M., Lin, S. C. & B., C. A. (2007) *Blueprints Clinical Cases in Surgery*, Baltimore: Lippincott Williams & Wilkins.
- Lloyd, G. J. (1985) Acute management for the injured hand. *Canadian Family Physician*, 31, 557-559.
- Logical Images Inc. (2009a) Herpetic Whitlow Available at: <http://www.skindsight.com/child/herpesSimplexVirusHSV.htm> [Accessed 17/11/2010].
- Logical Images Inc. (2009b) Solar Lentigo [Photograph] Available at: <http://www.skindsight.com/adult/solarLentigo.htm> [Accessed 30/07/2010].

- Logical Images Inc. (2009c) Mole, Atypical (Atypical Nevus) [Photograph] Available at: <http://www.skindsight.com/adult/atypicalNevus.htm> [Accessed 30/07/2010].
- Logical Images Inc. (2009d) Keloid [Photograph] Available at: <http://www.skindsight.com/adult/keloid.htm> [Accessed 04/08/2010].
- Logical Images Inc. (2009e) Normal Nevus [Photograph] Available at: <http://www.skindsight.com/adult/nevus.htm> [Accessed 19/11/2010].
- Lucy, D. (2010) The Presentation of Results and Statistics for Legal Purposes. In Black, S., Aggrawal, A. & Payne-James, J. (Eds.) *Age Estimation in the Living: The Practitioner's Guide*, Chichester: Wiley-Blackwell. pp 267-283.
- Machesney, M., Tidman, N., Waseem, A., Kirby, L. & Leigh, I. (1998) Activated keratinocytes in the epidermis of hypertrophic scars. *American Journal of Pathology*, 152, (5): 1133-1141.
- Macintyre, L. & Baird, M. (2006) Pressure garments for use in the treatment of hypertrophic scars--a review of the problems associated with their use. *Burns*, 32, (1): 10-15.
- Mackenzie, K. & Peters, M. (2000) Handedness, hand roles, and hand injuries at work. *Journal of Safety Research*, 31, (4): 221-227.
- Mallett, X. (2010) Admissibility. In Evison, M. P. & Bruegge, R. W. V. (Eds.) *Computer-Aided Forensic Facial Comparison*, Boca Raton: CRC Press. pp 139-143.
- Maltoni, D., Maio, D., Jain, A. K. & Prabhakar, S. (2009) *Handbook of Fingerprint Recognition*, 2nd edition. London: Springer-Verlag.
- Mayers, L. B. & Chiffriller, S. H. (2008) Body art (body piercing and tattooing) among undergraduate university students: "Then and now". *Journal of Adolescent Health*, 42, (2): 201-203.

- Mayers, L. B., Judelson, D. A., Moriarty, B. W. & Rundell, K. W. (2002) Prevalence of body art (body piercing and tattooing) in university undergraduates and incidence of medical complications. *Mayo Clinic Proceedings*, 77, (1): 29-34.
- McKee, P. H. & Calonje, E. (2009) *Diagnostic Atlas of Melanocytic Pathology*, China: Elsevier Inc.
- Meding, B. & Järholm, B. (2004) Incidence of hand eczema-a population-based retrospective study. *Journal of Investigative Dermatology*, 122, (4): 873-877.
- Metropolitan Police (2009) *Freckles Prove Child Abuse*. [Online] Available from: http://cms.met.police.uk/news/convictions/freckles_prove_child_abuse [Last accessed: 26/10/2010]
- Mitchell, T. & Penzer, R. (2004) *Psoriasis At Your Fingertips*, London: Class Publishing Ltd.
- Mollin, R. A. (2001) *An Introduction to Cryptography*, 2nd edition. Boca Raton: CRC Press.
- Monestier, S., Gaudy, C., Gouvernet, J., Richard, M. A. & Grob, J. J. (2006) Multiple senile lentigos of the face, a skin ageing pattern resulting from life excess of intermittent sun exposure in dark-skinned caucasians: a case-control. *British Journal of Dermatology*, 154, (3): 438-444.
- Mooney, L. A., Knox, D. & Schacht, C. (2010) *Understanding Social Problems*, 7th edition. California: Wadsworth.
- Mortz, C. G., Lauritsen, J. M., Bindslev-Jensen, C. & Andersen, K. E. (2001) Prevalence of atopic dermatitis, asthma, allergic rhinitis, and hand and contact dermatitis in adolescents. The Odense adolescence cohort study on atopic diseases and dermatitis. *British Journal of Dermatology*, 144, (3): 523-532.

- Musgrave, M. A., Umraw, N., Fish, J. S., Gomez, M. & Cartotto, R. C. (2002) The effect of silicone gel sheets on perfusion of hypertrophic burn scars. *Journal of Burn Care & Rehabilitation*, 23, (3): 208-214.
- Nadort, A. (2007) *The Hand Vein Pattern Used as a Biometric Feature*. Masters Thesis, Free University of Amsterdam, Amsterdam.
- Naldi, L. & Chalmers, R. J. G. (2008) Psoriasis. In Williams, H., Bigby, M., Diepgen, T., Herxheimer, A., Naldi, L. & Rzany, B. (Eds.) *Evidence-Based Dermatology*, 2nd edition. Massachusetts: Oxford. pp 171-188.
- Nambudripad, D. S. (2008) *Freedom From Eczema*, California: Delta Publishing.
- Narinesingh, S. & Mahmoud, M. (2008) Common Hand Surgery Procedures. In Cheema, M., Ali, S. N. & Rajaratnam, V. (Eds.) *Understanding Hand Surgery: A Guide for Junior Doctors*, Unknown: V. Rajaratnam. pp 61-96.
- National Policing Improvement Agency (2009) Facial Identification Guidance. Association of Chief Police Officers.
- Netscher, D. T. & Gharbaoui, I. (2007) Hand and Upper Extremities. In Britt, L. D., Trunkey, D. D. & Feliciano, D. V. (Eds.) *Acute Care Surgery: Principles and Practice*, New York: Springer Science+Business Media, LLC. pp 615-655.
- NHS (2010a) Psoriasis [Image] Available at: <http://www.whittington.nhs.uk/default.asp?c=7886&t=1,151,7877> [Accessed 28/10/2010].
- NHS (2010b) Eczema [Image] Available at: <http://www.whittington.nhs.uk/default.asp?c=7886&t=1,151,7877> [Accessed 28/10/2010].
- Nicholls, E. M. (1973) Development and elimination of pigmented moles, and the anatomical distribution of primary malignant melanoma. *Cancer*, 32, (1): 191-195.

- Niessen, F. B., Spauwen, P. H., Schalkwijk, J. & Kon, M. (1999) On the nature of hypertrophic scars and keloids: A review. *Plastic and Reconstructive Surgery*, 104, (5): 1435-1458.
- O'Sullivan, S. T., O'Shaughnessy, M. & O'Connor, T. P. F. (1996) Aetiology and management of hypertrophic scars and keloids. *Annals of the Royal College of Surgeons of England*, 78, (3): 168-175.
- Ogawa, R., Akaishi, S. & Kinoshita, K. (2010) Treatments for Post-Burn Hypertrophic Scars. In Hyakusoku, H., Orgill, D. P., Teot, L., Pribaz, J. J. & Ogawa, R. (Eds.) *Color Atlas of Burn Reconstructive Surgery*, Berlin: Springer Verlag. pp 76-81.
- Pavlotsky, F., Azizi, E., Gurvich, R., Lusky, A., Barell, V., Weiner, M. & Iscovich, J. (1997) Prevalence of melanocytic nevi and freckles in young Israeli males. Correlation with melanoma incidence in Jewish migrants: Demographic and host Factors. *American Journal of Epidemiology*, 146, (1): 78-86.
- Pekkarinen, A., Salminen, S. & Järvelin, M.-J. (2003) Hand preference and risk of injury among the Northern Finland birth cohort at the age of 30. *Laterality: Assymetries of Body, Brain and Cognition*, 8, (4): 339-346.
- Prasad, M. V. N. K., Kumar, M. K. P. & Sharma, K. (2009) Classification of palmprint using principle line. *Information Systems, Technology and Management: Communications in Computer and Information Science*, 31, (8): 208-219.
- Pray, W. S. (2006) *Nonprescription Product Therapeutics*, 2nd edition. Maryland: Lippincott Williams & Wilkins.
- Pruitt Jr., B. A., Wolf, S. E. & Mason Jr., A. D. (2007) Epidemiological, Demographic, and Outcome Characteristics of Burn Injury. In Herndon, D. N. (Ed.) *Total Burn Care*, 3rd edition. Philadelphia: Saunders Elsevier. pp 14-32.

- Rajendran, R. (2009) Benign and Malignant Tumors of the Oral Cavity. In Rajendran, R. & Sivapathasundharam, B. (Eds.) *Shafer's Textbook of Oral Pathology*, 6th edition. Noida: Elsevier. pp 80-218.
- Rampen, F. H., Fleuren, B. A., de Boo, T. M. & Lemmens, W. A. (1988) Prevalence of common "acquired" nevocytic nevi and dysplastic nevi is not related to ultraviolet exposure. *Journal of the American Academy of Dermatology*, 18, (4): 679-683.
- Ranadive, N. S., Shirwadkar, S., Persad, S. & Menon, I. A. (1986) Effects of melanin-induced free radicals on the isolated rat peritoneal mast cells. *Journal of Investigative Dermatology*, 86, (3): 303-307.
- Regina v T* [2010] EWCA Crim 2439.
- Rendon, M. I. (2008) Skin-Lightening Agents. In Grimes, P. E. (Ed.) *Aesthetics and Cosmetic Surgery for Darker Skin Types*, Philadelphia: Lippincott Williams & Wilkins. pp 73-81.
- Rizzo, M. & Cooney, W. P. (2009) Principles of Hand Incisions. In Moran, S. L. & Cooney, W. P. (Eds.) *Soft Tissue Surgery*, Baltimore: Lippincott Williams & Wilkins. pp 169-178.
- Robertson, J. (2009) *Horror upon horror that unfolded in 'worst ever' abuse trial*. [Online] The Scotsman. Available from: <http://thescotsman.scotsman.com/scotland/Horror-upon-horror-that-unfolded.5247628.jp> [Last accessed: 26/10/2010]
- Romo, T., Pearson, J. M., Yalamanchili, H. & Zoumalan, R. A. (2008) *Wound Healing, Skin*. [Online] eMedicine. Available from: <http://emedicine.medscape.com/article/884594-overview> [Last accessed: 17/06/10]

- Rosberg, H. E. & Dahlin, L. B. (2004) Epidemiology of hand injuries in a middle-sized city in southern Sweden: A retrospective comparison of 1989 and 1997. *Scandinavian Journal of Plastic and Reconstructive Surgery and Hand Surgery*, 38, (6): 347-355.
- Roseborough, I. E., Grevious, M. A. & Lee, R. C. (2004) Prevention and treatment of excessive dermal scarring. *Journal of the National Medical Association*, 96, (1): 108-116.
- Rosistem (n.d.) *Hand/Finger Geometry*. [Online] Available from: http://www.barcode.ro/tutorials/biometrics/hand_geometry.html [Last accessed: 22/10/2010]
- Ross, D. J., Smith, M. E. & Angarita, G. (1985) Hand injury in the accident and emergency service. *Archives of Emergency Medicine*, 2, (3): 155-160.
- Rudin, N. & Inman, K. (2002) *An Introduction to Forensic DNA Analysis*, 2nd edition. Boca Raton: CRC Press.
- Rudolph, R. (1987) Wide spread scars, hypertrophic scars, and keloids. *Clinics in Plastic Surgery*, 14, (2): 253-260.
- Rusciani, L., Paradisi, A. & Rusciani, A. (2008) Keloid Therapy. In Rusciani, L. & Robins, P. (Eds.) *Textbook of Dermatologic Surgery: Vol. 2*, Padova: Piccin. pp 863-874.
- Rutty, G. N. (2007) Soft Tissue Trauma. In Thompson, T. & Black, S. (Eds.) *Forensic Human Identification*, Boca Raton: CRC Press. pp 113-126.
- Sagoo, G. S., Cork, M. J., Patel, R. & Tazi-Ahnini, R. (2004) Genome-wide studies of psoriasis susceptibility loci: a review. *Journal of Dermatological Science*, 35, (3): 171-179.

- Salter, M. (2000) Function of the Hand. In Salter, M. & Cheshire, L. (Eds.) *Hand Therapy: Principles and Practice*, Oxford: Reed Educational and Professional Publishing Ltd. pp 3-12.
- Sarna, T. & Plonka, P. M. (2005) Biophysical Studies of Melanin: Paramagnetic, Ion-Exchange and Redox Properties of Melanin Pigments and Their Photoreactivity. In Eaton, S. S., Eaton, G. R. & Berliner, L. J. (Eds.) *Biomedical EPR-Part A: Free Radicals, Metals, Medicine, and Physiology*, New York: Kluwer Academic/Plenum Publishers. pp 125-146.
- Scambler, A. (2008) Women and Health. In Scambler, G. (Ed.) *Sociology as Applied to Medicine*, 6th edition. London: Saunders Elsevier. pp 133-158.
- Scar Treatment Blog (2009) Keloid scar [Photograph] Available at: <http://scartreatments.wordpress.com/tag/scar-removal/page/2/> [Accessed 04/08/2010].
- Science Photo Library (2010) Solar Lentigine [Photograph] Available at: <http://www.sciencephoto.com/images/imagePopUpDetails.html?pop=1&id=772000274&pviewid=&country=67&search=age+AND+spot&matchtype=FUZZY> [Accessed 30/07/2010].
- Semchyshyn, N. L. & Sengelmann, R. D. (2009) Dermatologic Surgical Complications [Image] Available at: <http://emedicine.medscape.com/article/1128404-overview> [Accessed 28/10/2010].
- Semer, N. B. (2001) *Practical Plastic Surgery for Nonsurgeons*, Philadelphia: Hanley & Belfus, Inc.
- Sexual Offences Act (2003).
- Sharpe, F. & Stevanovic, M. (2000) Hand. In Jordan, C. & Mirzabeigi, E. (Eds.) *Atlas of Orthopaedic Surgical Exposures*, New York: Thieme Medical Publishers Inc. pp 80-102.

- Shetty, V. & Bertolami, C. N. (2004) Wound Healing. In Miloro, M., Larsen, P. E. & Waite, P. D. (Eds.) *Peterson's Principles of Oral and Maxillofacial Surgery: Volume 1*, 2nd edition. Hamilton: BC Decker Inc. pp 3-16.
- Simandl, G. (2007) Structure and Function of the Skin. In Porth, C. M. (Ed.) *Essentials of Pathophysiology: Concepts of Altered Health States*, 2nd edition. Philadelphia: Lippincott Williams & Wilkins. pp 1047-1056.
- Skinsight (2008) *Herpes Simplex Virus (HSV): A Parent's Guide to Condition and Treatment Information*. [Online] Available from: <http://www.skindsight.com/child/herpesSimplexVirusHSV.htm> [Last accessed: 17/11/2010]
- Sorock, G. S., Lombardi, D. A., Hauser, R. B., Eisen, E. A., Herrick, R. F. & Mittleman, M. A. (2001) A case-crossover study of occupational traumatic hand injury: Methods and initial findings. *American Journal of Industrial Medicine*, 39, (2): 171-179.
- Spaun, N. A. (2007) Forensic Biometrics from Images and Video at the Federal Bureau of Investigation. *IEEE Conference on Biometrics: Theory, Applications and Systems*. Washington DC.
- Srihari, S. N., Srinivasan, H. & Fang, G. (2008) Discriminability of fingerprints of twins. *Journal of Forensic Identification*, 58, (1): 109-127.
- Stanley, J. (2001) Child Abuse and the Internet. Child Abuse Prevention Issues, Australian Government.
- Steadman, D. W., Adams, B. J. & Konigsberg, L. W. (2006) Statistical basis for positive identification in forensic anthropology. *American Journal of Physical Anthropology*, 131, (1): 15-26.
- Steingrímsson, E., Copeland, N. G. & Jenkins, N. A. (2005) Melanocyte stem cell maintenance and hair graying. *Cell*, 121, (1): 9-12.

- Sterry, W., Paus, R. & Burgdorf, W. (2006) *Dermatology*, New York: Thieme.
- Stier, M. F. & Hirsch, R. J. (2009) Rejuvenation of Scars and Striae. In Hirsch, R. J., Sadick, N. & Cohen, J. L. (Eds.) *Aesthetic Rejuvenation: A Regional Approach*, China: McGraw-Hill Professional. pp 210-234.
- Su, W. H., Cheng, M. H., Lee, W. L., Tsou, T. S., Chang, W. H., Chen, C. S. & Wang, P. H. (2010) Nonsteroidal anti-inflammatory drugs for wounds: Pain relief or excessive scar formation? *Mediators of Inflammation*, 2010, 1-8.
- Sussman, C. (2006) Assessment of the skin and wound. In Sussman, C. & Bates-Jensen, B. M. (Eds.) *Wound care: A collaborative practice manual for health professionals*, 3rd edition. Baltimore: Lippincott Williams & Wilkins. pp 85-122.
- Tannous, Z. S., Mihm, M. C., Sober, A. J. & Duncan, L. M. (2005) Congenital melanocytic nevi: clinical and histopathologic features, risk of melanoma, and clinical management. *Journal of the American Academy of Dermatology*, 52, (2): 197-203.
- Taylor, M. & Quayle, E. (2006) *Child Pornography: An Internet Crime*, East Sussex: Routledge.
- The Law Commission (2009) *The Admissibility of Expert Evidence in Criminal Proceedings in England and Wales: Consultation Paper 190*.
- The U.K. Biometric Working Group (2010) *Frequently Asked Questions about Biometrics - MS02*. [Online] Available from: http://www.cesg.gov.uk/policy_technologies/biometrics/ms02.shtml [Last accessed: 18/10/2010]
- Tillman, L. J. & Hanks, J. E. (2006) Wound Healing: Injury and Repair of Dense Connective Tissue. In Hertlin, D. & Kessler, R. M. (Eds.) *Management of*

Common Musculoskeletal Disorders: Physical Therapy Principles and Methods, 4th edition. Philadelphia: Lippincott Williams & Wilkins. pp 15-26.

Tommy T's Body Piercing (2006) Hand Piercing [Photograph] Available at:

<http://www.tommybodypiercing.com/Kevin%20H%202002%20Small.jpg>

[Accessed 04/12/2010].

Tripp, J. M. & Kopf, A. W. (2004) Dysplastic Nevus (Atypical Mole). In Marghoob, A. A. & Braun, R. P. (Eds.) *Atlas of Dermoscopy*, Abingdon: Taylor & Francis. pp 160-172.

Trozak, D. J., Tennenhouse, D. J. & Russell, J. J. (2006) *Dermatology Skills for Primary Care: An Illustrated Guide*, New Jersey: Humana Press Inc.

Trybus, M., Lorkowski, J., Brongel, L. & Hl'adki, W. (2006) Causes and consequences of hand injuries. *American Journal of Surgery*, 192, (1): 52-57.

Tulli, A. & Diociaiuti, A. (2008) Scar Revision. In Rusciani, L. & Robins, P. (Eds.) *Textbook of Dermatologic Surgery: Vol. 2*, Padova: Piccin. pp 547-553.

Turkington, C. & Dover, J. S. (2007) *The Encyclopedia of Skin and Skin Disorders*, 3rd edition. New York: Facts On File, Inc.

U.S. Consumer Product Safety Commission (n.d.) *National Electronic Injury Surveillance System*. [Online] Available from:

<http://www.cpsc.gov/cpscpub/pubs/3002.html> [Last accessed: 27/10/2010]

Centre for Anatomy and Human Identification Image Database. University of Dundee

Urioste, S. S., Arndt, K. A. & Dover, J. S. (1999) Keloids and hypertrophic scars:

Review and treatment strategies. *Seminars in Cutaneous Medicine and Surgery*, 18, (2): 159-171.

Usatine, R. P. (2008) Dermatology. In Sloane, P. D., Slatt, L. M., Ebell, M. H., Jacques, L. B. & Smith, M. A. (Eds.) *Essentials of Family Medicine*, 5th edition. Philadelphia: Lippincott Williams & Wilkins. pp 617-632.

- Valverde, P., Healy, E., Jackson, I., Rees, J. L. & Thody, A. J. (1995) Variants of the melanocyte-stimulating hormone receptor gene are associated with red hair and fair skin in humans. *Nature Genetics*, 11, (3): 328-330.
- van den Wijngaard, R., Wankowicz-Kalinska, A., Le Poole, C., Tigges, B., Westerhof, W. & Das, P. (2000) Local immune response in skin of generalized vitiligo patients. Destruction of melanocytes is associated with the prominent presence of CLA+ T cells at the perilesional site. *Laboratory Investigation*, 80, (8): 1299-1309.
- Vejjabhinanta, V., Nouri, K. & Patel, A. R. (2009) Treatment of Keloids and Hypertrophic Scars in Ethnic Skin. In Alam, M., Bhatia, A. C., Kundu, R. V., Yoo, S. S. & Hin-Lee Chan, H. (Eds.) *Cosmetic Dermatology for Skin of Color*, China: The McGraw-Hill Companies, Inc. pp 156-162.
- Wang, L., Leedham, G. & Siu-Yeung Cho, D. (2008) Minutiae feature analysis for infrared hand vein pattern biometrics. *Pattern Recognition*, 41, (3): 920-929.
- Wang, S. Q., Rabinovitz, H. & Oliviero, M. C. (2004) Dermoscopic Patterns of Solar Lentigines and Seborrheic Keratoses. In Marghoob, A. A. & Braun, R. P. (Eds.) *Atlas of Dermoscopy*, Abingdon: Taylor & Francis. pp 60-71.
- Weller, R., Hunter, J., Savin, J. & Dahl, M. (2008) *Clinical Dermatology*, 4th edition. Oxford: Blackwell Publishing Ltd.
- Wiles, M. R., Williams, J. & Ahmad, K. A. (2010) *Essentials of Dermatology for Chiropractors*, Sudbury: Jones and Bartlett Publishers, LLC.
- Wulf, H. C., Sandby-Møller, J., Kobayasi, T. & Gniadecki, R. (2004) Skin aging and natural photoprotection. *Micron*, 35, (3): 185-191.
- Yngveson, M., Svensson, A. & Isacson, A. (1998) Prevalence of self-reported hand dermatosis in upper secondary school pupils. *Acta Dermato-Venereologica*, 78, (5): 371-374.

- Young, A. R. & Walker, S. L. (2008) Acute and Chronic Effects of Ultraviolet Radiation on the Skin. In Wolff, K., Goldsmith, L. A., Katz, S. I., Gilchrist, B. A., Paller, A. S. & Leffell, D. J. (Eds.) *Fitzpatrick's Dermatology in General Medicine*, 7th edition. London: The McGraw-Hill Companies, Inc. pp 809-815.
- Zhang, D. D. (2000) *Automated Biometrics: Technologies and Systems*, Massachusetts: Kluwer Academic Publishers.
- Zhou, Y. (2006) Pigmentation: Too much or too little? *Canadian Journal of Continuing Medical Education*, 19, (1): 64-66.
- Zunkel, R. L. (2002) Hand Geometry Based Verification. In Jain, A., Bolle, R. & Pankanti, S. (Eds.) *Biometrics: Personal Identification in Networked Society*, Massachusetts: Kluwer Academic Publishers. pp 87-102.

Appendices

Appendix A

Observer Information Pack

This information was provided to the two observers who participated in inter-observer error studies. The information is aimed at providing a summary of the methods to the observers to allow them to follow the same protocols as the author when assessing images.

The landmarks used to form the grid seen in the hands in this study are listed in Table 1, and are partially based on landmarks used in previous studies by Berry (2008) and Huggins (2010). They were chosen due to their homogeneity and reproducibility across the entire image database. These landmarks allow the hand to be subdivided into 24 individual grid-cells. A description of each grid-cell's position on the hand is shown in Table 2.

Table 1. Landmarks for grid placement

1	Most medial point on the forearm-hand constriction
2	Most lateral point on the forearm-hand constriction
3	Point where the thumb or its associated interdigital webbing meets the palm
4	Most lateral (prominent) point over the 1 st metacarpophalangeal joint
5	Deepest point in the interdigital webbing between the 3 rd and 2 nd digits
6	Deepest point in the interdigital webbing between the 4 th and 3 rd digits
7	Deepest point in the interdigital webbing between the 5 th and 4 th digits
8	Point reached by extending line from point 7 parallel with knuckle crease to medial edge of hand
9	Point reached by extending line from point 5 in line with knuckle crease to lateral edge of 2 nd digit.
10	Most medial (deepest) point in the crease over the interphalangeal joint of the thumb
11	Most lateral (prominant) point in the crease over the interphalangeal joint of the thumb
12	Most medial point in middle of proximal interphalangeal (PIP) joint crease of 5 th digit
13	Most lateral point in middle of PIP joint crease of 5 th digit
14	Most medial point in middle of PIP joint crease of 4 th digit
15	Most lateral point in middle of PIP joint crease of 4 th digit
16	Most medial point in middle of PIP joint crease of 3 rd digit
17	Most lateral point in middle of PIP joint crease of 3 rd digit
18	Most medial point in middle of PIP joint crease of 2 nd digit
19	Most lateral point in middle of PIP joint crease of 2 nd digit
20	Most medial point in middle of distal interphalangeal (DIP) joint crease of 5 th digit
21	Most lateral point in middle of DIP joint crease of 5 th digit
22	Most medial point in middle of DIP joint crease of 4 th digit
23	Most lateral point in middle of DIP joint crease of 4 th digit
24	Most medial point in middle of DIP joint crease of 3 rd digit
25	Most lateral point in middle of DIP joint crease of 3 rd digit
26	Most medial point in middle of DIP joint crease of 2 nd digit
27	Most lateral point in middle of DIP joint crease of 2 nd digit

The most proximal limit of the grid was defined as the constriction between the hand and forearm, as described by Amayeh and colleagues (2009). Points 8 and 9 were drawn parallel with knuckle creases due to the lack of a reproducible anatomical point that could be identified in all of the images. Similarly, points 10 and 11 were located at the most medial and lateral points respectively

on the interphalangeal joint of the thumb due to a lack of reproducible anatomical landmarks in that region. Lines demarcating the division between digit proximal and intermediate digit regions and intermediate and distal digit regions were drawn in a position that visually appeared to be central according to the knuckle creases. Again, this was due to the difficulty of identifying a reproducible point on each knuckle.

The 24 grid-cells can be also be grouped into three distinct sectors. The final grid is also shown in Figure 1.

Proximal sector of the dorsum
Distal sector of the dorsum
Finger sector

Table 2. Hand cell descriptors

Cell letter	Descriptor
1	Most lateral proximal region
2	2 nd lateral proximal region
3	Proximal central region
4	2 nd medial proximal region
5	Most medial proximal region
6	Most lateral distal region
7	2 nd lateral distal region
8	Distal central region
9	2 nd medial distal region
10	Most medial distal region
11	Proximal region, digit 1
12	Proximal region, digit 2
13	Proximal region, digit 3
14	Proximal region, digit 4
15	Proximal region, digit 5
16	Distal region, digit 1
17	Intermediate region, digit 2
18	Intermediate region, digit 3
19	Intermediate region, digit 4
20	Intermediate region, digit 5
21	Distal region, digit 2
22	Distal region, digit 3
23	Distal region, digit 4
24	Distal region, digit 5

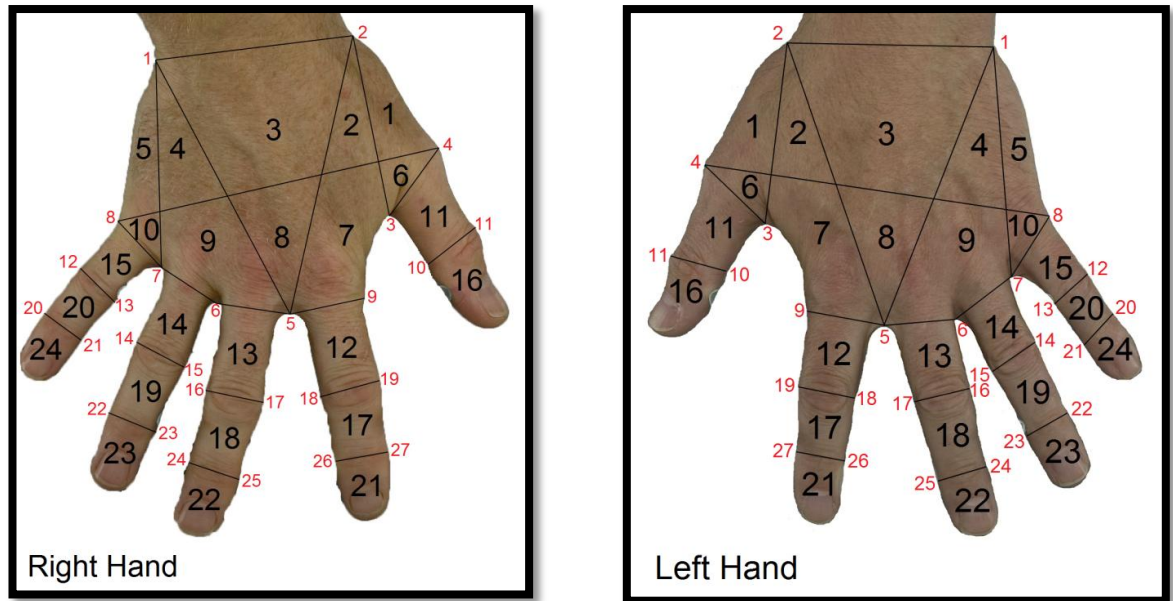


Figure 1. Hand grid, showing the 24 grid-cells

Image Analysis

Each image was observed once, and the features in each cell were recorded. The data collected on each feature is shown in Table 3. No information was gathered on spatial relationships between features and recording was carried out manually, based on a visual observation of each image.

The Count Tool in Adobe Photoshop was used to mark features with a numerical marker, which allowed quantification of features to be carried out in a more accurate fashion. The yellow channel of the image was viewed in addition to the full colour image in order to better visualise ephelides. Switching between the full colour image and the yellow channel of the same image can easily be done in Adobe Photoshop via the Channels tab.

Some images may be missing some areas due to the image having been cropped when the images were originally gathered. Grid-cells that have parts missing are recorded as empty.

Table 3. Information gathered according to feature

Feature	Information gathered
Ephelides (freckles)	Number
Nevi (moles)	Number
Lentiginos (liver spots)	Number
Depigmentation and hypopigmentation	Number
Dermatological conditions	Number, condition
Scars	Number, type, size, orientation
Hypertrophic scars	Number, size
Keloid scars	Number, size
Amputations	Number
Body modifications (piercings, tattoos)	Number, colours present in tattoo, type of piercing

The following criteria were used to recognise the features discussed in Table 3.

Ephelides (Freckles) (Figure 2)

- Small regions of darkened pigmentation.
- Generally possess a diameter of 1-3 mm.
- Angular or stellate border.

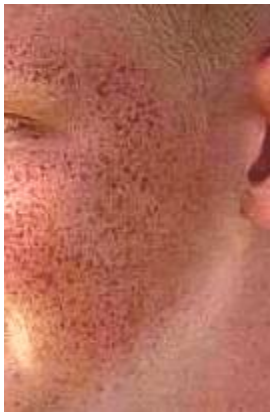

Figure 2. Ephelides
(L'Oréal, n.d.)

Nevi (Moles) (Figure 3)

- Regular, smooth, round, well-demarcated border.
- Dark pigmentation.
- May have long, coarse, darkly pigmented hairs growing in association with them.
- Atypical nevi can possess asymmetrical shape, irregular borders, varied colouring and a large diameter (Figure 4).

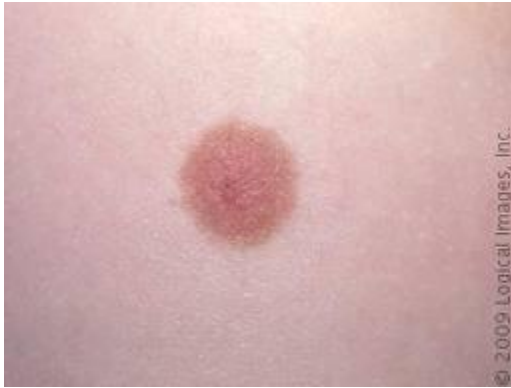

Figure 3. Nevus
(Logical Images Inc., 2009e)

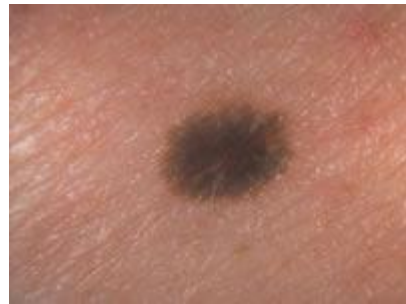

Figure 4. Atypical nevus
(Dermatology Associates of Plymouth Meeting, 2010)

Lentigines (Liver spots) (Figure 5 and Figure 6)

- Shape can be oval, round, or irregular.
- Diameter can vary from a few millimetres up to a few centimetres.

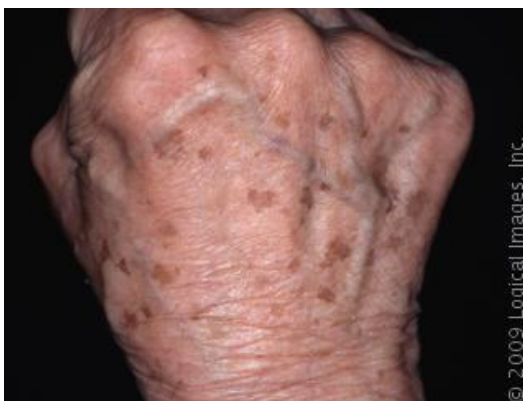

Figure 5. Lentigines I
(Logical Images Inc., 2009b)

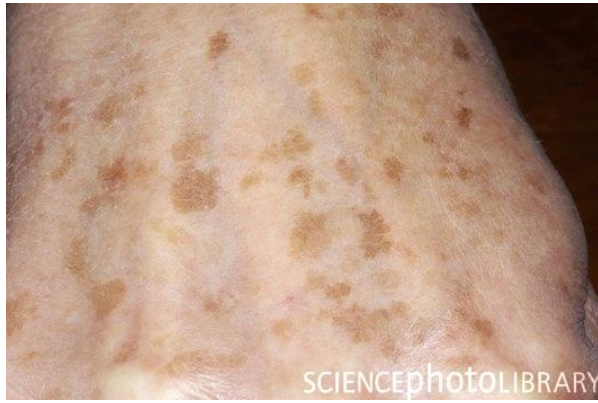

Figure 6. Lentigines II
(Dr. P Marazzi/Science Photo Library, 2010)

Depigmentation and Hypopigmentation

Vitiligo (Figure 7 and Figure 8)

- Oval or round macules
- Sharply circumscribed but irregular borders
- Can vary in size from a few mm to several cm

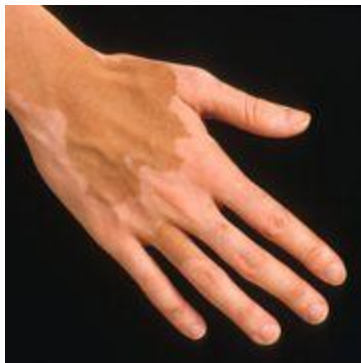

Figure 7. Vitiligo I
(Florida Skin Center, 2010)

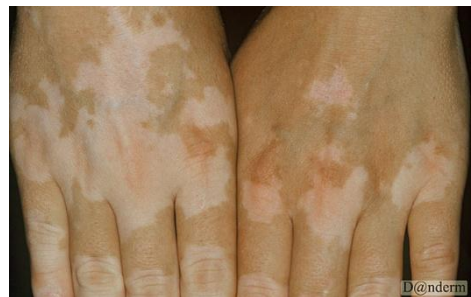

Figure 8. Vitiligo II
(Danderm, n.d.)

Dermatological Conditions

Dermatological conditions were recorded in a single column, labelled as “Dermatological conditions”. The name of the particular condition was then recorded in the “Notes” column.

Atopic Dermatitis (Eczema) (Figure 9)

- Prurigo papules (inflamed areas of skin)
- Lichenification (thickened areas of skin)
- Eczematous skin lesions (redness, lesions discharging serous matter, encrusted and scaly lesions)
- Thickened plaques of skin.

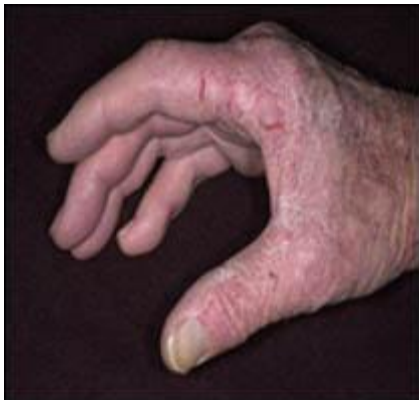

Figure 9. Atopic Dermatitis
(NHS, 2010b)

Psoriasis (Figure 10 and Figure 11)

- Raised, round, well-circumscribed, pink papules and plaques.
- Overlying silvery scale.
- Sores may be cracked and bleeding.

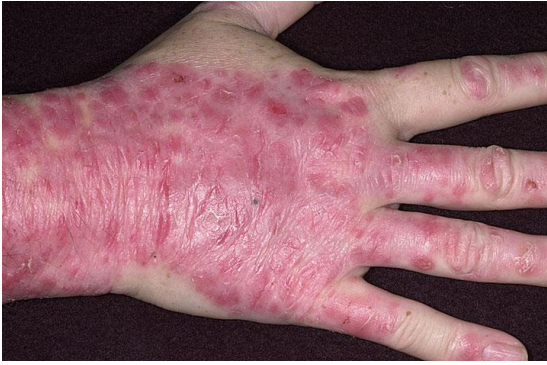

Figure 10. Psoriasis I
(DermNet.com, 2010)

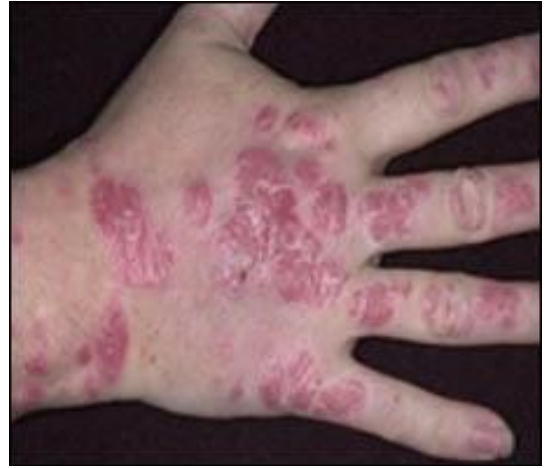

Figure 11. Psoriasis II
(NHS, 2010a)

Herpes Simplex (Figure 12)

- Fluid-filled vesicles
- Swelling
- Inflammation
- Pruritus
- Dry, crusted lesions in later stages

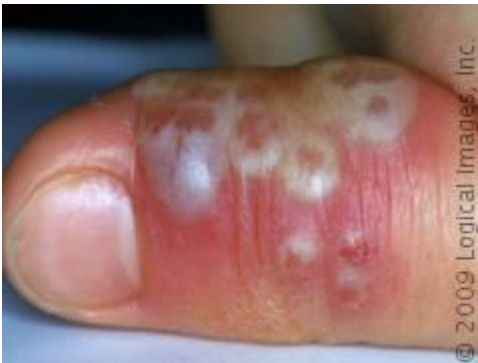

Figure 12. Herpes simplex in the finger
(Logical Images Inc., 2009a)

Actinic Keratinosis (Figure 13)

- Flat, scaly, thickened papules
- Can vary in size
- Rough appearance in later stages

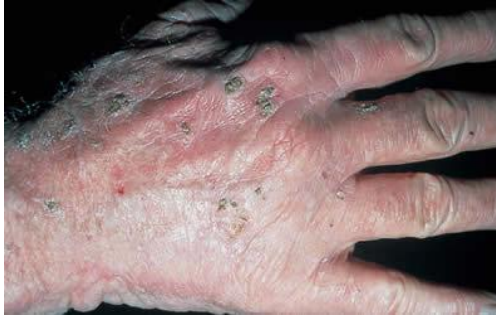

Figure 13. Actinic keratinosis
(American Academy of Dermatology, 2010)

Corns, Knuckle Pads Calluses (Figure 14, Figure 15 and Figure 16)

- Localised areas of thickened skin.
- Corns are inflamed and have a soft, damp peeling surface.
- Calluses (knuckle pads) are circumscribed areas of hardened skin over the interphalangeal or metacarpophalangeal joints.

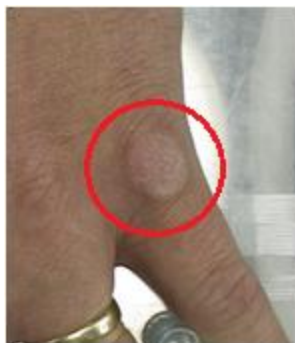

Figure 14. Knuckle pad I

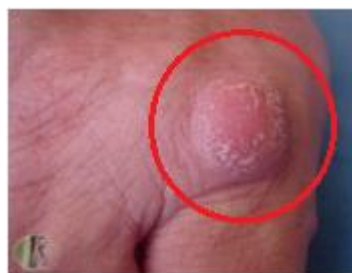

Figure 15. Knuckle pad II

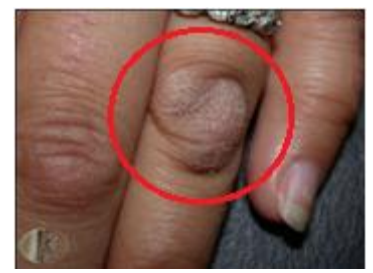

Figure 16. Knuckle pad III

Hypertrophic and Keloid Scars (Figure 17, Figure 18 and Figure 19)

- Hypertrophic appearance
- Raised, red, nodular appearance

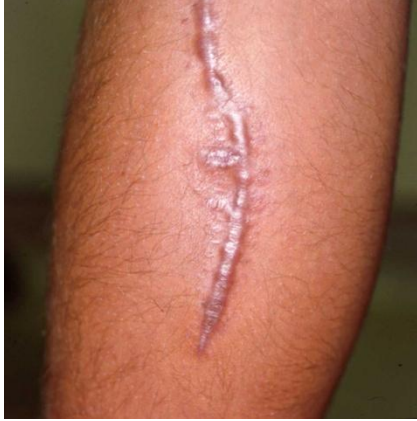

Figure 17. Hypertrophic scar
(Semchyshyn and Sengelmann, 2009)

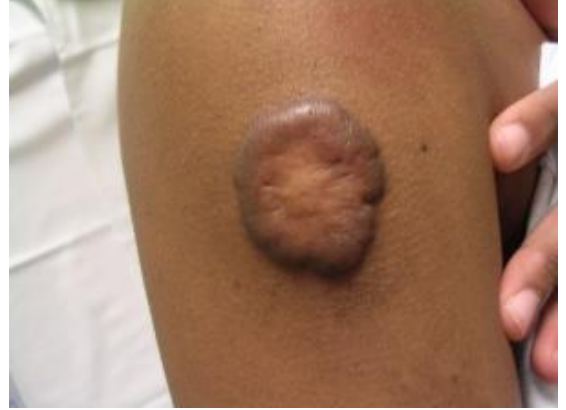

Figure 18. Keloid scar
(Scar Treatment Blog, 2009)

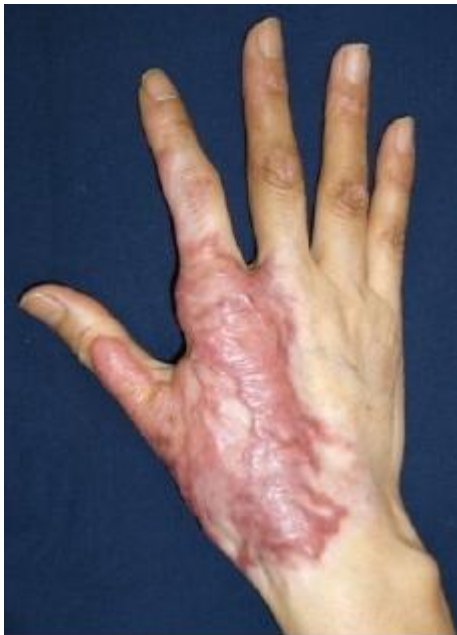

Figure 19. Burn, two years post-injury
(Ogawa *et al.*, 2010)

Scars

All scars were recorded along with additional information relating to their size and appearance. Scar type was assessed as linear or non-linear. Non-linear scars were characterised by the inability to identify an overall orientation. Non-linear scars were measured at their widest point. Assessment of orientation of scars was carried out based on a 4-direction scale, which is shown in Figure 2. Scar orientation was determined by the direction the scar most closely followed.

Size was assessed via the scale marker at the top of every image. Scars ≤ 5 mm were classed as small, scars that were 5-10 mm were classed as medium, and scars ≥ 10 mm were classed as large. Scars larger than 10mm in length were classed as extra large. These size classifications were based on the range of scar sizes seen in the first 100 images analysed.

In cases where a scar crossed a gridline, the scar and its additional information on size, orientation, and type were recorded in the grid cell in which the majority of the scar was located. Size was measured according to the size of scar tissue in each grid cell.

Amputation was recorded according to which grid-cells were removed. For example if an amputation had been carried out at the proximal interphalangeal joint of the first finger, grid-cells 17 and 21 were both recorded as amputated.

Scar orientation

The long axis of the middle finger was used to define the orientation of the proximo-distal axis, defined as orientation 1, shown in Figure 20.

An orientation was not recorded for non-linear scars, as identifying an overall orientation was not possible due to their appearance.

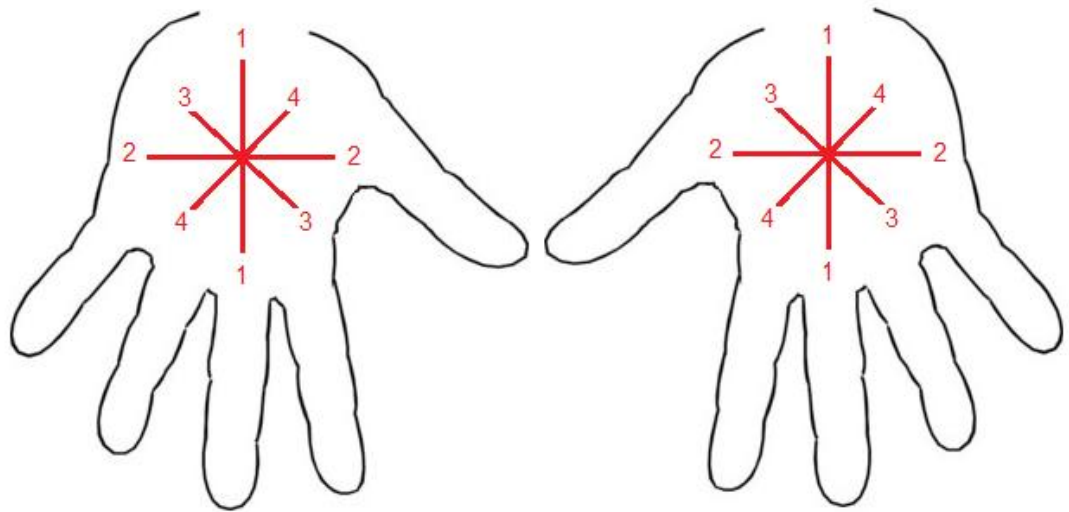


Figure 20. Scar orientation

Data was recorded in spreadsheets created in Microsoft Excel. Each hand had two tables of information associated with it, one for ephelides, lentigines, nevi, tattoos, amputations, and hypopigmentation, and one for the scar information. Data was recorded for each cell individually. Scar type was recorded as L (linear) or NL (non-linear) and size was recorded as small (S), medium (M), large (L), or extra large (XL). Orientation was recorded as 1, 2, 3, or 4. Finally, additional characteristics were recorded under the headings irregular, surgical, degloving, keloid and hypertrophic.

Irregular scar appearance was characterised by linear scars that were angled or curvilinear, or that divided into multiple scars. Examples of irregular scarring are shown in Figure 21. An example of degloving injury scarring is shown in Figure 22.

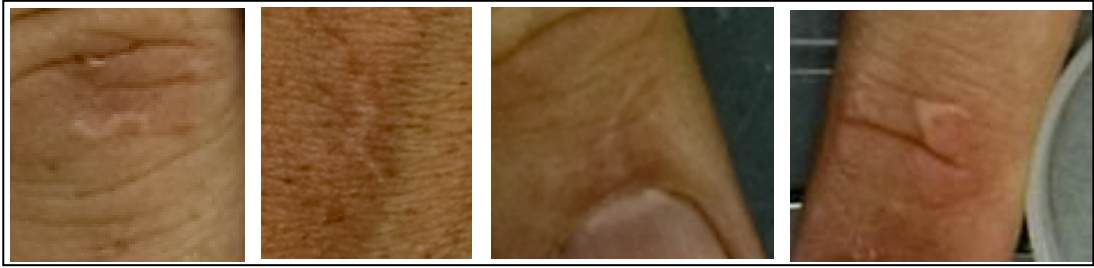

Figure 21. Irregular scar examples

Shown in Figure 22 is an example of a degloving scar, characterised by the presence of multiple scars of both a linear and non-linear type.

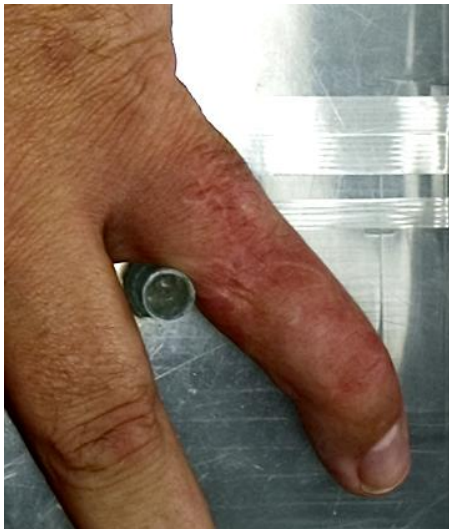

Figure 22. Degloving injury scarring

Surgical Scars

Examples of surgical incision sites in the hand are shown in Figures 23-31.

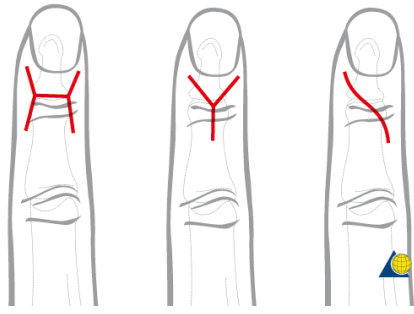


Figure 23. H-shaped, Y-shaped and curvilinear incisions (Colton *et al.*, n.d.)

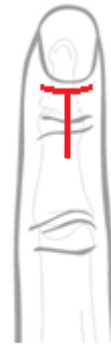

Figure 24. T-shaped incision

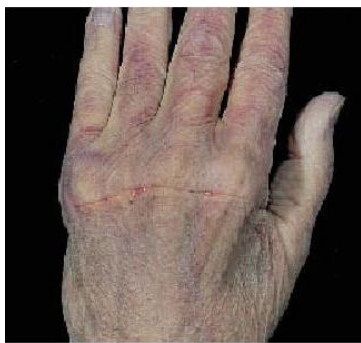

Figure 25. Dorsal approach to MCP joint (Sharpe and Stevanovic, 2000)

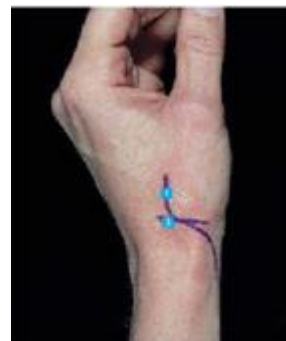

Figure 26. Dorsal approach to basal joint of the thumb (Sharpe and Stevanovic, 2000)

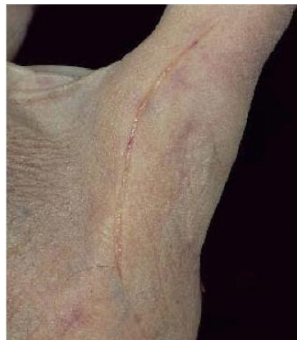

Figure 27. Gamekeeper's thumb approach to the thumb MCP joint (Sharpe and Stevanovic, 2000)

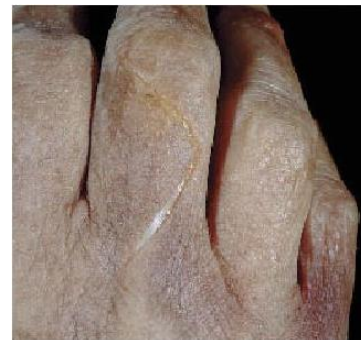

Figure 28. Dorsal approach to fingers (Sharpe and Stevanovic, 2000)

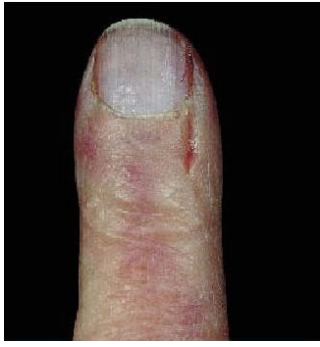

Figure 29. Paronychia approach

(Sharpe and Stevanovic, 2000)

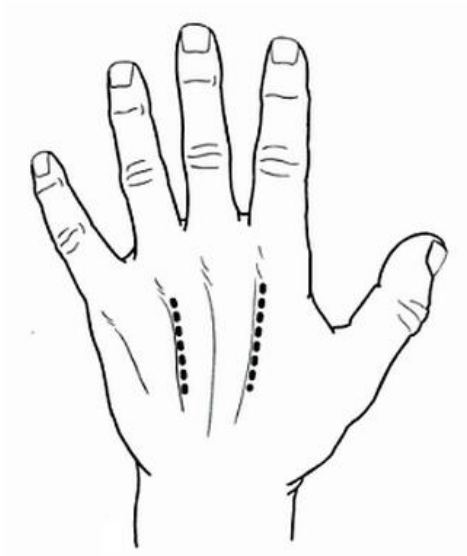


Figure 30. Dorsal interosseous compartment incisions for compartment syndrome treatment

(Doyle *et al.*, 2006)

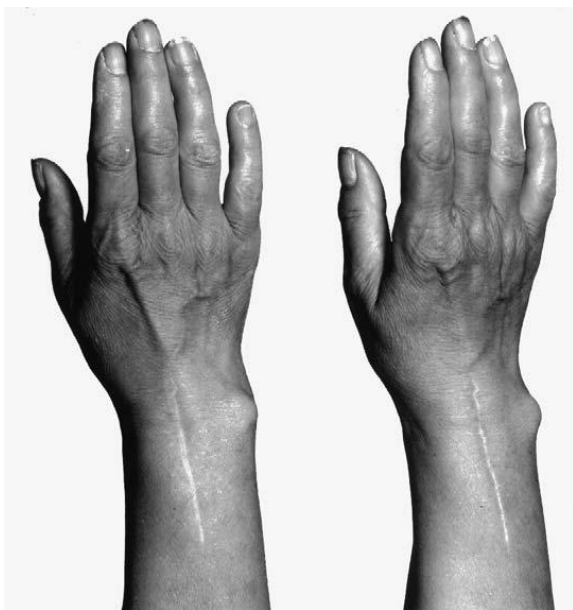


Figure 31. Linear incision for radial fracture fixation

(Gangopadhyay and Packer, 2003)

Data Recording

Six images are provided for observation. All six images are to be observed and recorded according to the methods set out in this document once every two days. This will be repeated for twelve days, giving six repeated observations.

The recording sheets are in Excel format. The workbook is composed of six worksheets, one for each image. Each worksheet is titled with the same number as the image it applies to. Within each worksheet, there are 6 tables, one for each observation. So for the first observation, the first table in each of the 6 worksheets will be completed. Then for the second observation, the second table in each worksheet will be completed.

An example of the features part of the recording form is shown in Table 4. In this example, there were 12 freckles in grid-cell 1, 4 freckles in grid-cell 2, and 2 freckles in grid-cell 3. There was 1 mole in grid-cell 2. There was a dermatological condition in grid-cell 3, which was identified as dermatitis.

Table 4. Feature Recording Forms

Grid ref	Freckles	Moles	Liver spots	Dermatological conditions	Tattoos	Knuckle pads	Amputations	Piercings	Notes
1	12								
2	4	1							
3	2			1					dermatitis

In the example of the scars section of the recording form, shown in Table 5, grid-cell 2 has two scars contained within it. The first scar is linear, small in size, has an orientation of 2 and has a hypertrophic appearance. The second scar is linear, large in size and has an orientation of 4. In grid-cell 3, there is a medium sized non-linear scar.

Appendix B

- **Mean Values from Multiple Comparison of Grid-cells in Sex, Hand Dominance and Age Cohorts**

AND

Appendix C

- **Multiple Comparison of Grid-cells**