

# Use of Recombinant Human Bone Morphogenetic Protein (rhBMP2) in Bilateral Alveolar Ridge Augmentation: Case Report

Davor Katanec<sup>1</sup>, Marko Granić<sup>1</sup>, Martina Majstorović<sup>2</sup>, Zdenko Trampuš<sup>3</sup> and Dragana Gabrić Pandurić<sup>1</sup>

<sup>1</sup> University of Zagreb, School of Dental Medicine, Department for Oral Surgery, Zagreb, Croatia

<sup>2</sup> University of Zagreb, School of Dental Medicine, Department of Pediatric and Preventive Dentistry, Zagreb, Croatia

<sup>3</sup> Private Dental Clinic, Zagreb, Croatia

## ABSTRACT

*In recent years, the delivery of osteoinductive factors such as bone morphogenic proteins (BMPs) has become an alternative approach to traditional bone grafting due to their capacity to produce bone healing and new bone formation. BMP-2 has proved to possess the highest osteoinductive potential among BMPs. The case reported the clinical use of recombinant human BMP-2 for bilateral vertical alveolar ridge augmentation. In a case of 61 year-old patient with a significant bilateral vertical bony deficiency of the mandible, rhBMP-2 administered via an absorbable collagen sponge carrier (ACS) was used for bilateral alveolar ridge bone induction. Augmented sites were covered and fixed with titanium mesh. Augmented sites were reopened 6 months after surgery. Titanium membrane and retaining screws were removed and three dental implants were placed. The tissue samples for the histologic analysis were harvested. Following 3 months healing period, the submerged implants were uncovered and restored with zirconium-ceramic crowns. Cone beam computed tomography (CBCT), panoramix and 3D radiographic evaluation were obtained prior to and after the surgical procedure. Vertical gain of the bone was 5.5 mm on the left and 5 mm on the right side, with 6 mm width of the bone. Histologic analysis revealed formation of mature trabecular bone with signs of osteoblastic proliferation. Implant stability quotient (ISQ) values were in the range between 69 and 75 for all three implants. No suppuration, gingival recession or pain were present 24 months after surgery. Vertical bone augmentation using rhBMP-2 is optional treatment modality to consider when planning dental implant placement in sites where severe vertical insufficiency exists.*

**Key words:** rhBMP-2, collagen sponge carrier, vertical alveolar ridge augmentation, implant placement

## Introduction

Use of autogenous block grafts has long been accepted as the gold standard for reconstruction of deficient alveolar ridge dimension. However, its numerous risks, such as pain, infection, and morbidity, combined with a limited quantity of available donor site tissue have led many to employ alternative regenerative materials including allografts, xenografts or synthetic materials. In recent years, the delivery of osteoinductive factors such as bone morphogenic proteins (BMPs) have become an alternative approach to traditional bone grafting due to their capacity to enhance the natural ability of the surrounding tissues to produce bone healing and new bone formation<sup>1,2</sup>. BMP-s are members of the transforming growth

factor- $\beta$  (TGF- $\beta$ ) family of proteins<sup>3</sup>. Their activity related to bone induction remained unknown until 1988. when first recombinant BMPs were cloned<sup>4</sup>, BMP-2 has proved to possess the highest osteoinductive potential among BMPs and thus plays an important role in the early phase of proliferation and differentiation of mesenchymal progenitor cells into osteoblasts<sup>5,6</sup>. Prior to FDA approval, extensive preclinical and animal studies were conducted to examine the efficacy and limitations of BMP-2 in promoting bone formation<sup>7</sup>. Animal models have demonstrated that fracture healing can be accelerated by local administration of rhBMP-2<sup>8,9</sup>. Most recently, the effects of rhBMP-2 on the osseointegration of tita-

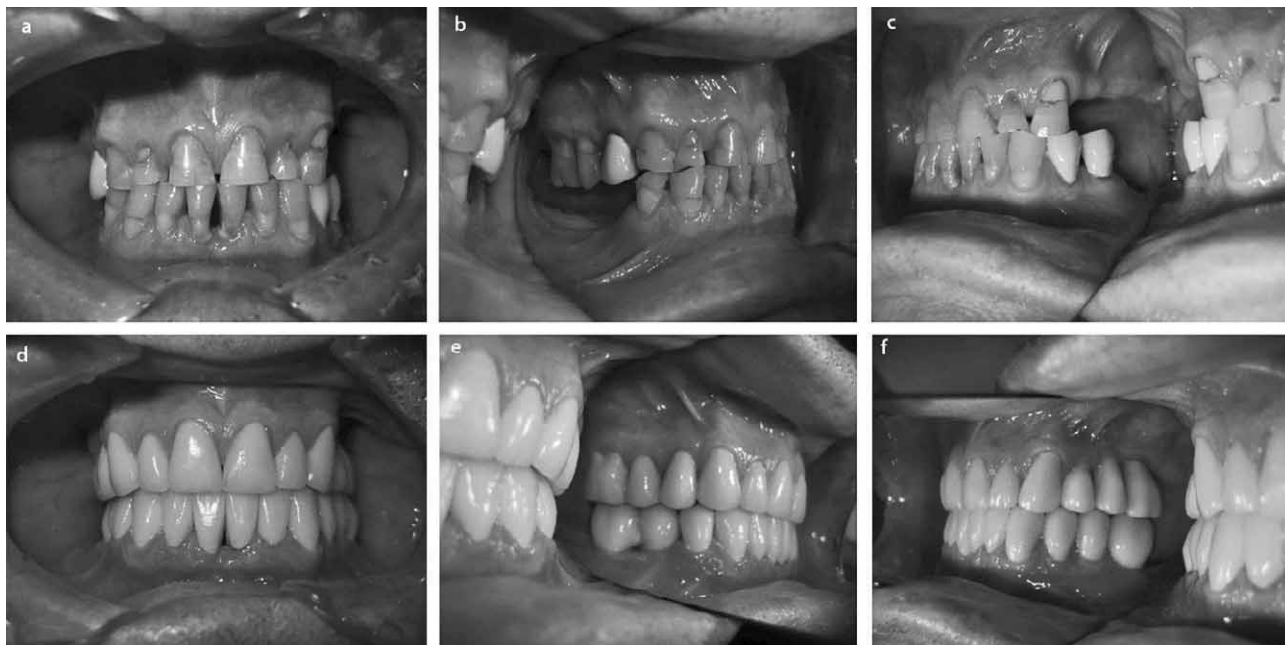


Fig. 1. Clinical findings in the 61-year-old patient pre-surgery and postoperatively.

nium implants have also been investigated in the experimental animal studies. Basic clinical research showed that newly formed bone is woven bone with vital osteoblasts and adequate vascularisation, thus representing a favorable environment for implant placement<sup>2,10–13</sup>. The safe application of rhBMP-2 has further been confirmed in human studies<sup>14,15</sup>.

In this report, a case of clinical usage of rhBMP-2 for bilateral alveolar ridge bone induction following dental implants placement, was presented.

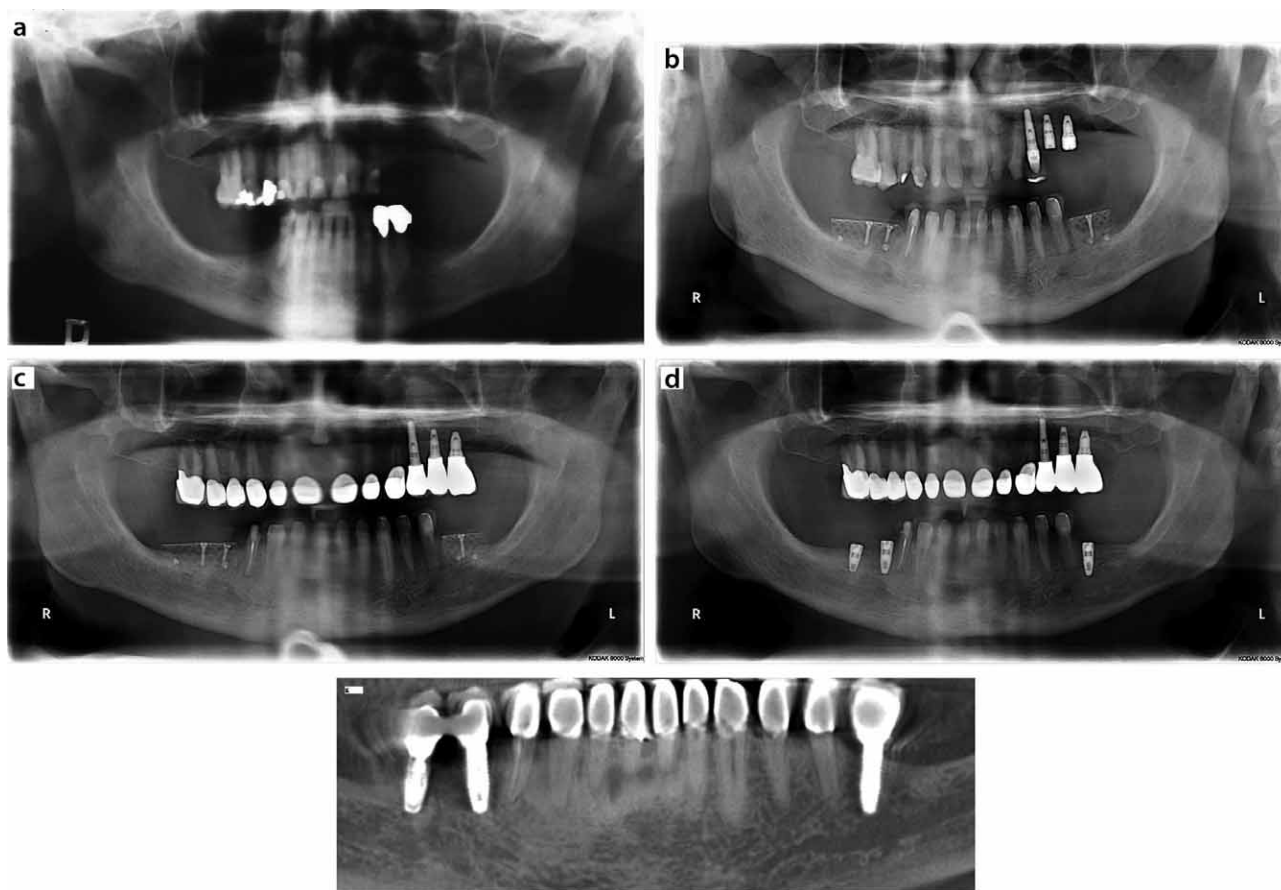
### Case Report

A 61-year-old man was referred to the Department of Oral Surgery University of Zagreb by his general dentist for treatment of severe vertical bone deficiency in both the mandibular molar regions (Figure 1). The patient's medical history was not contributory. CBCT and panoramic mandibular scans were obtained preoperatively and showed 5-6 mm of bone superior to the mandibular canal which was insufficient to enable dental implant placement without augmentation procedures (Figure 2a). The patient underwent initial periodontal therapy prior to surgery. A written consent was obtained by the patient prior to surgical treatment.

A broad-spectrum antibiotic was administered preoperatively. Anesthesia was achieved via mandibular block (Articaine 1:200000, 3M ESPE AG, Seefeld, Germany). Full thickness horizontal incision was made along the edentulous crest and extended intrasulcularly at the lingual aspect of the mandibular premolars on each side. Vertical releasing incisions, located at the mesio-buccal line angles of the adjacent anterior teeth, were created to facilitate surgical access and tension-free flap closure. Bone

augmentation of the mandibular alveolar ridge was performed using rhBMP-2 (1.5 mg/mL) in combination with an absorbable collagen sponge (ACS) carrier (INFUSE® Bone Graft, Medtronic Spinal and Biologics, Memphis, TN, USA). 2.5 mL of the solution was applied to the carrier for treatment of the right side and 1.5 mL for the left side, according to the manufacturer prescribed protocol. Augmented sites were covered with a rigid titanium membrane, 0.1 mm thick (Titanium Mesh, 25x30 mm, Salvin, USA), and fixed using screws located in the anticipated sites of the future dental implants. Two screws were secured through the mesh to support the height of the alveolar ridge, and two tacks were also placed to secure the edges to the native bone. Periosteal releasing was done to allow for passive primary closure using silk sutures (Mersilk, 4/0, Ethicon, INC, New Jersey, USA). Moderate edema and erythema were observed on day 2 following surgery and persisted for 2 weeks. Sutures were removed ten days after surgical procedure.

Six months after surgery, reopening of the augmented sites were performed when the titanium membrane and the stabilizing screws were removed (Figure 3). Newly formed bone appeared immature, trabecular in appearance and did not have a dense outer cortical layer in comparison to the adjacent native bone and felt soft in consistency relative to the subjacent native bone when being drilled during implant sites preparation. The osteotomies for the implants placement were prepared through previous screws sites following drilling with the trephine due to harvesting regenerated bone samples for histological analysis. Dental implants (NobelReplace™ Tapered Groovy, Nobel Biocare AB, Göteborg, Sweden) were placed (Figure 3) in the sites 36 (4.3x13 mm), 46 (4.3x13 mm) and 47 (4.3x10 mm) and good primary stability was



*Fig. 2. Radiographic evaluation. a) Panoramix prior to surgery representing significant vertical bony deficiency in both mandibular right and left molar regions. b) Panoramix 3 months post surgery representing bone growing into space delineated by titanium membrane. c) Panoramix 6 months post surgery representing significant bone growth into space delineated by titanium membrane. d) Panoramix after placement of dental implants representing bone overgrowing the top of the implant cover screws. e) CBCT taken 12 months post surgery representing vertical gain of newly formed bone.*

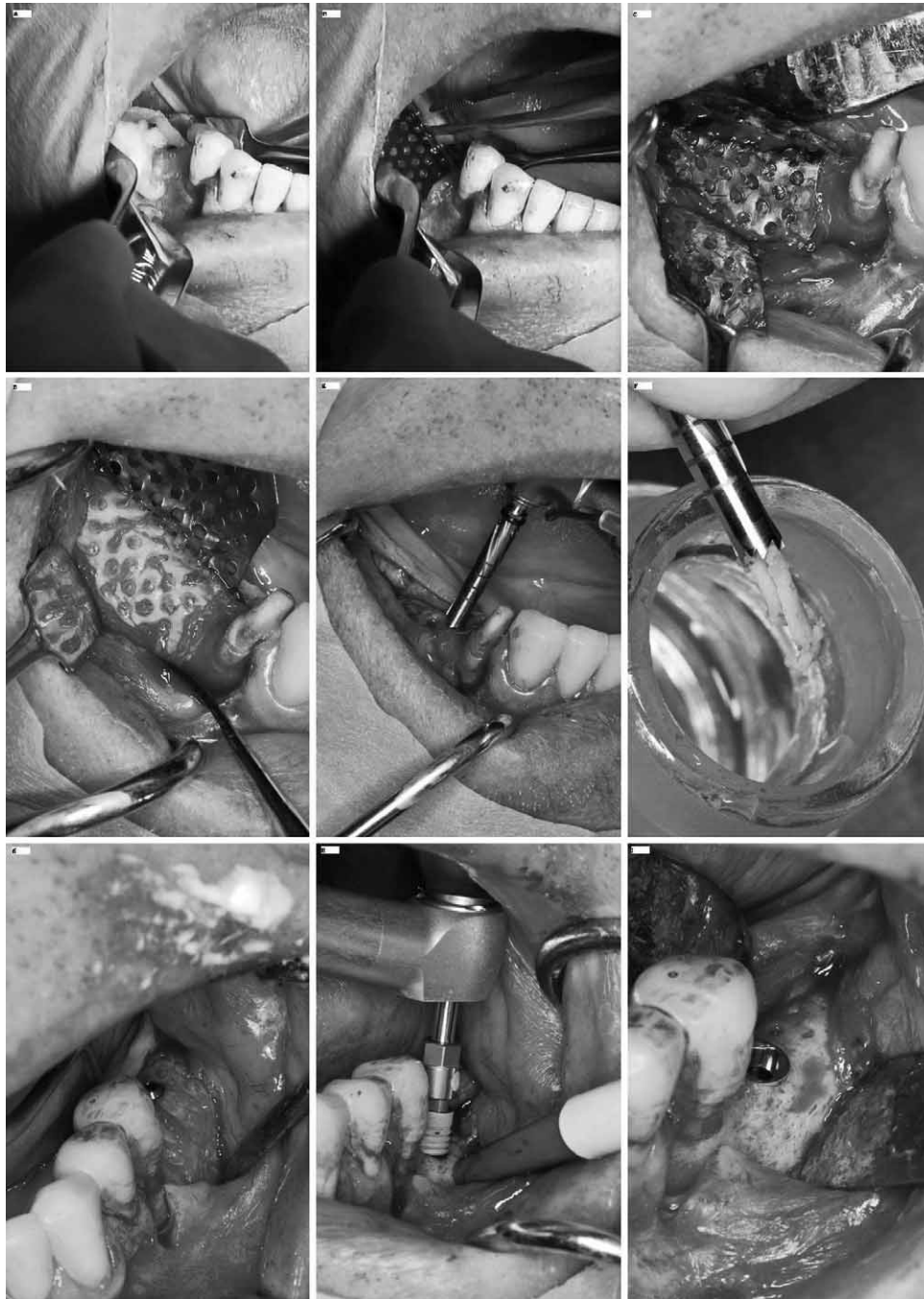achieved. The bone quality was evaluated by resonance frequency device Osstell (Osstell AB, Goteborg, Sweden). ISQ values were in the range between 73 and 76 for all three implants. The surgical site was sutured using silk sutures (Mersilk, 4/0, Ethicon, INC, New Jersey, USA). Plaque control was maintained by daily rinses of the oral cavity with 0.2% chlorhexidine (Corsodyl, GlaxoSmith-Kline, UK) and hyaluronic acid agent (Gengigel, Medis Adria, Italy), which were used separately 3 times a day until suture removal. Sutures were removed 10 days post-surgery. Three months following implant placement, second surgical phase was performed. Thin layer of soft tissue of fibrous consistency was noted overlying the surface of the regenerated bone which, when removed, revealed bone overgrowing the top of the implant cover screws. Healing abutments were placed for a period of two weeks after which ceramic abutments were placed on the implants, and finally restored with zirconia-ceramic restorations.

CBCT radiographic evaluation was obtained prior to and 1 month following dental implants placement, as well as on the 24 month recall. Panoramics radiographs

were obtained prior to and 6 months following ridge augmentation, and then at 12 and 24 months after implants placement (Figure 2). ISQ values were in the range between 69 and 74 for all three implants during follow-up period of 12 months.

Histological analysis revealed the architecture of harvested bone tissue comprised of mainly lamellar bone and smaller amount of woven bone (Figure 4). Woven bone showed signs of trabecular remodelling as differentiated by the pattern of osteoclasts and moderate osteoblastic proliferation. The newly formed bone was more similar to trabecular bone typical of the maxilla and was represented by higher percentage of bone marrow surrounding bone fragments. Bone fragments with signs of mechanically damaged structure (basophilic areas) were randomly present in the medullary space with signs of mechanical damage due to using the trephine drill. Inflammatory cells were not present and bone voids were not detected.

No suppuration, gingival recession, pain or ongoing pathologic processes were present on the time of follow-up 24 months after surgery.



*Fig. 3. Second surgical procedure, removal of the titanium mesh, sample for the histological analysis harvesting and dental implants placement.*

## Discussion

Several groups of authors showed in animal models that rhBMP-2 induced bone formation accommodates not only installation and osseointegration, but also long-term functional loading of endosseous implants<sup>2,10–13</sup>. Early rh-BMP use in humans was reported in case report whereby reconstruction of a large mandibular resection defect was done following removal of an ameloblastoma<sup>16</sup>.

The Food and Drug Administration approved rhBMP-2 for autograft replacement in spinal fusions in 2002, in 2004 for open tibia fractures, and in 2007 for sinus augmentations, and for localized alveolar ridge defects, when for the first time were used for reconstruction of mandibular bone defects in humans<sup>17</sup>. Most of the authors found several problems when using rhBMP-2 in human surgical procedures. Some disadvantages of the collagen carrier proved to be related to its lack of struc-

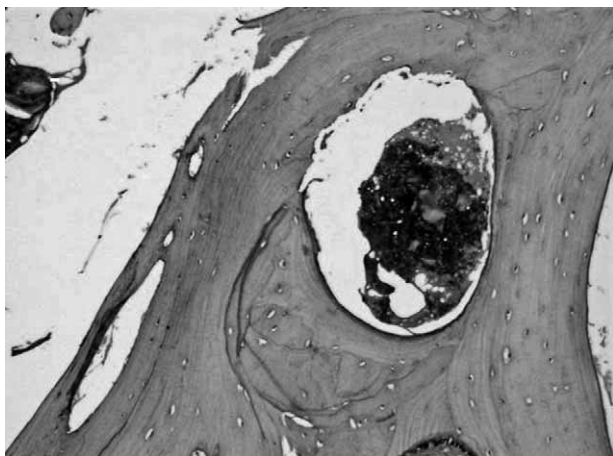


Fig. 4. Histological evaluation of newly formed bone revealing mature cancellous bone with mature lacunar structure of osteocytes.

tural stability and inability to maintain space as it is compressed by soft-tissues overlying the defect<sup>10–13</sup>. For these reasons, current research attempts are directed toward developing a matrix with more structural ability capable of maintaining the space for bone induction during healing<sup>17</sup>. For this reason the treatment we presented in this case report included the use of a pure titanium membrane which was secured prior to placing the loading collagen carrier as a means of creating a physical structure to maintain space for regeneration to occur. Furthermore, rhBMP-2/ACS in the amount of 1.5 mg/cc was used, which has been proved to be optimal for bone augmentation<sup>7</sup>. Based on the comparison of two doses of rhBMP-2/ACS (0.75 and 1.5 mg/cc) for treating post-extraction defects, a higher dose seems to affect the amount and velocity of the newly formed bone<sup>18</sup>. However, peri-implant bone remodelling and seroma formation has been observed to be considerably more extensive and aggressive at a higher rhBMP-2 concentration<sup>10</sup>. The results reported by Carter<sup>17</sup>, attributed some failures of bone regeneration using rhBMP-2 due to infection. Documented adverse events linked to rhBMP-2 include bone resorption or remodelling at the graft site, severe neck swelling, hematoma, painful seroma, ectopic bone formation and severe dysphagia<sup>14–18</sup>. The most frequent complication is edema, noted in our case as well, which may occur partially due to fast releasing of the full dose of rhBMP-2 from ACS once being placed in the defect. A disadvantage of rhBMP-2/ACS is its half-time of approximately 7–16 minutes with a burst release within 1 hour

## REFERENCES

1. JUNG RE, THOMA DS, HAMMERLE CH, *J Clin Periodontol*, 35 (2008) 255. DOI: 10.1111/j.1600-051X.2008.01270.x. — 2. SCHWARZ F, FERRARI D, SAGER M, HERTEN M, HARTIG B, BECKER J, *Clin Oral Implants Res*, 20 (2009) 1219. DOI: 10.1111/j.1600-0501.2009.01796.x. — 3. KING GN, *Curr Pharm Biotechnol*, 2 (2001) 131. DOI: 10.2174/1389201013378716. — 4. WOZNEY JM, ROSEN V, CELESTE AJ, MITSOCK LM, WHITTEERS MJ, KRIZ RW, HEWICK RM, WANG EA, *Science*, 242

of implantation and lacks any controlled releasing property. Further research is indicated to better understand and determine optimal dose of rhBMP-2, timing of its release and carrier vehicle to yield predictable and reliable bone regeneration.

Although the expectation was to gain approximately 8–9 mm of bone height, the final outcome was represented by gaining 5–5.5 mm of the newly formed bone in the posterior mandible. Vertical gain of newly formed bone was 5.5 mm on the left and 5 mm on the right side, which was comparable with the similar results achieved by using the conc. of 1.5 mg/cc in the case of sinus augmentation, representing newly formed bone height of 7.83 mm and 9.46 mm respectively<sup>14</sup>. It could be also assumed that the type of bone in the surgical site may affect induction of the bone formation.

ISQ values, which in our study ranged from 69–76, were comparable with the study of Alsabeeha<sup>19</sup>, in which the ISQ values ranging between 75–85 acquired for the posterior portion of the mandible presented the native bone standard measurement. The lower ISQ values were obtained due to the type of newly formed bone induced by rhBMP-2, rather than related to the implant site preparation.

Radiographic findings in our study revealed improved density of newly formed bone, which in structure was very similar to the native bone. These results contribute to previous findings that rhBMP-2 induced bone continues maturing and by 12–24 weeks post implantation cannot be radiographically differentiated from the resident bone<sup>20</sup>. Radiolucent voids in rhBMP-2 induced bone have been observed in multiple studies utilizing a variety of carriers in suprealveolar or saddle-type defects in dogs, being detected as seromas or sterile accumulations of serum in a circumscribed location<sup>20,21</sup>. However, no voids were detected in our study, which is in accordance with findings from other human reports following the use of us rhBMP-2<sup>22</sup>.

## Conclusion

Vertical bone augmentation using rhBMP-2 is optional treatment modality to consider when planning dental implant placement in sites where severe vertical insufficiency exists. However, further research is indicated to better understand and determine optimal dose of rhBMP-2, timing of its release and carrier vehicle to yield predictable and reliable bone regeneration.

(1988) 1528. DOI: 10.1126/science.3201241. — 5. REDDI AH, *Nat Biotechnol*, 16 (1998) 247. DOI: 10.1038/nbt0398-247. — 6. HUGHES FJ, TURNER W, BELIBASAKIS G, MARTUSCELLI G, *Periodontology*, 2000 41 (2006) 48. DOI: 10.1111/j.1600-0757.2006.00161.x. — 7. MCKAY WF, PECKHAM SM, BADURA JM. A, *Orthop*, 31 (2007) 729. DOI: 10.1007/s00264-007-0418-6. — 8. BOSTROM MP, SALEH KJ, EINHORN TA, *Orthop Clin North Am*, 30 (1999) 647. DOI: 10.1016/S0030-5898(05)70117-

6. — 9. DEN BOER FC, BRAMER JA, BLOKHUIS TJ, VAN SOEST EJ, JENNER JM, PATKA P, BAKKER FC, BURGER EH, HAARMAN HJ, Bone, 31 (2002) 158. DOI: 10.1016/S8756-3282(02)00816-5. — 10. LEKNES KN, YANG J, QAHASH M, POLIMENI G, SUSIN C, WIKESJO UME, Clin Oral Implants Res, 19 (2008) 1027. DOI: 10.1111/j.1600-0501.2008.01567.x. — 11. WIKESJO UM, XIROPAIDIS AV, THOMSON RC, COOK AD, SELVIG KA, HARDWICK WR, J Clin Periodontol, 30 (2003) 715. DOI: 10.1034/j.1600-051X.2003.00364.x. — 12. JOVANOVIĆ SA, HUNT DR, BERNARD GW, SPIEKERMANN H, NISHIMURA R, WOZNEY JM, WIKESJO UM, Clin Oral Implants Res, 14 (2003) 793. DOI: 10.1046/j.0905-7161.2003.chr140617.x. — 13. JOVANOVIĆ SA, HUNT DR, BERNARD GW, SPIEKERMANN H, WOZNEY JM, WIKESJO UM, Clin Oral Implants Res, 18 (2007) 224. DOI: 10.1111/j.1600-0501.2006.01324.x. — 14. BOYNE PJ, LILLY LC, MARX RE, MOY PK, NEVINS M, SPAGNOLI DB, TRIPLETT RG, J Oral Maxillofac Surg, 63 (2005) 1693. DOI: 10.1016/j.joms.2005.08.018. — 15. COCHRAN DL, JONES AA, LILLY LC, FIORELLINI JP, HOWELL TH, J Periodontol, 71 (2000) 1241. DOI: 10.1902/jop.2000.71.8.1241. — 16. MOGHADAM HG, URIST MR, SANDOR GK, CLOKIE CM, J Craniofac Surg, 12 (2001) 119. DOI: 10.1097/00001665-200103000-00005. — 17. CARTER TG, BRAR PS, TOLAS A, BEIRNE OR, J Oral Maxil Surg, 66 (2008) 1417. DOI: 10.1016/j.joms.2008.01.058. — 18. FIORELLINI JP, HOWELL TH, COCHRAN DL, MALMQUIST J, LILLY LC, SPAGNOLI D, TOLJANIC J, JONES A, NEVINS M, J Periodontol, 76 (2005) 605. DOI: 10.1902/jop.2005.76.4.605. — 19. ALSABEEHA NH, DE SILVA RK, THOMSON WM, PAYNE AG, Clin Oral Implants Res, 21 (2010) 563. DOI: 10.1111/j.1600-0501.2009.01890.x. — 20. HUNT DR, JOVANOVIĆ SA, WIKESJO UM, WOZNEY JM, BERNARD GW, J Periodontol, 72 (2001) 651. DOI: 10.1902/jop.2001.72.5.651. — 21. WIKESJO UM, QAHASH M, THOMSON RC, COOK AD, ROHRER MD, WOZNEY JM, HARDWICK WR, Clin Oral Implants Res, 15 (2004) 194. DOI: 10.1111/j.1600-0501.2004.00971.x. — 22. JUNG R, GLAUSER R, SCHARER P, HAMMERLE CH, SAILER HF, WEBER FE, Clin Oral Implants Res, 14 (2003) 556. DOI: 10.1034/j.1600-0501.2003.00921.x.

D. Gabrić Pandurić

University of Zagreb, School of Dental Medicine, Department of Oral Surgery, Ivana Gundulića 5, 10000, Zagreb, Croatia

e-mail: dgabric@sfzg.hr

## UPOTREBA REKOMBINATNOG HUMANOG MORFOGENETSKOG PROTEINA (rhBMP-2) U OBOSTRANOJ AUGMENTACIJI ALVEOLARNOG GREBENA – PRIKAZ SLUČAJA

### SAŽETAK

U posljednjih nekoliko godina upotreba oseoinduktivnih faktora rasta kao što su BMP-i, postali su alternativni izbor u odnosu na tradicionalnom koštanom presađivanju zbog svoje sposobnosti formiranja novog koštanog tkiva. Najveći oseoinduktivni potencijal među BMP pokazuje BMP-2. U ovom prikazu slučaja prikazujemo upotrebu rekombinatnog humanog BMP-2 (rhBMP-2) u kombinaciji sa kolagenom spužvicom za obostranu vertikalnu augmentaciju alveolarnog grebena kod pacijenta starog 61 godinu sa značajnim obostranim vertikalnim nedostatkom kosti u donjoj čeljusti. Augmentacijska mjesta su prekrivena i fiksirana titanskom mrežicom. 6 mjeseci nakon augmentacije titanska mrežica je uklonjena i na njenom mjestu su postavljena 3 dentalna implantata. Prilikom preparacije ležišta implantata uzet je dio novostvorenog tkiva za histološku analizu. Nakon tromjesečnog perioda cijeljenja postavljene su cirkon-keramičke krunice. CBCT i panoramske snimke su poslikane prije i nakon operacije. Vertikalni dobitak kosti je bio 5,5 mm za lijevu i 5 mm za desnu stranu donje čeljusti sa širinom od 6 mm. Histološka analiza je pokazala formiranje zrele spužvaste kosti sa znakovima proliferacije osteoblasta. ISQ vrijednosti su u rasponu od 69 do 75 za sva tri implantata. Nakon 24 mjeseci nije opisane nikakve komplikacije u vidu gnojenja, recesije ili boli. Vertikalna augmentacija pomoću rhBMP-2 može se uzeti u obzir za liječenje većih vertikalnih koštanih insuficijencija prije implantoprotetske rehabilitacije.