


CD4, CD8 and MHC Class I Expression in Epstein-Barr Virus-Associated Nasopharyngeal Carcinoma: An Immunohistochemical Study



Dyah R. Budiani¹, Sofia M. Haryana², Marsetyawan HNE Soesatyo², Wihaskoro Sosroseno³

¹Sebelas Maret University, Faculty of Medicine, Department of Pathology, Surakarta, Indonesia

²Gadjah Mada University, Faculty of Medicine, Department of Histology and Cell Biology, Yogyakarta, Indonesia

³AIMST University, Faculty of Dentistry, Semeling, Bedong, Kedah Darul Aman, Malaysia

Eur J Gen Med 2010;7(3):277-281

Received: 27.07.2009

Accepted: 18.11.2009

ABSTRACT

Aim: The exact immunopathogenesis of Epstein-Barr virus (EBV)-associated nasopharyngeal carcinoma (NPC) remains unclear. The aim of the present study was to assess the expression of CD4, CD8, and MHC class I molecules in NPC.

Method: Biopsies were obtained from patients with NPC as well as the Epstein Barr virus (EBV)-seronegative patients as a control. Nasopharyngeal carcinoma patients were classified using the World Health Organization (WHO) pathological assessment and clinical staging of NPC. The expression of CD4, CD8, and MHC class I in the biopsies were assessed immunohistochemically.

Result: The results showed that the number of CD4 positive, CD8 positive, and MHC class I positive cells in NPC patients were higher than those in EBV-negative subjects ($p < 0.05$). The number of these positive cells in NPC patients with WHO Type II or early clinical stage was not significantly differences with those with WHO Type III or late clinical stage, respectively ($p > 0.05$). No statistical differences between the number of CD4 positive and CD8 positive cells in NPC patients could be found ($p > 0.05$).

Conclusion: The results of the present study suggest, therefore, that the expression of CD4, CD8 and MHC class I molecules may not be associated with the pathologic classification and clinical staging of NPC and that the CD4:CD8 ratio in nasopharyngeal carcinoma may indicate decreased functions of these infiltrating T cell subsets.

Key words: CD4; CD8; MHC class I; NPC

Correspondence: Wihaskoro Sosroseno,
Faculty of Dentistry, AIMST University,
Semeling, 08100 Bedong, Kedah Darul
Aman, Malaysia
Fax: 60 4 4422887;
E-mail: wsosroseno@yahoo.com

Epstein-Barr virus ilişkili Nazofaringeal Karsinomada CD4, CD8 ve MHC Klas I Ekspresyonu: İmmunohistokimyasal Çalışma

Amaç: Epstein-Barr virus (EBV) ilişkili Nazofarengal Karsinomun (NFK) immunopatogenezi tam olarak aydınlatılamamıştır. Bu çalışmanın amacı, NPC de CD4, CD8 ve MHC Klas I ekspresyonunun araştırmasıdır

Metod: NFK tanı ve kontrol grubu olarak EBV seronegatif olan hastaların biyopsileri incelendi. Nasofarengal karsinom hastaları Dünya Sağlık Örgütü (WHO) NFK patolojik değerlendirme ve klinik evrelemesi kullanılarak sınıflandırıldı. Biyopsilerdeki CD4, CD8 ve MHC Klas I ekspresyonu immunhistokimyasal olarak değerlendirildi.

Bulgular: CD4 pozitif, CD8 pozitif ve MHC Klas I pozitiflik miktarı NFK hücrelerinde EBV negatif guruba göre yüksek bulundu ($p < 0.05$). WHO Tip 2 veya erken evre NFK daki pozitif hücre sayısı ile WHO Tip 3 veya geç evre arasında istatistiksel olarak fark yoktu ($p > 0.05$). NFK hastalarında CD4 pozitif hücre sayısı ile CD8 pozitif hücre sayısı arasında istatistiksel olarak fark yoktu ($p > 0.05$).

Sonuç: CD4, CD8 ve MHC Klas I moleküllerinin ekspresyonunun NFK hastalarında patolojik sınıflandırma ve klinik evreleme ile alakalı olmadığını, nasofarenks karsinomunda CD4/CD8 oranı infiltre eden T hücre alt gurublarının fonksiyonunda azalma olduğuna işaret etmektedir.

Anahtar kelimeler: CD4; CD8; MHC klas I; NFK

INTRODUCTION

Nasopharyngeal carcinoma (NPC) is a tumor of epidermoid origin and prevalent in several regions around the world. Based on the degree of differentiation, the World Health Organization (WHO) classifies NPC into keratinizing squamous cell carcinoma (WHO Type I) and nonkeratinizing carcinoma which is further subdivided into the differentiated subtype (WHO Type II) and undifferentiated subtype (WHO Type III). The association between Epstein-Barr virus (EBV) and NPC is well known as shown by the fact that the EBV genome was found in the NPC specimens (1,2). However, it would appear that EBV is much more strongly associated with the undifferentiated NPC as compared with other NPC subtypes (3). EBV is a member of the herpesvirus family and primarily infects and replicates in the stratified squamous epithelium of oropharynx (1,2).

The precise pathogenesis by which EBV induces the development of NPC remains to be further elucidated. Both CD4+ and CD8+T cells have been shown to infiltrate in the stroma of NPC (4,5). Altered expression of major histocompatibility complex (MHC) class I has also been reported (5). However, despite abundant infiltrating T cells in the stroma of NPC, the development of tumor remains progressive, suggesting that the immune responses against the cancerous cells may be down-regulated, perhaps by cancer-derived immunosuppressive cytokines. Indeed, a previous study showed that an increased production of interleukin-10 (IL-10) in the patients with NPC-WHO type III or clinical late stage (6), suggesting that this cytokine may inhibit the functions of infiltrating T cell subsets in NPC tissues. Therefore, the aim of the present study was to immunohistochemically determine the ex-

pression of CD4, CD8 and MHC class I in NPC tissues from Indonesian patients.

MATERIALS AND METHODS

NPC biopsies were obtained from 8 patients with nonkeratinizing carcinoma (WHO Type II) and 19 patients with undifferentiated carcinoma (WHO Type III). The clinical staging of NPC was examined according to tumor-node-metastasis (TNM) classification of the International Union Against Cancer rules for head and neck cancer. These NPC patients were then classified as early stage (stage I and II) and late stage (stage III and IV) as previously described (7). Biopsies were collected from the patients undergone observations and treatments at the Dr. Sardjito's General Hospital, Yogyakarta, Indonesia. All NPC patients were EBV positive by serological tests. The controls were derived from the nasopharyngeal tissues of the EBV-seronegative subjects undergoing for the elective surgery. All participants and/or their relatives gave informed contents and this study was approved by the ethical committee of the Faculty of Medicine, Gadjah Mada University.

CD4+ and CD8+T cells as well as MHC class I positive cells in paraffin-embedded blocks were determined using the avidin-biotin-peroxidase complex. Following cut and deparaffinization, the sections were blocked in 3% H₂O₂ dissolved in absolute methanol and then mounted with protein blocking agent (Lipshaw, Pittsburgh, PA). Biotinylated mouse anti-human CD4, CD8 and MHC class I antibodies (Sigma, St. Louis, MO) were applied on all sections which were then incubated for 30 minutes at room temperature. After washing, all sections were re-

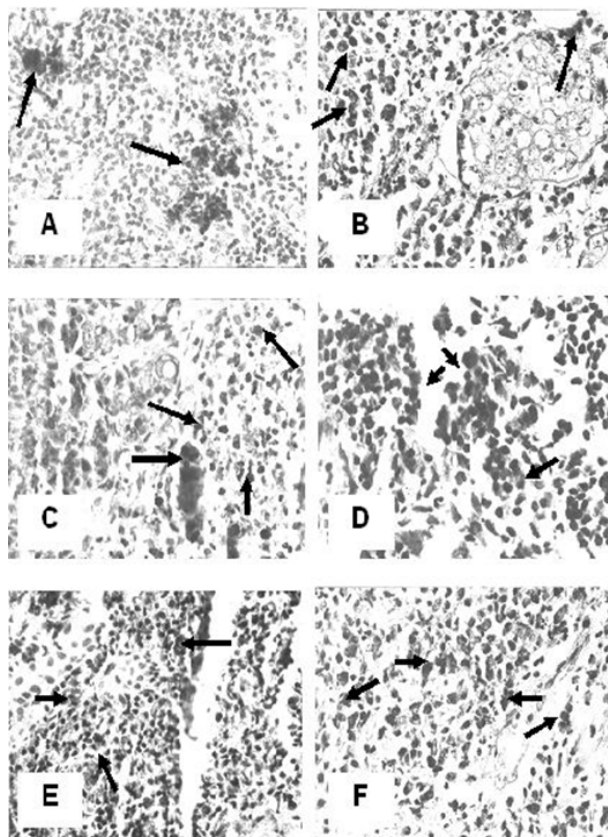


Figure 1. CD4, CD8 and MHC class I protein expression in nasopharyngeal carcinoma (NPC). Panel A, C and E are WHO Type II NPC, whereas panel B, D and F are WHO Type III. (A and B) = CD4 protein expression; (C and D) = CD8 protein expression; (E and F) = MHC class I protein expression. Arrows indicate positive cells. (Original magnification X 400)

acted with the streptavidin-peroxidase (Lipshaw) for 30 minutes, visualized using a 3-3'-diaminobenzidine tetrahydrochloride solution (DAB; Lipshaw) for 10-20 minutes and subsequently counterstained with hematoxylin. Cells with positive staining per mm² were microscopically counted.

The data was statistically determined by a one way analysis of variance followed by Fischer's least squared differences using a statistical package (SPSS Inc., Chicago).

RESULTS

The positive staining for CD4⁺ and MHC class I⁺ cells were scattered in the stroma of NPC tissues (Figure 1). The distribution of these positive cells in NPC tissues with WHO II classification was almost similar with that in NPC tissues with WHO III. Statistically, CD4⁺, CD8⁺ and MHC class I⁺ cells in cancerous tissues from NPC patients were higher than those from the healthy subject

($p < 0.05$) (Figure 2 and 3). No statistically differences in the number of positive cells between WHO II and WHO III of NPC could be found ($p > 0.05$) (Figure 1 and 2). When NPC patients were divided into clinical stages, the number of positive cells between early and late stage were not also significantly different ($p > 0.05$) (Figure 3). The number of CD4⁺ cells in each of pathological classifications and the clinical staging was not significantly difference with that of CD8⁺ cells ($p > 0.05$) (Figure 2 and 3).

DISCUSSION

The present study showed that the number of infiltrating CD4⁺ cells in tissues from patients with NPC was significantly higher than the control, suggesting that infiltrating CD4⁺ cells may play a role in the progression of NPC as also previously demonstrated (4,5). Interestingly, the present study indicated that the number of CD4⁺T cells was independent upon the pathological classification and clinical staging of NPC. The exact reason to explain

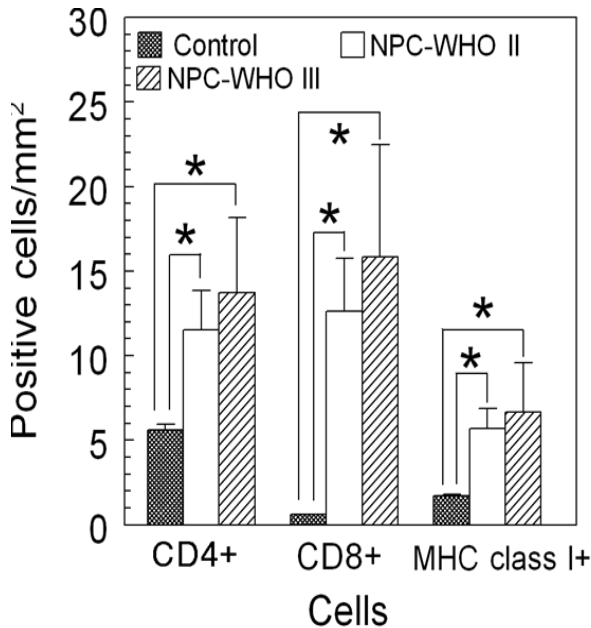


Figure 2. The number of CD4+, CD8+ and MHC class I+ cells in NPC tissues based on the WHO's pathological classification. Bars represent mean and standard deviation. (*) = significant at $p < 0.05$

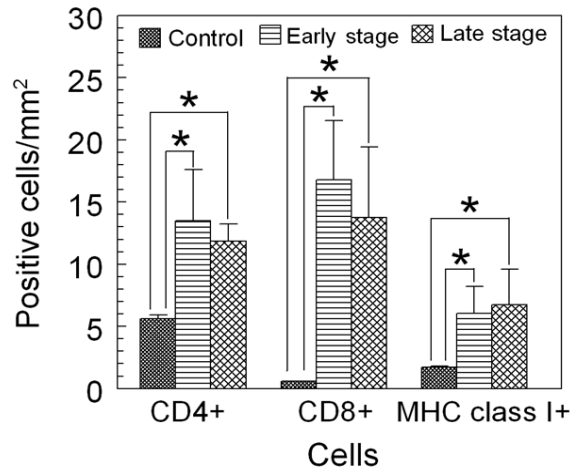


Figure 3. The number of CD4+, CD8+ and MHC class I+ cells in NPC tissues based on the clinical staging. Bars represent mean and standard deviation. (*) = significant at $p < 0.05$

these results remains unclear. One of the possibilities is that CD4+T cells may be activated at the premalignant to malignant stage of EBV infection; so that, the number of infiltrating CD4+ cells remains stable throughout the progression of NPC as previously suggested (8,9).

CD8 cells can be activated by EBV-derived antigens in a MHC class I-dependent mechanism (1). Therefore, increased number of infiltrating cells CD8+ cells in NPC seen in the present study is not surprising and is supported by previous studies (5,10). Interestingly, the number of CD8+T cells in NPC biopsies as seen in the present study was not associated with the pathological classification and clinical staging of NPC. The exact reason to explain these results is not clear, yet again. It is possible that the number CD8+T cells in the late stage of NPC as seen in the present study might reflect a defect of cell activation or functions in this clinical staging of this tumor (10,11), perhaps due to the action of IL-10 (6,12), thereby inhibiting further proliferation and differentiation of this T cell subset in NPC. However, this notion needs to be further clarified.

Of interest, the CD4+ and CD8+ cell ratio in all pathological classifications and clinical stages of NPC seen in

the present study was equal. In contrast, previous studies found that the number of infiltrating CD4+T cells in NPC is significantly higher than that of CD8+T cells (4,5). The exact reason to explain the discrepancy between the previous (5) and the present study is far from clear. Perhaps, this discrepancy may be due to different patient's genetic background and/or EBV strains infected the NPC patients participated in the previous and the present study (1,2).

NPC cells possess normal expression of essential components, such as TAPs and LMP, of MHC class I processing pathway and hence, normal MHC class I-antigen processing functions (13). Therefore, the results of present study showing that MHC class I expression in NPC was increased as compared with the healthy control indicates that EBV infection may stimulate the synthesis of MHC class I molecules and antigen-presentation functions of NPC cells. Furthermore, the present study also demonstrated that the expression of MHC class I in NPC is independent on the clinical staging and pathological classification of tumor and these results are in accordance with the previous study (5). One may assume, therefore, that MHC-class I-bearing NPC cells may present EBV-derived

peptides to cytotoxic T cells at a similar magnitude in both early and late NPC stage or both non-keratinizing and undifferentiated NPC.

In conclusion, the results of the present study showed that the number of CD4+, CD8+ and MHC class I+ cells in the biopsies from NPC patients on Indonesia was higher than that in the healthy control. However, the number of these positive cells between WHO type II and III or between early and late clinical stage of NPC was not significantly differences. These results suggest, therefore, that the expression of CD4+, CD8+ and MHC class I may be increased in NPC but may not be associated with the pathological classification and clinical staging of this carcinoma in Indonesia.

Acknowledgements

This work was supported by DCRG-URGE 2000/2001, the Ministry of National Education, the Indonesian Government. The authors gratefully thank to Drs. A. Haryadi and B. Hariwiyanto (Faculty of Medicine, Gadjah Mada University, Yogyakarta, Indonesia) for sharing the samples.

REFERENCES

- Ohga S, Nomura A, Takada H, Hara T. The immunological aspects of Epstein-Barr virus infection. *Crit Rev Oncol Hematol* 2002;44:203-15.
- Middeldorp JM, Brink AATP, van den Brule AJC, Meijer CJLM. Pathogenic roles for Epstein_/Barr virus (EBV) gene products in EBV-associated proliferative disorder. *Crit Rev Oncol Hematol* 2002;44:1-36.
- Vasef M, Ferlito A, Weiss L. Nasopharyngeal carcinoma with emphasis on its relationship to Epstein-Barr virus. *Ann Otol Rhinol Larynol* 1997;106:348-56.
- Hsu MM, Hsu HC, Liu LT. Local immune reaction in nasopharyngeal carcinoma with special reference to its prognostic evaluation. *Head Neck* 1989;11:505-10.
- Lai FM, Cheng PN, Tsao SY, Lai KN. Immunohistological characteristics of the infiltrating lymphoid cells and the expression of HLA class I and II antigens in nasopharyngeal carcinoma. *Virchow Arch A Pathol Anat Histopathol* 1990; 417:347-52.
- Budiani DR, Hutahaean S, Haryana SM, Soesatyo MHNE, Sosroseno W. Interleukin-10 levels in Epstein-Barr virus-associated nasopharyngeal carcinoma. *J Microbiol Immunol Infect* 2002;35:265-8.
- Lu JJY, Chen CL, Hsu TY et al. Expression of Epstein-Barr virus latent membrane protein 1 and B-cell leukemia-lymphoma 2 gene in nasopharyngeal carcinoma tissues. *J Microbiol Immunol Infect* 2002;35:136-40.
- Long HM, Haigh TA, Gudgeon NH et al. CD4+ T-cell responses to Epstein-Barr virus (EBV) latent-cycle antigens and the recognition of EBV-transformed lymphoblastoid cell lines. *J Virol* 2005;79:4896-907.
- Adhikary D, Behrends U, Moosmann A, Witter K, Bornkamm GW, Mautner J. Control of Epstein-Barr virus infection in vitro by T helper cells specific for virion glycoproteins. *J Exp Med* 2006;203:995-1006.
- Zanussi S, Vaccher E, Caffau C et al. Interferon-gamma secretion and perforin expression are impaired in CD8+ T lymphocytes from patients with undifferentiated carcinoma of nasopharyngeal type. *Cancer Immunol Immunother* 2003;52:28-32.
- Ferradini L, Miescher S, Stoeck M et al. Cytotoxic potential despite impaired activation pathways in T lymphocytes infiltrating nasopharyngeal carcinoma. *Int J Cancer* 1991;47:362-70.
- Yao M, Ohshima K, Suzumuya J, Kume T, Shiroshita T, Kikuchi M. Interleukin-10 expression and cytotoxic-T-cell response in Epstein-Barr-virus-associated nasopharyngeal carcinoma. *Int J Cancer* 1997;72:398-402.
- Khanna R, Busson P, Burrows SR et al. Molecular characterization of antigen-processing function in nasopharyngeal carcinoma (NPC): evidence for efficient presentation of Epstein-Barr virus cytotoxic T-cell epitopes by NPC cells. *Cancer Res* 1998;58:310-4.

Copyright of European Journal of General Medicine is the property of Medical Investigations Society and its content may not be copied or emailed to multiple sites or posted to a listserv without the copyright holder's express written permission. However, users may print, download, or email articles for individual use.