

Detection of illegal estrogen administration through immunohistochemical markers in the bovine prostate¹

Patricia Elena Fernández^{2*}, Héctor Ramón Sanguinetti^{2,4}, Enrique Leo Portiansky², Claudio Gustavo Barbeito^{2,3} and Eduardo Juan Gimeno²

ABSTRACT.- Fernández P.E., Sanguinetti H.R., Portiansky E.L., Barbeito C.G. & Gimeno E.J. 1999. Detection of illegal estrogen administration through immunohistochemical markers in the bovine prostate. *Pesquisa Veterinaria Brasileira* 19(3/4):133-138. Institute of Pathology "Prof. Dr. Bernardo Epstein", School of Veterinary Sciences, National University of La Plata, P.O.Box 296, (1900) La Plata, Argentina.

The immunodetection of diverse cell markers was evaluated in prostatic samples from bullocks, and bullocks showing epithelial hyperplasia-metaplasia, with oestrogen-induced changes, and in experimental samples from bullocks inoculated with diethylstilbestrol (DES). Antigen-retrieval procedures allowed the use of tissues that had been fixed in formalin for long periods. Three tissue markers were chosen for the study: cytokeratins 13 and 16, vimentin and desmin. Monoclonal antibody K8.12 (specific for cytokeratins 13 and 16) stained basal cells and hyperplastic-metaplastic epithelium; monoclonal antivimentin, and desmin, allowed the definition of fibromuscular changes.

INDEX TERMS: Bovine prostate, cell markers, immunohistochemistry, oestrogen.

RESUMO.- [Verificação da administração ilegal de estrógenos através de marcadores imunohistoquímicos na próstata de bovinos.] A imunodeteção de marcadores celulares foi avaliada em amostras prostáticas de bovinos com hiperplasia ou hiperplasia-metaplasia epiteliais, induzidas por estrógenos administrados ilegalmente e em próstatas de bovinos inoculados com dietilstilbestrol (DES). A técnica de recuperação antigênica permitiu o uso de tecidos fixados em formalina, por longos períodos. Foram utilizados os anticorpos monoclonais K8.12, anti-vimentina e anti-desmina para determinação de células basais coradas/epitélio hiperplásico-metaplásico, células do estroma e células musculares, respectivamente. As alterações tissulares observadas nos casos de campo e nos experimentais foram semelhantes, através do que se concluiu

que houve administração ilegal de estrógenos. O teste imunohistoquímico com esses marcadores específicos foi útil ao exame histológico da próstata, uma vez que a análise das imagens permite maior e melhor quantificação das alterações observadas. Os testes bioquímicos, entretanto, são necessários para uma avaliação mais precisa.

TERMOS DE INDEXAÇÃO: Próstata bovina, marcadores de células, imunohistoquímica, estrógenos.

INTRODUCTION

The use of hormonal anabolics in the fattening of cattle can lead to an increase of about 10-20% of its body weight by mainly affecting the musculature (Engst & Sauerlich 1965, McMartin et al. 1978). The most frequently used drugs are diethylstilbestrol (DES) or DES esters such as DES dipropionate (DES-DP) due to their efficacy, price, availability and stability (Jansen et al. 1989). DES has been banned from beef production primarily because of health risks resulting on account of its carcinogenic and teratogenic properties (Herbst et al. 1974, McMartin et al. 1978). Nevertheless, illegal DES administration occurs and it is a matter of concern in many countries (Epstein 1990).

Hyperplasia and squamous metaplasia of the prostatic glandular epithelium have been considered as DES-induced

¹Accepted for publication on February 24, 1999.

²Institute of Pathology "Prof. Dr. Bernardo Epstein", School of Veterinary Sciences, National University of La Plata, P.O.Box 296, (1900) La Plata.

³Department of Histology and Embryology, School of Veterinary Sciences, National University of La Plata, (1900) La Plata.

⁴Department of Pathology, Central Laboratory, National Service for Animal Health (SENASA), Buenos Aires, Argentina.

*Author to whom correspondence should be addressed.

changes. Tests for the presence of oestrogenic hormones in bullocks to slaughter make use chiefly of chemical and biological methods, by means of which any oestrogens in the urine and tissues of slaughterhouse animals can be detected (Allen & Doisy 1923, Brown 1955, Dryer 1956, Huis in't Veld et al. 1967). The disadvantage of these methods is that they are too complicated or too time-consuming to use in the routine slaughterhouse laboratory. Therefore, the histological examination of the organ has been widely employed as a method for evaluation of oestrogen administration (Ruitenbergh et al. 1970, Kroes et al. 1971, Jansen et al. 1989, Groot 1992). The "Prostate test" can be carried out rapidly, is easy-evaluating and reliable, and any administration of oestrogenic hormones during the fattening period will be histologically identifiable at slaughter regardless of the actual presence of oestrogens in the urine of the animals.

Cytokeratins are a complex group among the intermediate filaments (IF) which are cytoskeletal differentiation-related proteins detected in virtually all eukaryotic cells (Alberts et al. 1994). IF are intermediate in size (diameter, 8 to 11 nm) between actin-based microfilaments (diameter, 6 nm) and tubulin-containing microtubules (diameter, 25 nm) (Anderton 1981). The functions of IF proteins are not completely known; however, they appear to play a role in the maintenance of cellular integrity, shape, and organelle positioning, the regulation of cellular and intracellular movement, and the regulation of gene expression (Miettinen et al. 1984, Traub & Shoeman 1994).

Immunohistochemical demonstration of cytokeratin has been used in frozen sections of DES-treated and normal bulls and goats (Weijman et al. 1987, Jansen et al. 1989, Weijman et al. 1990, Weijman et al. 1992). Biochemical and immunohistochemical studies have demonstrated that five different types of IF proteins can be distinguished in mammalian cells (Ramaekers et al. 1986). Most mesenchymal cells contain vimentin as the main intermediate filament-forming protein, most muscle cells contain desmin, astrocytes contain glial fibrillary acidic protein (GFAP), neuronal cells contain neurofilament triplet proteins whereas the epithelia contains different keratin proteins. IF demonstration has been extensively used in human pathology (Osborn & Weber 1983). The demonstration of IF has also found a place in the study of normal and diseased canine and feline tissues (Andreasen et al. 1988, Moore et al. 1989, Desnoyers et al. 1990, Vos et al. 1992, Martín de las Mulas et al. 1994, Gimeno et al. 1995a, Fernández et al. 1998), but few studies have investigated the expression of IF proteins in bovine pathology (Weijman et al. 1987, Jansen et al. 1989, Weijman et al. 1990, Gimeno et al. 1994, Gimeno et al. 1995b).

The expression of different antigens as molecular markers for illegal oestrogen administration has already been undertaken. Among these markers, the immunodetection of cytokeratins has already proved to be more sensitive than conventional histology (Weijman et al. 1987, Jansen et al. 1989, Weijman et al. 1990, 1992) but the requirement of frozen sections has precluded its routine use.

Formalin is the most common fixative employed in

diagnostic pathology laboratories. However, the use of formalin fixation implies significant problems in immunohistochemical studies, as its time dependent cross-linking action that can mask many antigens (Fox et al. 1985, Puchtler & Meloan 1985, Gown et al. 1993).

In this work the potential usefulness of molecular markers for the detection of illegal oestrogen administration was evaluated. For this purpose, prostatic lesions from animals inoculated under controlled conditions and random samples from oestrogen treated bullocks (OTB) collected at abattoirs and positive to the "Prostate test" were compared.

MATERIALS AND METHODS

Tissue samples

Bovine prostatic tissue samples were collected at two abattoirs in Argentina by veterinary inspectors from the National Animal Health Service.

Ten bovine males, two to three years old, 400 kg live body weight, were bullocks castrated when they were three to seven months old. These animals were divided into two groups: 1) bullocks of well known origin neither oestrogen inoculated nor fed in oestrogen-pasture or with a supplementary diet, and 2) cases highly positive to the "Prostate test", according to the method of Ruitenbergh et al. (1970). The latter group was named as oestrogen treated bullocks (OTB). Doses and time of inoculation were not confirmed.

Samples were also collected from five experimentally oestrogen inoculated bullocks (group A). DES was administered by a parenteral injection of 50mg/100 kg body weight on five animals in a single dose. The animals were sacrificed 21 days post inoculation (short-term experiment, examination of the reaction 21 days after inoculation). A second experimental group of five animals was administered a parenteral injection of 50mg/100 kg body weight in a single dose and sacrificed 90 days post inoculation (long term experiment) (group B).

All the samples were taken from the body of the prostatic gland of bullocks, and fixed in 10% formaldehyde.

Immunohistochemical examination

Based on a previous study in which a wide range of tissue markers were evaluated (Gimeno et al. 1996), the following monoclonal antibodies (m Ab) were selected: against cytokeratins 13 and 16, clone K8.12 (Sigma Co.) diluted 1:40, against vimentin, clone V9 (Dako Co) prediluted, and against desmin, clone DER 11 (Dako Co) prediluted.

Five micrometers paraffin embedded sections, mounted on slides coated with poly-L-Lysine (Sigma Diagnostics, Saint Louis, MO, USA) were deparaffinized with xylene, incubated with 0.03% methanolic hydrogen peroxide for 30 minutes at room temperature to inhibit endogenous peroxidase activity, dehydrated through a series of increasing concentrated ethanol solutions, and rinsed successively in deionized water and phosphate buffered saline (PBS), pH 7.6.

To overcome the effects of overfixation, a new physical antigen retrieval (AR) method based on ultrasound (US) and developed at our laboratory (Portiansky & Gimeno 1996) was used in the present study. This technique is more efficient in detecting IF compared with other retrieval methods (Portiansky et al. 1997).

A double AR method, combining microwave (MW) and US was applied only as a trial on some samples, according to previously described techniques on MW (Shi et al. 1991, Leong & Gilham 1989, Leong & Milios 1993, Gown et al. 1993, Beckstead 1994, Taylor et al.

1994, Shi et al. 1995). Non retrieval samples were used as controls.

The EnVision System Kit (Dako, Carpinteria, CA, USA) for polyclonal and monoclonal antibodies was used as immunohistochemical detection system. This kit is based on a dextran polymer coupled to horseradish peroxidase and secondary antibodies (Vyberg & Nielsen 1998). Positively stained cells showed a golden dark brown 3,3'-diaminobenzidine tetrahydrochloride-H₂O₂ reaction product. After counterstaining with alcoholic haematoxylin the slides were dehydrated and mounted for examination.

In control sections, the primary antibody was replaced by normal mouse serum.

Image processing and analysis

Histological images were captured from a microscope (Olympus BX50 system microscope, Tokyo, Japan) with an objective magnification of x40, through an attached video camera (Sony DXC-151A CCD color video camera, Tokyo, Japan) and digitized in a 24 bits true color TIFF format in a PC Pentium II 266 MHz, 64 Mb RAM, Flashpoint 128 frame grabber (Integral Technologies Inc., Indianapolis, IN, USA) software: Image Pro Plus for Windows v3.01 (Media Cybernetics, Silver Spring, MA, USA). The grid matrix of each of the images was calibrated so as to give a yield of 0.32 mm/pixel. The background correction operation was performed on each image in order to meaningfully compare the optical density (OD) of the different slides. To separate the immunostain (brown stain) from the haematoxylin stain (blue stain) the cube-based method of the color segmentation operation was applied. The brownish stain was selected with a sensitivity of 4 (maximum 5). A mask was then applied in order to make the separation of colors permanent. The images were then transformed to a 8 bit gray scale TIFF format. After spatial and intensity of light calibration of the images, the immunohistochemically stained area and the OD of the labelled reaction, defined by the antigen-antibody complex (Wells et al., 1993) was obtained. Values registered from the histograms obtained from at least 25 images of each slide were exported to a spreadsheet in order to perform the statistical analysis.

Statistical analysis

The variance analysis was used to evaluate differences between experimental groups. The Tuckey's method (Zar, 1984) was used as a post hoc test. Significant differences were defined as those with an error probability <0.05. Highly significant differences were defined as those with a P value <0.01.

RESULTS

Light microscopy

The lack of trophic hormones in the bullocks castrated at a prepubertal stage, resulted in marked hypoplasia of the secretory epithelial cells, and was accompanied by an increased presence of stromal cells. In the OTB-group, in addition to hyperplasia and/or squamous metaplasia in the glandular epithelium, hyperplasia of the urethral and collector ducts epithelia was also present. Mucous glands, like those present in the prostatic epithelia of bulls, were frequently present in the animals of this group. In the experimentally inoculated bullocks (groups A and B), the tissue changes were qualitatively similar to those present in the OTB-group (Table 1 and Table 2).

Immunohistochemistry

The K 8.12 mAb strongly stained basal cells whereas

Table 1. Immunohistochemical staining percentage of prostatic tissues in oestrogen-treated bullocks (OTB) and experimentally inoculated bullocks (A, B) after ultrasound antigen retrieval

Bullocks ^a	Cytokeratin k.8.12	Vimentin	Desmin
OTB	11.76±1.2	0.50±0.1	4.71±0.5
Group A	27.26±3.4	0.71±0.1	5.42±1.1
Group B	12.68±1.3	8.19±2.3	14.32±1.5

^aOTB: Oestrogen treated bullocks

Group A: Short term experiment, animals sacrificed 21 days post oestrogen inoculation.

Group B: Long term experiment, animals sacrificed 90 days post oestrogen inoculation.

Table 2. Immunohistochemical staining percentage of prostatic tissues in experimentally inoculated bullocks (A, B) after double antigen retrieval

Bullocks ^a	Cytokeratin k.8.12	Vimentin	Desmin
Group A	23.39±4.4	22.69±2.1	14.73±2.0
Group B	27.30±1.9	15.09±1.3	23.21±1.8

^aGroup A: Short term experiment, animals sacrificed 21 days post oestrogen inoculation.

Group B: Long term experiment, animals sacrificed 90 days post oestrogen inoculation.

luminal cells were unstained (Fig. 1). In the OTB-group (Fig. 2) and samples from A (Fig. 3) and B (Fig. 4) groups, the monoclonal antibody stained basal and proliferating cells. Vimentin was clearly marked after epitope retrieval in all the groups and its immunostaining highlighted the relative increase in mesenchymal elements in the castrated animals (Fig. 5).

Smooth muscle cells were readily detected by immunostaining of desmin after antigen retrieval. They formed tiny sheaths around the acini or alternatively, broad strands separating larger parts of the gland. (Fig. 6). The amount of desmin stained tissue increased in the OTB-group and in samples of animals experimentally inoculated.

Sections that were immunostained without AR treatment gave negative or had weak results, whereas after AR, an increase in staining intensity was found in the samples with all the applied antibodies.

The double AR method (MW plus US) utilized to unmask cytokeratins in the prostatic epithelium of the B experimental group revealed a dramatic increase in staining intensity compared with the single AR method.

Image analysis

Our results show that the immunohistochemical staining percentage (IHC%) for cytokeratins in the experimental group A was significantly higher ($p < 0.01$) than the results in the OTB group as well as those in the samples from group B. Meanwhile, the B experimental group, who had received the same dosis but had been sacrificed 90 days latter, showed results similar to the samples from the OTB group. The IHC% from the group B was lower compared with that from group A.

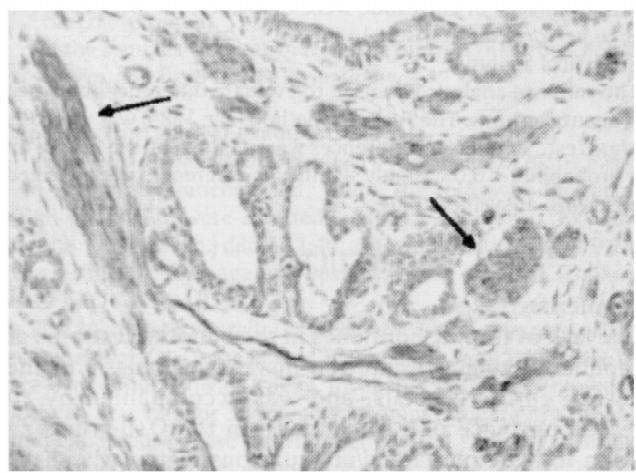
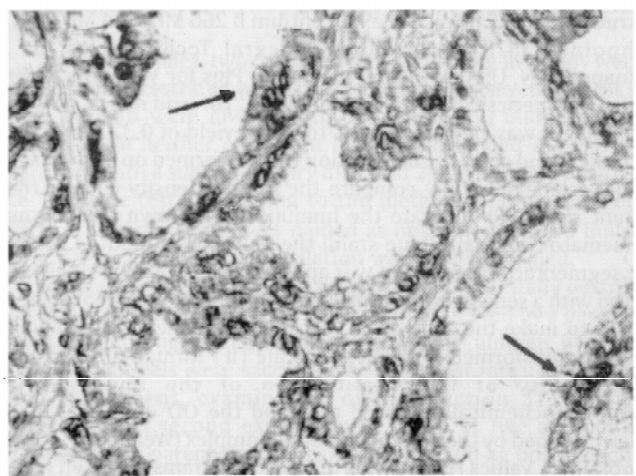
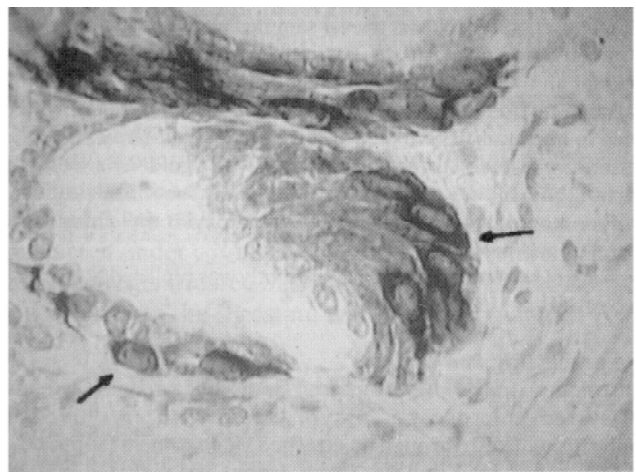
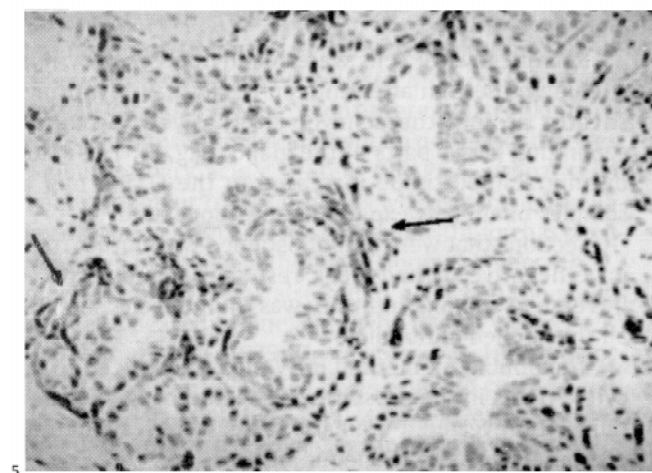
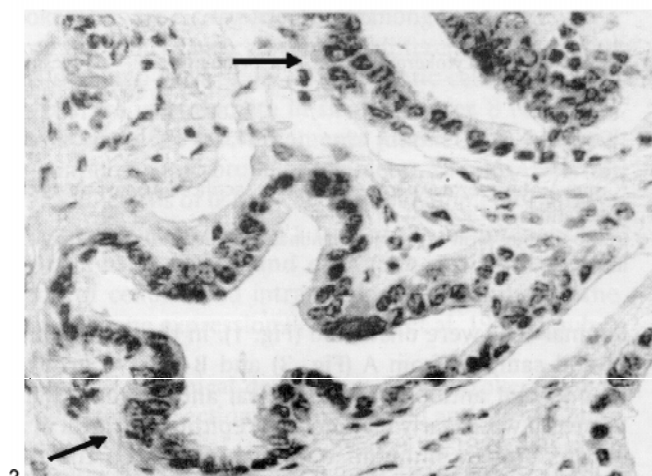
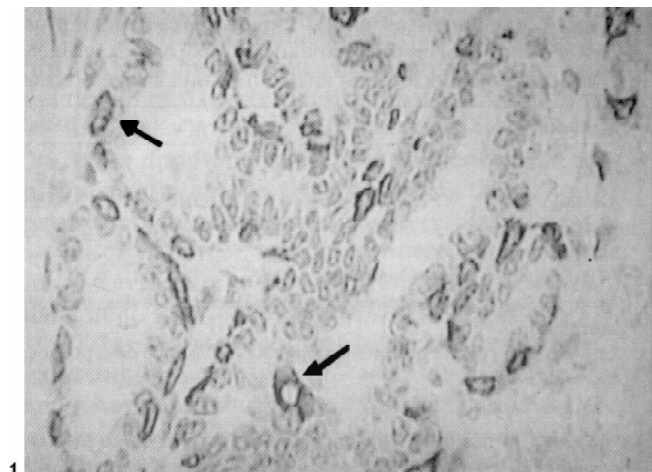


Fig. 1. Atrophic prostate gland of a bullock. Basal cell immunostaining by monoclonal antibody K 8.12; luminal cells are negative. Arrows show the positive reaction. Obj. 20.

Fig. 3. Prostate gland of an experimentally inoculated bullock (group A: short term experiment). Monoclonal antibody K.8.12 stained hyperplastic/metaplastic cells. Arrows show the positive reaction. Obj. 40.

Fig. 5. Prostate gland of a treated bullock. Demonstration of Vimentin in the connective tissue. Arrows show the positive reaction. Obj. 20.

Fig. 2. Prostate gland of an oestrogen treated bullock (OTB). Monoclonal antibody K 8.12 stained hyperplastic/metaplastic cells. Arrows show the positive reaction. Obj. 20.

Fig. 4. Prostate gland of an experimentally inoculated bullock (group B: long term experiment). Monoclonal antibody K.8.12 stained hyperplastic/metaplastic cells. Arrows show the positive reaction. Obj. 40.

Fig. 6. Prostate gland of a treated bullock. Demonstration of desmin in smooth muscle cells. Arrows show the positive reaction. Obj. 20.

The IHC % for vimentin and desmin was significantly higher ($p < 0.01$) after applying double AR methods on samples from groups A and B.

DISCUSSION

Histological examination of the prostate has been widely used as a screening method for the illegal administration of DES (Ruitenbergh et al. 1970, Kroes et al. 1971). The advantages of histology are broad screening, fast results and low costs (Groot 1992). Epithelial hyperplasia and squamous metaplasia are the basic changes that are used as an indication of oestrogen administration. Our studies suggest that bullocks castrated at a young age lack mucous glandular tissue, and those elements reappear after oestrogen treatment. Mucous glands are always present in the prostate of normal calves and bulls, either in separate acini or in intimate association with the secretory epithelial cells. The glandular epithelium has the potential to differentiate to various cell types (Bonkhoff et al. 1994), and apparently also to mucous cells (Shiraishi et al. 1993). Further studies are needed to clarify if the mucous metaplasia in the OTB animals has any relation to DES administration due to the fact that according to our experiments the tissue changes present in samples of prostatic tissue in the OTB animals and inoculated animals were alike.

Our material was fixed in 10 % formaldehyde, which is the most widely used fixative in diagnostic histopathology. However, formalin fixation impairs or, in some instances, totally destroys the immunoreactivity of many antigens. This is particularly the case after long exposure to the fixative (Leong & Gilham 1989).

Although our understanding of the formalin fixation process remains incomplete, it is generally accepted that the cross-linking of proteins produced by formalin fixation is the main factor in the impairment of antigen availability (Puchtler & Meloan 1985). Antigen retrieval of the sections before immunostaining results in a considerable improvement of the reaction obtained against many antigens (Shi et al. 1991, Gown et al. 1993, Leong & Milios 1993, Beckstead 1994, Taylor et al. 1994, Shi et al. 1995, Portiansky & Gimeno 1996, Portiansky et al. 1997). The present work confirms the remarkable unmasking effect on antigens in formalin fixed tissues by antigen retrieval methods.

The expression of cytokeratins has been found to vary with epithelial differentiation (Moll et al. 1982). The m Ab K8.12, which is specific for cytokeratins 13 and 16, stained the basal cells in all the groups as well as the hyperplastic-metaplastic cells. Although in a very different pattern of reactivity our results agree with previous studies that demonstrated cytokeratin 13 and 16 in basal cells and in hyperplastic cells (Verhagen et al. 1988, Weijman et al. 1990, Sherwood et al. 1991, Weijman et al. 1992, Bonkhoff et al. 1994), and seem to confirm the observation that proliferation induced by hormone administration starts in basal elements (Verhagen et al. 1988, Weijman et al. 1992). Electron microscopic studies have shown that the metaplastic changes, due to DES exposure, originate from the basal cells (Kroes & Teppema 1972).

Regarding vimentin, it was clearly marked after antigen retrieval techniques in all the samples. Its immunostaining highlighted the relative increase in mesenchymal elements in the animals related to DES. Muscle cells were also detected by immunostaining of desmin after AR. Smooth muscle cells were less prominent in the castrated animals, and the amount of stained tissue increased in the OTB and in the experimental samples.

In conclusion, the immunodetection of cell specific markers appears to be a useful adjunct to the histological examination of the prostate as an evaluation of the presence of illegal oestrogen administration in cattle.

Although image analysis cannot quantify the amount of DES administered, it does quantify the OD of the immunostained area, which is an approximation of the immunocomplexes present in the tissue (Wells et al. 1993). It is also concluded that the antibodies tested in our study can be effectively applied in tissues fixed in formalin for long periods, after AR methods. Furthermore, it is established that oestrogens cause reversible changes in the tissues. In the animals of group B, our results display signs of repair (change of metaplastic tissue into normal glandular epithelium) 90 days after the administration of oestrogen, although typical metaplastic changes of the glandular epithelium are still present. Inequivocal changes in the tissues arising from the suspicion of hormone administration on the basis of morphological changes, whether oestrogens are still present in the organism or not.

Acknowledgements.- The authors thank CONICET (National Scientific Research Council, Argentina) for partial support. E.J.G. and E.L.P. are Research Career Members of CONICET. P.E.F. is a scholarship member from CIC (Scientific Research Commission of the Province of Buenos Aires). Our gratitude to Mrs. Rosa Villegas de Guidi for her skilful technical assistance and to Miss Adela Heras for the proofreading of the manuscript.

REFERENCES

- Alberts B., Bray D., Lewis J., Raff M., Roberts K. & Watson J.D. 1994. The cytoskeleton, p. 788-841. In: *Molecular Biology of the Cell*. Third Edition. Editor Garland Publishing Inc., New York and London.
- Allen E. & Doisy E.A. 1923. An ovarian hormone. Preliminary report on its localization, extraction and partial purification and action in test animals. *J. Am. Med. Assoc.* 81: 819.
- Anderton B.H. 1981. Intermediate filaments: a family of homologous structures. *J. Muscl. Res. Cell Motil.* 2:141-166.
- Andreasen C.B., Mahaffey E.A. & Duncan J.R. 1988. Intermediate filament staining in the cytologic and histologic diagnosis of canine skin and soft tissue tumors. *Vet. Pathol.* 25:343-349.
- Beckstead J.H. 1994. Improved antigen retrieval in formalin-fixed, paraffin-embedded tissues. *Appl. Immunohistochem.* 2:274-281.
- Bonkhoff H., Stein U. & Remberger K. 1994. Multidirectional differentiation in the normal, hyperplastic, and neoplastic human prostate: simultaneous demonstration of cell-specific epithelial markers. *Human Pathol.* 25:42-46.
- Brown J.B. 1955. Chemical methods for the determination of estradiol, estrone and estradiol in human urine. *Biochem. J.* 60:185.
- Denoyers M.M., Haines D.M. & Searcy G.P. 1990. Immunohistochemical detection of intermediate filament proteins in formalin fixed normal and neoplastic canine tissues. *Can. J. Vet. Res.* 54:360-365.
- Dryer R.L. 1956. Chemical assay of diethylstilboestrol. *Clin. Chem.* 23:30.
- Engst R & Sauerlich R. 1965. Lebensmittelhygienische Betrachtungen zur oestrogenen Mast von Schlachttieren. *Die Nahrung* 9:363.

- Epstein S.S. 1990. The chemical jungle: today's beef industry. *Int. J. Health Serv.* 20:277-280.
- Fernández P.E., Portiansky E.L., Barbeito C.G. & Gimeno E.J. 1998. Characterization of cytotrophoblastic-like cells present in subinvolutioned placental sites of the bitch. *Histol. Histopathol.* 13:995-1000.
- Fox C.H., Johnson F.B., Whiting J. & Roller P.P. 1985. Formaldehyde fixation. *J. Histochem. Cytochem.* 33:845-853.
- Gimeno E.J., Idiart J.R., Massone A.R. & Nakayama H. 1994. Double immunoenzymatic detection of intermediate filaments in neoplasms of the bovine urinary bladder. *J. Comp. Pathol.* 111:15-20.
- Gimeno E.J., Massone A.R., Marino F.P. & Idiart J.R. 1995a. Intermediate filament expression and lectin histochemical features of canine transmissible venereal tumour. *APMIS* 103:645-650.
- Gimeno E.J., Sanguinetti H.R., Massone A.R., Kaloghlian A.S., Fernández P.E., Marino F.P. & Idiart J.R. 1995b. Detección de la administración de estrógenos en novillos por análisis inmunohistoquímico de marcadores celulares en la próstata. *Revta Argent. Prod. Anim.* 15:3/4, 803-806.
- Gown A.M., Weber N. & Battifora H. 1993. Microwave-based antigen unmasking. A revolutionary new technique for routine immunohistochemistry. *Appl. Immunohistochem.* 1:256-266.
- Groot M.J. 1992. Histological screening for illegal administration of growth promoting agents in veal calves. Dissertation, Utrecht.
- Herbst A.L., Robboy S.J., Scully R.W. & Poskanzer D.C. 1974. Adenocarcinoma of the vagina: association of maternal stilbestrol therapy with tumor appearance in young women. *New Engl. J. Med.* 284:878-881.
- Huis in't Veld L.G., Jonkman-van den Broek E.B., Groot W.C. & Krusel H.C. 1969. Het ge aan stoffen met oestrogene werking in de musculatuur van de injectieplaats en in de urine van kal na toediening van diethylstilboestrol en hexoestrol. *Tijdschr. Diergeneesk.* 94:169.
- Jansen A.H.J.M., Stephany R.W., Vos J.G., Ruitenber E.J., Benraad T.J., Boer F., Ruig W.G., Weijman J. & Schmidt N.A. 1989. Application of diethylstilbestrol dipropionate in bulls. I. Excretion of residues in urine and faeces and histological and immunohistochemical changes in the prostate. *Vet. Quarter.* 11:1-111.
- Kroes R., Berkvens J.M., Loendersloot H.J. & Ruitenber E.J. 1971. Oestrogen-induced changes in the genital tract of the male calf. *Zbl. Vet. Med. A* 18:717-730.
- Kroes R. & Teppema J.S. 1972. Development and restitution of squamous metaplasia in the calf prostate after a single estrogen treatment: an electron microscope study. *Exp. Molec. Pathol.* 16:286-301.
- Leong A.S.Y. & Gilham P.N. 1989. The effects of progressive formaldehyde fixation on the preservation of tissue antigens. *Pathology* 21:266-268.
- Leong A.S.Y. & Milios J. 1993. An assessment of the efficacy of the microwave antigen-retrieval procedure on a range of antigens. *Appl. Immunohistochem.* 1:267-274.
- Martin de las Mulas J.M., Espinosa de los Monteros A., Gomez-Villamandos J.C., Fernandez A. & Vos J.H. 1994. Immunohistochemical distribution of keratin proteins in feline tissues. *J. Vet. Med. A* 41:238-297.
- McMartin K.E., Kennedy K.A., Greenspan P., Alam S.N., Greiner P. & Yam U. 1978. DES: a review of its toxicity as a growth promotant in food-producing animals. *Pathol. Toxicol.* 1:279-313.
- Miettinen M., Lehto V.P. & Virtanen I. 1984. Antibodies to intermediate filament proteins in the diagnosis and classification of human tumors. *Ultrastr. Pathol.* 7:83-107.
- Moll R., Franke W.W., Schiller D.L., Geiger B. & Krepler R. 1982. The catalogue of human cytokeratins: patterns of expression in normal epithelia, tumors and cultured cells. *Cell.* 31:11-24.
- Moore A.S., Madewell B.R. & Lund J.K. 1989. Immunohistochemical evaluation of intermediate filament expression in canine and feline neoplasms. *Am. J. Vet. Res.* 50:88-92.
- Osborn M. & Weber K. 1983. Tumor diagnosis by intermediate filament typing: a novel tool for surgical pathology. *Labor. Invest.* 48:372-394.
- Portiansky E.L. & Gimeno E.J. 1996. A new epitope retrieval method for the detection of structural cytokeratins in the bovine prostatic tissue. *Appl. Immunohistochem.* 4 (3):208-214.
- Portiansky E.L., Massone A.R. & Gimeno E.J. 1997. Kinetics of epitope retrieval techniques for unmasking cytokeratins in bovine prostatic tissues after different formaldehyde fixation times. *Appl. Immunohistochem.* 5:194-201.
- Puchtler H. & Meloan S.N. 1985. On the chemistry of formaldehyde fixation and its effects on immunohistochemical reactions. *Histochem.* 82:201-204.
- Ramaekers F., Broers J. & Vooijs G. 1986. Immunocytochemistry of intermediate filament proteins, p. 390-400. In: Polak J.M. & Van Noorden S. (ed.) *Immunocytochemistry: modern methods and applications.* Wright Wright, Boston.
- Ruitenber E.J., Kroes R. & Berkvens J. 1970. Evaluation of the "Prostate test" in checking the administration of oestrogens in the calf. *Zbl. Vet. Med. A* 17:351-357.
- Sherwood E.R., Theyer G., Steiner G., Berg L.A., Kozlowski J.M. & Lee C. 1991. Differential expression of specific cytokeratin polypeptides in the basal and luminal epithelia of the human prostate. *Prostate* 18:303-314.
- Shi S.R., Key M.E. & Kalra K.L. 1991. Antigen retrieval in formalin-fixed, paraffin-embedded tissues: an enhancement method for immunohistochemical staining based on microwave oven heating of tissue sections. *J. Histochem. Cytochem.* 39:741-748.
- Shi S.R., Imam S.A., Young L., Cote R.J. & Taylor C.R. 1995. Antigen retrieval immunohistochemistry under the influence of pH using monoclonal antibodies. *J. Histochem. Cytochem.* 43:193-201.
- Shiraishi T., Kusano I., Watanabe M., Yatani R. & Liu P.I. 1993. Mucous gland metaplasia of the prostate. *Am. J. Surg. Pathol.* 17:618-622.
- Taylor C.R., Shi S.R., Chaiwun B., Young L., Imam S.A. & Cote R.J. 1994. Strategies for improving the immunohistochemical staining of various intranuclear prognostic markers in formalin-paraffin sections: androgen receptor, estrogen receptor, progesterone receptor, p53 protein, proliferating cell nuclear antigen, and Ki-67 antigen revealed by antigen retrieval techniques. *Human Pathol.* 25:263-270.
- Traub P. & Shoeman R.L. 1994. Intermediate filament proteins: cytoskeletal elements with gene-regulatory function? *Int. Rev. Cytol.* 154:1-103.
- Verhagen A.P.M., Aalders T.W., Ramaekers F.C.S., Debryne F.M.J. & Schalken J.A. 1988. Differential expression of keratins in the basal and luminal compartments of rat prostatic epithelium during degeneration and regeneration. *Prostate* 13:25-38.
- Vos J.H., van den Ingh T.S.G.A.M., de Neijis M., van Mil F.N., Ivanyi D. & Ramaekers F.C.S. 1992. Immunohistochemistry with keratin monoclonal antibodies in canine tissues: urogenital tract, respiratory tract, neuroendocrine tissues, choroid plexus and spinal cord. *J. Vet. Med. A* 39:721-740.
- Vyberg M. & Nielsen S. 1998. Dextran Polymer Conjugate Two Step Visualization System for Immunohistochemistry. A comparison of EnVision+ With Two Three-Step Avidin-Biotin Techniques. *Appl. Immunohistochem.* 6:3-10.
- Weijman J., Ramaekers F.C.S. & Vos J.G. 1987. Immunohistochemie van cytokeratines in prostaatweefsel als mogelijk gevoelige methode voor screening van met oestrogene anabolica behandelde mestkalveren. *Tijdschr. Diergeneesk.* 112:507-513.
- Weijman J., Ramaekers F.C.S., Elsinghorst Th.A.M., van Wichen P.J. & Zwart P. 1990. Immunohistochemistry of cytokeratins in prostate glandular epithelium as a sensitive method to detect (illegal) administration of oestrogens in cattle. European Research Conference of Veterinary Medicine, May 21-23, The Netherlands.
- Weijman J., Ramaekers F.C.S., Elsinghorst Th.A.M., van Wichen P.J. & Zwart P. 1992. Changing cytokeratin expression patterns in diethylstilbestrol dipropionate-induced metaplastic lesions of the goat prostate. *Vet. Quart.* 14:2-7.
- Wells W.A., Rainer R.O. & Memoli V.A. 1993. Equipment, standardization and application of image processing. *Am. J. Clin. Pathol.* 99: 48-56.
- Zar J.H. 1984. Multiple comparisons, p. 185-205. In: *Biostatistical Analysis.* Prentice Hall, Englewood Cliffs, NJ.