

Review article

Korean J Pediatr 2016;59(10):395-401

<https://doi.org/10.3345/kjp.2016.59.10.395>

pISSN 1738-1061 • eISSN 2092-7258



CrossMark
click for updates



Enterovirus 71 infection and neurological complications

Kyung Yeon Lee, MD, PhD

Department of Pediatrics, Ulsan University Hospital, University of Ulsan College of Medicine, Ulsan, Korea

Since the outbreak of the enterovirus 71 (EV71) infection in Malaysia in 1997, large epidemics of EV71 have occurred in the Asia-Pacific region. Many children and infants have died from serious neurological complications during these epidemics, and EV71 infection has become a serious public health problem in these areas. EV71 infection causes hand, foot and mouth disease (HFMD) in children, and usually resolves spontaneously. However, EV71 occasionally involves the central nervous system (CNS), and induces diverse neurological complications such as brainstem encephalitis, aseptic meningitis, and acute flaccid paralysis. Among those complications, brainstem encephalitis is the most critical neurological manifestation because it can cause neurogenic pulmonary hemorrhage/edema leading to death. The characteristic clinical symptoms such as myoclonus and ataxia, cerebrospinal fluid (CSF) pleocytosis, and brainstem lesions on magnetic resonance imaging, in conjunction with the skin rash of HFMD and the isolation of EV71 from a stool, throat-swab, or CSF sample are typical findings indicating CNS involvement of EV71 infection. Treatment with intravenous immunoglobulin and milrinone are recommended in cases with severe neurological complications from EV71 infection, such as brainstem encephalitis. Despite the recent discovery of receptors for EV71 in human cells, such as the scavenger receptor B2 and P-selection glycoprotein ligand 1, it is not known why EV71 infection predominantly involves the brainstem. Recently, 3 companies in China have completed phase III clinical trials of EV71 vaccines. However, the promotion and approval of these vaccines in various countries are problems yet to be resolved.

Key words: Human enterovirus 71, Neurological manifestations, Brain stem, Pulmonary edema, Vaccines

Corresponding author: Kyung Yeon Lee, MD, PhD
Department of Pediatrics, Ulsan University Hospital, 877 Bangeojinsunhwan-doro, Dong-gu, Ulsan 44033, Korea
Tel: +82-52-250-8980,
Fax: +82-52-250-7068,
E-mail: pdsnoopy@naver.com

Received: 15 August, 2015

Revised: 14 October, 2015

Accepted: 14 October, 2015

Introduction

Enterovirus 71 (EV71) is one of the main causative pathogens of hand, foot and mouth disease (HFMD). Since EV71 occasionally involves the central nervous system (CNS) and can cause serious and potentially fatal neurological complications, it has emerged as a major concern among pediatric infectious diseases, particularly in the Asia-Pacific region^{1,2}. EV71 is a single-stranded RNA virus that belongs to the human enterovirus A species of the Picornaviridae family. EV71 was first identified in California in 1969 and described by Schmidt et al. in 1974³. Epidemic outbreaks with high mortality rates occurred in Europe in the 1970s (Bulgaria in 1975 and Hungary in 1978)^{4,5}. The first major EV71 outbreak in the Asia-Pacific region occurred in 1997 in Malaysia and caused 41 child deaths⁶. Since then, large-scale epidemics of EV71 have been reported in many Asia-Pacific countries including Taiwan, Australia, China, Singapore, Vietnam, and Cambodia, and have caused many fatalities⁷⁻¹⁴. In 1998, a major epidemic of EV71 in Taiwan caused 1.5 million infections, 405 with severe neurological complications, and 78 child deaths^{7,8}.

Copyright © 2016 by The Korean Pediatric Society

This is an open-access article distributed under the terms of the Creative Commons Attribution Non-Commercial License (<http://creativecommons.org/licenses/by-nc/3.0/>) which permits unrestricted non-commercial use, distribution, and reproduction in any medium, provided the original work is properly cited.

More than 7 million HFMD cases and 2,457 deaths were reported in China during EV71 epidemics between 2008 and 2012^{9,10}. Recently, EV71 epidemics have been reported in the USA and European countries outside the Asia-Pacific region, such as the Netherlands, France, Norway, the UK, Hungary, and Greece¹⁵⁻²¹. In Korea, epidemics of EV71 infection occurred between 2009 and 2013 and included fatal cases. According to one report²², which compared the viral pathogens and clinical features of HFMD between 2008 and 2009 in Korea using data from a nationwide surveillance system, the main causative viruses were coxsackievirus A10 and echovirus 30 in 2008, whereas the chief pathogen in 2009 was EV71. During this period, the prevalence of accompanying meningoencephalitis increased considerably, from 4.0% to 15.2%. The main subgenotype of EV71 detected during 2009 and 2012 in Korea was C4a, which is nearly identical to the EV71 genotype detected in China in 2008²³.

In this review, the author will discuss the clinical features and neurological manifestations of EV71 infection, focusing on brainstem encephalitis, the magnetic resonance imaging (MRI) findings for neurological complications, the pathophysiology, diagnosis, treatment, and prognosis for EV71 infection with CNS involvement, and the development of new vaccines.

Clinical features of EV71 infection

As mentioned above, EV71 infection causes HFMD in children, and this usually resolves spontaneously. However, EV71 can cause more severe neurological complications compared with other enterovirus serotypes, including brainstem encephalitis and acute flaccid paralysis^{2,24}. According to clinical studies conducted in northern Taiwan²⁵⁻²⁷, symptomatic EV71 infection is divided into 4 stages: HFMD/herpangina (stage 1), CNS involvement (stage 2), cardio-pulmonary failure (stage 3), and convalescence (stage 4). Most EV71 cases remain at stage 1, some progress to stage 2, and a few advance to the most severe condition, stage 3. Some survivors of stage 3 have long-term sequelae during convalescence (stage 4).

The majority of patients with neurological complications of EV71 infection have been under the age of 5 years^{28,29}. The peak seasons for the disease are late spring to summer, although infections occur with high incidence throughout the year in tropical areas. The patients usually have a high fever above 38°C, unlike HFMD caused by other enterovirus serotypes such as coxsackievirus A16³⁰. Neurological symptoms or signs appear within 3 to 5 days after the onset of fever or skin lesions³¹. Some patients show neurological manifestations without the skin or oral mucosal lesions typical of HFMD². Therefore, during EV71 epidemics, the neurological complications of EV71 infection should always be considered in children who develop neurolo-

gical diseases, even when patients show no skin lesions characteristic of HFMD. EV71 can be transmitted via contaminated hands; either directly from vesicles on the hands, secretions from the oropharynx, or feces³². The EV71 transmission rate to household contacts is approximately 50%²⁷. Transmission rates are approximately 80% between siblings and cousins³³. A total of 50% of infected adults are asymptomatic, but infected adults often spread the disease to preschool children. It is estimated that approximately 0.2%–1% of children with EV71 infection develop neurological complications³⁴.

Neurological manifestations of EV71 infection

1. Brainstem encephalitis

Brainstem encephalitis is the most common neurological presentation, accounting for 58% of neurological manifestations, followed by aseptic meningitis (36%), and brainstem encephalitis with cardiorespiratory dysfunction (4%)²⁹. Despite the recent discovery of receptors for EV71 in human cells^{35,36}, the reason for the predominant involvement of the brainstem in EV71 infection is currently unknown. EV71 brainstem encephalitis occasionally induces autonomic dysfunction, such as fluctuating blood pressure and pulmonary hemorrhage/edema (Fig. 1). Most deaths caused by pulmonary hemorrhage in patients with EV71 brainstem encephalitis usually occur within 24 hours after admission because the disease rapidly progresses to the critical stage^{2,37}.

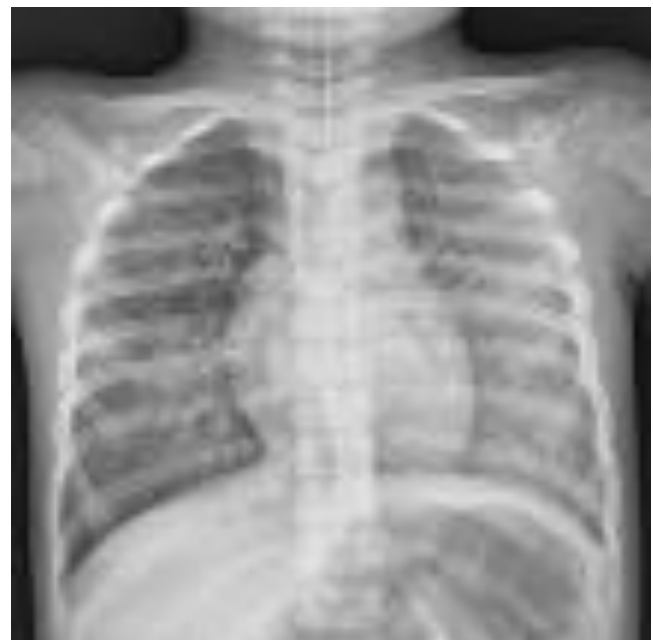

Fig. 1. Chest radiograph of a patient with enterovirus 71 infection presenting with pulmonary hemorrhage and shock. Note the diffuse haziness on both lungs.

Therefore, early diagnosis of EV71 infection with neurological involvement and prompt, appropriate management is crucial. EV71 brainstem encephalitis has been defined as an illness characterized by myoclonus, ataxia, nystagmus, oculomotor palsies, and bulbar palsy, and various combinations of these, with or without confirmation by neuroimaging, in conjunction with virus isolation from at least one site (throat swab, stool, cerebrospinal fluid [CSF], or other)^{29,38}. According to one Taiwanese report, the most prominent neurological presentations for EV71 CNS involvement are myoclonic jerk (68%), vomiting (53%), ataxia (35%), and tremor (21%)²⁹. Myoclonus in patients with EV71 brainstem encephalitis occurs during wakefulness and deep sleep, as well as during light sleep, and may appear very frequently, unlike sleep myoclonus^{30,39}. Myoclonus is not only the most common symptom, but also an early indicator of brainstem involvement in EV71 infection^{2,24}. However, physicians and parents often overlook myoclonus as a nonspecific symptom of febrile illnesses in children with HFMD due to EV71 infection, which may possibly lead to the misdiagnosis of brainstem encephalitis as a benign condition. Hence, all patients with suspected EV71 infection should be carefully observed for all clinical symptoms, including myoclonus and ataxia that are the characteristic clinical features of brainstem encephalitis. Ataxia is also a frequent neurological feature in EV71 brainstem encephalitis^{24,29}. Although ataxia has been sometimes reported as a main clinical feature of acute cerebellar ataxia due to EV71 infection^{2,9}, it more often appears together with other clinical features of brainstem encephalitis, such as myoclonus and tremor²⁹. In addition, patients with EV71 brainstem encephalitis frequently reveal concurrent lesions of the cerebellum and brainstem on brain MRI.

2. Aseptic meningitis

Aseptic meningitis is also a main neurological presentation in EV71 infection. Some studies have noted that aseptic meningitis

is the most common neurological complication of EV71 infection^{30,40}, although many other studies have reported brainstem encephalitis as the most common neurological complication^{24,29}. Aseptic meningitis from EV71 is clinically indistinguishable from that of other viruses that present with headache, fever, and recurrent emesis without any other neurological manifestations. Although EV71 aseptic meningitis is usually considered a more benign condition compared with brainstem encephalitis, patients with clinical aseptic meningitis from EV71 infection may show brainstem lesions on MRI³¹.

3. Acute flaccid paralysis

Acute flaccid paralysis is also one of the major presenting features among several neurological syndromes caused by EV71 infection, along with brainstem encephalitis and aseptic meningitis. It usually presents like poliomyelitis with acute motor weakness of the extremities, but unlike poliomyelitis, the recovery rate is relatively high². Guillain-Barré syndrome and transverse myelitis have also been reported in patients with acute motor weakness of the extremities and EV71 infection⁹.

MRI findings of neurological complications

The characteristic MRI findings of EV71 brainstem encephalitis are high signal intensities on T2-weighted and fluid-attenuated inversion recovery images in the posterior region of the pons, medulla oblongata, midbrain, and bilateral dentate nuclei of the cerebellum (Fig. 2), although MR images may show normal findings^{2,41}. Rarely, some MRI reports have demonstrated the involvement of the cerebral cortex, subcortical white matter, thalamus, putamen, corpus callosum, and hippocampus instead of the brainstem in patients with EV71 infection⁴²⁻⁴⁵. Although the clinical features are positively correlated with the MRI

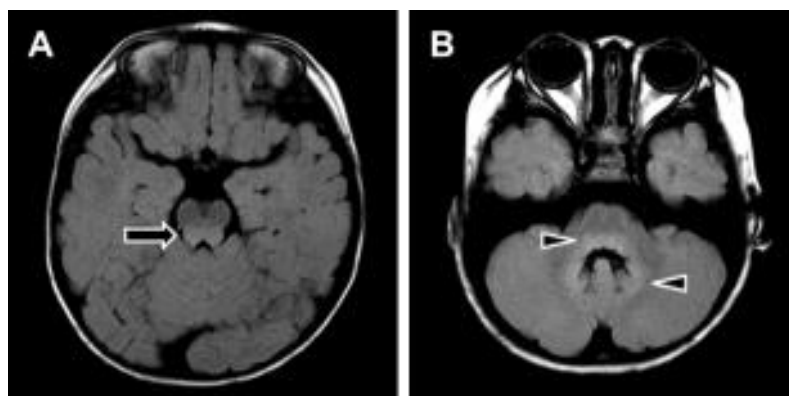


Fig. 2. Brain magnetic resonance imaging findings in a patient with enterovirus 71 brainstem encephalitis. (A) Note the high signal-intensity lesion in the posterior aspect of the midbrain (arrow). (B) Note the high signal-intensity lesion in the posterior aspect of the pons and the bilateral dentate nuclei of the cerebellum (arrowheads).

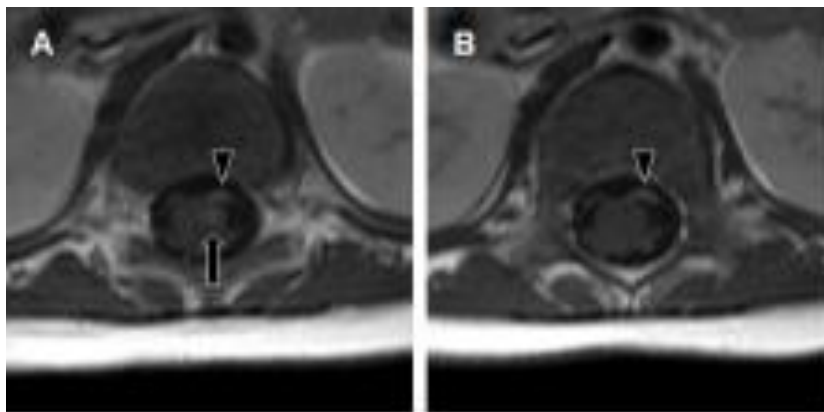


Fig. 3. Spine magnetic resonance imaging findings in a 4-month-old infant. The patient presented with acute motor weakness of the left lower extremity along with enterovirus 71 infection. (A, B) Note the strong enhancement of the left anterior horn of the spinal cord (arrow) and the left ventral nerve roots (arrowhead) on gadolinium-enhanced T1-weighted images.

findings^{41,44}, they are not necessarily consistent³¹. In patients with acute flaccid paralysis, MRI typically shows high-signal lesions in the anterior horn cells of the spinal cord on T2-weighted images, and contrast enhancement in the ventral root on T1-weighted images (Fig. 3)^{43,44}.

Pathophysiology of pulmonary hemorrhage/edema in EV71 brainstem encephalitis

Pathophysiologically, pulmonary hemorrhage/edema in EV71 brainstem encephalitis results from injury to the vasomotor center of the brainstem²⁴, which increases sympathetic outflow, and vasoconstriction leads to a shift of blood from the highly resistant systemic circulation to the less-resistant pulmonary circulation. Hydrodynamic studies of patients with pulmonary edema have demonstrated normal cardiac function and normal pulmonary hydrostatic pressure²⁴. Pathology studies revealed no necrosis or calcification in the myocardium²⁴. Meanwhile, some studies have shown that the serum and CSF levels of proinflammatory cytokines (interleukin [IL]-6, tumor necrosis factor- α , IL-1 β , and interferon- γ) are significantly higher in patients with brainstem encephalitis accompanied by pulmonary edema than in those with uncomplicated brainstem encephalitis^{46–48}. These findings suggest that pulmonary hemorrhage/edema might be the result not only of direct hydrostatic force by systemic vasoconstriction resulting from brainstem injury, but also increased pulmonary vascular permeability caused by a systemic inflammatory response.

Recently, several molecules that act as cell surface receptors for EV71 have been identified, such as scavenger receptor B2 (SCARB2), P-selection glycoprotein ligand 1 (PSGL-1), annexin II (Anx2), sialylated glycan, and heparan sulfate^{35,36,49}. SCARB2

plays major roles in attachment, viral entry, and uncoating, and it can enable effective EV71 infection³⁵. In addition, SCARB2 plays key roles in the development of EV71 neurological disease *in vivo*. PSGL-1, Anx2, sialylated glycan, and heparan sulfate are attachment receptors, which potentiate viral infection^{36,49}. However, despite the discovery of these receptors, the reason for EV71 neurotropism on the brainstem is still unknown. A study using an orally infected EV71 murine model has suggested that EV71 enters the CNS via the active retrograde axonal-transport system⁵⁰. This implies the probability that mechanisms other than receptors for EV71 elicit EV71 brainstem encephalitis.

Virological diagnosis

Although the gold standard for the diagnosis of enterovirus infection is virus isolation via viral culture, this takes more than 7–10 days, and nowadays a molecular serotyping approach is usually employed for the virological diagnosis of EV71 using polymerase chain reaction and sequencing of the *VP1* gene². In patients with neurological complications, isolation of the virus from CSF is the most ideal approach for diagnosing EV71 infection. However, the detection rate for EV71 in CSF obtained from patients with neurological disease is very low (0%–5%)². EV71 is isolated mainly from throat or stool specimens, and occasionally from skin-vesicle fluid, rather than CSF^{2,34}. A Taiwan study showed that EV71 can be detected in the throat up to 2 weeks after recovery from HFMD or herpangina, and can be detected in stool samples up to 11 weeks after recovery⁵¹. Nevertheless, CSF examination is essential in patients with EV71 infection who have suspected CNS involvement to identify the presence not only of the virus but also pleocytosis in the CSF. A mild lymphocytic pleocytosis of 10–100 cells per μ L is typical,

although occasionally pleocytosis is not observed^{2,31}.

Treatment and prognosis

Regarding the treatment of EV71 infection, antiviral therapy is currently ineffective despite efforts to develop new antiviral agents⁵². A disease-management program developed in Taiwan in 2000 recommended the use of intravenous immunoglobulin and milrinone for the treatment of EV71 brainstem encephalitis²⁴. Intravenous immunoglobulin therapy provides neutralizing antibodies, decreases sympathetic outflow, and attenuates cytokine production. If the patient has a persistent heart rate of more than 180/min and even a high blood pressure, milrinone can be administered simultaneously²⁴. Milrinone is a drug for congestive heart failure, and has both inotropic and vasodilator properties⁵³. Milrinone also has anti-inflammatory effects⁵⁴. A recent prospective, open-label, randomized controlled study demonstrated that patients who were treated with intravenous milrinone (0.5 µg/kg/min) and intravenous immunoglobulin had a lower 1-week mortality rate compared with patients who were treated with dopamine or dobutamine and intravenous immunoglobulin (18.2% vs. 57.9%)⁵⁵.

CNS involvement with cardiopulmonary failure is associated with a high mortality rate (about 30%–40%) during the acute stage of the infection^{26,56}. In regard to the long-term outcome, one study conducted follow-up of 142 children after EV71 infection with CNS involvement, including 28 cases of cardiopulmonary failure (median follow-up of 2.9 years), and showed that CNS involvement with cardiopulmonary failure is associated with neurological sequelae (limb weakness and atrophy in 64% of patients, and a requirement for tube feeding in 61% and ventilator support in 57%), delayed neurodevelopment (75% of patients), and reduced cognitive function. By contrast, only 1 of 20 children (5%) with CNS involvement without cardiopulmonary failure showed delayed neurodevelopment⁵⁷.

Development of new vaccines

Recently, 3 companies have completed phase III clinical trials of inactivated EV71 whole-virus vaccines. More than 30,000 infants and children aged 6–71 months from 3 different regions of China were included in those clinical trials^{58–60}. The results demonstrated the high safety and immunogenicity of the EV71 vaccines. Protective efficacies were over 90% for EV71-associated HFMD and over 80% for serious EV71-associated diseases^{58–60}. The most common adverse reaction was fever. There were no critical vaccine-associated side effects or immunopathological responses during the study period^{58–60}. Despite the development

of new vaccines, the promotion and approval of these vaccines in various countries are problems yet to be resolved.

Conclusions

Epidemics of EV71 infection have caused many fatalities from serious neurological complications in the Asia-Pacific region since 1997, and have become a serious public health problem in these areas. Among the diverse neurological complications of EV71 infection, brainstem encephalitis is the most critical neurological manifestation, because it can cause pulmonary hemorrhage leading to death. During EV71 epidemics, the neurological complications of EV71 infection always should be considered in the differential diagnosis in children with neurological diseases. Early diagnosis and treatment with intravenous immunoglobulin and milrinone can reduce mortality and morbidity in patients with CNS involvement relating to EV71 infection. Recently, phase III clinical trials of 3 new EV71 vaccines were completed in China. However, it seems to take time for the promotion and approval of these vaccines to take effect in various countries.

Conflict of interest

No potential conflict of interest relevant to this article was reported.

References

1. McMinn PC. The emergence of enterovirus 71 as a major cause of acute neurological disease in young children of the Asia-Pacific region. *J Pediatr Infect Dis* 2006;1:17-23.
2. Ooi MH, Wong SC, Lewthwaite P, Cardoso MJ, Solomon T. Clinical features, diagnosis, and management of enterovirus 71. *Lancet Neurol* 2010;9:1097-105.
3. Schmidt NJ, Lennette EH, Ho HH. An apparently new enterovirus isolated from patients with disease of the central nervous system. *J Infect Dis* 1974;129:304-9.
4. Chumakov M, Voroshilova M, Shindarov L, Lavrova I, Gracheva L, Koroleva G, et al. Enterovirus 71 isolated from cases of epidemic poliomyelitis-like disease in Bulgaria. *Arch Virol* 1979;60:329-40.
5. Nagy G, Takatsy S, Kukan E, Mihaly I, Domok I. Virological diagnosis of enterovirus type 71 infections: experiences gained during an epidemic of acute CNS diseases in Hungary in 1978. *Arch Virol* 1982;71:217-27.
6. Chan LG, Parashar UD, Lye MS, Ong FG, Zaki SR, Alexander JP, et al. Deaths of children during an outbreak of hand, foot, and mouth disease in sarawak, malaysia: clinical and pathological characteristics of the disease. For the Outbreak Study Group. *Clin Infect Dis* 2000;31:678-83.
7. Shih SR, Ho MS, Lin KH, Wu SL, Chen YT, Wu CN, et al. Genetic analysis of enterovirus 71 isolated from fatal and non-fatal cases

- of hand, foot and mouth disease during an epidemic in Taiwan, 1998. *Virus Res* 2000;68:127-36.
8. Ho M, Chen ER, Hsu KH, Twu SJ, Chen KT, Tsai SF, et al. An epidemic of enterovirus 71 infection in Taiwan. Taiwan Enterovirus Epidemic Working Group. *N Engl J Med* 1999;341:929-35.
 9. cMinn P, Stratov I, Nagarajan L, Davis S. Neurological manifestations of enterovirus 71 infection in children during an outbreak of hand, foot, and mouth disease in Western Australia. *Clin Infect Dis* 2001;32:236-42.
 10. Zeng M, El Khatib NF, Tu S, Ren P, Xu S, Zhu Q, et al. Seroepidemiology of Enterovirus 71 infection prior to the 2011 season in children in Shanghai. *J Clin Virol* 2012;53:285-9.
 11. Yip CC, Lau SK, Woo PC, Yuen KY. Human enterovirus 71 epidemics: what's next? *Emerg Health Threats J* 2013;6:19780.
 12. Wu Y, Yeo A, Phoon MC, Tan EL, Poh CL, Quak SH, et al. The largest outbreak of hand; foot and mouth disease in Singapore in 2008: the role of enterovirus 71 and coxsackievirus A strains. *Int J Infect Dis* 2010;14:e1076-81.
 13. Thoa le PK, Chiang PS, Khanh TH, Luo ST, Dan TN, Wang YF, et al. Genetic and antigenic characterization of enterovirus 71 in Ho Chi Minh City, Vietnam, 2011. *PLoS One* 2013;8:e69895.
 14. Seiff A. Cambodia unravels cause of mystery illness. *Lancet* 2012;380:206.
 15. Fowlkes AL, Honarmand S, Glaser C, Yagi S, Schnurr D, Oberste MS, et al. Enterovirus-associated encephalitis in the California encephalitis project, 1998-2005. *J Infect Dis* 2008;198:1685-91.
 16. van der Sanden S, Koopmans M, Uslu G, van der Avoort H; Dutch Working Group for Clinical Virology. Epidemiology of enterovirus 71 in the Netherlands, 1963 to 2008. *J Clin Microbiol* 2009;47:2826-33.
 17. Mirand A, Schuffenecker I, Henquell C, Billaud G, Jugie G, Falcon D, et al. Phylogenetic evidence for a recent spread of two populations of human enterovirus 71 in European countries. *J Gen Virol* 2010;91(Pt 9):2263-77.
 18. Witso E, Palacios G, Ronningen KS, Cinek O, Janowitz D, Rewers M, et al. Asymptomatic circulation of HEV71 in Norway. *Virus Res* 2007;123:19-29.
 19. Bible JM, Iturriza-Gomara M, Megson B, Brown D, Pantelidis P, Earl P, et al. Molecular epidemiology of human enterovirus 71 in the United Kingdom from 1998 to 2006. *J Clin Microbiol* 2008;46:3192-200.
 20. Kapusinszky B, Szomor KN, Farkas A, Takács M, Berencsi G. Detection of non-polio enteroviruses in Hungary 2000-2008 and molecular epidemiology of enterovirus 71, coxsackievirus A16, and echovirus 30. *Virus Genes* 2010;40:163-73.
 21. Siafakas N, Attilakos A, Vourli S, Stefanos E, Meletiadi J, Nikolaidou P, et al. Molecular detection and identification of enteroviruses in children admitted to a university hospital in Greece. *Mol Cell Probes* 2011;25:249-54.
 22. Ryu WS, Kang B, Hong J, Hwang S, Kim J, Cheon DS. Clinical and etiological characteristics of enterovirus 71-related diseases during a recent 2-year period in Korea. *J Clin Microbiol* 2010;48:2490-4.
 23. Choi CS, Choi YJ, Choi UY, Han JW, Jeong DC, Kim HH, et al. Clinical manifestations of CNS infections caused by enterovirus type 71. *Korean J Pediatr* 2011;54:11-6.
 24. Wang SM, Liu CC. Enterovirus 71: epidemiology, pathogenesis and management. *Expert Rev Anti Infect Ther* 2009;7:735-42.
 25. Chang LY, Lin TY, Hsu KH, Huang YC, Lin KL, Hsueh C, et al. Clinical features and risk factors of pulmonary oedema after enterovirus-71-related hand, foot, and mouth disease. *Lancet* 1999;354:1682-6.
 26. Chang LY, Hsia SH, Wu CT, Huang YC, Lin KL, Fang TY, et al. Outcome of enterovirus 71 infections with or without stage-based management: 1998 to 2002. *Pediatr Infect Dis J* 2004;23:327-32.
 27. Chong P, Liu CC, Chow YH, Chou AH, Klein M. Review of enterovirus 71 vaccines. *Clin Infect Dis* 2015;60:797-803.
 28. Chen KT, Chang HL, Wang ST, Cheng YT, Yang JY. Epidemiologic features of hand-foot-mouth disease and herpangina caused by enterovirus 71 in Taiwan, 1998-2005. *Pediatrics* 2007;120:e244-52.
 29. Wang SM, Liu CC, Tseng HW, Wang JR, Huang CC, Chen YJ, et al. Clinical spectrum of enterovirus 71 infection in children in southern Taiwan, with an emphasis on neurological complications. *Clin Infect Dis* 1999;29:184-90.
 30. Hu Y, Jiang L, Peng HL. Clinical analysis of 134 children with nervous system damage caused by enterovirus 71 infection. *Pediatr Infect Dis J* 2015;34:718-23.
 31. Lee KY, Lee YJ, Kim TH, Cheon DS, Nam SO. Clinico-radiological spectrum in enterovirus 71 infection involving the central nervous system in children. *J Clin Neurosci* 2014;21:416-20.
 32. Wang SM, Liu CC. Update of enterovirus 71 infection: epidemiology, pathogenesis and vaccine. *Expert Rev Anti Infect Ther* 2014;12:447-56.
 33. Chang LY, Tsao KC, Hsia SH, Shih SR, Huang CG, Chan WK, et al. Transmission and clinical features of enterovirus 71 infections in household contacts in Taiwan. *JAMA* 2004;291:222-7.
 34. Lee MS, Chang LY. Development of enterovirus 71 vaccines. *Expert Rev Vaccines* 2010;9:149-56.
 35. Yamayoshi S, Yamashita Y, Li J, Hanagata N, Minowa T, Takemura T, et al. Scavenger receptor B2 is a cellular receptor for enterovirus 71. *Nat Med* 2009;15:798-801.
 36. Nishimura Y, Shimojima M, Tano Y, Miyamura T, Wakita T, Shimizu H. Human P-selectin glycoprotein ligand-1 is a functional receptor for enterovirus 71. *Nat Med* 2009;15:794-7.
 37. Lin TY, Chang LY, Hsia SH, Huang YC, Chiu CH, Hsueh C, et al. The 1998 enterovirus 71 outbreak in Taiwan: pathogenesis and management. *Clin Infect Dis* 2002;34 Suppl 2:S52-7.
 38. Huang MC, Wang SM, Hsu YW, Lin HC, Chi CY, Liu CC. Long-term cognitive and motor deficits after enterovirus 71 brainstem encephalitis in children. *Pediatrics* 2006;118:e1785-8.
 39. Lee KY, Yeh HR. Continuous myocloni and tonic spasms in a 2-month-old infant with enterovirus 71 brain stem encephalitis. *Neuropediatrics* 2015;46:52-5.
 40. Cho HK, Lee NY, Lee H, Kim HS, Seo JW, Hong YM, et al. Enterovirus 71-associated hand, foot and mouth diseases with neurologic symptoms, a university hospital experience in Korea, 2009. *Korean J Pediatr* 2010;53:639-43.
 41. Shen WC, Chiu HH, Chow KC, Tsai CH. MR imaging findings of enteroviral encephalomyelitis: an outbreak in Taiwan. *AJNR Am J Neuroradiol* 1999;20:1889-95.
 42. Jang S, Suh SI, Ha SM, Byeon JH, Eun BL, Lee YH, et al. Enterovirus 71-related encephalomyelitis: usual and unusual magnetic resonance imaging findings. *Neuroradiology* 2012;54:239-45.
 43. Li J, Chen F, Liu T, Wang L. MRI findings of neurological complications in hand-foot-mouth disease by enterovirus 71 infection. *Int J Neurosci* 2012;122:338-44.
 44. Zeng H, Wen F, Gan Y, Huang W. MRI and associated clinical characteristics of EV71-induced brainstem encephalitis in children with hand-foot-mouth disease. *Neuroradiology* 2012;54:623-30.
 45. Lian ZY, Huang B, He SR, Liang CH, Guo YX. Diffusion-weighted imaging in the diagnosis of enterovirus 71 encephalitis. *Acta Radiol* 2012;53:208-13.
 46. Lin TY, Chang LY, Huang YC, Hsu KH, Chiu CH, Yang KD. Different proinflammatory reactions in fatal and non-fatal enterovirus 71

- infections: implications for early recognition and therapy. *Acta Paediatr* 2002;91:632-5.
47. Lin TY, Hsia SH, Huang YC, Wu CT, Chang LY. Proinflammatory cytokine reactions in enterovirus 71 infections of the central nervous system. *Clin Infect Dis* 2003;36:269-74.
 48. Wang SM, Lei HY, Su LY, Wu JM, Yu CK, Wang JR, et al. Cerebrospinal fluid cytokines in enterovirus 71 brain stem encephalitis and echovirus meningitis infections of varying severity. *Clin Microbiol Infect* 2007;13:677-82.
 49. Yamayoshi S, Fujii K, Koike S. Receptors for enterovirus 71. *Emerg Microbes Infect* 2014;3:e53.
 50. Chen YC, Yu CK, Wang YF, Liu CC, Su IJ, Lei HY. A murine oral enterovirus 71 infection model with central nervous system involvement. *J Gen Virol* 2004;85(Pt 1):69-77.
 51. Chung PW, Huang YC, Chang LY, Lin TY, Ning HC. Duration of enterovirus shedding in stool. *J Microbiol Immunol Infect* 2001;34:167-70.
 52. Kung YA, Hung CT, Liu YC, Shih SR. Update on the development of enterovirus 71 vaccines. *Expert Opin Biol Ther* 2014;14:1455-64.
 53. Shipley JB, Tolman D, Hastillo A, Hess ML. Milrinone: basic and clinical pharmacology and acute and chronic management. *Am J Med Sci* 1996;311:286-91.
 54. Gong M, Lin XZ, Lu GT, Zheng LJ. Preoperative inhalation of milrinone attenuates inflammation in patients undergoing cardiac surgery with cardiopulmonary bypass. *Med Princ Pract* 2012;21:30-5.
 55. Chi CY, Khanh TH, Thoa le PK, Tseng FC, Wang SM, Thinh le Q, et al. Milrinone therapy for enterovirus 71-induced pulmonary edema and/or neurogenic shock in children: a randomized controlled trial. *Crit Care Med* 2013;41:1754-60.
 56. Wang SM, Lei HY, Huang MC, Wu JM, Chen CT, Wang JN, et al. Therapeutic efficacy of milrinone in the management of enterovirus 71-induced pulmonary edema. *Pediatr Pulmonol* 2005;39:219-23.
 57. Chang LY, Huang LM, Gau SS, Wu YY, Hsia SH, Fan TY, et al. Neurodevelopment and cognition in children after enterovirus 71 infection. *N Engl J Med* 2007;356:1226-34.
 58. Zhu FC, Meng FY, Li JX, Li XL, Mao QY, Tao H, et al. Efficacy, safety, and immunology of an inactivated alum-adjunct enterovirus 71 vaccine in children in China: a multicentre, randomised, double-blind, placebo-controlled, phase 3 trial. *Lancet* 2013;381:2024-32.
 59. Li R, Liu L, Mo Z, Wang X, Xia J, Liang Z, et al. An inactivated enterovirus 71 vaccine in healthy children. *N Engl J Med* 2014;370:829-37.
 60. Zhu F, Xu W, Xia J, Liang Z, Liu Y, Zhang X, et al. Efficacy, safety, and immunogenicity of an enterovirus 71 vaccine in China. *N Engl J Med* 2014;370:818-28.