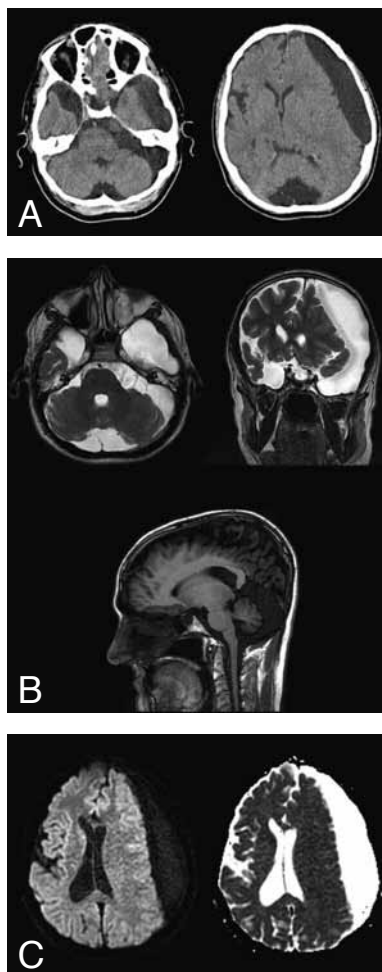


IMAGES IN CLINICAL RADIOLOGY



Multiple intracranial arachnoid cysts

G. Koc¹, C. Altay¹, T. Bozkurt¹, M. Varer¹, O. Oyar¹

A 26-year-old-man presented with intermittent headache for the last two years. The patient had no other medical history such as infection, subarachnoid hemorrhage, trauma or malignancies affecting central nervous system. A cranial CT and MR were performed. Cranial imaging revealed multiple arachnoid cysts located in right temporal fossa (Galassi type 2), left temporal fossa extending to the convexity (Galassi type 3), prepontine cistern extending to the cerebellopontine angle cistern and laterally to the left cerebellar hemisphere, cerebellar interhemispheric fissure (Fig. A). The arachnoid cyst was located left to the temporal fossa and extended to the convexity and caused a moderate shift in central cranial structures. The arachnoid cysts had the same signal intensity as cerebrospinal fluid in FLAIR and other conventional sequences (Fig. B). On diffusion MR, lesions had no restricted diffusion (Fig. C). No concomitant brain abnormality was identified. Neurological examination findings were not compatible with intracranial stasis. The patient underwent cyst fenestration operation and the diagnosis was also confirmed histopathologically. After the operation the amount of headache episodes and shift of central cranial structures decreased.

Comment

Arachnoid cysts can be incidental findings on cranial imaging or can be found in patients with non-specific complaints such as headache, seizures or behavioral problems. Arachnoid cysts consist of 1% of the intracranial non-traumatic space occupying lesions, they are usually diagnosed at an early age (13%) but may also be diagnosed in adulthood. Multiple intracranial arachnoid cysts are extremely rare.

Arachnoid cysts are defined as developmental cavities located between arachnoid membranes and filled by cerebrospinal fluid. A small number of arachnoid cysts are acquired, such as those occurring in association with neoplasms or those resulting from adhesions occurring in association with leptomeningitis, hemorrhage or surgery.

The localization of 50-60% of arachnoid cysts is usually middle cranial fossa and also can take place in cerebellopontine, retrocerebellar, suprasellar cisterns

and interhemispheric area. The arachnoid cysts become symptomatic and can cause some neurological findings when cysts enlarge and compress a cranial structure. Symptomatic cysts usually present with features of hydrocephalus due to obstruction of the third ventricle and aqueduct, and occlusion or partial obstruction of both foramina of Monro. Larger cysts can cause increased intracranial pressure and have a propensity to subdural hemorrhage following minor trauma.

Galassi classification is one of the systems that is used for classifying arachnoid cysts especially located in the middle cranial fossa. In type 1 the arachnoid cyst is small, spindle shaped and located in the middle cranial fossa. Type 2 arachnoid cyst extends along sylvian fissure and displaces the temporal lobe, and lastly in type 3 not only the temporal lobe but also the parietal lobe are displaced by the arachnoid cyst and the whole middle cranial fossa is filled by the cyst.

On cranial imaging, arachnoid cysts are easily recognizable because of the signal similarity with the cerebrospinal fluid. The signal can rarely differ due to proteinaceous or hemorrhagic content. The most important differentiation to make is between arachnoid and epidermoid cysts; diffusion-weighted MR images (DWIs) differentiates between the two masses easily. On DWIs images unlike arachnoid cysts, epidermoid cysts demonstrate high signal intensity and not suppressed on FLAIR images.

In conclusion, the radiologist should consider the arachnoid cysts in the event of intracranial cystic space-occupying lesions and use multi-modality cranial imaging for differentiation.

Reference

1. Catala M., Poirier J.: Arachnoid cysts. Histologic, embryologic and physiopathologic review. *Rev Neurol (Paris)*, 1998, 154: 489-501.

1. Department of Diagnostic Radiology, Ataturk Research and Training Hospital, Izmir, Turkey.