

Addison's disease due to bilateral adrenal tuberculosis on 18F-fluorodeoxyglucose positron emission tomography computed tomography

Sung Ae Koh

Department of Hematology-Oncology,
College of Medicine, Yeungnam
University, Daegu, Korea

Abstract

We present a case of a 60-year-old woman diagnosed with disseminated tuberculosis with bilateral adrenalitis resulting in Addison's disease. The 18-fluorodeoxyglucose (18-FDG) positron emission tomography (PET) computed tomography (CT) was performed, which revealed increased FDG uptake in the neck, mediastinal, and abdominal lymph nodes, and both adrenal glands, similar to the lesions noted on CT. We suspected the patient to have a lymphoma; therefore, axillary biopsy was performed, which revealed chronic granulomatous lesion with focal caseous necrosis.

Introduction

The 18-fluorodeoxyglucose (18-FDG) positron emission tomography/computed tomography (PET/CT) is an important non-invasive diagnostic tool for the diagnosis and management of solid cancers such as lymphoma. Addison's disease or primary adrenal insufficiency involves 90% destruction of the adrenal cortex and is caused by different factors. One of the main causes is autoimmune adrenalitis.¹ Other rare causes include histoplasmosis, blastomycosis, metastatic tumor, adrenal hemorrhage, and various opportunistic infections due to acquired immunodeficiency syndrome in developed countries.²⁻⁴ However, in developing countries, adrenal tuberculosis is still the major cause of Addison's disease.⁵ We report a case of a woman with Addison's disease due to adrenal tuberculosis.

Case Report

A 60-year-old woman, who had been in good health until 1 month earlier, presented with general weakness and fever. On admission, her temperature was 39°C; pulse, 110

beats/min; respiratory rate, 22 breaths/min; and blood pressure, 120/80 mmHg. On physical examination, she had palpable mass on both sides of the neck, axilla, and inguinal areas. In addition, she had pigmented skin on her hands, tongue, and buccal mucosa (Figure 1). In laboratory test, adrenocorticotrophic hormone level was higher than the normal level, and basal cortisol level was very low. Steroid medication was started. A CT scan was also obtained and showed multiple lymphadenopathy in the neck, mediastinal, and abdominal lymph nodes as well as an enlarged bilateral adrenal mass. Adrenal masses presented mass-like enlargement, rim enhancement, and focal cystic lesion (Figure 2). 18-FDG PET CT was performed, which revealed an increased FDG uptake in the neck, mediastinal, abdominal lymph node, and both adrenal glands, similar to the lesions noted in the CT (Figure 3).

We presumed the patient to have a lymphoma; therefore, axillary biopsy was performed, which revealed chronic granulomatous lesion with focal caseous necrosis. Thus, the patient was diagnosed with tuberculosis. An empirical treatment for tuberculosis was started with isoniazid, 300 mg; ethambutol; 800 mg; rifampin; 600 mg; and pyrazinamide, 1500 mg daily. She was also prescribed 10 mg of corticosteroids daily for Addison's disease. After 1 week, the fever and general condition were insidiously improving. In the laboratory test results, erythrocyte sedimentation rate and C-reactive protein level decreased. The patient was discharged after 2 weeks.

Discussion

We reported a rare case of Addison's

Correspondence: Sung Ae Koh, Department of Hematology-Oncology, College of Medicine, Yeungnam University, Daegu, Korea.
Tel.: +82.53.620.3826 - Fax: +82.53.654.8386.
E-mail: sakoh@yu.ac.kr

Key words: Addison's disease; tuberculosis; 18-FDG PET CT.

Conflict of interest: the authors declare no potential conflict of interest.

Received for publication: 5 June 2018.
Revision received: 23 June 2018.
Accepted for publication: 25 June 2018.

This work is licensed under a Creative Commons Attribution-NonCommercial 4.0 International License (CC BY-NC 4.0).

©Copyright S.A.Koh, 2018
Licensee PAGEPress, Italy
Infectious Disease Reports 2018; 10:7773
doi:10.4081/idr.2018.7773

disease with adrenal tuberculosis diagnosed with 18-FDG PET imaging. The 18-FDG PET had been mainly used to differentiate benign from malignant tumors/lesions.^{6,7} However, in this case, 18-FDG PET was not used for the differentiation. We performed 18-FDG PET, which revealed high FDG uptakes in both adrenal glands and multiple lymphadenopathy. Furthermore, lesions were not found in the lungs, the common tuberculosis site, in this patient. We presumed lymphoma or other malignancies. However, the patient was finally diagnosed with adrenal tuberculosis, not a malignancy. A study reported the use of FDG-PET CT in diagnosing infectious diseases and its clinical value in the early diagnosis of metastatic infections that showed late anatomical

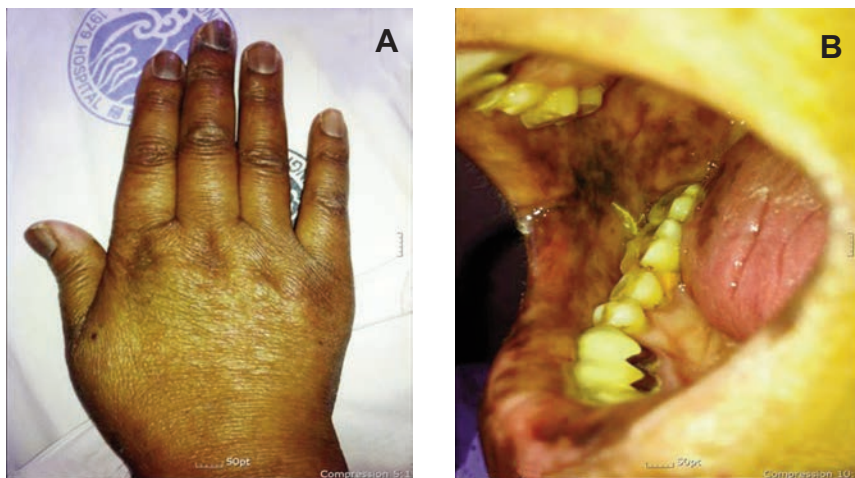


Figure 1. Skin pigmentation in the hands (A), tongue, and buccal mucosa (B).

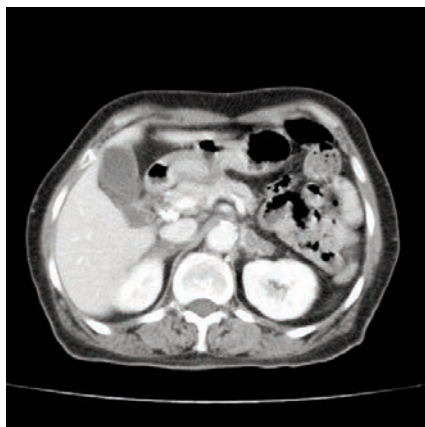

Figure 2. Contrast-enhanced CT scan shows mass-like enlargement and rim enhancement and focal cystic lesion of bilateral adrenal glands on axial images.

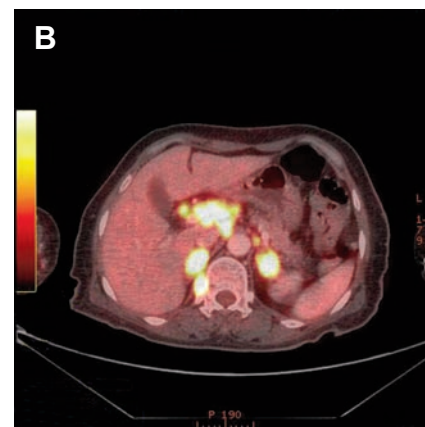
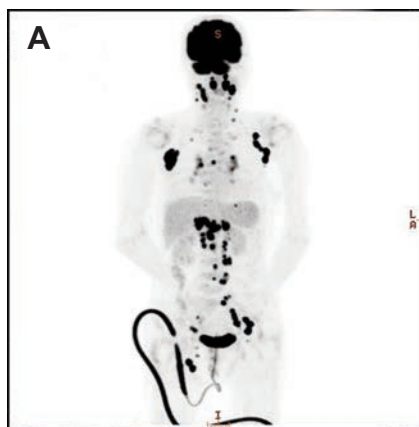


Figure 3. 18-FDG PET CT (coronal and axial view; A and B respectively) shows high FDG uptake in the neck, axilla, abdominal, and inguinal lymph nodes and both adrenal glands.

changes on CT.⁸

Addison's disease is initially presented as the cause of autoimmune adrenalitis, malignancy, or adrenal tuberculosis, as well as other diseases including metastatic tumor, blastomycosis, and histoplasmosis.^{1,2,4,9} However, in developing countries, infections like tuberculosis are still thought to cause the disease.^{3,5} Other modalities were helpful to distinguish the malignancy. In particular, CT showed peripheral rim enhancement and mass-like lesion in early adrenal tuberculosis.¹⁰ In our case, CT also showed similar findings like in other cases.

The 18-FDG PET finding in this case showed that high uptake in both adrenal glands and other lymphadenopathies similar to malignancies like lymphoma. However, this result was a false-positive finding.¹¹ Therefore, we suggest that benign adrenal mass and lymphadenopathies could show high FDG uptake, and false-positive results should be considered when interpreting the findings of 18-FDG PET. In addition, biopsy should be performed to confirm the diagnosis.

Conclusions

We report a rare case of disseminated

tuberculosis involving both adrenal glands, resulting in Addison's disease. High FDG uptake on PET findings mimic malignancies like lymphoma, which leads to false-positive results. We should consider not only malignancy but also benign disease involving tuberculosis infection despite high FDG uptake on PET. Moreover, a biopsy examination is required for an accurate diagnosis.

References

1. Betterle C, Dal Pra C, Mantero F, et al. Autoimmune adrenal insufficiency and autoimmune polyendocrine syndromes: autoantibodies, autoantigens, and their applicability in diagnosis and disease prediction. *Endocr Rev* 2002;23:327-64.
2. Oelkers W. Adrenal insufficiency. *N Engl J Med* 1996;335:1206-12.
3. Vita JA, Silverberg SJ, Golland RS, et al. Clinical clues to the cause of Addison's disease. *Am J Med* 1985;78:461-6.
4. Seidenwurm DJ, Elmer EB, Kaplan LM, et al. Metastases to the adrenal glands and the development of Addison's disease. *Cancer* 1984;54:552-7.
5. Efremidis SC, Harsoulis F, Douma S, et al. Adrenal insufficiency with enlarged adrenals. *Abdom Imaging* 1996;21:168-71.
6. Kumar R, Xiu Y, Mavi A, et al. FDG-PET imaging in primary bilateral adrenal lymphoma: a case report and review of the literature. *Clin Nucl Med* 2005;30:222-30.
7. Yun M, Kim W, Alnafisi N, et al. 18F-FDG PET in characterizing adrenal lesions detected on CT or MRI. *J Nucl Med* 2001;42:1795-9.
8. Kouijzer IJ, Vos FJ, Bleeker-Rovers CP, et al. Clinical application of FDG-PET/CT in metastatic infections. *The quarterly journal of nuclear medicine and molecular imaging*. 2017;61:232-46.
9. Dorin RI, Qualls CR, Crapo LM. Diagnosis of adrenal insufficiency. *Ann Intern Med* 2003;139:194-204.
10. Guo YK, Yang ZG, Li Y, et al. Addison's disease due to adrenal tuberculosis: contrast-enhanced CT features and clinical duration correlation. *Eur J Radiol* 2007;62:126-31.
11. Chen YK, Shen YY, Kao CH. Abnormal FDG PET imaging in tuberculosis appearing like lymphoma. *Clin Nucl Med* 2004;29:124.