

JBR-BTR, 2010, 93: 302-304.

## AN ELDERLY WOMAN WITH OBSTRUCTED OBTURATOR HERNIA: A LESS COMMON VARIETY OF EXTERNAL ABDOMINAL HERNIA

L. De Clercq<sup>1</sup>, K. Coenegrachts<sup>1</sup>, T. Feryn<sup>2</sup>, A. Van Couter<sup>3</sup>, P. Vandevoorde<sup>1</sup>, K. Verstraete<sup>4</sup>, H. Rigauts<sup>1</sup>

**Obturator hernia is a type of external abdominal hernia. Site of herniation is the obturator canal, which is the superolateral aspect of the obturator foramen. The herniation sac exits the pelvis near the obturator nerve and vessels. Herniated loops of small bowel extend between the pectineus and obturator muscles. In this report, we present a case of obstructed obturator hernia.**

**Key-word:** Intestines, stenosis or obstruction

External abdominal hernias are usually found in the inguinal region, where most are inguinal or femoral hernias. Traditionally diagnosed clinically, hernias may be difficult to identify and even more difficult to classify. Ultrasonography is used to evaluate hernias in the inguinal region (1). The obturator canal however is hardly visible by sonography. Most patients with obstructed obturator hernia are thin elderly women presenting with acute or recurrent small bowel obstruction. Dilated fluid-filled loops of small bowel can be found on abdominal radiograph (2). CT images confirm the presence of obstructed small bowel, moreover they determine the site of obstruction and enable to identify the underlying cause of obstruction. Mortality rate in obturator hernia is highest among all abdominal wall hernias: 13-40% (3, 4). Rapid evaluation and early surgical intervention can reduce morbidity and mortality (3).

### Case report

A 91-year-old woman was admitted to the geriatric ward with new onset pain in the right leg, radiating upwards to the right thigh, right groin and right fossa. She recently suffered from chronic obstipation. She had a medical history of deep venous thrombosis 4 years previously and appendectomy long before admission. On physical examination, abdominal tenderness was present but no rebound. Bowel sounds were normal on auscultation. Blood samples showed hyperglycemia. Ultrasonographic examination (Aplio, Toshiba, Japan) of the abdomen was non-specific. Doppler

ultrasound of the legs excluded recurrent deep venous thrombosis. Abdominal X-ray was normal at the first day of admission. One day later pelvic X-ray revealed several pathological dilated small bowel loops up to 45 mm in the mesogastric region. No pathological air-fluid levels were visible. Consequently

Computed Tomography (CT) (64-slice CT HD 750 – General Electric Medical Systems, Milwaukee, USA) of the abdomen and pelvis was performed to investigate the cause of suspected small bowel obstruction. Acquired images were reconstructed in axial and coronal planes. On CT images dilated fluid-filled loops of small bowel were found up to a herniated loop of small bowel in the pelvic region, through the obturator canal. Small bowel was seen superficial to the obturator muscles and deep to the pectineus muscle. There were no signs of bowel strangulation but images suggested an incarcerated hernia. Diagnosis of an obstructed

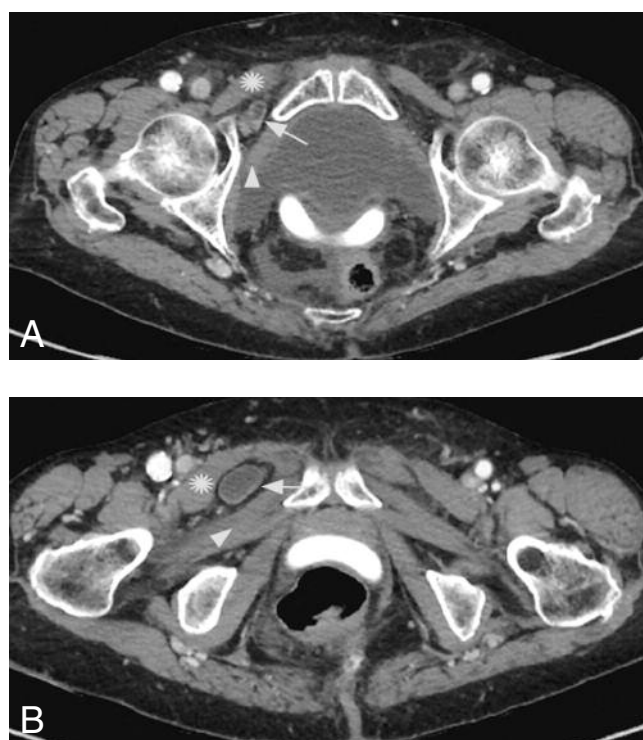


Fig.1. — A 91-year-old woman with obturator hernia. Axial CT (A) showing obturator hernia with small bowel protruded through the obturator canal (white arrow) between pectineus (white star) and obturator muscles (arrowhead). B shows obturator hernia with small bowel (white arrow) protruded between pectineus (white star) and obturator externus (arrowhead) muscle.

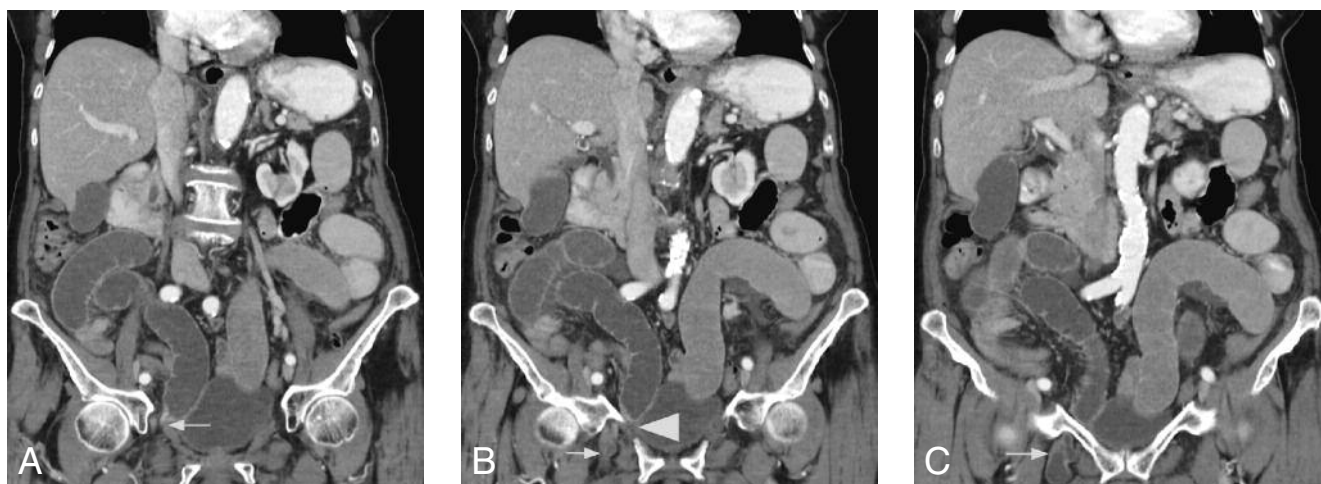

Fig.2. — Reconstructed coronal CT image (A) shows multiple dilated small bowel loops and level of herniated small bowel through the obturator canal (white arrow). B shows multiple dilated small bowel loops and herniated small bowel (white arrow) inferior to the right ramus pubis inferior (arrowhead). C. shows multiple dilated small bowel loops and herniated small bowel (white arrow) inferior to the right ramus pubis inferior.

obturator hernia was made. Patient was taken into surgery room for laparoscopic repair.

## Discussion

### Definition

Obturator hernia is a rare but life-threatening cause of obstructed abdominal wall hernia. Rarity and non-specific signs contribute to late diagnosis and late operation (1). It accounts for up to 1.4% of all abdominal wall hernias and up to 1.6% of small bowel obstructions (3, 5). Obturator hernia is also called “little old ladies hernia”. It is more common in elderly females owing to the greater width of the pelvis, larger obturator canal after pregnancy and age-related increased tissue laxity. In thin ladies loss of protective fat in the obturator canal facilitates the formation of hernia (3, 5). There is no external lump on abdominal examination but a tender mass on rectal or vaginal examination may be found. Obturator nerve irritation by compression of the herniated sac causes pain in the medial aspect of the thigh, the Howship-Romberg sign (HRS), which is positive in 20-50% of cases (3, 5). Absent adductor reflex in the thigh, The Hannington-Kiff sign, is more specific but less known (3). Obturator hernias affect the right side more frequently. Small bowel protruding through the obturator canal, which is 2-3 cm long and 1 cm wide, or lying between the pectineus and obturator muscles often incarcerates (1). This leads to acute or intermittent small bowel

obstruction with high risk of strangulation (5).

### Imaging findings

Ultrasonography is used as a first step method to evaluate hernias in the inguinal region (2). Conventional radiography may detect small bowel obstruction and sometimes a fixed loop containing gas in the obturator region is seen (1).

Ultrasonographic findings indicating hernial incarceration include free fluid in the hernial sac, bowel wall thickening in the hernia, fluid in the herniated bowel loop, and dilated bowel loops in the abdomen (6). Free fluid is an eye-catching finding on sonography. This single sign easily indicates that a hernial complication has a high probability of being present. Also, free fluid within the herniated bowel loops indicates incarceration of a hernia containing bowel with high specificity but limited sensitivity. The reason for the presence of fluid in an incarcerated bowel loop may be exudation into the bowel lumen, causing excess fluid in the bowel in cases of bowel obstruction (6). An indirect sign of an incarcerated hernia is the evidence of dilated, fluid-filled bowel loops in the abdomen. This sign indicates incarceration of the hernias containing bowel with excellent specificity but limited sensitivity. The absence of blood flow in the contents of a hernia should not be taken as a sign of incarceration because many incarcerated hernias have detectable blood flow on color Doppler sonography (6). Also, the absence of peri-

stalsis should not be considered a sign of incarceration because nonincarcerated hernias do not show peristalsis during the sonographic investigation in a relatively high percentage of patients. However, if peristalsis is present in an incarcerated hernia on sonography, bowel resection at surgery is probably not necessary. Gas in the bowel wall or free gas, either in the abdomen or the hernia sac, also is considered a sign of a complicated hernia (6).

The best imaging tool in obturator hernia however is CT of the pelvis and upper thigh. CT evidence of bowel herniating through the obturator foramen and lying between the pectineus and obturator muscles is the best diagnostic clue (1). CT accurately identifies the anatomical definition of the hernia and its content and also differentiates it from other abdominal masses eg tumors, hematomas, abscesses. Postural manoeuvres or increasing intraabdominal wall pressure can help depict subtle hernias. Thin reformatted images of 2.5 mm or less may better delineate the size and shape of the hernia sac and associated complications (4). Intravenous administration of contrast material is necessary for characterization of the vascular supply of the bowel wall to detect complications and guide treatment planning. Dilatation and/or fecalization of small bowel proximal to the hernia and tapering of the limbs at the hernia defect are signs of obstructed hernia. Helical CT signs in the diagnosis of intestinal ischemia have been described before: in a study by Zalcman M et

al, reduced enhancement of the bowel wall had a sensitivity of 48% and specificity of 100%, mural thickening had a sensitivity of 38% and specificity of 78%, mesenteric fluid had a sensitivity of 88% and specificity of 90%, congestion of mesenteric veins had a sensitivity of 58% and specificity of 79%, and ascites had a sensitivity of 75% and specificity of 76% (7).

#### Differential diagnosis

Differential diagnosis of obturator hernia should be made with other hernias in the groin region: inguinal, femoral, perineal and sciatic hernias. Inguinal and femoral hernias are the most common type of abdominal wall hernia (4, 8). Indirect inguinal hernias originate lateral to the inferior epigastric artery through the deep inguinal ring, traversing the inguinal canal inferomedially, along the spermatic cord or round ligament. They may exit the superficial inguinal ring to enter the scrotum or labium majus. Direct inguinal hernias originate medial to the inferior epigastric artery and protrude anteriorly through Hesselbach's triangle. Femoral hernias, like obturator hernias, originate inferior to the inguinal ligament but protrude medial to the femoral vein through the femoral ring (2, 8). Perineal hernias protrude anterior through the urogenital diaphragm and posterior between the levator ani and coccygeus muscles (1). Sciatic hernias protrude through the greater sciatic foramen and extend laterally into the subgluteal region.

#### Treatment

There is often a delay in diagnosis and surgical intervention of obturator hernia because of a hesitation to operate early due to vague symptoms, advanced age of patients and presence of comorbidities. Given the high risk of bowel incarceration and perforation, obturator hernias are always treated surgically (5). The majority of cases require resection of strangulated small bowel. The classical approach is abdominal exploratory laparotomy, although an inguinal approach is possible. In elective early surgery laparoscopic approach can be used (5). Repair is effected by closure of the peritoneum with stitches or by placement of a mesh. Contralateral side exploration is recommended.

#### Conclusion

Obturator hernia is a rare but life-threatening type of external abdominal hernia. Signs and symptoms are often non-specific. Patients are usually thin elderly women presenting with intermittent or acute small bowel obstruction, which can be seen on abdominal radiographs. Small bowel herniating through the obturator foramen and lying between the pectineus and obturator muscles is a diagnostic clue on CT of the abdomen and pelvis. High risk of bowel incarceration requires rapid diagnosis and early surgical repair to reduce morbidity and mortality of patients with obstructed obturator hernia (3, 4).

#### References

1. Jamadar D., Jacobson J., Morag Y., Girish G., Ebrahim F., Gest T., Franz M. Sonography of Inguinal Region Hernias. *AJR*, 2006,187: 185-190.
2. Clair L. Shadbolt, Stefan B. J. Heinze, Rosalind B. Dietrich. Imaging of Groin Masses: Inguinal Anatomy and Pathologic Conditions Revisited. *RadioGraphics*, 2001, 21 :S261-S271.
3. Mantoo S.K., Mak K., Tan T.J. Obturator hernia: diagnosis and treatment in the modern era. *Singapore Med J*, 2009, 50: 866-870.
4. Aguirre D., Santosa A., Casola G., Sirlin C. Abdominal Wall Hernias: Imaging Features, Complications, and Diagnostic Pitfalls at Multi-Detector Row CT. *RadioGraphics*, 2005, 25: 1501-1520.
5. Rodríguez-Hermosa J.I., Codina-Cazador A., Maroto-Genover A., Puig-Alcántara J., Sirvent-Calvera J.M., Garsot-Savall E., Roig-García J. Obturator hernia: clinical analysis of 16 cases and algorithm for its diagnosis and treatment. *Hernia*, 2008, 12: 289-297.
6. Rettenbacher T., Hollerweger A., Macheiner P., Gritzmann N., Gotwald T., Frass R., Schneider B. Abdominal Wall Hernias: Cross-Sectional Imaging Signs of Incarceration Determined with Sonography. *AJR*, 2001, 177: 1061-1066.
7. Zalcman M., Sy M., Donckier V., Closset J., Van Gansbeke D.. Helical CT Signs in the Diagnosis of Intestinal Ischemia in Small-Bowel Obstruction. *AJR*, 2000, 175: 1601-1607.
8. Upponi S., Bungay H. Imaging of abdominal wall hernias. *Imaging*, 2006, 18: 268-277.