

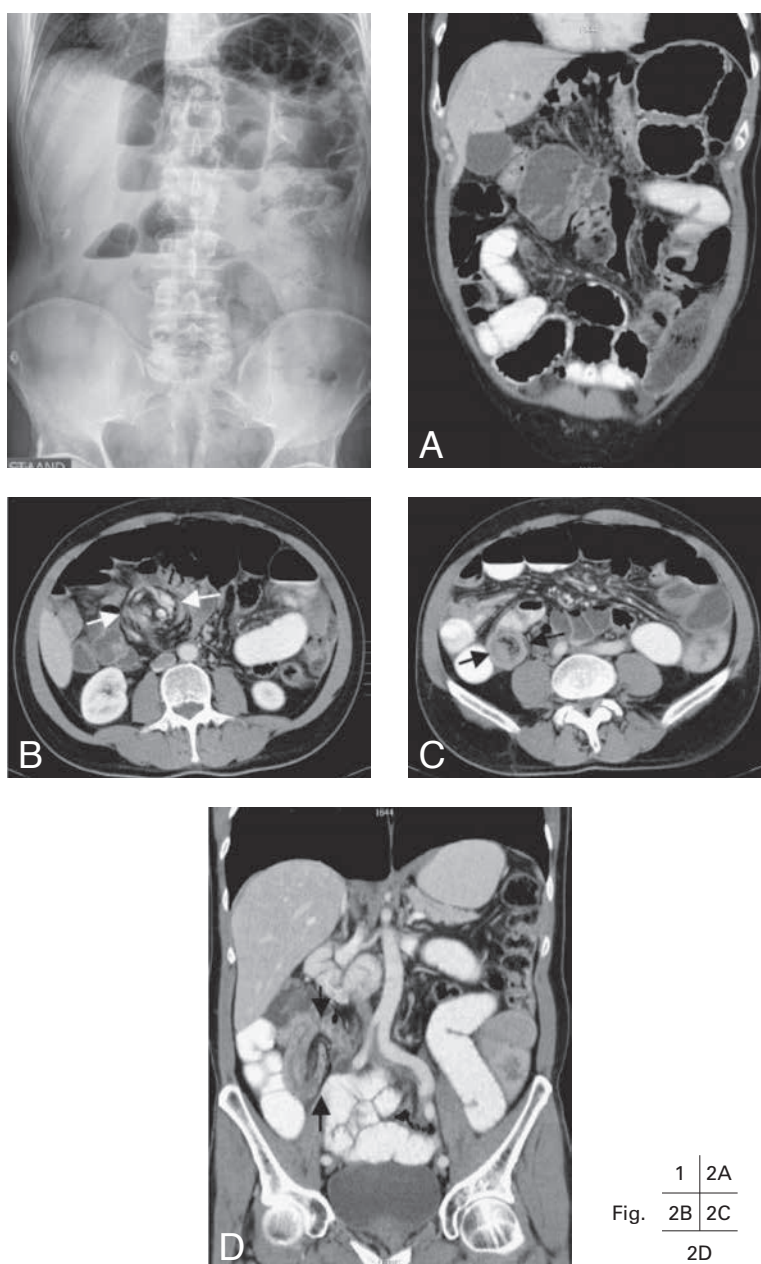
VOLVULUS OF CECUM AND ILEO-ILEAL INTUSSUSCEPTION

Y. Vande Weygaerde¹, M. Eyselbergs^{2,3}, K. De Cuyper², K.L. Verstraete¹, F.M. Vanhoenacker^{1,2,3}

Key-word: Intussusception

Background: A 55-year-old man without relevant medical history was admitted to the emergency department with painful abdominal cramps, vomiting, nausea, and absence of flatus. There was no altered bowel habit in the last months, no melena and no red blood loss per anum. Physical examination was normal except for lower abdominal tenderness and reduced bowel sounds. Laboratory findings were unremarkable.

Conventional radiography of the abdomen was made, followed by MultiDetector Computed Tomography (MDCT) scan of the abdomen.



1	2A
2B	2C
2D	

Fig.

1. Department of Medical Imaging, University Hospital Ghent, Ghent, Belgium, 2. Department of Radiology, AZ Sint-Maarten, Duffel-Mechelen, Belgium, 3. Department of Radiology, University Hospital Antwerp, Antwerp University, Edegem, Belgium

Work-up

On erect plain abdominal radiograph (Fig. 1) multiple air-fluid levels are seen at the epigastrium and right iliac fossa consistent with mechanical small bowel obstruction. The cecum is not well seen.

Contrast-enhanced CT scan of the abdomen (Fig. 2) shows on A (reformatted image in the coronal plane) that the cecum lies near the midline of the mesogastrium indicating incomplete fixation. On axial section at the level of the lower pole of the kidneys (B), the presence of a whirl sign (white arrows) at the mesentery, caused by twisting of mesenteric fat and vessels at the base of the cecal twist is noted. Axial section at the level of the iliac crests (C) demonstrates the multilayered appearance of a small bowel intussusception (black arrows). The outer layer consists of the thickened wall of the intussusciens, whereas the central part contains the intussusceptum with accompanying mesenteric fat and blood vessels. On reformatted image in the coronal plane (D), the length of the intussusception (black arrows) is better demonstrated.

Radiological diagnosis

Based on the clinical history and the imaging findings, this patient was diagnosed with a *combination of volvulus (of a mobile cecum) and ileo-ileal intussusception*. The diagnosis was confirmed on laparoscopic surgery. No underlying lead point was found. Postoperative recovery after reduction of the intussusception and ileo-cecocolostomy was uneventful.

Discussion

Volvulus of the cecum consists of torsion of the cecum around its own mesentery. It occurs when the cecum and proximal colon are insufficiently attached to the peritoneum and a fixed point can serve as fulcrum for rotation (i.e. an adhesion or abdominal mass).

Intussusception is an invagination of a part of bowel with its mesentery into the lumen of a contiguous part of bowel, due to peristalsis. Intussusception can be transient in the absence of a lead point. It can also occur due to a lead point (benign: lipomas, adenomatous polyps, Meckel diverticu-

lum; malignant: adenocarcinoma, metastasis; idiopathic: adhesions, motility disorders). The latter type is persistent, causes obstruction and needs surgery. Small bowel intussusceptions usually have a benign primary lead point. Both cecal volvulus and intussusception account for 1% each of all intestinal obstructions. Both conditions may be complicated by bowel ischemia, gangrene, perforation and death if left untreated. The association of cecal volvulus and intussusception in adult patients is rare.

It has been suggested that malrotation due to a mobile cecum acts as a causative lead point for small bowel intussusception.

A similar association of midgut malrotation and intussusception has been described in children as the

Waugh's syndrome.

Patients usually present with signs of intestinal obstruction: abdominal cramping pain, nausea, vomiting and constipation.

Imaging has a pivotal role in the correct diagnosis of gastro-intestinal obstruction.

Although the diagnosis can be made by conventional plain radiographs by demonstrating air-fluid levels, for more precise assessment of the etiology and precise location and extent of the obstruction, CT scan is required. The whirl sign which consists of spiralled loops of collapsed bowel with mesenteric fat and vessels and is a characteristic CT-finding of volvulus. Intussusception is seen on CT scan as a target like or sausage-shaped mass. CT is also a useful technique to reveal a causative lead point (although not always visible), which is very important for differentiation and determining whether surgery is necessary or not.

Bibliography

1. Inan M., Basaran U.N., Ayvaz S., et al.: Waugh's Syndrome: report of two cases. *Journal*, 2004, 39: 110-111.
2. Kim Y., Blake M., Harisinghani M., et al.: Adult Intestinal Intussusception: CT Appearances and Identification of a Causative Lead Point. *Radiographics*, 2006, 26: 733-744.
3. Rosenblat J., Rozenblit A., Wolf E., et al.: Findings of Cecal Volvulus at CT. *Radiology*, 2010, 256: 169-175.