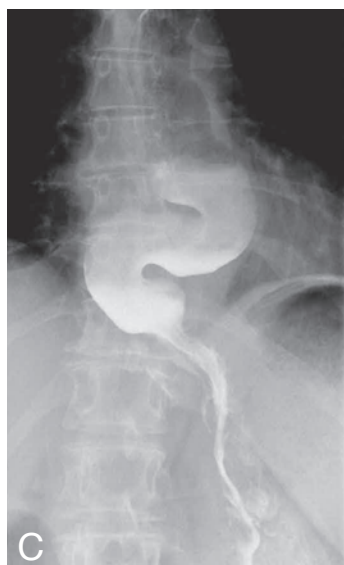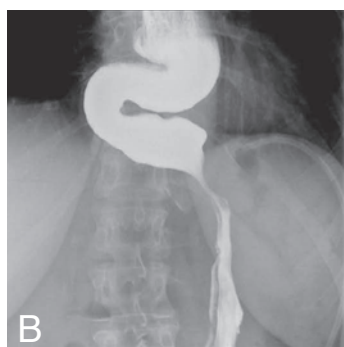

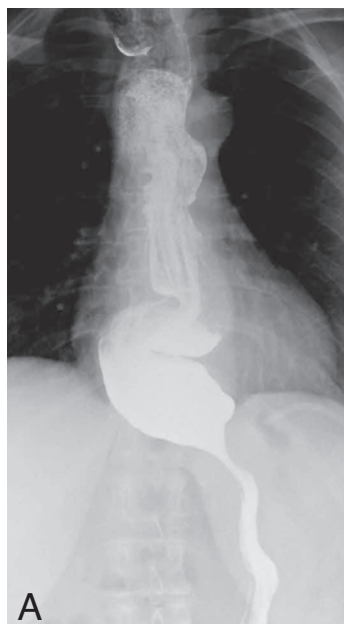
IMAGES IN CLINICAL RADIOLOGY



Pseudo-achalasia: a complication of laparoscopic adjustable gastric banding

P. Terryn¹, J. Pringot¹, L. Ghijselings¹, B. Bomans², P. Matthys¹

A 49-year-old woman presented with dyspepsia and nocturnal regurgitation. A laparoscopic adjustable gastric banding (LAGB) had been performed 6 years before presentation.

An upper gastrointestinal barium contrast study was performed and revealed a marked dilatation and tortuous course of the esophagus as well as absence of peristalsis and delayed evacuation of the esophagus (Fig. A, B).

The findings were compatible with an achalasia-like disorder. An esophageal manometry revealed a constant high LES pressure with aperistalsis, thus confirming the diagnosis of (pseudo-)achalasia. Consequently a complete band deflation was conducted and resulted in a complete resolution of the patient's symptoms. Two weeks later the control contrast study showed a marked improvement of the delayed evacuation and a small regain of peristaltic function. The dilatation and "sigmoid-like" image of the esophagus remained unchanged (Fig. C).

Comment

Obesity is an important public health problem in all western countries with an increasing incidence and significant morbidity and mortality. LAGB is due to its limited invasiveness and therefore very low operative risk a frequent procedure for the management of obesity. It is however not free of complications and side effects with the most common being band erosion, band slippage, pouch dilatation, esophagitis and pseudo-achalasia.

Pseudo-achalasia is in fact secondary achalasia, with a mechanical obstruction in the majority of the cases. This may include malignant disease, benign lesion or complications of surgical procedures at the distal esophagus or proximal stomach.

The motility disorder is often indistinguishable from true achalasia through manometry or upper gastrointestinal barium contrast study. Approximately 3-4% cases of achalasia are in fact pseudo-achalasia.

Pseudo-achalasia after LAGB is considered a rare complication (approximately 1,9%) but is generally underestimated with studies reporting up to 17%. Of all cases of pseudo-achalasia roughly 10% are caused by post-operative complications; with anti-reflux surgery being the most common. It is more frequent in patients with insufficiency of the LES (pre-existing or developed as a consequence of chronic pouch overfilling); furthermore it may occur secondary to band overinflation, band dislocation and placement of the band too far proximally at the level of the LES.

The gold standard for the diagnosis of (pseudo-)achalasia is upper gastrointestinal contrast study and esophageal manometry. The contrast studies are superior to computed tomography because of the ability to evaluate the esophageal motility. The role of CT is to rule out masses of or around the lower esophagus and to assist in the differentiation between pseudo-achalasia and achalasia.

Upper gastrointestinal contrast studies must ensure correct band placement, rule out slippage or pouch dilatation as well as assess the motility and diameter of the esophagus. An esophageal diameter above 35 mm is considered as dilated. The degree of pathology can be further assessed through the radiological classification of Dargent with stage I being moderate dilatation with delayed emptying, stage II hypercontracting esophagus (tertiary waves) with poor emptying, stage III significant dilatation and stage IV for major achalasia-like dilatation or megaesophagus (our patient).

The therapy consists of complete band deflation or removal of the band which often results in a significant decrease or complete resolution of symptoms due to the high reversibility of the disorder.

Reference

1. Lipka S., Katz S.: Reversible pseudoachalasia in a patient with laparoscopic adjustable gastric banding. *Gastroenterol Hepatol (N Y)*, 2013, 9: 469-471.

1. Department of Radiology, 2. Department of Surgery, Clinique Ste-Elisabeth Ziekenhuis, Brussels, Belgium.