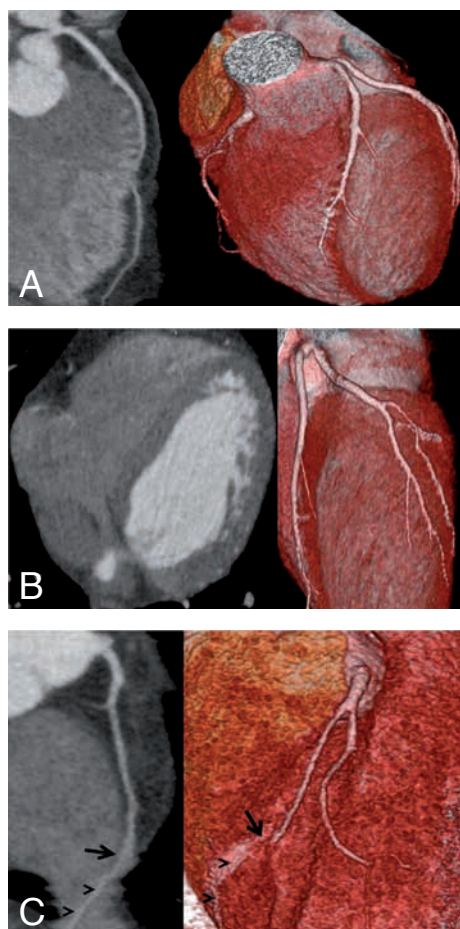


JBR-BTR, 2015, 98: 97.

IMAGES IN CLINICAL RADIOLOGY



320-row-detector CT angiography findings in a case with myocardial bridging in the three main coronary arteries

S. Akay¹, U. Bozlar², Demirkol Sait³, M. Tasar²

A 46-year-old man with the complaining of palpitation was admitted to our hospital. Polymorphic ventricular early beats were observed on electrocardiography. The patient was referred to our department for coronary artery computed tomography angiography (CTA) for a probable congenital anomaly.

On coronary CTA performed by a 320-Row-Detector scanner; left main coronary artery was short. The myocardial bridging (MB) causes approximately 75% luminal stenosis in a 2.5-cm segment was observed in the middle segment of left anterior descending artery (Fig. A, white arrow). The circumflex artery was continuing as the first obtus margin artery and this branch was separating to four branches in the middle part. All of these branches were coursing subepicardially in the middle and distal part (Fig. B, white arrowheads). The right main coronary artery was separating to two branches in the proximal part, and the thinner one was showing MB in its middle part (Fig. C, black arrow). This branch had a subepicardial course as well, in its distal part along the right atrium (Fig. C, black arrowheads).

Eventually, all the cardiologic examinations and imaging findings were reevaluated. Based on those findings, antiarrhythmic drug therapy was prescribed by cardiology department, and the patient was called for regular follow-up.

Comment

CTA study was performed by using a 320 row-detector CT scanner (Aquilion One; Toshiba Medical Systems, Ottawara, Japan). Because of the heart rate of the patient was 60 beats per minute, we did not give beta-blocker drug. Prospective ECG-triggered dose modulation was used. The tube voltage was 120 kV. A biphasic injection of intravenous contrast was used and the total amount of 70 ml non-ionic contrast agent (Iohexol-350; GE Healthcare, USA) was injected into the antecubital vein at a flow rate of 5.0 ml, followed by a saline flush. In order to synchronise the arrival of

the contrast agent and the scan, bolus arrival was detected using automated peak enhancement detection in the ascending aorta using a threshold of 200 HU. An initial data set was reconstructed with a slice thickness of 0.5 mm and a reconstruction interval of 0.25 mm. The images were transferred to an image postprocessing workstation (Vitrea 2.0; Vital Images, Minnetonka, MN). Then axial raw, multiplanar, curved and rotated reformatted images were evaluated along the course of each coronary artery and major side branches, and thin-slab maximum-intensity projection images created at the workstation.

The clinical importance of the MB is controversial. Although the bridging is asymptomatic in most of the cases, it can rarely cause myocardial ischemia and related complications. While MB was observed in 0.5-2.5% of the catheter angiography studies, it was reported as ranging rates from 15% to 85% in the autopsy series. MB is seen most commonly in the middle segment of left descending artery. The other main coronary arteries and their branches are affected less frequently.

In 320-detector row CT, the entire heart is imaged with temporal uniformity. The temporal resolution of a multi-detector CT scanner reflects the ability to freeze cardiac motion, thus producing motion-free images. The 320-detector scanner has a standard temporal resolution of approximately 175 ms which is a very short time compared with the lower detector row CT scanners. Wide-area coverage multidetector CT, such as 320-detector row scanner, has enabled volumetric imaging of the entire heart free of stair-step artifacts at a single time point within one cardiac cycle.

MB is not a rare situation in the routine clinical practice. But bridging in all the three main coronary arteries is very uncommon. Multidetector coronary CTA, especially by using a 320-row-detector scanner is an effective and non-invasive imaging modality for understanding the normal coronary anatomy and detecting the congenital anomalies of the coronary arteries.

References

1. Möhlenkamp S., Hort W., Ge J., Erbel R.: Update on myocardial bridging. *Circulation*, 2002, 106: 2616-22.
2. Hsiao E.M., Rybicki F.J., Steigner M.: CT coronary angiography: 256-slice and 320-detector row scanners. *Curr Cardiol Rep*, 2010, 12: 68-75.

1. Dpt of Radiology, Sirnak Military Hospital, Sirnak, 2. Dpt of Radiology, 3. Dpt of Cardiology, Gulhane Military Medical School, Ankara, Turkey.