

# APPEARANCE AND VANISHING OF A SPINAL INTRADURAL ARACHNOID CYST AFTER MULTIPLE EPIDURAL CORTICOSTEROID INJECTIONS. A SPONTANEOUSLY RESOLVING CAUSE OF SYMPTOMATIC LUMBAR STENOSIS

P. Mailleux<sup>1</sup>, G. Milbouw<sup>2</sup>, G. Koerts<sup>3</sup>, P. Verbeek<sup>3</sup>, X. Willems<sup>3</sup>

**Background:** Spinal intradural arachnoid cyst is a rare lesion, sometimes acquired.

**Purpose:** To describe the appearance and later spontaneous disappearance of a lumbar intradural arachnoid cyst, following perineural corticoid injections.

**Method:** Review of the clinical data and imaging, with final spontaneous return to initial state.

**Discussion:** Atypical intradural arachnoid cysts can be related to perineural injections and can cause symptoms of spinal stenosis. Its spontaneous vanishing is a very rare event, up to now unreported.

**Key-word:** Arachnoid, cysts.

Intradural spinal arachnoid cysts are rare, sometimes symptomatic with radiculopathy, cord compression or symptoms of canal stenosis (1-4). They can be incidental findings on MRI. The majority lay dorsally (80%), only 20% are ventrally located. Only 5% occur in the lumbar region, most being thoracic (80%) with 15% in the cervical spine. Their etiology remains uncertain. Most are thought to be congenital, some being related with the development of arachnoiditis, or following surgical or percutaneous dural approach.

## Case report

The patient is a 80 years old female patient with chronic cervical and lumbar pain, and non specific irradiation in both lower legs, more painful on the left side. She consulted multiple physicians and multiple L4-L5 and L5-S1 intra-articular corticosteroid injections were performed during the last 10 years in various hospitals, as well as epidural corticosteroid injections, while the diagnosis of "restless legs syndrome" was formerly proposed by neurologist.

MRI performed in November 2011 (Fig. 1A) showed chronic lumbar discopathies, and normal distribution of the roots in a large lumbar thecal sac.

Two more periradicular epidural corticoid injections close to the intraforaminal left L5 root were performed in January and February 2012 (Fig. 2).

In March 2012, the patient was not able to walk more than one hundred meters, which was diagnosed as a possible "neurological claudication".

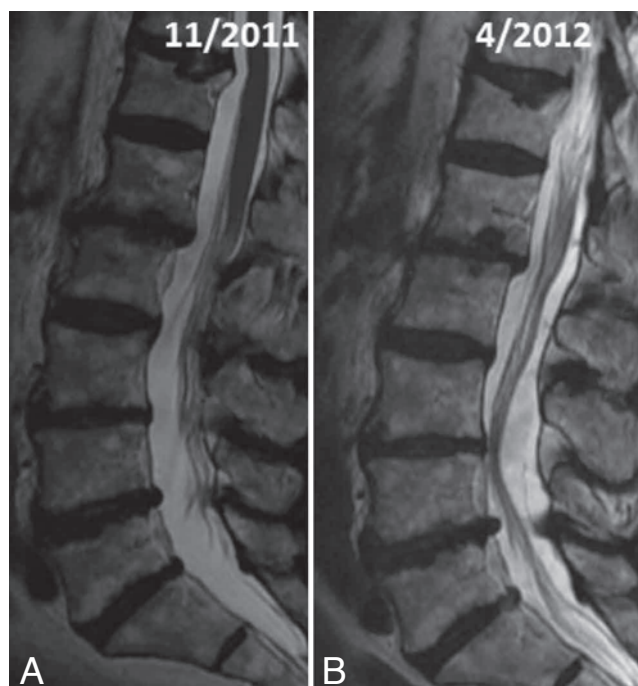


Fig. 1. — A. Sagittal T2 MRI of the lumbar spine (November 2011): multiple discopathies, no stenosis. B. Sagittal T2 MRI of the lumbar spine (April 2012): lumbar nerve roots pushed anteriorly by a cystic lesion.

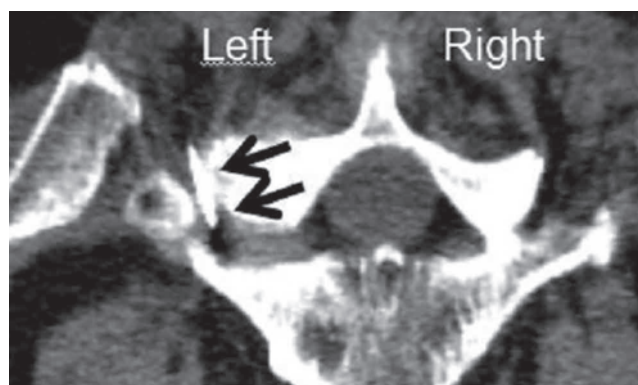


Fig. 2. — February 2012: perineural infiltration close to left L5 nerve root (arrows pointing to the needle).

From: 1. Dept of Medical Imaging, Clinique St Luc, Bouge, 2. Dept of Neurosurgery, Regional Hospital Center, Namur, 3. Dept of Medical Imaging, Clinique et Maternité Sainte Elisabeth, Namur, Belgium  
Address for correspondence: Dr P. Mailleux, M.D., Dpt Of Medical Imaging, Clinique St Luc, rue St Luc 8, 5004 Bouge, Belgium. E-mail: p.mailleux@skynet.be

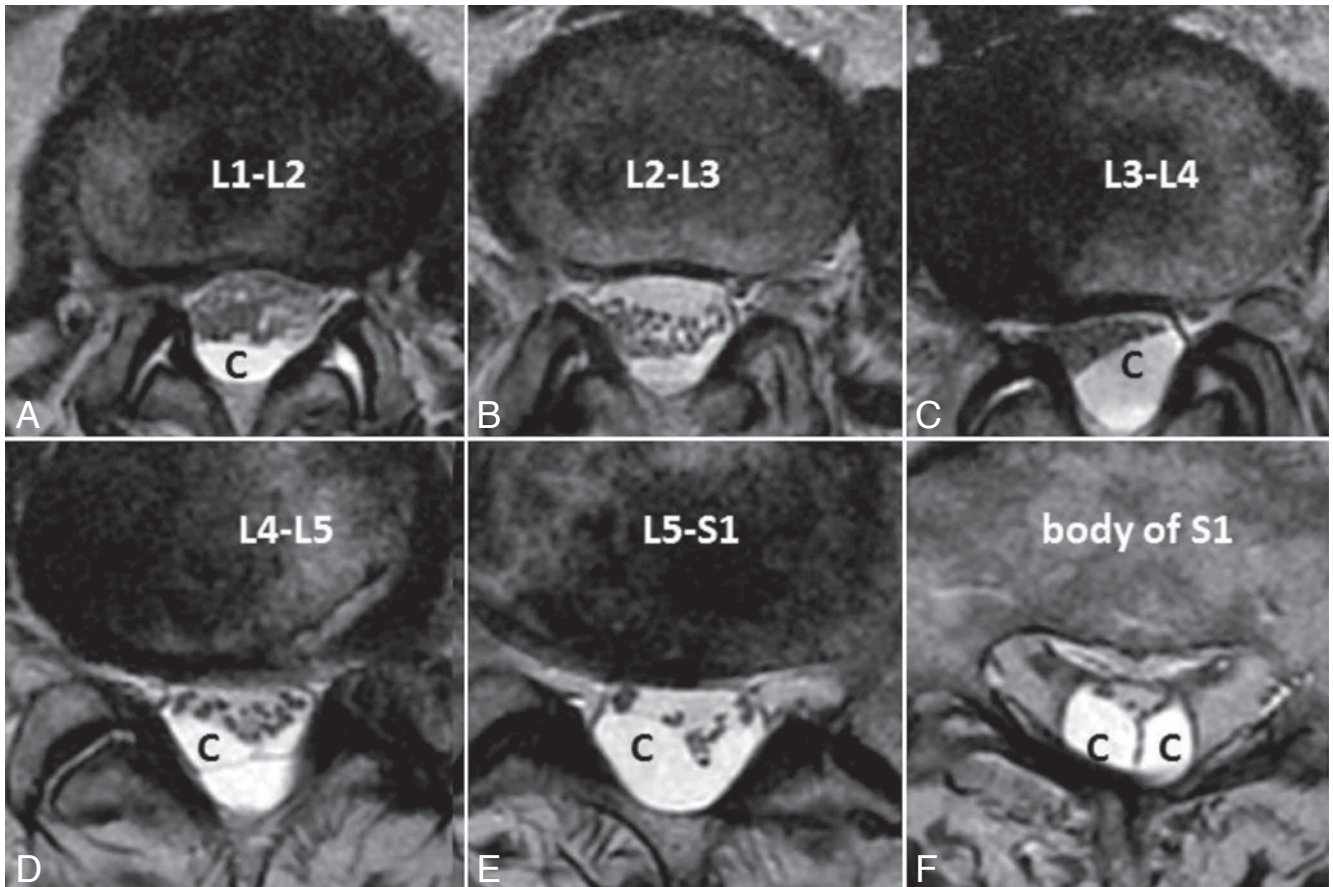


Fig. 3. — A to F: axial T2 slice of the lumbar spine. Posterior cystic lesion pushes the nerves anteriorly and causes severe spinal stenosis. Loculations are well seen at the lower level behind disc L5-S1.

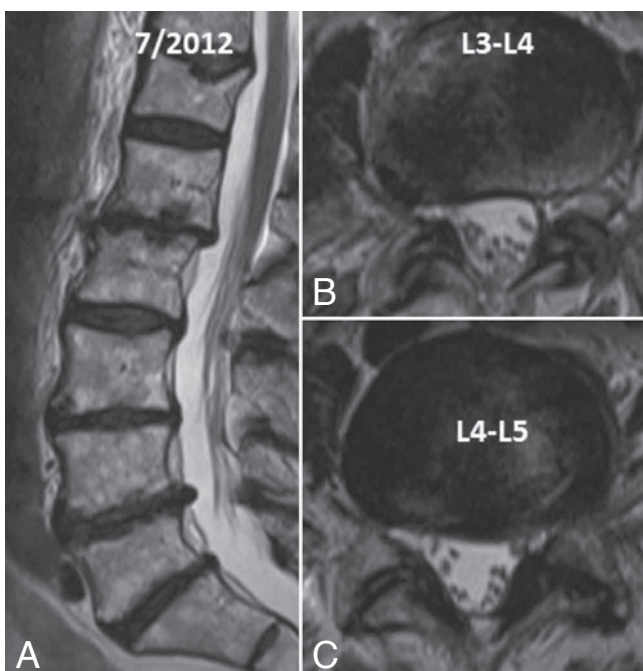


Fig. 4. — A (July 2012): Sagittal and axial T2 images showing normal dorsal position of the roots in the thecal sac, with regular distribution of the roots.

Electromyogram was unchanged, showing signs of chronic light neurogenic involvement in the left L5 root territory.

Another lumbar MRI in April 2012 showed unchanged chronic discal alterations and all the roots pushed anteriorly at the L3-L4 and L4-L5 levels by a large intradural multi-loculated cyst (Fig. 1B, Fig. 3). In consideration to the patient age, no surgery was proposed and abstention of anymore epidural injection was advocated.

Patient inability to walk more than a few meters subsided and a control MRI three months later (Fig. 4) showed complete disappearance of the cystic lesions in the lumbar dural space and return to normal posterior location of the roots in the thecal sac.

#### Discussion

The first lumbar MRI of the patient, at the age of 79 years shows only degenerative disc disease, without stenosis or signs of arachnoiditis. She received two epidural corticoid injections afterwards, close to the left L5 root, in the foramen

(Fig. 2). On the second lumbar MRI (Fig. 1B, 3B), the roots at the L3-L4 and L4-L5 levels are compressed anteriorly by a large intradural arachnoid cyst which extends on 10 cms from the L1-L2 level superiorly to lower than the L5-S1 level and appears multiloculated. Inferiorly located images (Fig. 3E and 3F) show the caudal extension of the cyst, displacing the S1 and S2 roots. The T2 signal intensity in the cyst is higher than in the CSF around the roots (Fig. 3B), which can probably be explained by a lesser transmission of the arterial pulsation of the arteries in the cyst compared to the "normal" thecal sac (5), a kind of "reversed flow void phenomenon".

Due to the old age of the patient, a surgical treatment was not proposed and the patient symptoms improved with the ability to perform longer walk, but with persistent lumbar pain. And no cyst could be seen the July 2012 lumbar MRI : the lumbar roots lay dorsally, without clumping or real sign of arachnoiditis (Fig. 4).

Most spinal intradural arachnoid cysts are thought to be congenital, some being related to arachnoid adhesions developing secondary to inflammation, which may arise from infection, hemorrhage, or an iatrogenic cause such as injected contrast

media or anesthetics (6). A symptomatic lumbar arachnoid cyst appearing a few months after a normal myelography was reported, supporting evidence for the traumatic etiology of some spinal intradural arachnoid cyst (7). Our case seems to comfort the hypothesis, with the cyst appearing just a few weeks after two periradicular injections. Its appearance is different from the classic globular form, with some septations well seen on Fig. 3D.

On the other hand, spontaneous vanishing of an arachnoid cyst seems to be very rare: just a few cases have been reported in the head (8-9), but not in the spine. One possible hypothesis is that the needle (or the corticosteroid injected) during the perineural injection could have caused a dural lesion with a "valve" effect, dissecting the dura and leading to the multiloculated appearance of the cyst, but that healed after a few months, with regression of the cyst. It is probably the first case of spontaneously disappearance of an spinal intradural arachnoid cyst.

#### References

1. Robinson Y., Reinke M., Haschtmann D., Ertel W., Heyde C.E.: Spinal extradural meningeal cyst with spinal stenosis. *Spinal Cord*, 2006, 44: 457-460.
2. Nabors M.W., Pait T.G., Byrd E.B., et al.: Updated assessment and current classification of spinal meningeal cysts. *J Neurosurg*, 1988, 68: 366-377.
3. Wang M.Y., Levi A.D., Green B.A.: Intradural spinal arachnoid cysts in adults. *Surg Neurol*, 2003, 60: 49-55.
4. Osenbach R.K., Godersky J.C., Traynelis V.C., Schelper R.D.: Intradural extramedullary cysts of the spinal canal: clinical presentation, radiographic diagnosis, and surgical management. *Neurosurgery*, 1992, 30: 35-42.
5. Brooks M.L., Jolsef F.A., Patz S.: MRI of pulsatile CSF motion within arachnoid cysts. *Magnetic resonance imaging*, 1988, 6: 575-584.
6. Hughes G., Ugokwe K., Benzel E.C.: A review of spinal arachnoid cysts. *Cleveland Clinic J Med*, 2008, 75: 311-315.
7. Kriss T.C., Kriss V.M.: Symptomatic spinal intradural arachnoid cyst development after lumbar myelography. Case report and review of the literature. *Spine*, 1997, 22: 568-572.
8. Weber R., Lumenta C., Lenard H.G.: Spontaneous regression of a temporal arachnoid cyst. *Childs Nerv Syst*, 1991, 7: 414-415.
9. Cokluk C., Senel A., Celik F., Ergür H.: Spontaneous disappearance of two asymptomatic arachnoid cysts in two different locations. *Minim Invasive Neurosurg*, 2003, 46: 110-112.