

NEONATAL CEPHALOHEMATOMA

L. Willemot¹, P. Lagae¹, P. Jeannin², N. Baelde¹, K. Verstraete³

Key-word: Infants, newborn, injuries

Background: A few hours after birth a newborn baby developed two soft well-defined bumps situated bilaterally on the posterior part of the parietal regions of the skull. The swellings were separated by the sagittal suture and do not cross the lambdoid suture. The infant was delivered vaginally in a head-first position after a full term pregnancy (G2A1P0) without complications. There was no prolonged labour nor use of forceps, vacuum extractor or other techniques of assisted delivery.

The newborn weighted 2.8 kg (P10) and measured 47 cm (P10) with a head circumference of 32.5 cm (P6). The APGAR scores after 1 and 5 minutes were respectively 6 and 9. Ultrasound examination showed crescentic hypoechoic fluid collection along the periosteum of the parietal bone bilaterally.

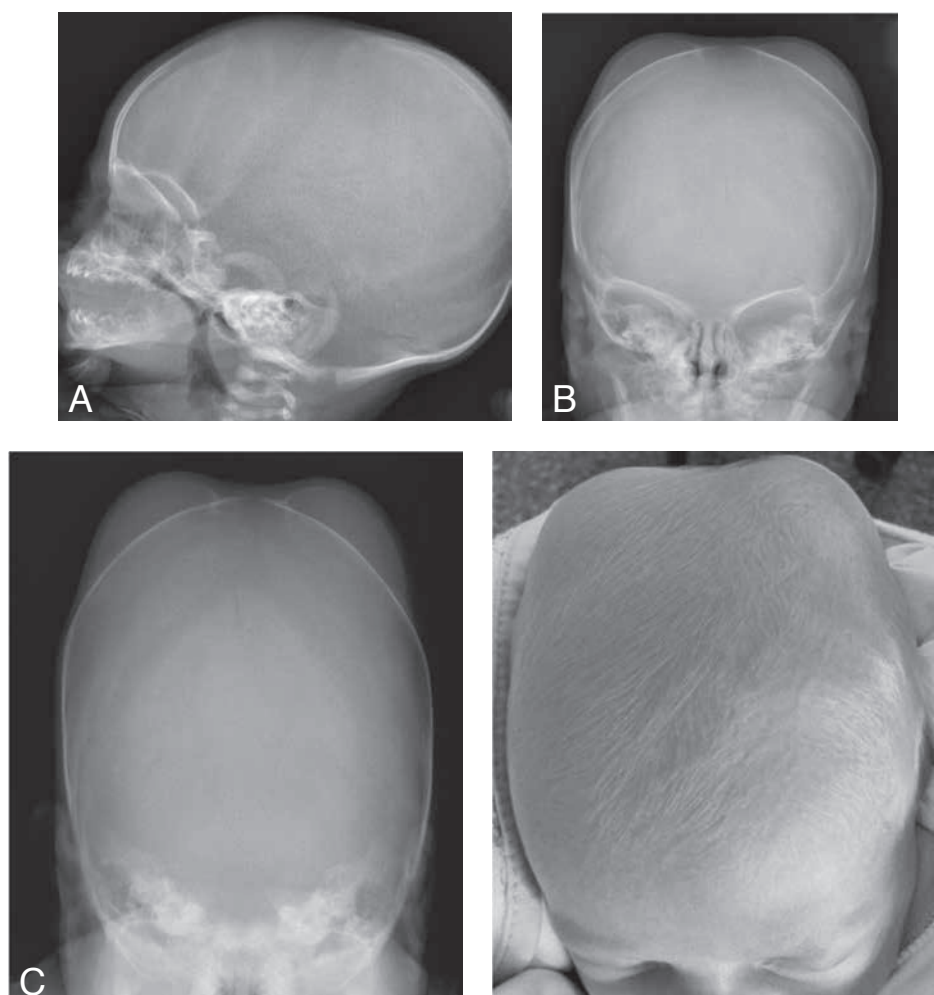


Fig.

1A	1B
1C	2

Work-up

Plain digital radiography of the skull (Fig. 1) shows on lateral view (A) a subtle soft tissue swelling and subperiosteal calcification at the superoposterior margin of the parietal bone.

Postero-anterior view (B) demonstrates bilateral soft tissue swelling with subperiosteal curvilinear calcification at the posterior margin of the parietal bone. The bumps are divided by the sagittal suture. There is no evidence of skull fracture. On Townes view (C) the parietal bumps are shown even more clearly. Also on this incidence, there is no evidence of fracture.

Figure 2 is the clinical photograph of the infant's head.

Radiological diagnosis

Based on the clinical findings of parietal scalp swellings confined to the parietal bone vault in a newborn, the subperiosteal fluid on ultrasound examination, and the characteristic radiographic appearance of soft tissue swelling with an elevated rim of curvilinear bone, the diagnosis of *cephalohematoma* was made.

The diagnosis was confirmed three weeks later on digital radiography of the skull.

Discussion

A cephalohematoma is a posttraumatic subperiosteal accumulation of blood. It is the most frequent cranial injury in the neonates, occurring in approximately 2.5% of all births. The hemorrhage is caused by traumatic passage through the birth canal and is associated with instrumental delivery (particularly vacuum extraction and forceps delivery), prolonged labour and primiparae. Clinically this condition presents as a soft fluctuant mass, typically located over the middle and posterior parts of the parietal bone, sometimes bilaterally.

The second most common site is over the occiput.

Anatomically the normal scalp consists of 5 layers: (1) the skin, (2) the subcutaneous tissue, (3) the galeal aponeurosis: a thin but dense layer of fibrous tissue continuous with the frontal, temporal and occipital muscles, (4) the subgaleal space, consisting of loose connective tissue allowing movement between the scalp and the skull, and (5) the periosteum or pericranium: a layer of fibrous tissue connected loosely through the subperiosteal layer to the cranial bone, but firmly attached to the sutures through which it is continuous with the dura mater.

Traumatic disruption of veins communicating between the cranial diploic space and the pericra-

nium causes subperiosteal hemorrhage. Because of a strong adherence of the pericranium to the sutures, cephalohematomas do not cross the suture lines. This characteristic facilitates differentiation with other posttraumatic scalp swellings in the neonate such as, the caput succedaneum, subgaleal hematoma and subgaleal hygroma. The caput succedaneum is a localized edema (often with hemorrhage) of the subcutaneous tissue due to injury to the presenting head after difficult or instrumental delivery. It is typically located on the vertex and is not restricted by suture lines. The swelling usually subsides within a few days. Subgaleal hemorrhage occurs in the subgaleal space which extends from the supraorbital ridges to the neck and laterally to the ears. Although rare, massive subgaleal hemorrhage can be fatal in neonates. Subgaleal hygroma is caused by skull fracture, usually after forceps delivery, whereby cerebral spinal fluid is allowed to flow through the fracture into the subgaleal space.

Infection of the cephalohematoma is rare and usually associated with (unnecessary) needle aspiration or scalp electrode application. Other complications are hyperbilirubinemia and anemia. Accompanying skull fractures or subdural hemorrhages should be excluded. Small cephalohematomas spontaneously disappear after a few weeks, others tend to increase in size. By the end of the first 2 or 3 weeks calcifications/ossifications produced by the elevated pericranium start to develop and the mass becomes firmer. In most cases subperiosteal hematomas resolve after 2 to 3 months, in some cases they persist through life.

Ultrasound and radiographic investigations usually suffice to diagnose birth trauma in newborns. However, when findings are unclear and/or further investigations are necessary to exclude more serious injuries, the use of other techniques like CT or magnetic resonance imaging is to be considered.

Bibliography

1. Currarino G.: Neonatal subperiosteal cephalohematoma crossing a synostosed sagittal suture. *Pediatr Radiol*, 2007, 37: 1283-1285.
2. King S.J., Bootroyd A.E.: Cranial trauma following birth in term infants. *BJR*, 1998, 71: 233-238.
3. Moron F.E., Morriss M.C., Jones J.J., et al.: Lumps and bumps on the head in children: use of CT and MR Imaging in solving the clinical diagnostic dilemma. *Radiographics*, 2004, 24: 1655-1674.
4. Watchko J.F.: Identification of neonates at risk for hazardous hyperbilirubinemia: emerging clinical insight. *Pediatric Clin North Am*, 2009, 56: 671-687.