

JBR-BTR, 2010, 93: 198-200.

SPONTANEOUS CHOLECYSTOCUTANEOUS ABSCESS

W.-J. Metsemakers¹, I. Quanten¹, F. Vanhoenacker², T. Spiessens¹

Spontaneous cholecystocutaneous abscesses or fistulae are rare complications of neglected biliary calculous disease which have become extremely rare during the last decades. We report a case of spontaneous cholecystocutaneous abscess in a 69-year-old male who presented with a mass in the right subcostal region. The diagnosis was made by CT scan with multiplanar reformatting. Treatment consisted of incision and drainage of the abdominal wall abscess followed by cholecystectomy in a one-stage protocol.

Key-words: Gallbladder, diseases – Abscess.

Spontaneous cholecystocutaneous abscesses or fistulae are uncommon complications of gallbladder disease. Thilesius first described the external biliary fistula in 1670 and it was Courvoisier who reported 169 cases in the nineteenth century. In their review in 1949, Henry and Orr found 36 cases of external biliary fistulas reported after 1890 (1). In the last decades these complications have become very rare, due to the improvements in diagnostic imaging, the use of broad-spectrum antibiotic therapy and advancements in biliary surgery (2, 3). We describe here a rare case of spontaneous cholecystocutaneous abscess.

Case report

A 69-year-old male was referred to the Emergency Department complaining of right upper quadrant abdominal pain that had lasted for 30 days. Clinical examination revealed a mass in the right subcostal region (Fig. 1). The patient had a history of cholecystolithiasis. Four months earlier he underwent an endoscopic retrograde cholangiopancreatography (ERCP) with papillotomy and temporary stent placement for obstructive choledocholithiasis. During a second ERCP, one month later, multiple gallstones were removed, together with the stent.

On admission the patient was in a relatively good general condition, with a heart rate of 100 beats/min and a systolic blood pressure of 140 mmHg. He was afebrile and anicteric. The white blood cell count was 15.900/mm³ (4-8) with 77% segments and we noted a CRP of 10.1 mg/dl (< 0.5). Gamma-glutamyl-

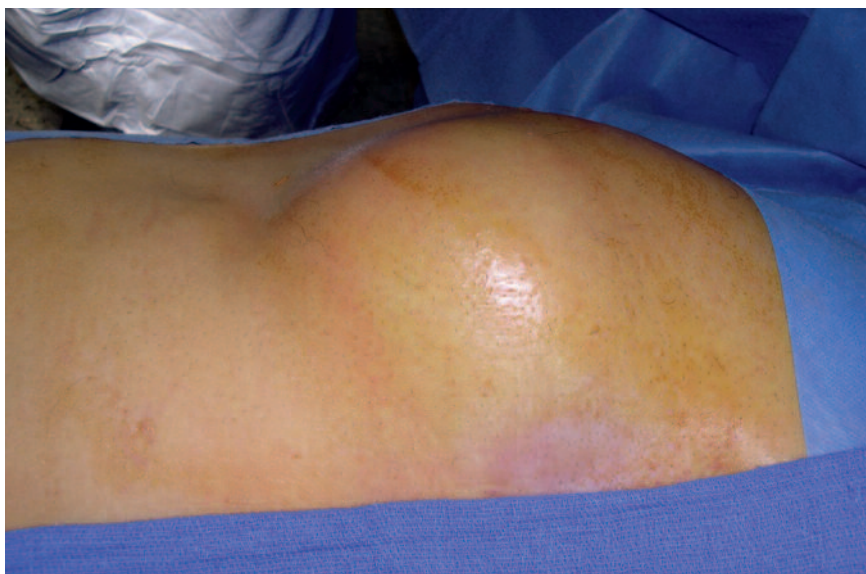


Fig. 1. — Preoperative photograph of the patient revealed a mass in the right subcostal region.

transferase (GGT) was 124 U/L (< 61). The other laboratory data were unremarkable, including normal haemoglobin, bilirubin, alkaline phosphatase, amylase and glucose levels. Computed tomography (CT) showed a huge abscess in the right anterior abdominal wall in communication with the gallbladder (Fig. 2). The abscess was drained under general anaesthesia through a small skin incision, followed by a cholecystectomy and excision of the fistula tract through a midline laparotomy. Broad-spectrum antibiotics were administered preoperatively and continued for seven days postoperatively. Histopathological analysis revealed chronic cholecystitis with no evidence of malignancy. The postoperative course was uneventful.

Discussion

Since the introduction of surgical treatment of gallbladder calculous diseases, the incidence of cholecystocutaneous abscesses and fistulae has reduced dramatically. The declining incidence is likely related to prompt diagnosis, availability of antibiotics, and early surgical intervention for cholecystitis and empyema (2, 3). Biliary fistulae can be divided into internal and external biliary fistulae by the site of exit of the fistulae. They are further subdivided based on etiology into spontaneously occurring or as post-traumatic, postoperative and iatrogenic fistulae. External biliary fistulae (biliocutaneous fistulae) or abscesses rarely occur spontaneously as a result of intrahepatic abscess, necrosis or perforation of the gallbladder, or other inflammatory process involving the biliary tree. They are more commonly postoperative or post-traumatic. Currently, iatrogenic fistulae complicating

From: Department of 1. Abdominal Surgery and 2. Radiology, General Hospital, AZ. St. Maarten, Duffel.

Address for correspondence: Dr Willem-Jan Metsemakers, M.D., AZ St. Maarten, Campus Rooienberg, Rooienberg 25, B-2570 Duffel, Belgium.
E-mail: willemjanmets@hotmail.com

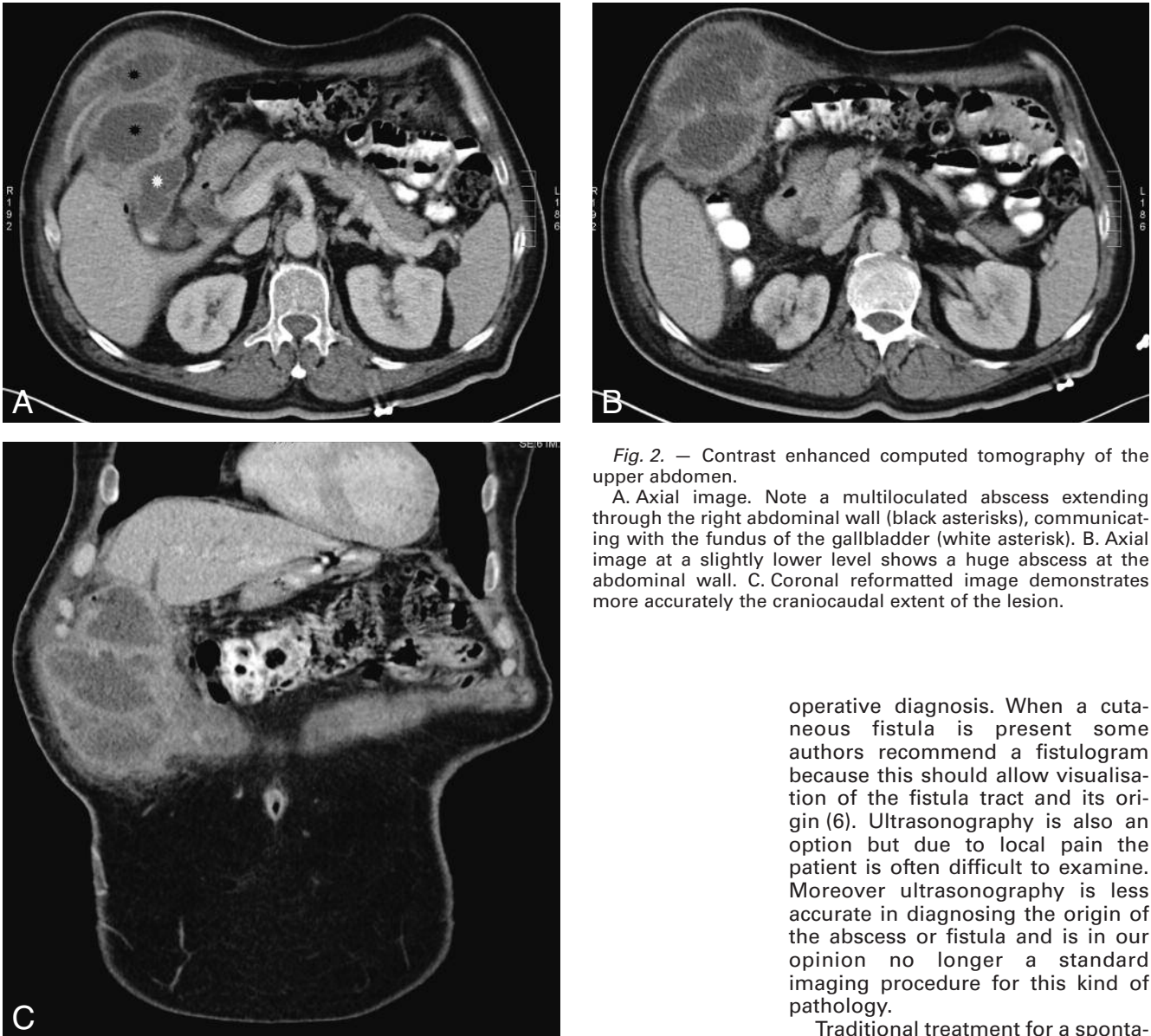


Fig. 2. — Contrast enhanced computed tomography of the upper abdomen.

A. Axial image. Note a multiloculated abscess extending through the right abdominal wall (black asterisks), communicating with the fundus of the gallbladder (white asterisk). B. Axial image at a slightly lower level shows a huge abscess at the abdominal wall. C. Coronal reformatted image demonstrates more accurately the craniocaudal extent of the lesion.

biliary tract surgery are the most common cause of external biliary fistulae (4).

Spontaneous cholecystocutaneous abscesses or fistulae are invariably a complication of neglected calculous disease, although isolated case reports have described spontaneous cholecystocutaneous fistulae due to carcinoma of the gallbladder and acalculous cholecystitis (4, 5). Women are affected more than men, reflecting the higher incidence of cholelithiasis and cholecystitis among women (2). Pathophysiologically, there is an increase in intraluminal pressure which leads to impairment of the blood flow and lymph supply to the gallbladder, thus causing mural necrosis and perforation. Perforation can occur as acute-free perforation causing peri-

tonitis, subacute perforation resulting in an abscess around the gallbladder, or chronic perforation with the formation of an internal or external biliary fistula (2, 6). On clinical examination the patient may be febrile and diaphoretic because of the infection but this is not necessarily the case. Prior to rupture, a raised erythematous area of affected skin may be observed. The surrounding skin is often cellulitic, frequently leading to an initial diagnosis of abscess as was the case in our patient. The majority of the fistulae are found in the right upper quadrant (48%) or at the site of the umbilicus (27%) (1, 5).

Because of the multiplanar reconstruction capabilities of modern CT technology, CT scan has become the imaging method of choice for pre-

operative diagnosis. When a cutaneous fistula is present some authors recommend a fistulogram because this should allow visualisation of the fistula tract and its origin (6). Ultrasonography is also an option but due to local pain the patient is often difficult to examine. Moreover ultrasonography is less accurate in diagnosing the origin of the abscess or fistula and is in our opinion no longer a standard imaging procedure for this kind of pathology.

Traditional treatment for a spontaneous cholecystocutaneous fistula or abscess has consisted of abdominal wall incision and drainage followed by "staged" cholecystectomy (5). But during the last decades a one-stage treatment protocol has become the preferred option. A laparoscopic approach appears to be a feasible option but the conversion rate is high (7, 8). Both the gallbladder and fistula need to be resected to achieve a cure. Generally the prognosis is good. However, as this condition commonly occurs in elderly patients who may have multiple medical comorbidities, surgical treatment must be tailored depending on the patient's fitness for surgery.

In conclusion, spontaneous cholecystocutaneous abscesses or fistulae are uncommon complications of gallbladder disease. In case of a high clinical suspicion prompt diagnosis

by CT scan is mandatory. Currently a one-stage, surgical, treatment protocol is the preferred option. In general the prognosis is good, however high age and coexisting medical problems may complicate therapy.

References

1. Henry C.L., Ort T.G. Jr.: Spontaneous external biliary fistulas. *Surgery*, 1949, 26: 641-646.
2. Vasanth A., Siddiqui A., O'Donnell K.: Spontaneous cholecystocutaneous fistula. *South Med J*, 2004, 97: 183-185.
3. Andley M., Biswas R.S., Ashok S., Somshekar G., Gulati S.M.: Spontaneous cholecystocutaneous fistula secondary to calculous cholecystitis. *Am J Gastroenterol*, 1996, 91: 1656-1657.
4. Knol J.A., Eckhauser FE.: Biliary fistulas. In: *Shackelford's surgery of the alimentary tract, volume 3*. Edited by Zuidema G.D., Yeo C.J. Printed by W.B. Saunders company, Philadelphia, 2002, pp 273-279.
5. Birch B., Cox S.: Spontaneous external biliary fistula uncomplicated by gallstones. *Postgrad Med J*, 1991, 67: 391-392.
6. Nicholson T., Born M., Garber E.: Spontaneous cholecystocutaneous fistula presenting in the gluteal region. *J Clin Gastroenterol*, 1999, 28: 276-277.
7. Kumar S.S.: Laparoscopic management of a cholecystocutaneous abscess. *Am Surg*, 1998, 64: 1192-1194.
8. Mathonnet M., Maissonette F., Gainant A., Cubertafond P.: Spontaneous cholecystocutaneous fistula: natural history of biliary cholecystitis. *Ann Chir*, 2002, 127: 378-380.