

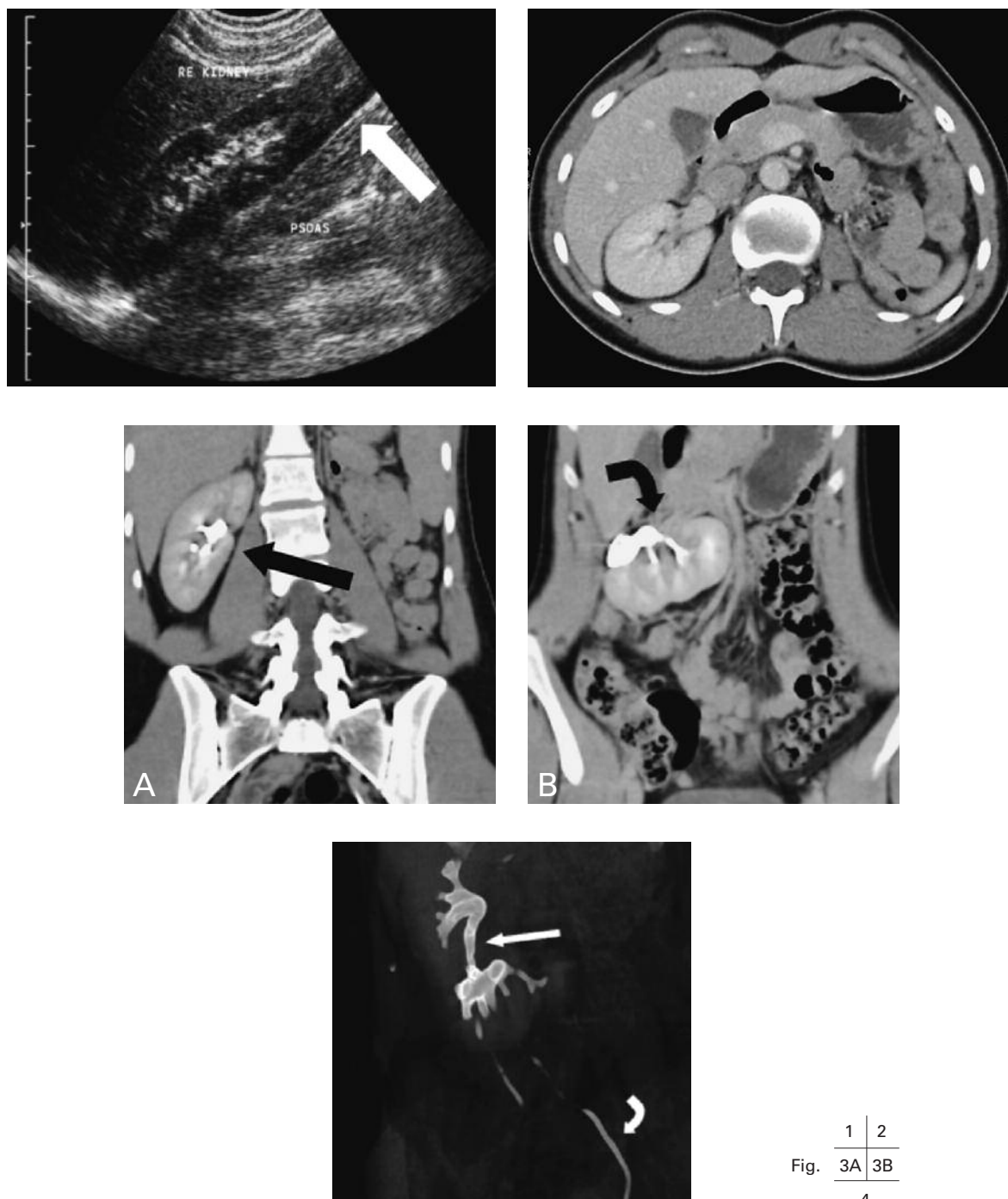
JBR-BTR, 2010, 93: 162-163.

ABDOMINAL MASS DUE TO CROSSED RENAL ECTOPIA AND FUSION

E.J. Vandervliet^{1,2}, F.M. Vanhoenacker^{1,2}, P.M. Parizel²

Key-word: Kidney, abnormalities

Background: A 22-year-old woman was referred to the department of Radiology, because of a painless mass at the right hemiabdomen.



	1	2
Fig.	3A	3B
	4	

Department of 1. Radiology, AZ St.-Maarten, Duffel and Mechelen, Belgium, and Department of 2. Radiology, Antwerp University Hospital, UZA, University of Antwerp, Edegem, Belgium

Work-up

Ultrasonography of the abdomen was performed (Fig. 1) and shows on the longitudinal view a mass extending along the inferior border of the right kidney (arrow).

On axial contrast-enhanced CT-image of the abdomen (Fig. 2) the absence of a kidney in the left retroperitoneal space is noted.

Coronal reformatted contrast-enhanced CT-images of the abdomen (Fig. 3) shows on A a normally located right kidney (arrow) and on B ectopic location of the left kidney, which appears to be fused with the lower pole of the right kidney (curved arrow).

On coronal MIP-image (Fig. 4), two ureters are noted, one originating at the normal, orthotopic right kidney (arrow), and the other originating at the ectopic kidney (curved arrow). The latter ureter crosses the midline and ends distally at the left posterior border of the bladder.

Radiological diagnosis

Based on the characteristic imaging features, the diagnosis of *crossed fused renal ectopia* is made.

Discussion

Renal ectopia (RE) is a rare condition in which one or both kidneys are abnormally located in the retroperitoneum due to a developmental anomaly. In ipsilateral RE the kidney is located on the same side as its ureteral orifice, whereas in crossed RE both kidneys are located in the same body half, albeit with their ureteral orifices normally situated. In the case of crossed RE many variants exist, with or without fusion of the kidneys. Only very seldom is there a solitary kidney.

Appearing at approximately 5 or 6 weeks of gestation at the level of the S2 vertebra, kidney and ureter develop from the renal blastema and the ureteric bud respectively. The ureteric bud and the blastema fuse and ascend as immature kidneys in the retroperitoneum towards the final location of the kidneys in the retroperitoneal space. Anomalies

develop due to any combination of growth arrest, arrest of renal ascent and fusion.

In autopsy series the incidence of crossed renal ectopia is estimated as 1 in 2000, 85% of which are fused variants. The male to female ratio is 3 to 2.

An autosomal recessive trait has been suggested and in animals teratogenic agents have been incriminated.

The most common associated anomalies include ectopic ureter, extrarenal calices, urethral valves, anorectal malformations and vertebral anomalies.

If symptomatic at all, the most common symptoms are pain and hematuria due to urolithiasis. Reflux is a very common finding, resulting in infection and even in end-stage renal insufficiency. A higher incidence of renal cell carcinoma has been described in RE.

Plain radiographs may show the absence of normal kidney shadow and an abdominal mass alongside the normal kidney. CT is considered the gold standard in the diagnosis as it offers excellent visualization of the implantation of the ureters and the vascular supply and may differentiate between fused and nonfused variants. Ultrasound is comparable to CT. MRI has no clear role in the diagnosis.

The differential diagnosis includes horseshoe kidney, which is the most common fusion anomaly of the urinary tract, transplanted kidney and acquired renal displacement, for instance due to hepatomegaly.

Therapy is limited to treatment of symptoms and complications.

Bibliography

1. Friedland G.W., de Vries P.: Renal ectopia and fusion. Embryologic Basis. *Urology*, 1975, 5: 698-706.
2. Guarino N., Tadini B., Camardi P., et al.: The incidence of associated urological abnormalities in children with renal ectopia. *J Urol*, 2004, 172: 1757-1759.
3. Hertz M., Rubinstein Z.J., Shahin N., et al.: Crossed renal ectopia: clinical and radiological findings in 22 cases. *Clin Radiol*, 1977, 28: 339-344.