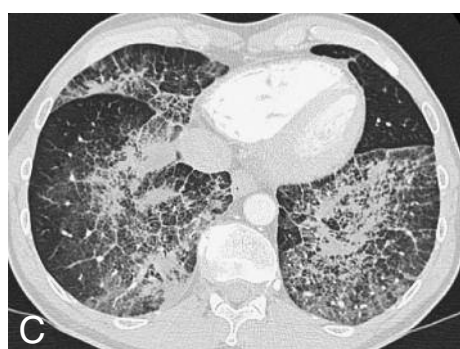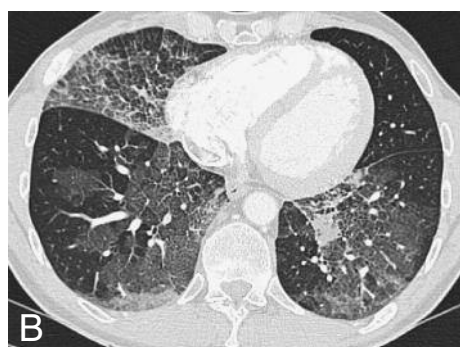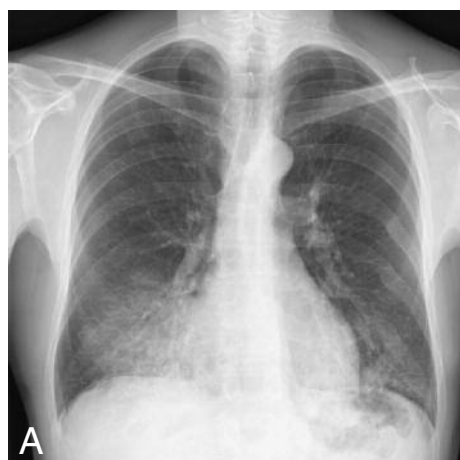


JBR-BTR, 2010, 93: 228.

IMAGES IN CLINICAL RADIOLOGY***An uncommon cause of asymptomatic crazy paving pattern: exogenous lipid pneumonia***

C. Schoofs, L. Bladt, W. De Wever

A 54-year-old man presented at our department complaining of chest wall pain with clinical suspicion of rib fractures. Neither the clinical examination, the medical history of the patient nor the laboratory findings revealed any abnormalities. The patient mentioned chronic use of Trazolan® (trazodon).

A chest X-ray (PA & lateral) was performed and revealed several post-traumatic rib fractures. There was also a patchy distribution of consolidations in the postero-basal segment of the right lower lobe, as well as in the basal segment of the right middle lobe (Fig. A). Those patchy consolidations were also present on a preceding chest film, obtained 2 years before date, but the consolidation had clearly gained in volume and density.

Spiral chest CT showed a crazy-paving pattern. There were diffuse ground-glass opacities with superposition of thickened inter- and intra-lobular septa and interlobular lines. In both lower lobes there was also superposition of consolidation areas. There was relative sparing of the subpleural space (Fig. B, C).

Since these radiologic findings could be part of a medicamentous-induced chronic eosinophilic pneumonia, an etiologic link was suspected with Trazolan and the use of this product was aborted without any results. Subsequent chest imaging showed no improvement after six weeks, even though the patient was completely asymptomatic. Lung biopsies were obtained, revealing definite deposition of lipid drops surrounded by histiocytes and at some point organizing in lipid-granulomas, with a surrounding lymphocytary infiltrate. These pathologic findings correlate with a lipid pneumonia.

At specific anamnestic questioning it appeared that the patient had been using decongestant nose drops for a long period in large amount. Paraffin-containing nose drops are the most common cause of exogenous lipid pneumonia.

Comment

Lipid pneumonia is an uncommon condition resulting from chronic aspiration of mineral, animal or vegetal oils into the lungs. Once inhaled, the oil is phagocytosed by macrophages that fill the alveoli and distend the alveolar walls, causing acute and chronic pneumonitis. Over time, the macrophages transport the oil from the alveoli to the interlobular septa, resulting in localized granulomas and pulmonary fibrosis.

Pathologically, exogenous lipid pneumonia is characterized by the presence of giant cell granulomas, alveolar and interstitial fibrosis, and chronic inflammation.

Symptoms are nonspecific and may include progressive dyspnea, cough and even hemoptoe, though the affected individual can also be asymptomatic, as proven by our case.

Conventional radiography can show airspace consolidation, an irregular mass-like lesion or a reticulonodular pattern. The most common locations for lipid pneumonia are the dependent portions of the lung. The characteristic finding on CT of the chest is lung consolidation with fat attenuation, but a crazy paving pattern with ground-glass opacification with superposition of septal thickening and centrilobular interstitial thickening as in our case has also been described.

The diagnosis is most often made based on a combination of radiographic and clinical features, long-term stability and the absence of other causes of pulmonary disease. Treatment involves discontinuation of the offending agent and radiographic follow-up to ensure stability.

Although lipid pneumonia is an unusual cause of chronic lung disease, it is an important consideration in the differential diagnosis of several pulmonary syndromes because progression is halted, or at least slowed, by stopping exposure to the offending lipid substance.

Department of Radiology, UZ Gasthuisberg, Leuven, Belgium.