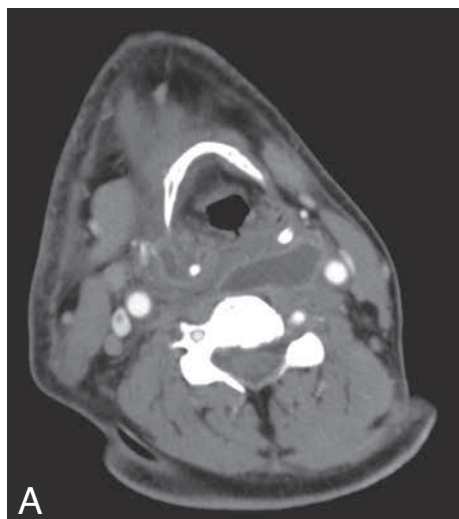


JBR-BTR, 2015, 98: 95.

IMAGES IN CLINICAL RADIOLOGY***MDCT findings of polymicrobial descending necrotizing mediastinitis***C. Karanikas, P. Lampropoulou, D. Karakiklas, C.S. Baltas, A. Demertzis, C. Drosos¹

A 43-year-old Caucasian male with an uneventful medical history presented to ER complaining of sore throat and fever of 38.3°C. Clinical examination revealed unilateral right sided tonsillitis. Over the next 4 days, he developed malaise, shortness of breath, right-sided neck swelling and chest pain and he was admitted. The patient was systematically unwell with clinical manifestations of persistent neck swelling and pain radiating to the right shoulder, fever, slight discoloration of overlying skin, subcutaneous crepitation, mild trismus, odynophagia and decreased oral intake, in the setting of a peritonsillar abscess.

Within a few hours after hospitalization, the patient presented upper airway obstruction due to massive edema, resulting in acute respiratory insufficiency that necessitated tracheal intubation and transfer to the ICU, while planning for surgical intervention.

MDCT scan of the cervical and thoracic region (Fig. A,B,C) showed a parapharyngeal abscess descending into the mediastinum, spreading towards the diaphragm, with bilateral pleural effusions, along with diffuse necrotizing fasciitis, collection of gas in mediastinal compartments and soft tissue infiltration with loss of normal fat planes. The patient underwent combined extensive neck and thorax drainage in conjunction with limited surgical debridement consisting of cervicotomy. Swabs identified a polymicrobial infection with predominant species of *Streptococcus pyogenes*, anaerobic *Peptostreptococci* and *Streptococcus viridans*. The empirical antibiotic regimen included piperacillin – tazobactam and vancomycin.

After 29 days of intubation and ventilation in ICU, the patient was extubated and transferred to the ward in order to complete the 6-week-course of IV antibiotic therapy. By this time the patient presented no residual deficits.

Comment

Numerous series of patients suffering of mediastinitis have been reported, especially the descending necrotizing type both focal and diffuse, that lead Endo et al to develop a classification system of the extent of the disease on the basis of the CT findings. Type I disease represents mediastinitis confined above the carina, type IIA disease extends to the anterior lower mediastinum and type IIB disease involves both anterior and posterior mediastinum. Patients with type I mediastinitis may not require drainage at all, while type IIA patients require drainage without sternotomy (via the subxiphoid approach) and type IIB patients require drainage with open thoracotomy.

MDCT is the study of choice for evaluation of mediastinal emergencies such as DNM, since it provides sagittal/coronal reconstructions, is readily available, non invasive and easy to perform. There are both primary and

secondary CT features of DNM, both of which were present in our case. Primary features include free gas bubbles in the mediastinum and/or localized fluid collections, or even abscess, and secondary CT findings include increased attenuation of mediastinal fat, pleural and/or pericardial fluid, enlargement of lymph nodes and rarely lung parenchymal abnormalities.

Reference

1. Weaver E., Nguyen X., Brooks M.A.: Descending necrotizing mediastinitis: two case reports and review of the literature. *Eur Respir Rev*, 2010, 19: 141-149.

1. Radiology Department, "G. Gennimatas" General Hospital of Athens, Athens, Greece.