

Short Communication

MIXED INTESTINAL PARASITIC INFECTION IN KID: A CASE REPORT

Madhulina Maity^{1*}, Vineetha S.², Monalisa Sahoo³, Abhijit Nandi⁴, Sumit Sardana⁵

Received 23 October 2017, revised 03 April 2018

ABSTRACT: A four months old female Black Bengal kid presented to post mortem examination, revealed heavy mixed infection of nematode (*Trichuris* sp.) and cestode (*Moniezia* sp.). The kid was reported anorectic, weak and unthrifty. After opening the carcass, moderate amount of sero-sanguineous fluid was found in the abdominal cavity along with inflamed intestine and enlarged, friable liver and distended gall bladder. In addition, there were adult parasites in intestine and microscopic examination of faeces showed characteristic parasitic eggs.

Key words: Goat kid, *Moniezia* sp., *Trichuris* sp.

Goat and sheep production is having a great socio-economic concern in India, particularly in the rural areas. The tropical monsoon climate favours the life-cycle of parasites, including the gastro-intestinal ones. Among the nematodes, *Haemonchus contortus*, *Trichostrongylus* spp., *Bunostomum trigonocephalum*, *Chabertia* sp., *Nematodirus* sp., *Skrjabinema ovis* and *Trichuris ovis* etc. are frequently seen (Gupta *et al.* 1987, Singh *et al.* 1997, Saminathan *et al.* 2015). *Moniezia* is a very common milk tapeworm of ruminants. It affects the young ones during suckling period. The intermediate host is a mite and it ingests the eggs from contaminated pasture and eggs are then accidentally swallowed by the calf, kid or lamb while grazing (Soulsby 1982). The most common symptoms of infection are anorexia, dullness, deprived growth and diarrhoea. Heavy infection of live tapeworm can block the gut and also dead and decomposing worms in the gut produce ammonia gas which eventually can kill the young animal. Here we report a case of mixed helminthic infection *i.e.* tapeworm and round worm resulting into diarrhoea and death of a goat kid.

The case

A four months old female Black Bengal goat kid with the history of anorexia, weakness and poor growth was presented at post mortem facility of the Institute. The clinical signs like loss of appetite, unthriftiness, diarrhoea were in accordance with the findings of earlier workers (Urquhart *et al.* 1996, Kim Suvarna *et al.* 2013). In addition, poor growth rate, anaemia, rough hair coat, pot-

belly and considerable intestinal affections were also reported earlier (Fagbemi and Dipeolu 1983). On external examinations, visible mucous membranes were found pale and perineal region was having oedematous swelling and soiled with faecal matter. Thorough and critical examination was carried out during necropsy. The abdominal cavity contained 10-15 ml of sero-sanguineous fluid. The liver was moderately enlarged with rounded edges and multiple to coalescing pin-point necrotic foci were observed on the cranio-dorsal surface. The gall bladder was severely thickened and distended with thick bile. The lungs were moderately swollen due to congestion and oedema. After completion of post-mortem examination, tissue sections from liver, lungs, spleen, kidneys, intestine, heart and brain were collected in 10% neutral buffered formalin (NBF) for routine histopathological examination. The small intestine was heavily loaded with twisting, white, flat, tape-like worms (*Moniezia* sp.) (Fig. 1). Moreover, slender, thread like round worm (*Trichuris* sp.) were found attached to the mucosal wall of the caecum. The worms were also collected in 10% NBF and subjected to parasitological examination. Similar type of stuffing of intestine with adult tapeworms was also found by earlier workers (Patil *et al.* 2016). The worm belonging to the genus *Trichuris* are generally known as 'whip-worm', since the anterior part of the body is long and slender, while the posterior part is much thicker (Soulsby 1982). Faecal examination revealed a mixture of characteristic brown, barrel-shaped eggs with transparent plug at both ends and quadrangular

^{1,2} PhD Scholar, ³ Scientist, ⁵ M.V.Sc Scholar, Division of Pathology, ICAR-Indian Veterinary Research Institute, Bareilly-243122, Uttar Pradesh, India.

⁴ PhD Scholar, Division of Parasitology, ICAR-Indian Veterinary Research Institute, Bareilly-243122, Uttar Pradesh, India.

*Corresponding author. e - mail: maity.madhulina@gmail.com

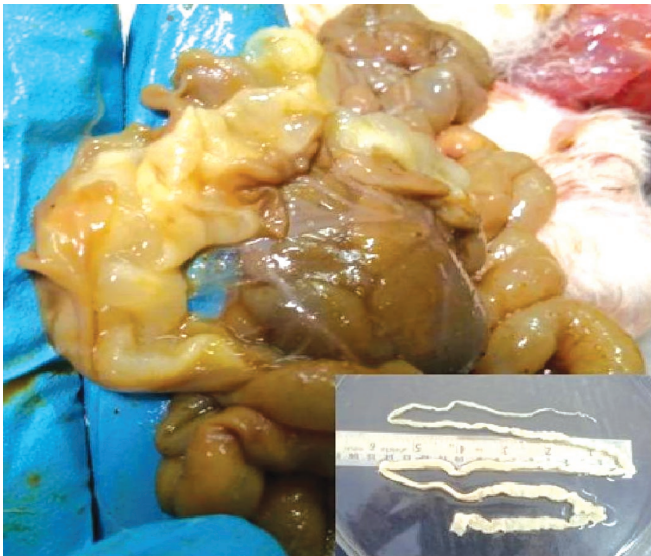


Fig. 1. Kid intestine loaded with tapeworms causing obstruction of the lumen. Inset: Adult *Moniezia* sp.

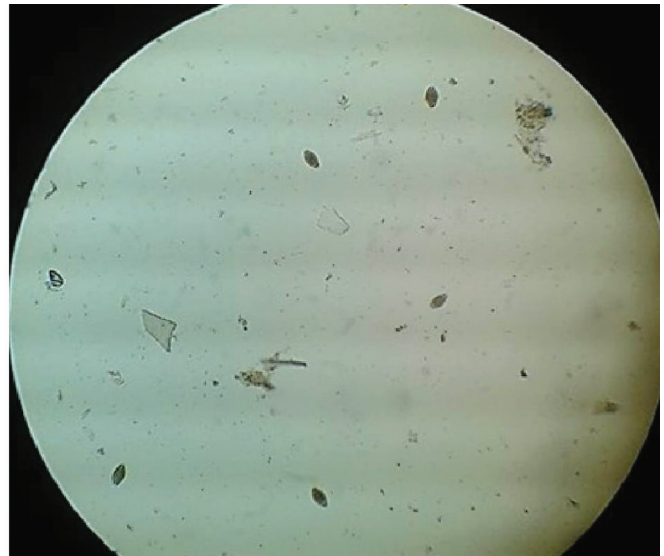


Fig. 2. *Trichuris* sp. egg in the faecal content.

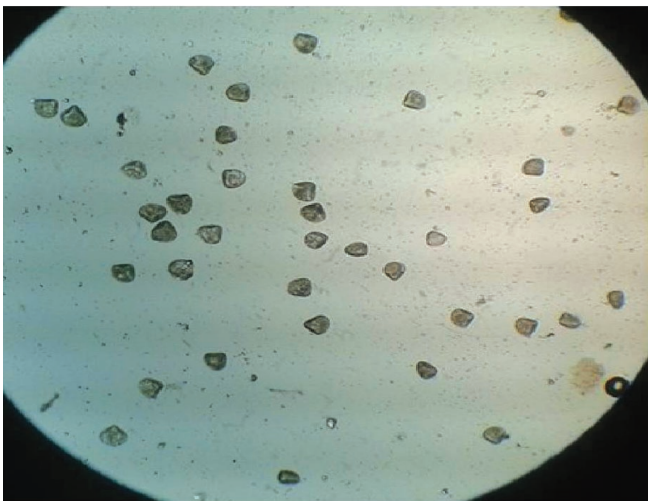


Fig. 3. *Moniezia* sp. egg in the faecal content.

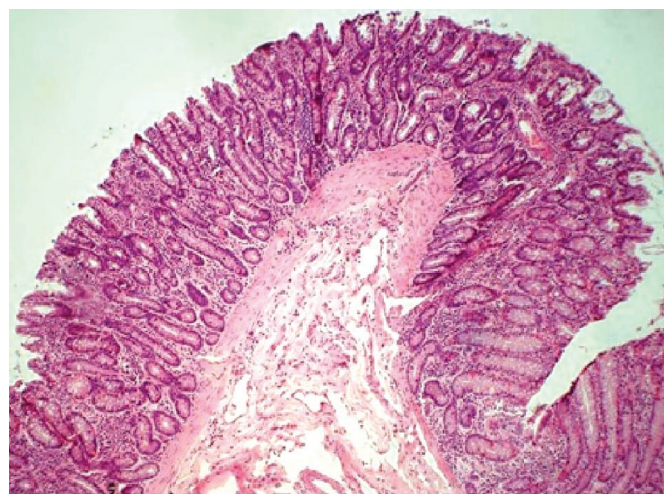


Fig. 4. Fusion of intestinal villi along with sloughing of mucosa at the crown of the villi (H&E, 10X).

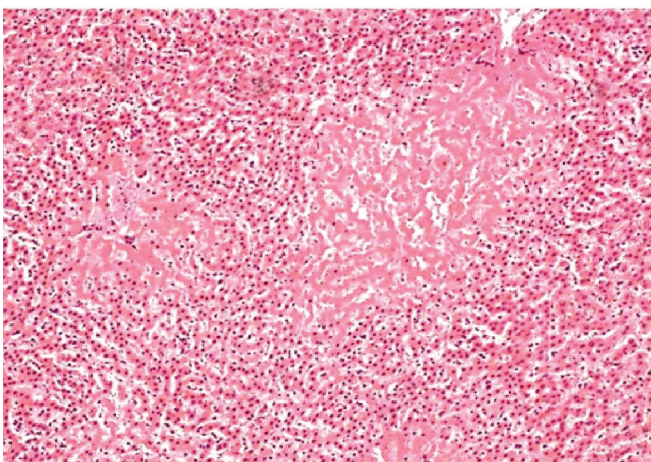


Fig. 5. Liver section showing foci of coagulative necrosis and infiltration of mononuclear inflammatory cells surrounding the necrotic areas. (H&E, 20X).

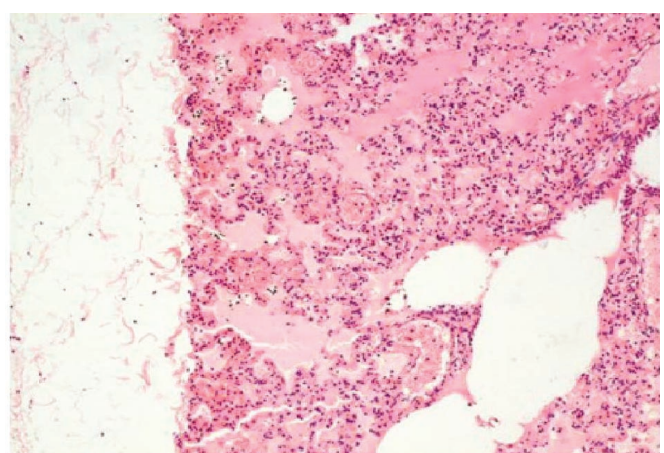


Fig. 6. Lung section showing thickened pleura, severe accumulation of oedematous fluid, infiltration of inflammatory cells and widening of interstitial wall (H&E, 10X).

shaped egg with pyriform apparatus, suggestive of eggs of *Trichuris* sp. (Fig. 2) and *Moniezia* sp. (Fig. 3) respectively. Soulsby (1982) described that eggs of *Trichuris* sp. are brown, barrel-shaped, with a transparent mass at either pole. Also, they contain an unsegmented embryo when laid. Furthermore eggs of *Moniezia* sp. are triangular or quadrangular in shape, containing a well-developed pyriform apparatus (Soulsby 1982).

Histopathological examination of the small intestinal segments revealed sloughing of mucosa at the crown of villi and increase in goblet cell population resulting into diffuse catarrhal exudation (Fig. 4). Also, widespread areas with fused and flattened villi were found. Caecum revealed infiltration of inflammatory cells along with moderate number of erythrocytes and occasional eosinophils. Similar types of findings *viz.* denudation of villi, petechiae on the mucosa, along with cellular infiltration in the caecum and goblet cell hyperplasia were reported earlier (Patil *et al.* 2016, Mohanta *et al.* 2007). The liver exhibited multiple to coalescing foci of coagulative necrosis over the cranio-dorsal surface. Infiltration of inflammatory cells predominantly mononuclear cells around the necrotic areas was evident (Fig. 5). Lungs exhibited diffuse accumulation of oedematous fluid in the alveoli as well as alveolar septa resulting into severe widening of the interstitial spaces (Fig. 6). Moreover, scattered areas with atelectic changes and few areas of compensatory emphysema were evident. On parasitological examination, characteristic milky white, flattened, tape-like worm of *Moniezia* sp. were identified.

This case of mixed parasitic infection was reported in mid-September of 2016. High prevalence of *Moniezia* sp. and *Trichuris* sp. during summer and monsoon was also reported earlier (Pathak and Pal 2008). Though, Horak *et al.* (2001) reported *Moniezia expansa* infection from January to March, mostly in the age group of 3-5 months. The authors also explained that the life cycle of the tapeworm takes one year to complete in goat including survival of the tapeworm in the intermediate host (*i.e.* oribatid mites) during intervening months. In conclusion, heavy, mixed parasitic infection of *Moniezia* sp. and *Trichuris* sp. caused severe malnutrition leading to pulmonary oedema which ultimately directed to the death of the Black Bengal kid.

ACKNOWLEDGEMENTS

The authors are thankful to the Director, Joint Directors and Head, Division of Pathology, ICAR-IVRI, Izatnagar

for providing the necessary facilities to carry out this work.

REFERENCES

- Fagbemi BO, Dipeolu OO (1983) *Moniezia* infection in the dwarf breeds of small ruminants in Southern Nigeria. *Vet Quarterl* 5: 75-80.
- Gupta RP, Yadav CL, Chaudhri SS (1987) Epidemiology of gastrointestinal nematodes of sheep and goats in Haryana, India. *Vet Parasitology* 24(1-2): 117-127.
- Horak IG, Macivor, KM De F, Greeff CJ (2001) Parasites of domestic and wild animals in South Africa. XXXIX. Helminth and arthropod parasites of Angora goats in the southern Karoo. *Onderstepoort J Vet Res* 68: 27-35.
- Kim Suvarna S, Layton C and Bancroft JD (2013) *Bancroft's Theory and Practice of Histological Techniques*, 7th edn. Churchill Livingstone, Elsevier Ltd. 105.
- Mohanta UK, Anisuzzaman A, Farjana T, Das PM, Majumder S, Mondal MMH (2007) Prevalence, population dynamics and pathological effects of intestinal helminths in Black Bengal goats. *Bangladesh J Vet Medic* 5(1): 63-69.
- Pathak AK, Pal S (2008) Seasonal prevalence of gastrointestinal parasites in goats from durg district of Chhattisgarh. *Vet World* 1(5): 136-137.
- Patil RJ, Sawale GK, Ramteke S, Pallampale HY, Bharkad GP (2016) Mixed parasitic infection of *Moniezia expansa* and *Trichuris* spp. in Sirohi kid. *Indian J Vet Pathol* 40(2): 174-176.
- Saminathan M, Gopalakrishnan A, Latchumikanthan A, Milton AAP, Aravind M, Dhama K Singh R (2015) Histopathological and parasitological study of blood-sucking *Haemonchus contortus* infection in sheep. *Advan Anim Vet Sci* 3(2): 99-108.
- Singh D, Swarnkar CP, Khan FA, Srivastava CP, Bhagwan PSK (1997) Epidemiology of ovine gastrointestinal nematodes at an organised farm in Rajasthan, India. *Small Rum Res* 26(1-2): 31-37.
- Soulsby EJM (1982) *Helminths, arthropods and protozoa of domesticated animals* (7th edn.). Bailliere Tindall.
- Urquhart GM, Armour J, Duncan JL, Dunn AM, Jennings FW (1996) *Veterinary Parasitology*. 2nd edn. Blackwell Science, Co. U.K. 132-233.

*Cite this article as: Maity M, Vineetha S, Sahoo M, Nandi A, Sardana S (2018) Mixed intestinal parasitic infection in kid: a case report. *Explor Anim Med Res* 8(1): 120-122.