

Original Article

Multifocality and Bilaterality of Papillary Thyroid Microcarcinoma

Yoon Kyoung So¹ · Myung Woo Kim¹ · Young-Ik Son²¹Department of Otorhinolaryngology-Head and Neck Surgery, Inje University Ilsan Paik Hospital, Inje University College of Medicine, Goyang;²Department of Otorhinolaryngology-Head and Neck Surgery, Samsung Medical Center, Sungkyunkwan University School of Medicine, Seoul, Korea

Objectives. Papillary thyroid carcinomas frequently occur as two or more separate foci within the thyroid gland (18%–87%). However, those multifocal tumors are easy to be undetected by preoperative radiologic evaluations, which lead to remnant disease after initial surgery. We aimed to study the incidence of multifocal papillary thyroid microcarcinomas (PTMCs), diagnostic accuracy of preoperative radiologic evaluation, predictive factors, and the chance of bilateral tumors.

Methods. Two hundred and seventy-seven patients with PTMC were included in this study. All patients underwent total thyroidectomy as an initial treatment. Medical records, pathologic reports, and radiological reports were reviewed for analysis.

Results. Multifocal PTMCs were detected in 100 of 277 patients (36.1%). The mean number of tumors in each patient was 1.6 ± 1.1 , ranging from 1 to 10. The additional tumor foci were significantly smaller (0.32 ± 0.18 cm) than the primary tumors (0.63 ± 0.22 cm) ($P < 0.001$). There was no significant relationship between primary tumor size and the presence of contralateral tumors. With more tumors detected in one lobe, there was greater chance of contralateral tumors; 18.8% with single tumor focus, 30.2% with 2 tumor foci, and 46.2% with 3 or more tumor foci in one lobe. Sensitivity of preoperative sonography was 42.7% for multifocal tumors and 49.0% for bilateral tumors. With multivariate analysis, nodular hyperplasia was the only significant factor for multifocal tumors.

Conclusion. In cases of PTMCs, the incidence of multifocal tumors is high. However, additional tumor foci are too small to be diagnosed preoperatively, especially under the recent guidelines on radiologic screening tests for papillary thyroid carcinoma. Multifocal PTMCs have high risk of bilateral tumors, necessitating more extensive surgery or more thorough follow-up.

Keywords. Thyroid Nodule; Papillary Thyroid Microcarcinoma; Neoplasms, Multiple Primary; Ultrasonography; Preoperative Procedures

INTRODUCTION

Papillary thyroid carcinomas (PTCs) may occur as two or more separate foci within the thyroid gland. The frequency of such

multifocal PTCs has been reported as 18%–87%, varying depending on the diagnostic techniques [1-6]. Multifocal PTCs have been associated with the increased risks of lymph node metastasis, distant metastases, persistent local disease after initial treatment and regional recurrence [1,3,4,6,7]. All these features warrant more aggressive treatment for multifocal PTCs [8-10].

However, additional tumor foci are smaller than the representative tumor and frequently not diagnosed preoperatively. In many cases, those multifocal tumors are incidentally found by pathological analysis. Importantly, preoperatively undiagnosed contralateral tumor foci can lead to undertreatment and remnant disease after initial surgery, especially, in cases of papillary thy-

• Received February 13, 2015

Revised February 27, 2015

Accepted March 7, 2015

• Corresponding author: **Young-Ik Son**

Department of Otorhinolaryngology-Head and Neck Surgery, Samsung

Medical Center, Sungkyunkwan University School of Medicine,

81 Irwon-ro, Gangnam-gu, Seoul 135-710, Korea

Tel: +82-2-3410-3577, Fax: +82-2-3410-6987

E-mail: yison@skku.edu

Copyright © 2015 by Korean Society of Otorhinolaryngology-Head and Neck Surgery.

This is an open-access article distributed under the terms of the Creative Commons Attribution Non-Commercial License (<http://creativecommons.org/licenses/by-nc/3.0>) which permits unrestricted non-commercial use, distribution, and reproduction in any medium, provided the original work is properly cited.

roid microcarcinomas (PTMCs) which are frequently managed with lobectomy alone. However, the diagnostic accuracy of preoperative radiologic tests for multifocal PTMCs has not been well investigated and there are no known predictor for multifocal or bilateral tumors.

In this study, we aimed to study the incidence of multifocal PTMCs, diagnostic accuracy of preoperative radiologic evaluation, predictive factors, and the chance of bilateral tumors.

MATERIALS AND METHODS

Patients

A total 300 patients with PTMC underwent thyroidectomy at Samsung Medical Center, Seoul, Korea, from January 2008 to December 2008. Of those patients, 13 patients who received thyroid lobectomy and 10 patients without available preoperative radiologic tests were excluded. As a result, 277 patients with PTMC who underwent total thyroidectomy were included in this study. Central neck dissection was performed for 253 patients and lateral neck dissection for 2 patients. Diagnosis of PTMC was reconfirmed by the surgical pathology for all patients. Ultrasound (US)-guided fine needle aspiration was performed for the representative largest tumor and contralateral suspicious nodule. Radiologic accuracy was studied in 274 patients, excluding 3 for whom the exact number and location of tumors are not clearly described on the radiologic reports. Preoperative US reports were available in 235 patients. For 39 patients without available US reports, computed tomography (CT) reports were reviewed.

Clinicopathological parameters

The mean age of the patients was 49.3 ± 9.4 years. The study included 225 females and 52 males. Medical records, pathologic

reports and radiological reports were reviewed for analysis. Clinicopathological characteristics of the 227 patients are presented in Table 1.

Statistical analysis

Descriptive statistics was presented regarding to multifocal tumors and bilateral tumors. For 274 patients excluding 3 patients for whom the exact number and distribution of tumors are not definitely described on the radiologic reports, sensitivity, specificity, positive predictive values and negative predictive values of CT/sonography for multifocal tumors and bilateral tumors are calculated. Including those 274 patients, correlation between unilateral multifocal tumors and bilateral tumors was analyzed using Fisher exact test. Paired *t*-test was performed to compare the size of largest primary tumors and secondary tumors in each case, including 94 patients for whom the size of primary and secondary tumors are available. Chi-square test and Fisher exact test were used to analyze the significance of difference in the proportion of variables (univariate analysis). Logistic regression analysis was performed for multivariate analysis to determine significant factors associated with multifocal tumor. All statistical analyses were performed using SPSS ver. 17.0 (SPSS Inc., Chicago, IL, USA) and significance was accepted at $P < 0.05$.

RESULTS

Characteristics of multifocal PTMC

Multifocal PTMCs were detected in 100 of 277 patients (36.1%). The mean number of tumors in each patient was 1.6 ± 1.1 , ranging from 1 to 10. One hundred seventy seven patients (63.9%) had single tumor focus, 59 (21.3%) had 2 foci, and 41 (14.8%) had 3 or more foci (Fig. 1). The mean size of the largest primary tumor in each patient 0.6 ± 0.2 cm. The other tumors of each patient were much smaller and had not been preoperatively detected by US \pm CT in most cases. In 94 cases of available size data on multifocal tumors, the mean number of secondary tumors of each patient was 0.32 ± 0.18 cm. in these 94 cases, the mean size

Table 1. Clinicopathological characteristics (n=277)

Characteristic	Value
Age (year)	49.3 ± 9.4
Sex (male:female)	52:225
Size of tumor (cm)*	0.6 ± 0.2
Total number of tumors	448
Classical papillary	443
Follicular variant	4
Tall cell variant	1
No. of tumor per each patient	1.6 ± 1.1
Multifocal tumors	100 (36.1)
Bilateral tumors	63 (22.7)
Extrathyroid extension	163 (58.8)
Lymphocytic thyroiditis	80 (28.9)
Nodular hyperplasia	87 (31.4)
Lymph node metastasis	88 (31.8)

Values are presented as mean \pm SD or number (%) unless otherwise indicated.

*Mean size of the largest tumor in each patient.

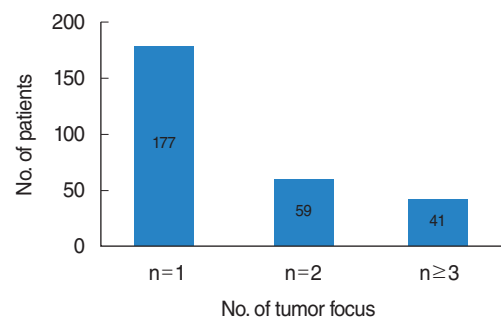


Fig. 1. Number of tumor per each patient. The number of tumor per each patient ranged from 1 to 10. The mean number of tumor per each patient was 1.6.

difference between primary and secondary tumors was 0.30 ± 0.23 cm (paired *t*-test, $P < 0.001$) (Table 2).

Extrathyroid extension was significantly more frequent in multifocal PTMC group than in unifocal PTMC group (71% vs. 52%, $P = 0.001$). Similarly, lymph node metastasis was more frequent in multifocal PTMC group, albeit without statistical significance (38.0% vs. 28.2%, $P = 0.062$).

Bilateral tumors

Bilateral PTMCs were detected in 63 of 277 patients (22.7%). There was no significant relationship between primary tumor size and the presence of contralateral tumors; the mean size of primary tumor was 0.58 ± 0.23 cm in 214 patients without contralateral tumors and 0.63 ± 0.22 cm in 63 patients with contralateral tumors (*t*-test, $P = 0.117$).

With more tumors detected in dominant lobe (in which the largest primary tumor is present), there was greater chance of contralateral tumors (Fisher exact test, $P = 0.024$). Contralateral tumors were detected in 41 of 218 cases (18.8%) with single tumor focus, in 13 of 43 cases (30.2%) with 2 tumor foci, and in 6 of 13 cases (46.2%) with 3 or more tumor foci in dominant lobe (Fig. 2).

Accuracy of preoperative radiologic examination

Sensitivity and specificity of preoperative US were 42.7% and 92.2% for multifocal tumors. Sensitivity and specificity of preoperative CT were 29.4% and 95.5% for multifocal tumors (Table 3). Sensitivity and specificity of preoperative sonography were 49.0% and 93.5% for bilateral tumors. Sensitivity and specificity

Table 2. Size difference between primary and secondary tumors

Tumor	Size (cm), mean \pm SD	<i>P</i> -value*
Primary	0.63 ± 0.22	< 0.001
Secondary	0.32 ± 0.18	

*Paired *t*-test was performed including 94 patients for whom the size of primary and secondary tumors are available. Mean size difference between primary and secondary tumors was 0.30 ± 0.23 cm.

Table 3. Sensitivity and specificity of preoperative radiologic evaluation for multifocal tumors

Tumor	Sensitivity (%)	Specificity (%)	PPV (%)	NPV (%)
Multifocal tumors				
US (n=235)*	42.7	92.2	74.5	75.0
CT (n=39)	29.4	95.5	83.3	63.6
Total (n=274)	40.4	92.6	75.5	73.3
Bilateral tumors				
US (n=235)*	49.0	93.5	66.7	87.4
CT (n=39)	28.6	100	100	71.4
Total (n=274)	44.4	94.3	70.0	85.0

PPV, positive predictive value; NPV, negative predictive value; US, ultrasound; CT, computed tomography.

*The results of fine needle aspiration were considered together for determination of multifocal tumors.

of preoperative CT were 28.6% and 100% for bilateral tumors (Table 3).

Relationship between multifocal tumors and other clinicopathological characteristics

Multivariate analysis involving clinicopathological parameters (age, sex, primary tumor size, presence of nodular hyperplasia, presence of lymphocytic thyroiditis) showed that nodular hyperplasia was predictive of multifocal tumors (logistic regression test; odds ratio,

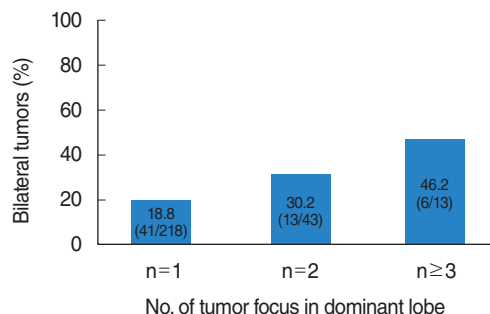


Fig. 2. Incidence of bilateral tumors depending on the number of tumor foci in a dominant lobe. Overall, the incidence of bilateral tumors in 274 patients was 22.7%. With 2 tumor foci in a dominant lobe, the incidence of synchronous tumor foci in the contralateral lobe was 30.2%. With 3 or more foci in a dominant lobe, the incidence was 46.2%. Fisher exact test, $P = 0.024$.

Table 4. Clinicopathological predictors of multifocality and bilaterality

Variable	Multifocal tumor		Bilateral tumor	
	No. (%)	<i>P</i> -value*	No. (%)	<i>P</i> -value*
Age (year)		0.522		0.719
<45	24/77 (31.2)		17/77 (22.1)	
≥45	76/200 (38.0)		46/200 (23.0)	
Sex		0.815		0.877
Male	18/52 (34.6)		10/52 (19.2)	
Female	82/225 (36.4)		53/225 (23.6)	
Size (cm) [†]		0.064		0.071
≤0.5	41/130 (31.5)		24/130 (18.5)	
>0.5	59/147 (40.1)		39/147 (26.5)	
Nodular hyperplasia		< 0.001 [‡]		< 0.001 [§]
Absent	52/190 (27.4)		30/190 (15.8)	
Present	48/87 (55.2)		33/87 (37.9)	
Thyroiditis		0.202		0.055
Absent	67/197 (34.0)		38/197 (19.3)	
Present	33/80 (41.2)		24/80 (31.2)	
No. of tumors in dominant lobe		-		0.038
1	-		41/218 (18.8)	
2	-		13/43 (30.2)	
3	-		5/12 (41.7)	
4	-		1/1 (100)	

*Logistic regression test was performed. [†]The largest tumor size of each case was selected for statistical analysis. [‡]Exp(B) was 3.396 (1.968–5.862). [§]Exp(B) was 0.314 (0.167–0.590). ^{||}Exp(B) was 1.688 (1.029–2.771).

3.396; $P < 0.001$) (Table 4). The incidence of multifocal tumors was higher in the cases with primary tumor > 0.5 cm (40.1%) than in cases with primary tumor ≤ 0.5 cm (31.5%), albeit without statistical significance (logistic regression test, $P = 0.064$).

For bilateral tumors, nodular hyperplasia and number of tumors in dominant lobe were the significant predictors. There was a tendency of increased bilateral tumors in cases with thyroiditis, although without statistical significance (Table 4).

DISCUSSION

PTCs often arise as multiple tumor foci in individual thyroid glands. The clonal origin of the multifocal PTCs has been investigated, but has not been completely settled. In the past, those multiple tumor foci were considered as the result of intraglandular metastasis of a single primary tumor via intraglandular lymphatics [3,5,11]. However, with the advance of modern molecular techniques, there have been reports that the multifocal PTCs are multiple synchronous primary tumors arising from independent clones [12-14].

Although the multifocal PTCs can be just synchronous tumors, not the metastatic foci of the largest primary tumor, they have been associated with increased risks of lymph node metastasis, distant metastasis, persistent local disease after initial treatment, and regional recurrence [1,3,4,6,7]. Those studies suggest more aggressive treatment for multifocal PTCs, i.e., total thyroidectomy, central neck dissection, or postoperative radioactive iodine treatment. Concordantly in this study, extrathyroid extension and lymph node metastasis were more frequent in multifocal PTMCs than in unifocal PTMCs.

However, multiple small tumor foci are often undiscovered with preoperative radiologic evaluation and incidentally diagnosed by surgical pathology. In this study, the sensitivity of preoperative US for multifocal tumors was only 42.7%. The sensitivity of preoperative US for bilateral tumors was 49.0%. Because the mean size of secondary tumor was significantly smaller (0.32 cm) than the largest primary tumor (0.63 cm, $P < 0.001$) (Table 2), those small tumors may be difficult to be diagnosed by routine US evaluation. The meticulous diagnosis of those small tumor less than 0.5 cm is not recommended according to the current American Thyroid Association guidelines [15]. Preoperatively undiagnosed tumor foci in contralateral thyroid lobes can cause postoperative remnant disease. Remnant disease not only may lead to an additional surgery, but also can be associated with regional and distant metastasis. In this study, the size of primary largest tumor was not associated with the multifocal tumors or bilateral tumors. Instead, unilateral multifocal PTMCs (number of unilateral tumor foci ≥ 2) have more than 30% chance of bilateral PTMCs (Fig. 2). Similarly, several studies have observed a higher rate of the contralateral tumors when multifocal disease is present in the ipsilateral lobe [16-18]. For unilateral multifocal PT-

MCs, the extent of surgery is still not determined clearly [15,19]. Although the prognosis of PTMCs is excellent [20,21], we suggest total thyroidectomy for preoperatively diagnosed multifocal PTMCs and completion thyroidectomy for multifocal PTMCs incidentally diagnosed after lobectomy, because of the high probability of contralateral tumor foci and the poor prognosis of multifocal PTCs. Though lobectomy alone may be performed, thorough and meticulous follow-up is necessary for those multifocal cases.

Additional to low sensitivity of preoperative radiologic tests for multifocal PTMCs and their undetermined prognostic significance, the predictors for those multifocal PTMCs are presently unknown. In this study, nodular hyperplasia was the only significant factor for multifocal PTMCs (Table 4), which is a novel finding to the best of our knowledge. As shown in Fig. 2, number of tumors in dominant lobe was the most significant clinicopathological predictor for bilateral PTMCs ($P = 0.038$; Exp (B) = 1.688) (Table 4). Well-verified predictive factors for multifocal PTMCs can decrease the risk of second operations.

In conclusion, in this study including 277 PTMC patients who underwent total thyroidectomy, the incidence of multifocal PTMC was 36.1%. The sensitivity of radiologic tests for multifocal and bilateral tumors were low (42.7% and 49.0%, retrospectively). The size of a primary PTMC was not associated with multifocality or bilaterality. In cases with multifocal tumors in the unilateral lobe, there were high chances of bilateral tumors. For which cases, more extensive surgery or more thorough follow-up may be warranted. Nodular hyperplasia was the meaningful predictor for both multifocality and bilaterality of PTMCs.

CONFLICT OF INTEREST

No potential conflict of interest relevant to this article was reported.

REFERENCES

1. Carcangiu ML, Zampi G, Rosai J. Papillary thyroid carcinoma: a study of its many morphologic expressions and clinical correlates. *Pathol Annu.* 1985;20 Pt 1:1-44.
2. Hawk WA, Hazard JB. The many appearances of papillary carcinoma of the thyroid. *Cleve Clin Q.* 1976 Winter;43(4):207-15.
3. Iida F, Yonekura M, Miyakawa M. Study of intraglandular dissemination of thyroid cancer. *Cancer.* 1969 Oct;24(4):764-71.
4. Katoh R, Sasaki J, Kurihara H, Suzuki K, Iida Y, Kawaoi A. Multiple thyroid involvement (intraglandular metastasis) in papillary thyroid carcinoma: a clinicopathologic study of 105 consecutive patients. *Cancer.* 1992 Sep;70(6):1585-90.
5. Russell WO, Ibanez ML, Clark RL, White EC. Thyroid carcinoma: classification, intraglandular dissemination, and clinicopathological study based upon whole organ sections of 80 glands. *Cancer.* 1963 Nov;16:1425-60.
6. Tscholl-Ducommun J, Hedinger CE. Papillary thyroid carcinomas:

- morphology and prognosis. *Virchows Arch A Pathol Anat Histol.* 1982; 396(1):19-39.
7. Mazzaferri EL, Jhiang SM. Long-term impact of initial surgical and medical therapy on papillary and follicular thyroid cancer. *Am J Med.* 1994 Nov;97(5):418-28.
 8. Iacobone M, Jansson S, Barczynski M, Goretzki P. Multifocal papillary thyroid carcinoma: A consensus report of the European Society of Endocrine Surgeons (ESES). *Langenbecks Arch Surg.* 2014 Feb; 399(2):141-54.
 9. Li X, Zhao C, Hu D, Yu Y, Gao J, Zhao W, et al. Hemithyroidectomy increases the risk of disease recurrence in patients with ipsilateral multifocal papillary thyroid carcinoma. *Oncol Lett.* 2013 Apr;5(4): 1412-6.
 10. Lin JD, Chao TC, Hsueh C, Kuo SF. High recurrent rate of multicentric papillary thyroid carcinoma. *Ann Surg Oncol.* 2009 Sep;16(9): 2609-16.
 11. Basser AG, Rundle FF. Stump recurrence and total thyroidectomy in papillary thyroid cancer. *Cancer.* 1956 Jul-Aug;9(4):692-7.
 12. Park SY, Park YJ, Lee YJ, Lee HS, Choi SH, Choe G, et al. Analysis of differential BRAF(V600E) mutational status in multifocal papillary thyroid carcinoma: evidence of independent clonal origin in distinct tumor foci. *Cancer.* 2006 Oct;107(8):1831-8.
 13. Giannini R, Ugolini C, Lupi C, Proietti A, Elisei R, Salvatore G, et al. The heterogeneous distribution of BRAF mutation supports the independent clonal origin of distinct tumor foci in multifocal papillary thyroid carcinoma. *J Clin Endocrinol Metab.* 2007 Sep;92(9):3511-6.
 14. Shattuck TM, Westra WH, Ladenson PW, Arnold A. Independent clonal origins of distinct tumor foci in multifocal papillary thyroid carcinoma. *N Engl J Med.* 2005 Jun;352(23):2406-12.
 15. American Thyroid Association (ATA) Guidelines Taskforce on Thyroid Nodules and Differentiated Thyroid Cancer, Cooper DS, Doherty GM, Haugen BR, Kloos RT, Lee SL, et al. Revised American Thyroid Association management guidelines for patients with thyroid nodules and differentiated thyroid cancer. *Thyroid.* 2009 Nov;19(11):1167-214.
 16. Connor MP, Wells D, Schmalbach CE. Variables predictive of bilateral occult papillary microcarcinoma following total thyroidectomy. *Otolaryngol Head Neck Surg.* 2011 Feb;144(2):210-5.
 17. Kim ES, Kim TY, Koh JM, Kim YI, Hong SJ, Kim WB, et al. Completion thyroidectomy in patients with thyroid cancer who initially underwent unilateral operation. *Clin Endocrinol (Oxf).* 2004 Jul;61(1): 145-8.
 18. Pasiaka JL, Thompson NW, McLeod MK, Burney RE, Macha M. The incidence of bilateral well-differentiated thyroid cancer found at completion thyroidectomy. *World J Surg.* 1992 Jul-Aug;16(4):711-6.
 19. Perros P, Boelaert K, Colley S, Evans C, Evans RM, Gerrard Ba G, et al. Guidelines for the management of thyroid cancer. *Clin Endocrinol (Oxf).* 2014 Jul;81 Suppl 1:1-122.
 20. Hay ID, Hutchinson ME, Gonzalez-Losada T, McIver B, Reinalda ME, Grant CS, et al. Papillary thyroid microcarcinoma: a study of 900 cases observed in a 60-year period. *Surgery.* 2008 Dec;144(6):980-7.
 21. Roti E, degli Uberti EC, Bondanelli M, Braverman LE. Thyroid papillary microcarcinoma: a descriptive and meta-analysis study. *Eur J Endocrinol.* 2008 Dec;159(6):659-73.