

Differential Diagnosis of Tumoral Lesions in the Spinal Canal in Patients Undergoing Hemodialysis

Keiji Wada, Yasuaki Murata, Yoshiharu Kato

Department of Orthopedic Surgery, Tokyo Women's Medical University, Tokyo, Japan

Study Design: A retrospective study.

Purpose: To clarify the features useful for the differential diagnosis of spinal canal tumoral lesions in patients undergoing hemodialysis.

Overview of Literature: Tumoral lesions in the spinal canal are rarely found in hemodialysis patients. Therefore, the differential diagnosis of tumoral lesions in the spinal canal in hemodialysis patients has been very difficult.

Methods: Spinal canal tumors in 17 patients undergoing hemodialysis or continuous ambulatory peritoneal dialysis were investigated. Histopathological analysis was conducted for all specimens obtained during surgery. The tumoral lesions were categorized into 3 groups on the basis of histopathology: spinal cord tumor, amyloidoma, and other. Patient medical history and diagnostic images of each group were reviewed.

Results: Eight of 17 cases were histopathologically diagnosed as spinal cord tumors and were neurinomas, 6 were amyloidomas, and 3 were classified as other. The rate of spinal cord tumors was 47.1% (8 of 17 cases), which revealed the most frequent lesion type. The rate of amyloidomas and other types was 35.3% (6 of 17 cases) and 17.6% (3 of 17 cases), respectively. In the amyloidoma group, the mean duration of hemodialysis (24.3 years) was longer than that of spinal cord tumors and other types (9.2 years and 8.6 years, respectively). All spinal cord tumors were intradural extramedullary, whereas all amyloidomas and other types were extradural.

Conclusions: The rate of each tumoral lesion, the duration of hemodialysis, and the tumoral localization are important features for the differential diagnosis of tumoral lesions in the spinal canal in hemodialysis patients.

Keywords: Hemodialysis; Tumoral lesions; Spinal canal; Differential diagnosis

Introduction

In hemodialysis (HD) patients, spinal disorders such as destructive spondyloarthropathy (DSA) and ligamentum flavum thickness (LFT) due to β_2 microglobulin (β_2M) amyloid deposition are currently well recognized [1-4]. Kuntz et al. [2] first reported that DSA is caused in patients receiving long-term HD by β_2M amyloid deposition to the intervertebral disc and facet joint. DSA

is characterized radiographically by intervertebral disc space narrowing with destruction of the adjacent vertebral endplates in the absence of osteophyte formation. Besides DSA, LFT is also observed in patients who undergo HD for around 20 years [5]. These spinal disorders sometimes compress the spinal canal, leading to myelopathy or radiculopathy.

Unlike DSA and LFT, tumoral lesions in the spinal canal are rarely found in HD patients. To our knowledge,

Received Aug 7, 2014; Revised Sep 24, 2014; Accepted Sep 25, 2014

Corresponding author: Keiji Wada

Department of Orthopedic Surgery, Tokyo Women's Medical University,
8-1 Kawada-cho, Shinjuku-ku, Tokyo 162-8666, Japan

Tel: +81-3-3353-8111, Fax: +81-3-3354-7360, E-mail: kejiwadajp@yahoo.co.jp

no cases of spinal cord tumors have been reported in HD patients. Furthermore, only a few cases of amyloidoma and pseudotumors in the spinal canal in long-term HD patients have been reported to date [6-10]. In addition, tumoral calcinosis has been reported as other HD-related tumoral lesions [11,12].

Despite these case reports, there have been no reports of a series of tumoral lesions in the spinal canal in HD patients. Therefore, the differential diagnosis of tumoral lesions in the spinal canal in HD patients has been very difficult in daily clinical practice.

In this study, we investigated the features of tumoral lesions in the spinal canal in HD patients that were useful for differential diagnosis. We retrospectively reviewed the medical history, radiology, and histopathology of 17 cases of tumoral lesions in the spinal canal in patients undergoing HD or continuous ambulatory peritoneal dialysis (CAPD).

All patients were informed that data regarding their case would be submitted for publication.

Materials and Methods

This study was approved by the institutional review board. The present study was conducted in 17 HD or CAPD patients who underwent surgery for tumoral lesions in the spinal canal at our hospital between 1994 and 2010. The duration of HD or CAPD and the cause of renal failure were reviewed. Plain radiographs and magnetic resonance imaging (MRI) on T1- and T2-weighted images were performed in all patients as well as gadolinium-enhanced images in some patients. MRI scans were evaluated with respect to signal intensity and localization in the spinal canal. For some patients, myelography and computed tomography after myelography (CTM) were performed. Histopathological analysis was conducted for all specimens obtained during surgery, which were stained with standard hematoxylin and eosin. Spinal cord tumors were diagnosed in this manner. Other tumoral lesions were further evaluated with Congo Red staining and immunostaining of β 2M to confirm the existence of β 2M amyloid. Based on the histopathological results, tumoral lesions were categorized into three groups: spinal cord tumor, amyloidoma, and other types. For each group, patient age at surgery, causes of HD or CAPD, duration of HD or CAPD, and MRI signal intensity were reviewed. The localization of the tumoral lesions

was evaluated using diagnostic imaging before surgery and confirmed during surgery. Patient age at surgery and duration of HD or CAPD in each group were compared using the Kruskal-Wallis test with significance as $p < 0.05$.

Results

A summary of the patients' data is shown in Table 1. There were 10 men and 7 women, with a mean age of 56.3 years (range, 42–69 years) at the time of surgery. Fifteen patients underwent HD, 1 was treated with CAPD, and 1 received a kidney transplant after 25 years of HD. The average duration of HD and CAPD was 14.4 years (range, 1–27 years) (Table 1). Causes of renal failure are shown in Table 1.

The characteristics of each disease group are shown in Table 2. Eight of 17 cases were histopathologically diagnosed as spinal cord tumors and were all neurinomas. Spinal cord tumors accounted for 47.1% (8 of 17 cases) of all tumoral lesions. The mean age of this group was 56.8 years (range, 42–69 years). The average duration of HD was 9.2 years (range, 1–22 years). The localization of tumors in the spinal canal was as follows: 1 thoracic (T), 2 thoraco-lumbar (T-L), and 5 lumbar (L), with cauda equina tumors being the most frequent. MRI showed low-signal intensity on T1-weighted images and high-signal intensity on T2-weighted images, both with gadolinium enhancement. Such imaging findings are typical of neurinomas [13]. All cases were diagnosed as intradural extramedullary tumors on MRI, myelography, or CTM before surgery, and confirmed during surgery.

Six of 17 cases (35.3%) were histopathologically diagnosed as amyloidomas; they were stained with Congo Red and were positive for β 2M immunostaining (Figs. 1, 2). The mean age of this group was 56.7 years (range, 53–60 years). It is interesting that the mean duration of HD was relatively long in this group at 24.3 years (range, 20–27 years). The locations of these tumoral lesions were: 3 cervical (C), 1 T, 1 T-L, and 1 L (Table 2). In three cases, MRI showed low-signal intensity on both T1- and T2-weighted images and three showed low-signal intensity on T1-weighted images, high-signal intensity on T2-weighted images, and gadolinium enhancement (Figs. 3, 4). Diagnostic images showed that these lesions were all extradural tumors. The localization was confirmed during surgery.

The other group comprised of three cases (17.6%).

Table 1. Patient data

Patient no.	Gender	Age (yr)	Histopathology	Duration of HD (yr)	Location	Cause of HD	Status of dialysis
1	Female	65	Neurinoma	1	L4	DM	HD
2	Male	69	Neurinoma	13	L4/5	Glumerulonephritis	HD
3	Male	51	Neurinoma	4	L1	Unknown	HD
4	Male	42	Neurinoma	10	T12/L1	Unknown	HD
5	Female	66	Neurinoma	22	L1	Unknown	HD
6	Male	46	Neurinoma	2	T1/2	Glumerulonephritis	HD
7	Female	62	Neurinoma	15	T12/L1	Hypertension	HD
8	Female	53	Neurinoma	7	L1/2	Glumerulonephritis	HD
9	Male	53	Amyloidoma	25	T10/11	Hypertension	RT
10	Female	58	Amyloidoma	27	L5	Glumerulonephritis	HD
11	Male	56	Amyloidoma	26	C5–7	Hypertension	HD
12	Male	58	Amyloidoma	20	C2–7	Glumerulonephritis	HD
13	Male	55	Amyloidoma	25	T12/L1	Unknown	HD
14	Male	60	Amyloidoma	23	C1–7	Glumerulonephritis	HD
15	Female	52	Tumoral calsinosis	4	C7–T4	Gout	CAPD
16	Female	60	Fibrous tissue	10	C7/T1	Nephrotic syndrome	HD
17	Male	54	Fibrous tissue	12	L3	Glumerulonephritis	HD
Mean	-	56.3	-	14.4	-	-	-

HD, hemodialysis; L, lumbar; DM, diabetes mellitus; T, thoracic; RT, renal transplantation; C, cervical; CAPD, continuous ambulatory peritoneal dialysis.

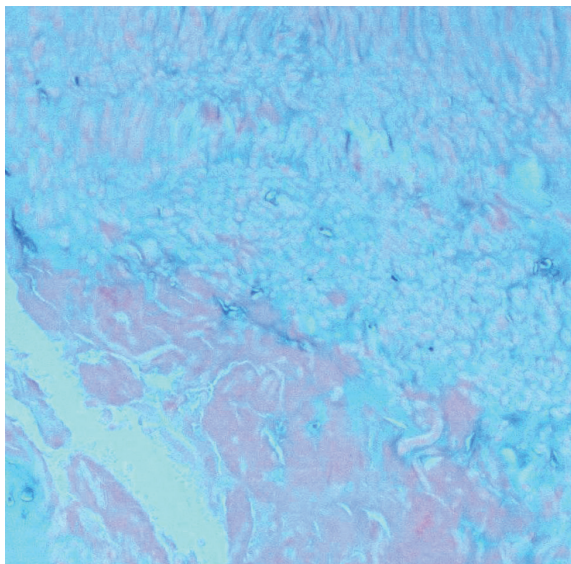


Fig. 1. Congo Red staining of case 13. Amyloid fibrils are densely stained with Congo Red ($\times 100$).

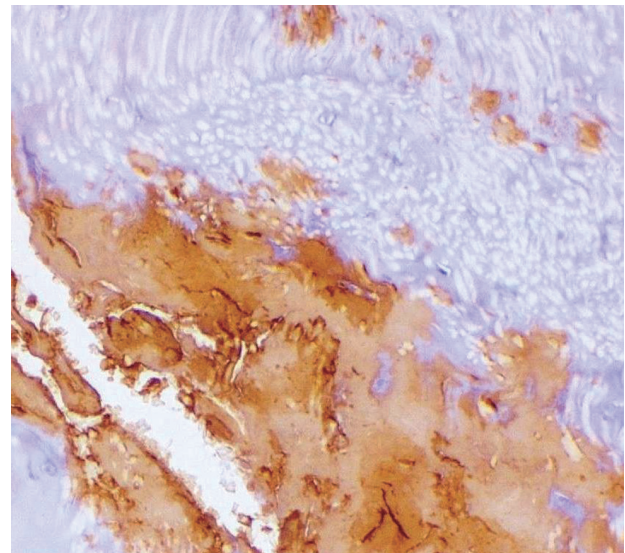


Fig. 2. Amyloid deposits are immunoreactive to anti- $\beta 2\text{M}$ antibody ($\times 100$).

The mean age of this group was 55.3 years (range, 52–60 years). One patient was treated with CAPD. The mean

duration of HD and CAPD was 8.7 years (range, 4–12 years). Two of these tumoral lesions occurred in the cer-

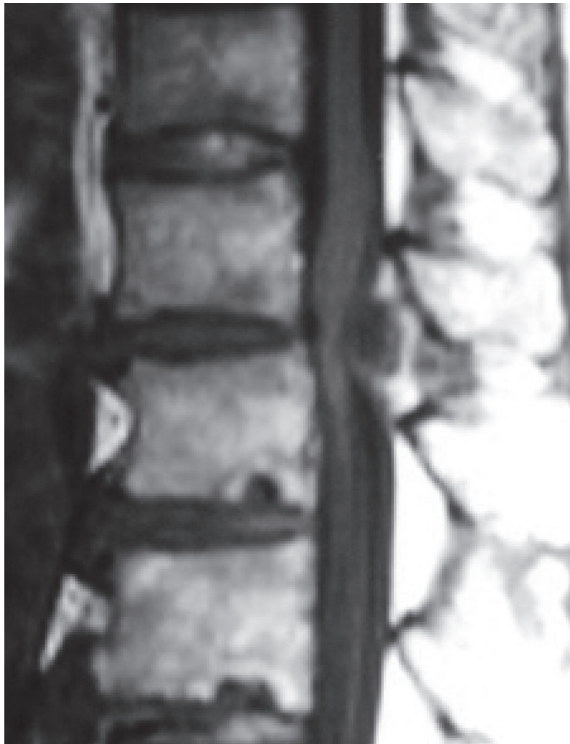

Fig. 3. Magnetic resonance imaging of T1-weighted image of a patient with amyloidoma (case 13).

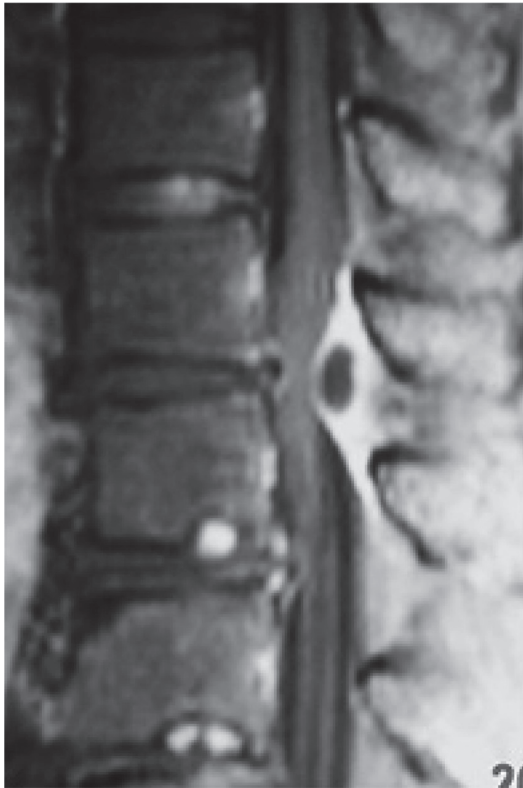

Fig. 4. Magnetic resonance imaging of gadolinium-enhanced T1-weighted image of a patient with amyloidoma (case 13).

vicothoracic (C-T) region and 1 in the L region (Table 2). Histopathologically, the patient treated with CAPD had tumoral calcinosis, and the other 2 had fibrous tissue with no evidence of β 2M amyloid deposition by Congo Red and β 2M immunostaining. MRI showed T1- and T2-weighted hypointense images in the case with tumoral calcinosis and T1-weighted hypointense and T2-weighted hyperintense images in the 2 cases with fibrous tissue. The tumoral calcinosis case was localized in C-T region, and the fibrous tissue cases in C-T and L regions (1 in each). These tumoral lesions were all determined to be extradural on diagnostic imaging and confirmed during surgery.

There was no significant difference in age at surgery among each group. However, the difference in HD duration among each group was statistically significant ($p < 0.05$).

Discussion

To date, a few cases of amyloidomas and pseudotumors in the spinal canal in long-term HD patients have been reported. However, there have been no reports of a series of tumoral lesions in the spinal canal in HD patients. Therefore, the differential diagnosis of tumoral lesions in the spinal canal in HD patients has been very difficult in daily clinical practice.

In this study, we found three major features of use in the diagnosis of tumoral lesions in the spinal canal in HD patients. First, the rate of each type of tumoral lesion is important. We categorized the lesions into 3 groups histopathologically: spinal cord tumor, amyloidoma, and other. Our histopathological study showed that 8 cases were spinal cord tumors, 6 were amyloidomas and 3 were other; thus the rates of these lesions were 47.1%, 35.3%, and 17.6%, respectively (Table 2). Although spinal cord tumors were the most frequent, the combined rate of amyloidomas and other (52.9%) was higher than that of spinal cord tumors alone. This result indicates that we should take into consideration that more than half of all spinal tumoral lesions in HD patients are not true spinal cord tumors.

The second important diagnostic feature is the duration of HD. There was a statistically significant difference in HD duration between each group ($p < 0.05$). The mean duration of HD was 24.3 years in the amyloidoma group, 9.2 years in the spinal cord tumor group, and 8.6 years in

Table 2. Summary of each tumoral lesion group

Group	Rate in all tumoral lesions (%)	Mean age (yr)	Mean duration of HD (yr)	Location
Spinal cord tumor	47.1 (8/17)	56.8 (42–69)	9.2 (1–22)	T:1, T–L:2, L:5 Intradural extramedullary
Amyloidoma	35.3 (6/17)	56.7 (53–60)	24.3 (20–27)	C:3, T:1, T–L:1, L:1 Extradural
Other	17.6 (3/17)	55.3 (52–60)	8.7 (4–12)	C–T:2, L:1 Extradural

Values are presented as % (number/total number) or mean±standard deviation (range). HD, hemodialysis; T, thoracic; L, lumbar; C, cervical.

the other group (Table 2). Therefore, the mean duration of HD was much longer in the amyloidoma group than in either of the other two groups. Only one patient in the spinal cord tumor group underwent HD for more than 20 years; all other spinal cord tumor cases underwent HD for 15 years or less (Table 2). Previous case reports describing patients with amyloidoma in the cervico-occipital area showed that they underwent HD for more than 20 years [6,9]. Our histopathological results indicate that spinal tumoral lesions in patients undergoing HD for more than 20 years are likely to be amyloidomas.

The third important diagnostic feature is the localization of the tumoral lesion in the spinal canal. Our results showed that all spinal cord tumors were neurinomas with intradural extramedullary locations (Table 2). In contrast, amyloidomas and other types were extradural. Previous reports showed that amyloidomas in the cervico-cranial area were extradural [6,9]. In addition, spinal tumoral calcinosis was also reported to be extradural [12]. However, to our knowledge there have been no reports of non-specific tumoral lesions such as our fibrous tissue cases. Our results indicated that extradural spinal tumoral lesions in HD patients were likely to be amyloidomas or other tumoral lesions. This result is significant for the diagnosis of these tumoral lesions, allowing us to determine whether they are extradural or intradural using MRI, myelography, or CTM before surgery. We also investigated the level of tumoral lesions in the spinal canal. Spinal cord tumors tend to localize in the cauda equina, though amyloidomas and other types localized at all spinal levels (Table 2). Conti et al. [13] reported that 68 of 123 (55.3%) neurinomas were localized in the lumbo-sacral area. Neurinomas in HD patients also tend to localize in this area, and this result may help with the differential

diagnosis. Contrary to previous reports, we did not show any amyloidoma cases occurring in the occipitocervical or upper cervical areas. The discrepancy in the results occurred because we only included spinal tumoral lesions that we were able to examine histopathologically. Although we have observed some spinal tumoral lesions in the occipitocervical or upper cervical areas, we have often found it difficult to collect specimens from these areas. Furthermore, MRI signal intensity was investigated for all tumoral lesions. Because all spinal cord tumors were neurinomas, MRI showed low-intensity T1-weighted, high-intensity T2-weighted images, and gadolinium enhancement, which are typical findings for neurinomas. On the other hand, no clear signal intensity characteristics were found for amyloidomas and other types.

Conclusions

We have shown the features of spinal tumoral lesions in HD patients. Three major features have been identified that may be useful for the differential diagnosis of spinal tumoral lesions in HD patients: rate of tumoral lesion, duration of HD, and localization. These findings provide significant information that can be used to treat HD patients with spinal tumoral lesions.

Conflict of Interest

No potential conflict of interest relevant to this article was reported.

References

1. Ito M, Abumi K, Takeda N, Satoh S, Hasegawa K,

- Kaneda K. Pathologic features of spinal disorders in patients treated with long-term hemodialysis. *Spine* 1998;23:2127-33.
2. Kuntz D, Naveau B, Bardin T, Drueke T, Treves R, Dryll A. Destructive spondylarthropathy in hemodialyzed patients. A new syndrome. *Arthritis Rheum* 1984;27:369-75.
 3. Maruyama H, Gejyo F, Arakawa M. Clinical studies of destructive spondyloarthropathy in long-term hemodialysis patients. *Nephron* 1992;61:37-44.
 4. Naito M, Ogata K, Nakamoto M, Goya T, Sugioka Y. Destructive spondylo-arthropathy during long-term haemodialysis. *J Bone Joint Surg Br* 1992;74:686-90.
 5. Nokura K, Koga H, Yamamoto H, et al. Dialysis-related spinal canal stenosis: a clinicopathological study on amyloid deposition and its AGE modification. *J Neurol Sci* 2000;178:114-23.
 6. Amoroso E, Vitale C, Silvestro A. Spinal-cord compression due to extradural amyloidosis of the cervico-occipital hinge, in a hemodialysed patient. A case report. *J Neurosurg Sci* 2001;45:120-4.
 7. Chassagne P, Dhib M, Aït Saïd L, et al. Spinal cord compression revealing a destructive arthropathy of the atlanto-occipital joint associated with beta-2 microglobulin amyloidosis in a haemodialysed patient. *Br J Rheumatol* 1992;31:427-8.
 8. Hatakeyama A, Fujinaga H, Togo T, et al. Remarkable improvement of activity by CAPD in a hemodialysis patient with a pseudotumor of the craniocervical junction. *Adv Perit Dial* 1992;8:116-9.
 9. Rousselin B, Helenon O, Zingraff J, et al. Pseudotumor of the craniocervical junction during long-term hemodialysis. *Arthritis Rheum* 1990;33:1567-73.
 10. Vignes J, Eimer S, Dupuy R, Donois E, Liguoro D. beta(2)-Microglobulin amyloidosis caused spinal cord compression in a long-term haemodialysis patient. *Spinal Cord* 2007;45:322-6.
 11. Carlson A, Yonas H, Turner P. Disorders of tumoral calcification of the spine: illustrative case study and review of the literature. *J Spinal Disord Tech* 2007;20:97-103.
 12. Durant D, Riley LH 3rd, Burger P, McCarthy E. Tumoral calcinosis of the spine: a study of 21 cases. *Spine* 2001;26:1673-9.
 13. Conti P, Pansini G, Mouchaty H, Capuano C, Conti R. Spinal neurinomas: retrospective analysis and long-term outcome of 179 consecutively operated cases and review of the literature. *Surg Neurol* 2004;61:34-43.