



Research Article

Effect of Carbamate Insecticide, Lannate, on the Gonads of Mice

Saleh A.M.T.*, Hijji A.M., Elel S.J. and Al Yacoub A.N.

Biology Department, Faculty of Applied Sciences, Umm Al-Qura University, Makka, 21955, PO Box 715, Kingdom of Saudi Arabia.

Abstract: The effect of the carbamate insecticide, lannate, on the gonads of mice was studied. Treating mice with lannate at a dose level of 10mg/kg body weight daily for 3-6 weeks had induced degenerative effects in the gonads, as follows, first in testis, a significant reduction in the diameter of the seminiferous tubules and germinal epithelial height. Histological examination of the testis showed that the seminiferous tubules were elongated and contained reduced spermatogenic cells. The number, of mature sperms was markedly reduced and after 3 weeks the sperm bundles were completely absent. On the other hand, the effect on the ovarian structure showed that, decrease in the number of secondary ovarian follicles and corpora lutea was recorded, while, the number of atretic follicles showed a significant increase. It is speculated that it may be resulted from the inhibition of RNA synthesis due to the effect of lannate.

Keywords: Testis, Ovary, Histological examination, Seminiferous tubules, Ovarian follicles, Corpora lutea.

1. Introduction

There is no doubt that chemical pesticides have many detrimental effects on the surrounding environment. In addition to their destroying effect on their targets, pesticides could pollute water resources, soil, air and food which have harmful effect on many beneficial insects and animals as well as direct effects on humans (McEwen and Stephenson, 1979). Thousands of new chemical formulations are used as pest controls (Matsumura *et al.*, 1979; Aciole *et al.*, 2014).

The effect of insecticides on male reproductive system was widely studied and many insecticides were proven to be potential risk factors that might cause male impotence (Espir *et al.*, 1970; Amr *et al.*, 1997; Polsky *et al.*, 2007). Insecticides were found to affect the testicular tissue of many laboratory animals (Shtenberg and Ozhovan, 1971; Dikshith and Datta, 1972a; Sakr and Salib, 1987; Mahgoub and El-Medany, 2001; Shalaby *et al.*, 2010). Furthermore, insecticides showed an inhibitory effect on the male reproductive function through changing the hormonal balance and decreasing the hormonal levels in mice (Smith *et al.*, 1972) and rats (Mahgoub and El-Medany, 2001).

Parallel research targeting the female reproductive system proved detrimental effects of insecticides.

Heinrichs *et al.*, (1971) showed that DDT induced persistent estrus syndrome when administered to neonatal rats. The carbamate insecticide was proven to cause reduction in the number of ovarian follicles in mice (Boseila *et al.*, 1981; Shanthalatha *et al.*, 2012). Sakr *et al.*, (1988) found a reduction in the number of ovarian follicles and an increase in follicular atresia in hamsters fed dimethoate.

The present study was designed to investigate the effect of the carbamate insecticide, lannate, on the gonads of male and female mice.

2. Material and Methods

Adult male and female mice weighing (25 – 30g) were used in the present work; they were maintained on a standard diet with a free access to water. Males were divided into two groups. The first group (15 mice) was given orally a daily dose of carbamate lannate (10mg/kg body weight) dissolved in distilled water for 3 weeks. All mice in the second group were considered as control animals. The treated animals, as well as the controls, were sacrificed by decapitation after 1, 2 and 3 weeks of treatment for histological examination. The testes of the males were removed and fixed in Bouin's fluid. They were subsequently embedded in paraffin wax, sectioned at 4gm and stained with haematoxylin

*Corresponding author:
E-mail: atsaleh@uqu.edu.sa.

and eosin. Seminiferous tubule diameter and germinal epithelial height were measured with an ocular micrometer.

In the second part of the experiment, the females were divided into three groups; animals in the first group (10 mice) were treated with carbamate lannate similarly as in the first male group. The second female group (10 mice) was given the same dose, but for 6 weeks, while the third group was considered as a control. All treated animals and controls were sacrificed by decapitation and their ovaries were removed. Histological standard procedures were applied (Newton and Hays, 1968) and different ovarian follicles and corpora lutea were counted in each ovary of the experimental groups. Student's "t-test" was used for statistical data analysis of both female and male animals.

3. Results

First, starting with the male experiment results, data in Table (1) show that treating mice with the insecticide, lannate had induced a significant decrease in the diameter of the seminiferous tubules ($P < 0.05$) after 2 weeks of treatment. This decrease became highly significant ($P < 0.01$) after 3 weeks of treatment. Likewise, there was a significant decrease in the epithelial height of the seminiferous tubules in the treated mice.

Table (1). Effect of carbamate lannate insecticide on the diameter and epithelial height of the seminiferous tubules of treated male mice.

| Experimental groups | Diameter in Um (Mean \pm S.D) | Epithelial height in Um (Mean \pm S.D) |
|-----------------------|---------------------------------|--|
| Control | 3.03 \pm 0.5 | 6.6 \pm 0.8 |
| One week treatment | 2.5 \pm 0.3 | 5.3 \pm 0.01 |
| Two weeks treatment | 2.1 \pm 0.1* | 4.6 \pm 0.7* |
| Three weeks Treatment | 1.01 \pm 0.4** | 2.3 \pm 0.5** |

(*) Significant at $P < 0.05$ in comparison with control;
 (**) Highly significant at $p < 0.01$

Histological examination of the testes of control mice showed that the seminiferous tubules were rounded and embedded in tightly packed connective tissue stroma (Fig. 1). The germinal epithelia was formed of normal spermatogenic layers represented by spermatogonia, primary and secondary spermatocytes, spermatids and sperms. The Lumina of the tubules were occupied by clumps of tightly-packed sperms which were oriented with their heads towards the germinal epithelium. Sertoli cells, the nutritive cells, rested on the basement membrane of the tubules (Fig. 2).

Testes of mice treated with lannate for one week showed that the seminiferous tubules were distended and irregularly shaped (Fig. 3). In these specimens, the

connective tissue stroma appeared loosely- packed around the seminiferous tubules. After 2 weeks of treatment, many vacuoles appeared in the seminiferous tubules opposite to the boundary tissue (Fig. 4) and the spermatogenic cells themselves showed marked cytoplasmic vacuolation (Fig. 5). The numbers of mature sperms and spermatogenic cells were clearly reduced, while the sperm bundles were completely absent. These changes were most apparent in animals treated with lannate for 3 weeks.

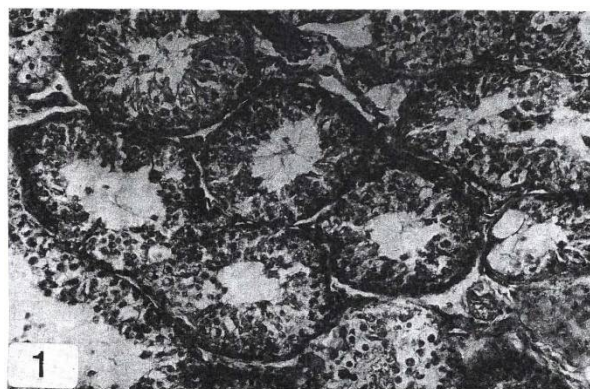

Fig. 1. A photomicrograph of a section in the testis of a control mouse (H & E; X 120).

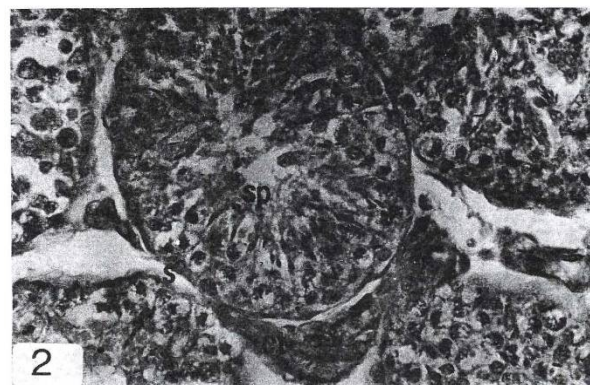


Fig. 2. Enlarged seminiferous tubule of a control mouse's testis showing all types of normal spermatogenic cells, CT: connective tissue stroma, SP: Sperm bundles, S: Sertoli cell, (H & E; X 300).

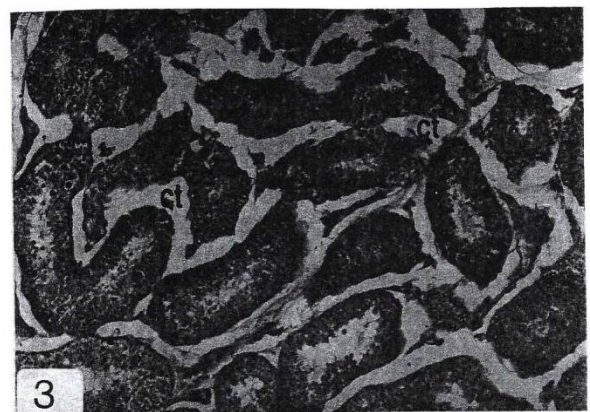


Fig. 3. A photomicrograph of a section in the testis of a mouse treated with lannate for one week, (H & E; X 100).

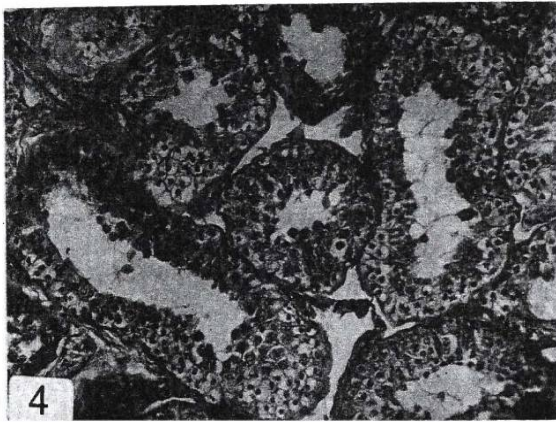


Fig. 4. A photomicrograph of a section in the testis of a mouse treated with lannate for two weeks, (H & E; X 120).

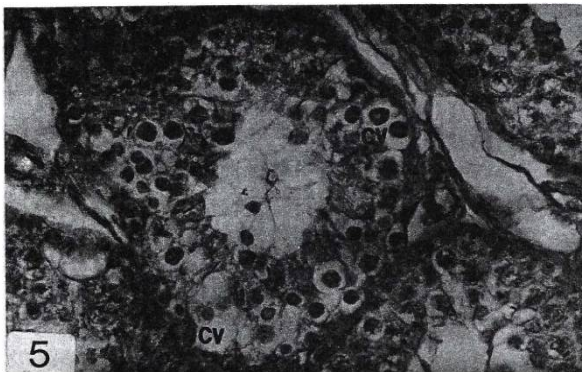


Fig. 5. Enlarged seminiferous tubule of the previous testis showing cytoplasmic vacuolation of the spermatogenic cells, (H&E; X 300).

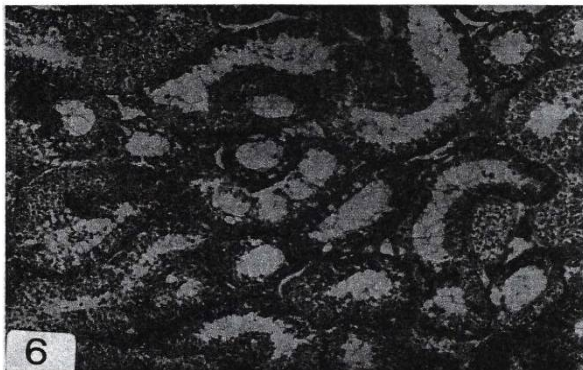

Fig. 6. A photomicrograph of a section in the testis of a mouse treated with lannate for 3 weeks showing reduction of spermatogenic cells, (H & E; 100).

Secondly, when considering the female part of this work, histological examination of the female mice showed that the ovaries of the controls contained different stages of developing and mature follicles (Fig. 7). Ovaries of animals treated with lannate for 3 weeks showed many degenerated follicles. Most of the oocytes became completely destroyed and only an empty ring of granulosa cells remained. Atretic changes were

apparent in a large number of follicles and included dissociation of cumulus granulosa cells from the oocytes, disruption of the zona pellucida, cellular debris in the antrum and pyknotic nuclei in both granulosa and theca cell layers (Fig. 8). After 6 weeks ovaries of the treated animals were found to be loaded with atretic follicles that occupy most of the stroma (Fig. 9).

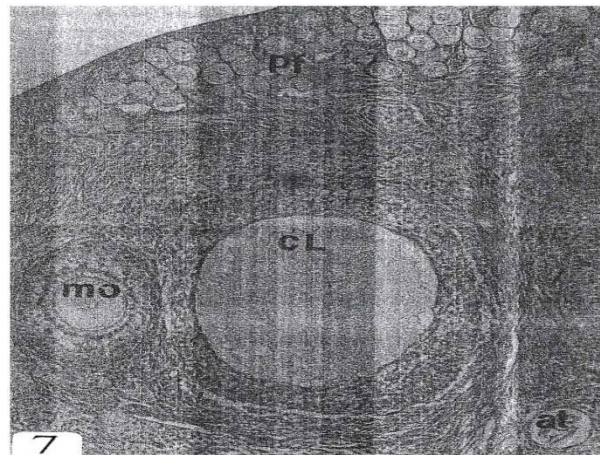


Fig. 7. Section in the ovary of a control mouse showing pr follicles (PF); mature ovum (mo), corpora luteum (CL) atretic follicle (at). (H&E. X 80).

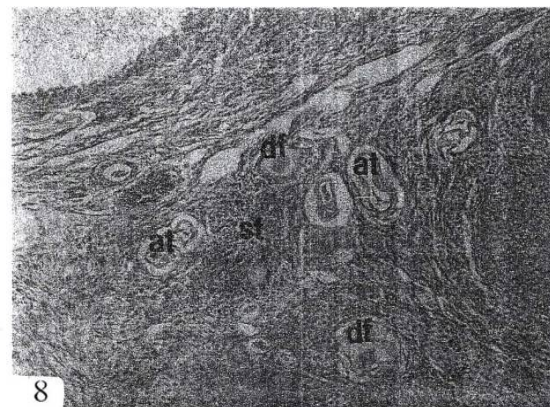


Fig. 8. Section in the ovary of a mouse treated with lannate for 3 weeks showing degenerated follicles (df) at different developmental stages, atretic follicles (at) and stroma (st), (H & E, X 80).




Fig. 9. Section in the ovary of a mouse 6 weeks post-treatment with lannate showing stroma (st) loaded with atretic follicles (at), (H & E, X 80).

Data in table (2) showed the changes in the number of ovarian follicles, atretic follicles and corpora lutea during the experiment. A significant reduction ($F < 0.05$) in the number of the secondary ovarian follicles was observed after 3 and 6 weeks. The number of mature follicles, as well as the corpora lutea, decreased after 6 weeks of treatment. On the other hand, the number of atretic follicles showed a significant increase. Being (8.3 ± 0.5) and (16 ± 0.3) after 3 and 6 weeks, respectively.

Table (2). Changes in the mean number of ovarian follicles and corpora lutea in female mice after treating with lannate.

| Group | Number of follicles (Mean \pm S.D) | | | | |
|-------------------|--------------------------------------|----------------|----------------|-----------------|----------------|
| | Primary | Secondary | Mature | Atretic | Corpora Lutea |
| Control | 19.3 \pm 1.2 | 6.8 \pm 0.6 | 5.3 \pm 0.9 | 3.1 \pm 0.6 | 7.3 \pm 0.5 |
| 3 weeks treatment | 16.6 \pm 0.4 | 2.1 \pm 0.4* | 4.5 \pm 0.7 | 8.3 \pm 0.5* | 4.2 \pm 0.9 |
| 6 weeks treatment | 18.5 \pm 1.0 | 1.6 \pm 0.7* | 2.1 \pm 0.5* | 16.0 \pm 0.3* | 3.1 \pm 0.4* |

(*) Significant ($P < 0.05$) in comparison with control.

4. Discussion

Results obtained in the present work revealed that treating mice with the insecticide lannate induced various histological changes in the testis which indicated inhibition of spermatogenesis. In addition, the measurements showed that the diameters of the seminiferous tubules, as well as the germinal epithelial height, were significantly reduced. These results are similar to those of Shtenberg and Orlova (1972) who found that oral treatment of rats with sevin decreased spermatogenesis, oogenesis and female fertility. Shtenberg *et al.*, (1973) reported that although carbaryl treatment of male rats at the dose level of 2mg/kg/day for 11-12 months did not alter testicular glucose 1,6-phosphate dehydrogenase or succinic dehydrogenase activities, sperm motility was decreased. Lannate was found to produce cytoplasmic vacuolation of the spermatogenic cells. Amarose and Czajka (1962) considered that the intercellular vacuolization found in the testis of mouse treated with deuterium oxide is due to degeneration and detachment of spermatogenic cells.

Several insecticides have been proved to injure and deteriorate the testes in laboratory animals. Dikshith and Datta (1972a) reported that intracellular injection of lindane produced hypertrophic and atrophic changes in the testis of rats, whereas, endrin did not induce atrophy of the testis. A single intraperitoneal injection of ethyl parathion, methyl parathion and DDT induced degenerative cellular changes in the seminiferous tubules of rats (Dikshith and Datta, 1972b). Such changes in spermatogenic cells included necrosis, karyopyknosis, vacuolation of the cytoplasm and formation of multinucleated giant cells.

Following oral treatment of mice with dichlorvos, significant testicular histopathology such as

degeneration of the seminiferous tubules and disappearance of spermatozoa and spermatids was observed (Krause and Homola, 1974). Feeding mature male quail with the chlorinated insecticide, Kepone had produced oedematous testes with highly dilated seminiferous tubules and reduced the germinal epithelium (Eroschenko and Wilson, 1975) El-Samannody *et al.*, (1986) found that injection of kepone into mice had resulted in decreased spermatogenic layers in the seminiferous tubules. Moussa and Abdel-Hafez (1982) reported that feeding guinea pigs with dimethoate induced degenerative effects in the testes. They added that dimethoate with the dose given and treatment periods applied, caused the inhibition of the normal function of the testis to a large extent, but did not destroy completely the germinal epithelium.

Feeding hamsters with dimethoate induced degenerative effects in the testis and the process of spermatogenesis was inhibited (Sakr and Salib, 1987).

Hormonal changes due to exposure to organophosphate and carbamate insecticides have been described. Among those changes were the increased levels of corticosterone and decreases in the ACTH and testosterone in the plasma of mammals (Fikes, 1990). The role played by androgenic steroids, such as testosterone, in spermatogenesis is well proved (Steinberger *et al.*, 1973). It is speculated that lannate reduced the level of testosterone in the blood of mice resulting in the inhibition of spermatogenesis observed in the present work.

Secondly, the results obtained in this work showed that treating mice with the carbamate insecticide, lannate, led to a significant decrease in the ovarian follicles as well as the appearance of many degenerated follicles. Moreover, the number of corpora lutea in the treated ovaries was also reduced and thus associated with an increase in the number of atretic follicles. These results are in agreement with the results of some investigators who reported that carbamate insecticides affected the ovary of experimental animals. Boseila *et al.*, (1981) reported that sevin induced degenerative effect and reduction in the number of rat ovarian follicles. Matter *et al.*, (1981) found similar changes in the rat ovaries when treated with carbaryl. El-Sayyad (1994) observed that the weight of the female reproductive system of mice was significantly decreased with thiodicarb treatment. He added that thiodicarb induced degeneration of the ovarian follicles and increase of atretic follicles. However, similar changes in the ovarian structure were induced by other insecticides (Heinrich *et al.*, 1971; Habib *et al.*, 1981; Sakr *et al.*, 1988)

On the other hand, it is well known that follicular atresia normally occurs in mammalian ovaries (Zuckerman and Weir, 1977). Peters *et al.*, (1975), reported that follicles grow sequentially and large follicles continue to grow until they ovulate or become atretic. It has been reported that estrogen is a primary

trigger of RNA synthesis in the cells of female sex organs (Ganong, 1977). The obvious decrease in the amount of estrogen at the time of ovulation (Ganong, 1977) can decrease RNA synthetic ability of follicular cells resulting in their atresia. The mode of action of carbamate insecticides was fully described in numerous reports. It was reported that carbamate metabolites can be incorporated into nucleic acids and blocked their synthesis (Aldridge and Magos, 1978).

Matter *et al.*, (1981) mentioned that follicular atresia may result from the inhibition of RNA synthesis in the follicular cells post carbaryl treatments. In the present work, it is speculated that the increase of atretic follicles in the treated animals may be resulted from inhibition of biosynthesis of RNA by lannate.

References

- [1]. Aciole, E.H., Guimarães, N.N., Silva, A.S., Amorim, E.M., Nunomura, S.M., Garcia, A.C., Cunha, K.S. and Rohde, C. (2014). Genetic toxicity of dillapiol and spinosad larvicides in somatic cells of *Drosophila melanogaster*. *Pest Manag Sci.*, 70(4):559-65.
- [2]. Aldridge, W.N. and L. Magos (1978). "Carbamates, thiocarbamates, dithiocarbamates", Luxembourg, Commission of the European Communities, Report No. V/F/1/78/75 EN.
- [3]. Amarose, A.P. and Czajka, D.M. (1962). Cytopathic effects of deuterium oxide on the male gonads of the mouse and dog. *Exp. Cell Res.*, 26: 43-61.
- [4]. Amr, M.M., Halim, Z.S. and Moussa, S.S. (1997). Psychiatric disorders among Egyptian pesticide applicators and formulators. *Environ. Res.*, 73(1-2):193-9.
- [5]. Boseila, A., El-Refaei, A., Matter, F., Farid, F. and Saleh, N. (1981). A histological and quantitative study on ovaries of rats treated with an insecticide, carbaryl. *Egypt. J. Histol.*, 4(2): 147 – 152.
- [6]. Dikshith, T.S. and Datta, K.K. (1972a). Effect of intratesticular injection of lindane and endrin on the testes of rat. *Acta Pharmacol. Toxicol.*, 31: 1-10.
- [7]. Dikshith, T.S. and Datta, K.K. (1972b). Pathologic changes induced by pesticides in the testes and liver of rats. *Exp. Pathol. (Jena)*, 7: 309-316.
- [8]. El-Samannody, F.A., Moussa, M.A., Abdel-Aal, M.E., Khater, M.O. and El-Assaby, M.A (1986). The effect of kepone injection on the testis of adult mice. *Egypt. J. Histol.*, 9: 251 – 254.
- [9]. El-Sayyad, H.I. (1994). Histological effects of thiosicarb on the reproductive system of the adult female mouse. *J. Egypt. Germ. Soc. Zool.*, 13(C) 47-65.
- [10]. Eroschenko, V.P. and Wilson, W.O. (1975). Cellular changes in the gonads, liver and adrenal glands of Japanese quail as affected by the insecticide, kepone. *Toxicol. Appl. Pharmacol.*, 31: 491-504.
- [11]. Espir, M.L., Hall, J.W., Shirreffs, J.G. and Stevens, D.L. (1970). Impotence in farm workers using toxic chemicals. *Br. Med. J.*, 1: 423-5.
- [12]. Fikes, J.D. (1990). Organophosphorus and carbamate insecticides. *Vet. Clin. North Am.: Small Anim Pract.*, 20: 353-367.
- [13]. Ganong, W.F. (1977). Review of Medical Physiology, Lange Medical Publications, Los Altos, California, PP. 330-337.
- [14]. Habib, M.K., Hashem, S.M., Farid, N., Shawky, N. and Gad, S. (1981). Effect of diazinon insecticide on the ovarian structure of rat. *Egypt. J. Histol.* 4 (1): 29 – 35.
- [15]. Heinrichs, W.L., Gellert, R.J., Bakke, J.L. and Lawrence, N.L. (1971). DDT administered to neonatal rats induces persistent estrus syndrome. *Science*, 173(3997):642-3.
- [16]. Krause, W. and Homola, S. (1974). Alterations of the seminiferous epithelium and the Leydig cells of the mouse testis after the application of dichlorvos (DDVP). *Bull. Environ. Contam. Toxicol.*, 11(5): 429-33.
- [17]. Mahgoub, A.A., El-Medany, A.H. (2001). Evaluation of chronic exposure of the male rat reproductive system to the insecticide methomyl. *Pharmacol. Res.*, 44(2):73-80.
- [18]. Matsumura, F., Boush, G.M. and Misato, T. (1979). Environmental toxicology of pesticides. Academic Press, New York.
- [19]. Matter, F.E., Farid, N.M. and Rageb, A.F. (2000). A histochemical study on the ovaries of rat treated with an insecticide. "Carbaryl". *Egypt. J. Histol.*, 4(1): 87-92.
- [20]. McEwen, F.L. and Stephenson, G.R. (1979). The use and significance of pesticides in the environment. John Wiley and Sons. New York.
- [21]. Moussa, T.A. and Abdel-Hafez, M.M. (1982). Effect of dimethoate on the guinea pig testis. *Egypt. J. Histol.*, 5: 181-189.
- [22]. Newton, D.W. and Hayes, R.I. (1968). Histological studies of ovaries in rats treated with hydroxybiphenyl tin acetate and triphenyltin chloride. *J. Econ. Entomol.* 61: 1668 – 1669.
- [23]. Peters, H., Byskov, A.G., Himelstein-Braw, R., Faber, M. (1975). Follicular growth: The basic event in the mouse and human ovary. *J. Reprod. Fertil.*, 45: 559 – 566.
- [24]. Polsky, J.Y., Aronson, K.J., Heaton, J.P., Adams, M.A. (2007). Pesticides and polychlorinated biphenyls as potential risk factors for erectile dysfunction. *J. Androl.*, 28(1):28-37.
- [25]. Sakr, S.A., El-Saadany, M.M. and Abdel-Galil, A.M. (1988). A histological study on the ovaries

- of hamsters fed with an insecticide, dimethoate. *J. Med. Res. Instit.*, 9(3): 57-65.
- [26]. Sakr, S.A. and Salib, E.A. (1987). Effect of dimethoate on spermatogenesis in hamster *Mesocricetus auratus*. *Alex. J. Agric. Res.*, 32: 491-499.
- [27]. Shalaby, M.A., El Zorba, H.Y. and Ziada, R.M. (2010). Reproductive toxicity of methomyl insecticide in male rats and protective effect of folic acid. *Food Chem. Toxicol.*, 48(11):3221-6.
- [28]. Shanthalatha, A., Madhuranath, B.N., Yajurvedi, H.N. (2012). Effect of methomyl formulation, a carbamate pesticide on ovarian follicular development and fertility in albino mice. *J. Environ. Biol.*, 33(1):33-7.
- [29]. Shtenberg, A.I. and Ozhovan, M.V. (1971). The Effect of low sevin doses on the reproductive function of animals in a number of generations. *Vopr. Pitan.*, 30: 42.
- [30]. Shtenberg, A.I., Orlova, N.V. and Torchinskii, A.M. (1973). Actions of pesticides of different chemical structures on the gonads and embryogenesis of experimental animals. *Gig. Sanit.*, 38: 16-20.
- [31]. Smith, M.T., Thomas, J.A., Smith, C.G., Mawhinney, M.G., Lloyd, J.W. (1972). Effects of DDT on radioactive uptake from testosterone-1,2-3 H by mouse prostate glands. *Toxicol. Appl. Pharmacol.*, 23(1): 159-164.
- [32]. Swartz, W.J. and Mall, G.M. (1989). Chlordecone-induced follicular toxicity in mouse ovaries. *Reprod. Toxicol.*, 3: 203 – 206.
- [33]. Zuckerman, L. and Weir, B.J. (1977). The ovary: general aspects. Academic Press, INC, New York, London, PP. 266 – 284.