

**Original Article****Study of diameter, length, tortuosity of splenic artery and its branches with its clinical implications**

Dr Bhivate Varsha R\*, Dr Suresh Roshan\*\*, Dr Kharate Rahul P\*\*\*, Dr Pandey Nivedita\*\*\*\*

\*Assistant Professor, Department of Anatomy, Terna Medical College, Nerul, Navi Mumbai, Maharashtra, India

\*\*Assistant Professor, Department of Anatomy, Shrinivas Institute of Medical Sciences and Research center, Makka, Manglore, Karnataka, India

\*\*\*Assistant Professor, Department of Anatomy, MGM Medical College, kamothe, Navi Mumbai, Maharashtra, India

\*\*\*\*Assistant Professor, Department of Anatomy, B.P.KOIRALA Institute of Health Sciences, Nepal

DOI: 10.5455/jrmds.2014244

**ABSTRACT**

**Background:** Systematic knowledge of the splenic arterial vasculature would provide greater safeguards in the design of the surgical techniques but there are surprisingly few studies on the subject. For this reason, we studied morphological anatomy of splenic artery.

**Aims:** To study morphological anatomy of splenic artery and clinical implications. The present study aims to report length, tortuosity, diameter of splenic artery and its branches.

**Material and Method:** The measurements were taken on 50 donated embalmed cadavers irrespective of the sex in the Department of Anatomy, MGM Medical College, Navi Mumbai, Maharashtra. The findings were noted after dissection. The study was carried out between May 2009 to December 2012.

**Results:** The mean length of splenic artery with tortuosity was 9.52 cm. The mean length of splenic artery without tortuosity was 12.76 cm. The splenic artery shows numerous tortuosities. The tortuosity decreases as the diameter increases. We found that superior polar branch was slender and thin can be easily damaged. To avoid this operation should start from inferior pole. The mean diameter of splenic artery was 5.144 mm that of superior ramus was 4.340 mm and inferior ramus was 3.760 mm. So we found weak inferior ramus supplying the lower pole of spleen. Due to which inferior pole was also supplied by additional branches.

**Conclusion:** Knowledge of splenic artery has the clinical significance in planning and conducting procedures such as partial or total splenectomy, splenic aneurysm, splenic embolisation, splenography, surgical and radiological procedures of upper abdominal region to avoid any complications.

**Key words:** splenic artery, length, diameter, tortuosity.

**INTRODUCTION**

Cadaveric study is not simply a method of learning a number of facts but the purpose of cadaveric study is to allow visualizing the living body in action so that one can appreciate the effect of injury or disease and recognize the abnormality from knowledge of the normal [1].

Surgery of the organs of the supracolic part of the abdomen requires a thorough knowledge of the vascular anatomy of this region. The vascular

anomalies are due to the aberration in the embryological development. Embryologically the splenic artery is one of the branches of the artery of foregut, i.e. celiac trunk. The splenic artery is remarkable for its tortuosity and because it is the largest branch of celiac trunk. It passes horizontally to the left, behind the stomach, along the upper border of the pancreas. Near the tail of the pancreas it enters in the lienorenal ligament and then divides into five or more terminal branches that enter the hilum of the spleen and spleen is supplied exclusively by splenic artery [2].

The anatomical variations of the splenic artery make it vulnerable to iatrogenic injury. Knowledge of the existing aberrations is important in planning and conducting surgical procedure [2].

Knowledge of variations concerning the CT is of extreme clinical importance in the areas of the Appleby procedure, laparoscopic surgery, and radiological procedures in the upper abdomen, and should be kept in mind by clinicians to avoid complications [3].

**MATERIALS AND METHODS**

The present study was conducted in Dept of Anatomy MGM Medical College, Kamothe, Navimumbai, Maharashtra during May 2009 to December 2012. The study was conducted on 50 formalin preserved cadavers irrespective of the sex. The study technique consisted of dissection, observations and measurement of various parameters. The study protocol was prepared in the form of a proforma.

In each cadaver, an incision was made in the midline from xiphoid process till the umbilicus and extended it till pubic symphysis encircling the umbilicus. A curved incision was made from anterior superior iliac spine to public symphysis. Skinflaps and superficial fascia were reflected by blunt dissection according to Cunningham [4]. The external oblique, internal oblique and transversus abdominis muscles were reflected. The rectus sheath, fascia transversalis and peritoneum were divided. Celiac trunk exposed. The tail of pancreas and lineorenal ligament identified and terminal branches of the splenic artery dissected and counted.

The course of splenic artery dissected along with pancreas. The diameter of splenic artery was measured 1cm before terminal branching. The diameters of superior and inferior were measured 5mm from the bifurcation. The length of the artery was measured by using measuring tape with tortuosity and after removing tortuosity by straitening the artery. Tortuosity was calculated by dividing length without tortuosity to length with tortuosity. Its variations about length, diameter was observed and noted down.

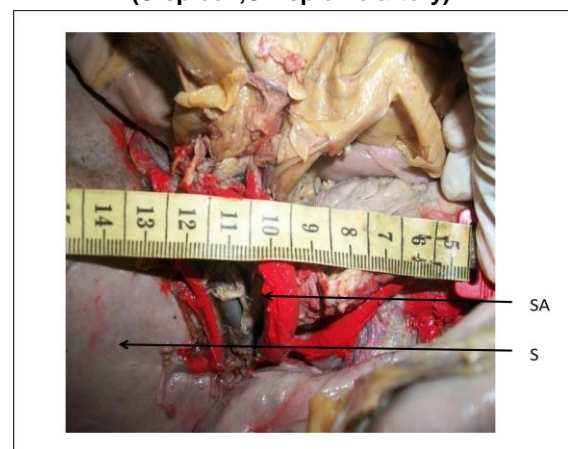
**RESULTS**

The variations of length, diameter and tortuosity of splenic artery were studied in 50 human cadavers. Below are the observations.

The splenic trunk divided into two primary branches in 84% and three primary branches 16%. Superior polar artery was present in 28%, inferior polar artery was present in 42% and in 12% both superior and inferior polar arteries were seen.

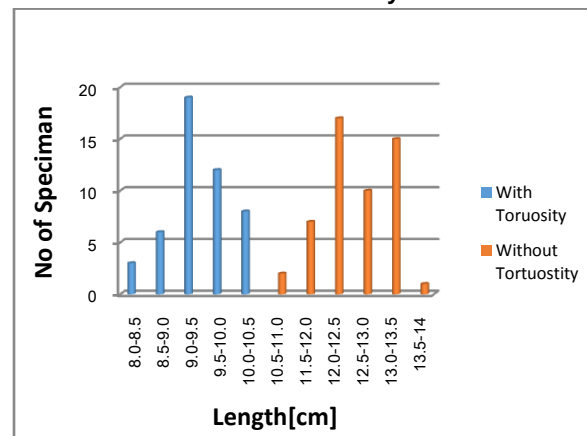
The mean distance of the point of division of splenic artery from the hilum was 4.368 cm, maximum 5.9cm and minimum was 3.1 cm. It is found that primary branches and polar branches of splenic artery divide the spleen into segments. In our study the segmental branches were 2 in 84% and 3 in 16%.

**Figure1: measurement of length of splenic artery (S-spleen,SA-splenic artery)**

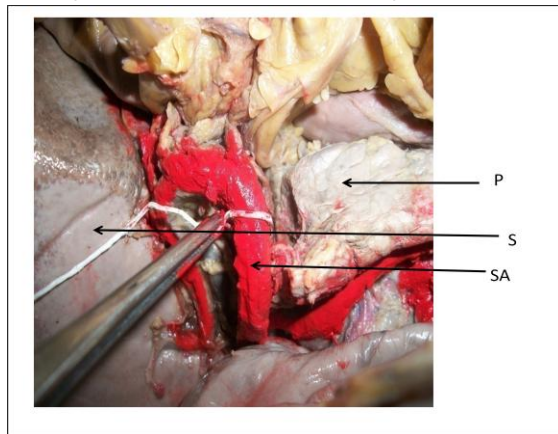


The mean length of splenic artery with tortuosity was 9.52 cm (fig1), maximum 10.7cm, minimum 8.2cm and 0.529 standard deviation. The mean length of splenic artery without tortuosity was 12.76 cm, maximum 14cm, minimum 11.5cm and standard deviation 0.598.

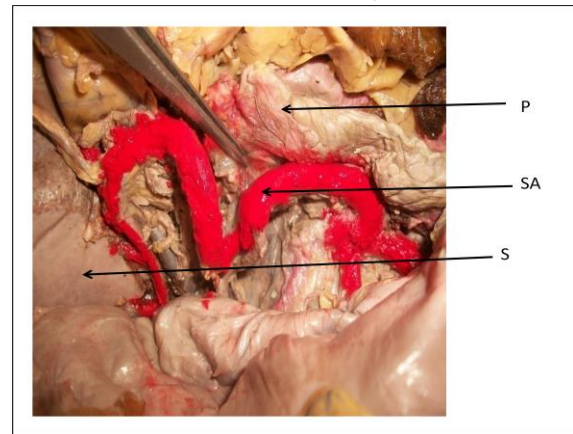
**Graph 1 – Length of splenic artery with and without tortuosity**



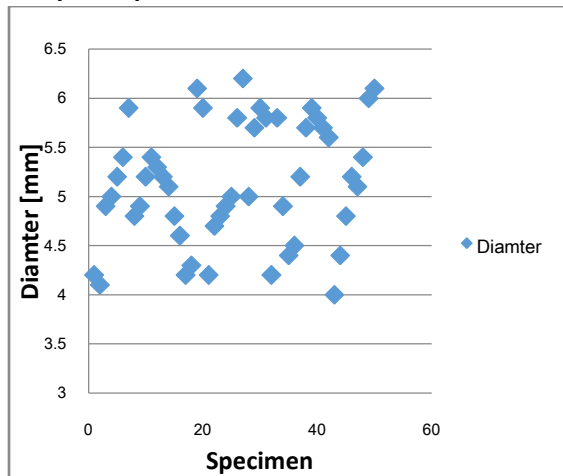
**Figure 2: measurement of diameter of splenic artery (S-spleen,SA-splenic artery,P-pancreas)**



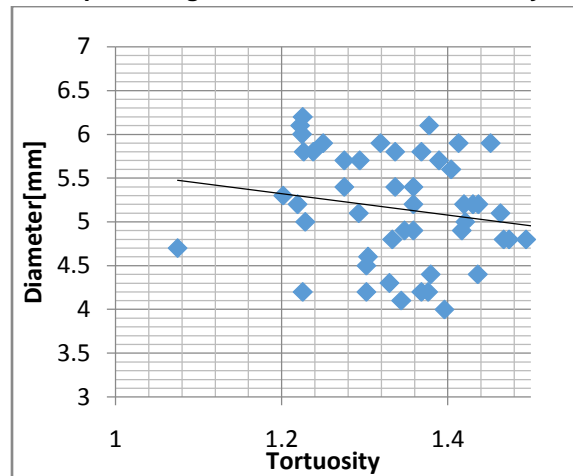
**Figure 3: Tortuous splenic artery (S-spleen,SA-splenic artery,P-pancreas)**



**Graph 2: splenic diameter observed in cadavers**



**Graph 3: Diagram of Diameter Vs Tortuosity.**



artery is 13cm (range 8-32cm) which was slightly more than what we found in our study [7].

In our study, we found that mean length with tortuosity was 9.52cm with standard deviation 0.59864 and standard variance 0.358. We also found mean length after straightening the artery i.e. mean length without tortuosity was 12.76 cm with standard deviation 0.52954 and standard variance 0.280.

In 1998 Libor, Machalek, Alzbeta, Holibkova, Jin Tuma and Dana Houserkova found that the average diameter of splenic artery was 5.144 mm, of superior ramus was  $4.2 \pm 0.7$  mm and the inferior ramus was  $3.7 \pm 0.8$  mm. The study was closely similar to our study in which the mean diameter of splenic artery was found to be 5.1440 mm with standard deviation 0.61484. The mean diameter of superior ramus was 4.3480 mm with standard deviation 0.62539 and the mean diameter of inferior ramus was found to be 3.3760 mm with standard deviation of 0.44472. As per this data we found that inferior ramus is smaller. This finding was also similar to study done by Machalek et al [8]. Malnar found that the diameter of splenic artery was  $0.61 \pm 0.05$  cm which was closer to our current study [9].

In 1995 Borley et al observed that the splenic artery has tortuous appearance throughout its course [10]. In 1995 Sylvester et al found that tortuosity increases with age [11]. In 2006, Daisy Sahni A et al found that splenic artery tortuosity was seen only in 10% adults, this characteristic tortuosity of splenic artery appear to be develop with age [12].

In medical imaging of spleen book by AMA de Schepper, Filip vahhoenache, it is given that the splenic artery tortuosity is unique among normal arteries. Often arteries become tortuous due to atherosclerotic disease or as a result of acting as a collateral vessels but a normal splenic artery can be very tortuous and may be characterized by loops and spiral. The artery becomes tortuous with age [7]. In our study, the splenic artery showed numerous tortuosities. As the diameter increases the tortuosity index was decreases.

We also found that superior polar branch was slender and thin can be easily damaged.

## CONCLUSION

Present study highlights the important findings that

The mean length of splenic artery with tortuosity was 9.52 cm and without tortuosity was 12.76 cm. The splenic artery shows numerous tortuosities. The tortuosity decreases as the diameter increases.

We found that superior polar branch was slender and thin can be easily damaged. To avoid this operation should start from inferior pole.

The mean diameter of splenic artery was 5.144 mm and mean distance of the point of division of splenic artery from the hilum was 4.308 cm.

Arterial variations and morphological anatomy should be taken care during the abdominal operative procedures. They may become important in patients undergoing diagnostic angiography for gastrointestinal bleeding, celiac compression syndrome or prior to operative procedure or transcatheter therapy [13].

During the surgical approach over the spleen and extrahepatic billiary apparatus it is imperative for the surgeon to take the note of such anomalous origin of splenic artery.

## REFERENCES

1. Romanes GJ, editor. Cunnigham's Manual of practical Anatomy: general introduction. vol1. 15<sup>th</sup> ed. Oxford: Oxford University Press; 1986. p. 17.
2. Pande SK, Bhattacharya S, Mishra RN, Shukla VK. Anatomical variations of splenic artery and its clinical implications. J Clinical Anatomy. 2004;17(6):497-502.
3. Padmi N, Verma S, Vollara VR. Anamolous branching pattern of celiac trunk. International journal of anatomical variations. 2008;1:8-9.
4. Romanes GJ,editor. Cunnigham's Manual of practical Anatomy: the abdominal cavity. vol3. 15<sup>th</sup> ed. Oxford: Oxford University Press; 1986.p. 122-35.
5. Jauregui E. Anatomy of splenic artery. Rev Fac Clin Med Univ Nac Cordoba. 1999;56:21-41.
6. Sindel M, Sarikcioglu L, Ceken K, Yilmaz S. The importance of anatomy of splenic artery and its branches in splenic artery embolisation. Folia Morphol (Warsz). 2001;60(4):333-6.
7. A. M. A. de Schepper, Filip Vanhoenacker. Medical Imaging of the Spleen, Springer – Verlag Berlin Heidelberg; 2000. p. 7-12.

8. Machalek L, Holibkova A, Tuma J, Houserkova D. The size of splenic hilus, diameter of splenic artery and its branches in humal spleen. *Acta Univ Palacki Olomuc Fac Med*. 1998;141:45-8.
9. Malnar D, Klasan GS, Miletic D, Bajek S, Vranie TS, Arbanas J et al. Properties of the celiac trunk – anatomical study. *Coll. Antropol* 2010;34(3): 917–21.
10. Borley NR, McFarlane JM, Ellis HA. Comparative study of tortuosity of the splenic artery. *Clin Anat*. 1995;8(3):219-21.
11. Sylvester PA, Stewart R, Ellis H. Tortuosity of the human splenic artery. *Clinical Anat*. 1995;8(3):214-8.
12. Daisy Sahni A, Indar Jit B, Gupta CN, Gupta DM, Harjeet E. Branches of splenic artery and splenic arterial segments. *Clinical Anat*. 2003;16(5):371-7.
13. Yalsin B, Kocabiyik N, Yazar F, Ozan H, Ozdogmus O. Variations of the branches of the celiac trunk. *J Gulhane Tip Dergisi* 2004;46:163-5.

---

**Corresponding Author:**

Dr. Bhivate Varsha R.  
Assistant Professor  
Department of Anatomy  
Terna Medical College  
Nerul, Navi Mumbai  
Maharashtra, India  
Email: [varshabhivate@gmail.com](mailto:varshabhivate@gmail.com)

Date of Submission: 30/08/2014

Date of Acceptance: 27/10/2014

---

**How to cite this article:** Bhivate VR, Suresh R, Kharate RP, Pandey N. Study of diameter, length, tortuosity of splenic artery and its branches with its clinical implications. *J Res Med Den Sci* 2014;2(4):22-6.

**Source of Support:** None

**Conflict of Interest:** None declared