



Research Article

Histopathological changes in Kidney of *Channa punctatus* (Bloch) under stress of Folidol

Satyapal Sulodia*, Surendra Singh and Harendra Nath Sharma¹

Department of Zoology, School of Life Sciences, Khandari Campus, Dr. B.R. Ambedkar University, Agra-282002, U.P., India.

¹Department of Environmental Toxicology, School of Life Sciences, Khandari Campus, Dr. B.R. Ambedkar University, Agra-282002, U.P., India.

Abstract: The concentration of pesticides is increasing day by day in the aquatic ecosystem. These concentrations are highest to limits; there is bioconcentration and bioaccumulation of these pesticides in the tissues and organ of fish which has a harmful effect on the human being when consumed by them. The effects of Folidol at 20 ppm sublethal doses were investigated on histopathology of kidney in full grown specimen of *Channa punctatus* (Bloch). Significant alterations were observed in kidney sections of treated fishes as compared to control group. These changes may be due to damage caused to the hepatic tissue.

Keywords: Snakehead fish, Histopathology, Organophosphate pesticides, Vacuolization, Hypertrophy.

1. Introduction

It is noticed that two-thirds of the illness in India relates to water pollution. Illnesses, such as typhoid, jaundice, cholera, dysentery, etc., are caused, mainly due to contaminated drinking water. With this background, an attempt is made for sustainable environmental safeguard measures for the water pollution problems. According, to a study by the National Institute of Oceanography, Goa, Mumbai cities discharge some 500 million cubic meters long, 700 meters wide and over 30,000 feet height additionally, 75 million cubic meters of industrial effluents are annually thrown into the sea.

Pesticide is physical, chemical or biological agent that will kill an undesirable plant or animal pest, the term 'pest' includes harmful, destructive or troublesome animals, plants or microorganisms. They have been widely used all over the world. Agrochemical, especially Organophosphorus compounds, chlorinated hydrocarbons are routinely employed as part of the integrated farming practice to protect crops and animals from insects, weeds and diseases. The Widespread use of pesticide in agriculture is now a worldwide phenomenon. Many of the pesticides currently in use are biocides that have high mammalian toxicity and necessitate considerable

precautions in their application. Several workers investigated the toxicity of organophosphate pesticides in fish.

Insecticides reach the body of man and animals through skin, respiratory system and gastrointestinal tract. An average person, who is not occupationally exposed to DDT and other pesticides, takes DDT into his or her body when eating DDT contaminated food items. All the food they eat and the air they breathe and some DDT is stored in body fat (3 ppm to 40 ppm or more). The Small amount of DDT may also be stored in other tissues. It may be stored in the liver, kidney and blood at concentrations of only 1% that in fat (Strobel *et al.*, 1981). The most questions are how a load of DDT (0.09 to 3.45 ppm) in our body fat, liver, kidneys, gonads, adrenal glands and blood affects our health. Autopsies have revealed fairly high levels of DDT and other pesticides in the fatty tissues of people who died from cancer, softening of the brain, high blood pressure stroke and cirrhosis of the liver (Miller, 1980). In a book entitled "Chemical carcinogenesis" Clayton (1962) suggested that the low levels of DDT and other pesticides that we carry in our bodies sooner or later may cause cancer. A study showed that human cancer could be caused by at least 1300 chemicals used in pesticides in the United States (Miller, 1980).

*Corresponding author:

E-mail: harendra_n_sharma@yahoo.com.

Some of the pesticides find on our fruit and vegetables, some are potentially harmful to our health. Aldicarb, Carbendazim and Vinclozolin are three pesticides that have appeared in the testing.

Aldicarb is a carbamate pesticide which acts as a more poison by disrupting nerve impulses. It is classified by the World Health Organization (WHO) as 'extremely hazardous'. It is dangerous to wild birds and animals, fish and other aquatic life etc.

Vinclozolin causes antiandrogenic ('anti-meleness') effects by binding to the natural male hormone receptors in the body. Since, 2004 Vinclozolin has been detected on imported celery, strawberries, Kiwi fruits, grapes and lettuce. Vinclozolin is harmful to fish and aquatic life, and there is a potential risk to breeding birds from the use of this pesticide.

Carbendazim is a suspected hormone disrupting chemical, as well as possible human carcinogen. Since 1998 to 2001 it has been found in 6 percent of supermarket apples, 23 percent of supermarket pears tested. It is harmful to fish, other aquatic life and harm to wildlife population.

The effect of chlorpyrifos exposure includes birth defects, nervous system disorders, and increased rates of leukemia and immune system abnormalities.

Children's fruit and vegetables such as apples, pears, oranges and carrots are regularly found to contain a cocktail of pesticide residues. 18 percent of apples contain chlorpyrifos and 23 percent of pears contain carbendazim, 21 percent contains dithiocarbamates and 35 percent contained multiple residues, 44 percent of carrots contained iprodione and 20 percent pendimethalin.

Studies have reported many cases of acute pesticides, poisoning from different part of the world. The people in contact with pesticides, such as farmers and farm workers, are much more likely to be poisoned by them. The observed DDT residues in the fat of the Indian population range from 12.6 ppm for Gujarat and 15.10 ppm for Delhi. There are several reports of mass poisoning of India. In 1957 pesticide poisoning in Kerala caused death of 102 people, in Indore, out of 35 cases of parathion poisoning reported during 1967-68, five died and December 1984 in a tragic accident in Bhopal, about 2500 people died due to Methyl isocyanate (MIC) poisoning and several thousand people are suffering from serious disease of eye, skin and lungs etc. In addition to, the loss of human life, a large number of cattle and birds also met the same fate. In fact, High DDT and other insecticides mortalities have been reported from the place where high residues of DDT were found in human milk. A study from Punjab University revealed high levels of DDT and BHC in breast milk samples.

The Effect of Organophosphorus compound on physiology of many non-target organisms, particularly fish, the symptom of Organophosphorus compound toxicity generally in value respiratory distress, increase

glycolytic rate, decreased oxidative metabolism, protein and RNA synthesis through a lot of work has been done on the pollutional characters and determinate effect of Organophosphorus compounds. Their indiscriminate use has increased the pollutional hazards, poisoning much danger to fish and other aquatic life.

Considerable interest has been shown in recent years in histopathological study while conducting sublethal tests on fish. Tissue changes in test organism exposed to a sublethal concentration of toxicant are a functional response of the organism which provides information on the nature of the toxicant. The liver is the primary organ for detoxication of organic xenobiotics. Wide varieties of insecticides and other toxic products tend and accumulate in high concentration within it and the organ suffers harmful effects.

The fish, *Channa punctatus* (Bloch) has been selected because it's very hardy and easily available throughout the year. The fish are commonly used in laboratory. It is commonly known as *Ophiocephalus punctatus* of the Day. Its importance as a food fish, especially by the high section of people in India, a number of workers have studied several aspects of toxic pollutant on the brain and muscles of fish, but in the present study histological and biochemical effects of Folidol on the liver and kidney of snakehead fish *C. punctatus* (Bloch).

The kidney is the main target organ as selected for study, which regulated all activities, while kidney is the chief excretory organ where the nitrogenous wastes are eliminated respectively.

2. Materials and Methods

A Full grown specimen of *Channa punctatus* (Bloch) also known as snakehead fish, measuring 12-15cm in length and 29-65gm in weight, were selected for the experiments. They were acclimatized at the room temperature in glass aquaria (75cm X 37.5cm X 37.5cm) containing 25 liters non-chlorinated tap water to assess the effect of folidol on the fish, *Channa punctatus* (Bloch).

The LC₅₀ value has been calculated as by log dose/probit regression line method (Finney, 1971). Kidney tissue was fixed in the Bouin's fluid. After washing and dehydration, the tissue was embedded in paraffin wax. The sections were cut at 5 microns and stained with haematoxylin and eosin (Humason, 1979). Sections were examined under trinocular research microscope and photomicrographs were taken at 400X.

3. Results and Discussion

The photomicrograph of the kidney (Plate 1 Control) showing the Collecting tubule (CT), Collecting duct (CD), Glomerulus (G), Blood vessels (Bv), Renal vein (Rv), Proximal segment (PS), Uriniferous tubule (UT), Tubular lumen (TL), Portion

of basement membrane (BM) were normal and systematically arranged.

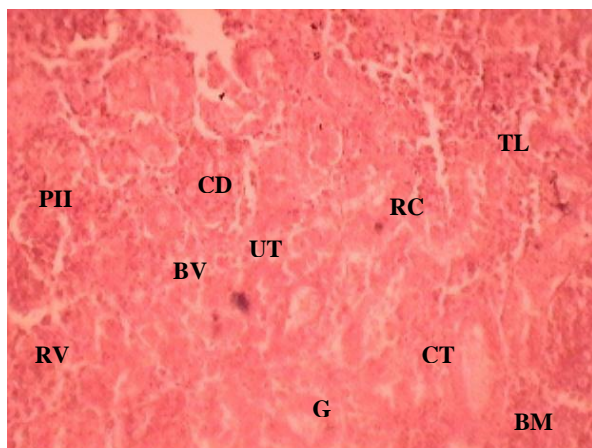


Plate 1. Section (T.S.) of the kidney of a control fish, showing Uriniferous tubule (UT), Collecting tubule (CT), Renal corpuscle (RC), Collecting duct (CD), Proximal segment (PS), Tubular lumen (TL), Glomerulus (G), Blood vessels (Bv), Renal vein (Rv), Portion of basement membrane (BM) are also normal and systematically arranged (20ppm; Control).

Vacuolization in the epithelial cells of renal tubules and hypertrophy of renal tubules were recorded at the concentration of 20 ppm at 1 day, (Plate 1). While after 15 days necrosis of epithelial cells of renal tubules (Plate 2), at 30 days were observed hypertrophy of renal epithelial cells (Plate 3).

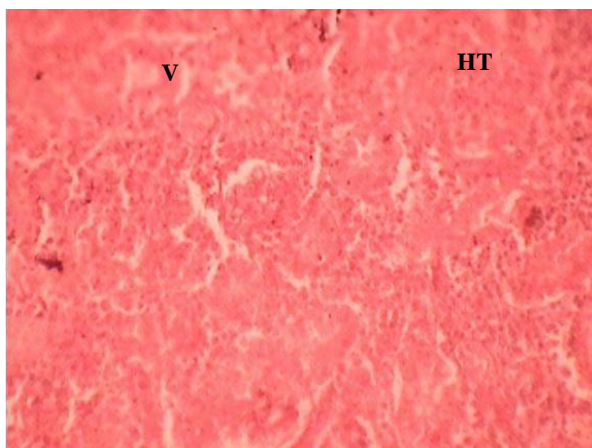


Plate 2. Section (T.S.) of the kidney of a treated fish showing vacuolization and hypertrophy in the epithelial cells of renal tubules (20ppm; 1 Day).

At 45 days were found vacuolization in the epithelial cells of renal tubules and pyknosis of uriniferous tubule cells (Plate 4). At 60 days were recorded hypertrophy of renal tubules and enlargement of epithelial cells. While at 75 days were recorded proximal tubule cells degeneration and hypertrophy of renal tubules (Plate 5) at 90 days were observed hypertrophy in proximal tubule and cells degeneration necrosis of glomerulus part and vacuolization in the

epithelial cells of renal tubules (Plate 6) while at a concentration of 40 ppm severe vacuolization in the epithelial cells of renal tubules and blood vessels ruptured (Plate 7) at 15 days were observed hypertrophy, pyknosis and necrosis epithelial cells of renal tubules (Plate 8).

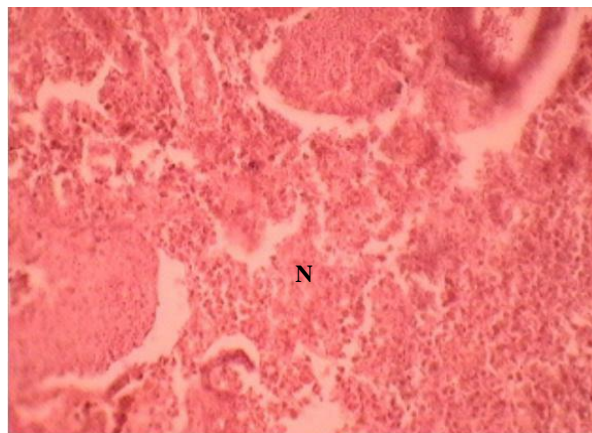


Plate 3. Section (T.S.) of the kidney of treated fish showing necrosis of epithelial cells of renal tubules (20ppm; 15 Days).

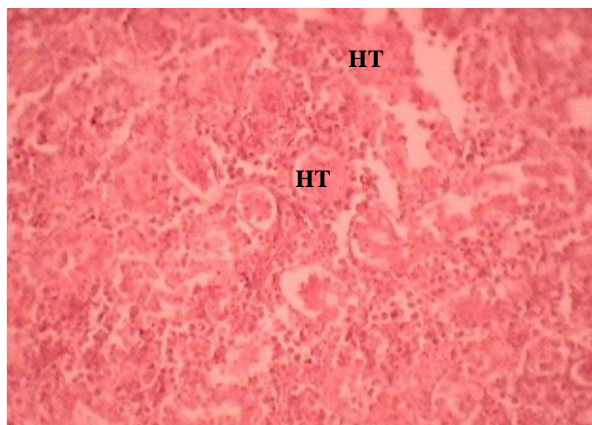


Plate 4. Section (T.S.) of the kidney of a treated fish showing hypertrophy of renal epithelial cells (20ppm; 30 Days).

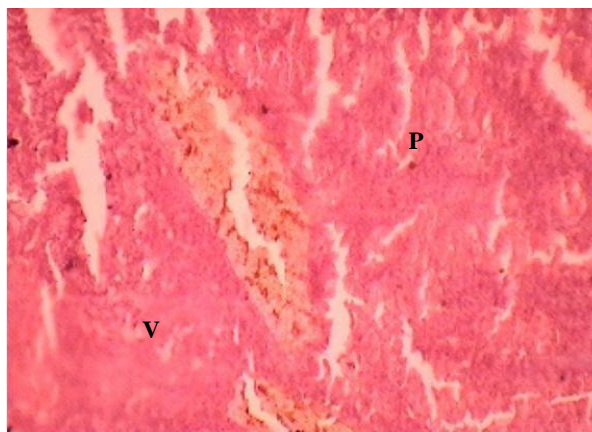


Plate 5. Section (T.S.) of the kidney of a treated fish showing vacuolization in the epithelial cells of renal tubules, pyknosis of uriniferous tubule cells (20ppm; 45 Days).

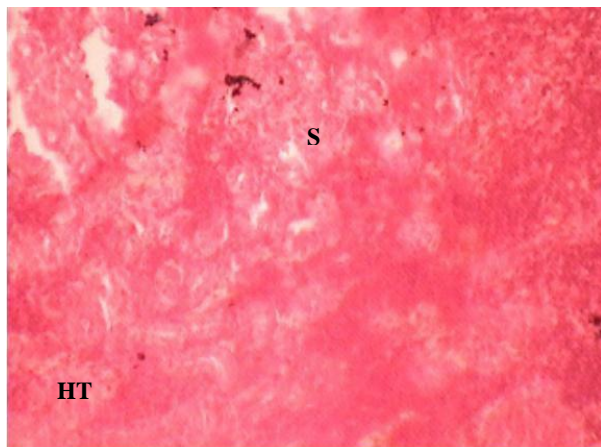


Plate 6. Section (T.S.) of the kidney of a treated fish showing hypertrophy in the proximal tubules and enlargement of epithelial cells (20ppm; 60 Days).

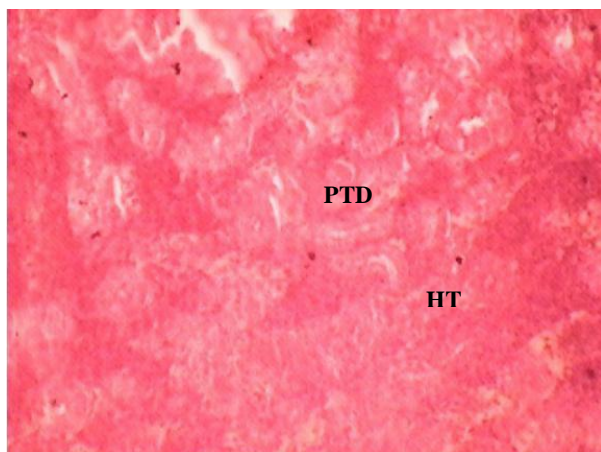


Plate 7. Section (T.S.) of the kidney of a treated fish showing proximal tubule cell degeneration and hypertrophy in proximal tubule (20ppm; 75 Days).

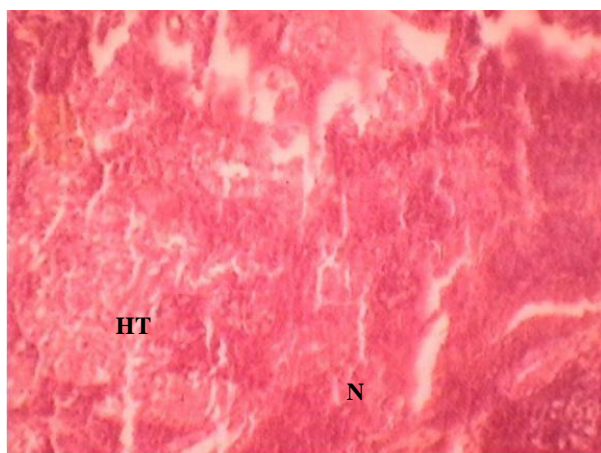


Plate 8. Section (T.S.) of the kidney of a treated fish showing hypertrophy and necrosis of glomerulus area (20ppm; 90 Days).

Considerable interest has been shown in recent year in histopathological study while conducting

sublethal test in fish. Tissue changed in test organism exposed to a sublethal concentration of toxicant, a functional response of organisms which provide information on the nature of the toxicant. Histopathological changes associated with pesticides in fish have been studied by many authors Narayan and Singh (1991); Mercy *et al.*, (2004).

Kidney plays a principal role in the excretion of metabolic wastes and in the regulation of extracellular fluid volume, electrolyte composition and acid base balance. Present observation shows tissue changes in kidney with histological abnormalities. Gupta and Dalela, (1987) reported histopathological changes in kidney of *Notopterus notopterus*, exhibiting degeneration and dissolution of epithelial cells of renal tubules, hypertrophy, vacuolization in the epithelial cells of renal tubules and necrosis following sublethal exposure to phenolic compounds. Similar changes were recorded in the present study with folidol.

Vacuolization and hypertrophy in the epithelial cells of renal tubules, necrosis of epithelial cells of renal tubules, pyknosis of uriniferous tubule cells, hypertrophy in proximal tubules, collecting duct necrosis, rupture of blood vessels causing haemorrhage and shrinkage of Bowman's capsule and glomerulus with folidol concentration were observed. Similar observations were reported by Csepai (1978) and Angelo *et al.*, (2005).

In a present histopathologically change in the anterior and posterior kidneys of snakehead fish *C. punctatus* (Bloch) induced by 20 ppm folidol on 45, 60, 75 and 90 days exposure showing in plates. Renal lesions consisted of minimal to mild multifocal acute tubular epithelial degeneration, karyolysis, and dilation or shrinkage of Bowman's capsule and glomerulus, necrosis of interstitial hematopoietic tissue, hypertrophy, pyknosis; observation of epithelial cell necrosis in the posterior kidney, may be correlated with uptake of folidol and rapid elimination phases. Present findings also support Thomson (1988); Wait *et al.*, (1990); and Banerjee and Bhattacharya (1994).

At the low concentration of folidol, hypertrophy, necrosis, enlargement of the cell sap and kidney proximal tubule cell degeneration, while at highest concentration of folidol recording histopathological abnormality in kidney such as collecting dust tubular necrosis, debris in tubular Lumina and nephritic lesions, including degenerative changes in tubular epithelium, cytoplasmic vacuolization, rupture of blood vessels causing haemorrhage and epithelium necrosis. Similarly, reported by King (1962); Mathur (1962); Mount and Putnicki (1966).

Nestle and Budd (1975) studied chronic oral exposure of rainbow trout, *Salmo gairdneri* to a polychlorinated biphenyl have shown that kidney histopathological changes, nephrotoxic lesions, including degenerative changes in tubular epithelium (Cytoplasmic vacuolation, hydropic degeneration)

tubular necrosis and necrosis of interstitial haematopoietic tissues.

DiMichele and Taylor (1978) studied histopathological and physiological responses of *Fundulus heteroclitus* exposure to naphthalene (Petroleum compound) and found that kidney necrosis of interstitial haematopoietic tissue, haemorrhage, hypertrophy and necrosis of interstitial haematopoietic tissue.

References

- [1]. Paolini, A., Berti, M., D'Angelo, A., Scortichini, G. and Giansante, C. (2005). Use of histopathological indicators on chub (*Leuciscus cephalus*) and brown trout (*Salmo trutta fario*) in evaluating river environments. *Vet. Ital.*, 41(3): 189-198.
- [2]. Banerjee, S., and Bhattacharya, S. (1994). Histopathology of kidney of *Channa punctatus* exposed to chronic nonlethal level of Elsan, mercury, and ammonia. *Ecotoxicol. Environ. Saf.*, 29(3): 265-275.
- [3]. Csepai, F. (1978). Histological detectable dystrophies in the carps kidney exposed to chronic effect of some pesticides. *Magy. Allatorv. Lapja*, 33: 55-58.
- [4]. DiMichele, L. and M.H. Taylor (1978). Histopathological and physiological responses of *Fundulus heteroclitus* to naphthalene exposure. *J. Fish Res. Board Can.*, 35: 1060-1066.
- [5]. Gupta, A.K. and R.C. Dalela (1987). Kidney damage in *Notopterus notopterus* (Pallus) following exposure to phenolic compounds. *J. Environ. Biol.*, 8: 167-172.
- [6]. King, S.F. (1962). Some effects of DDT on the guppy and the brown trout. *Spec. Scient. Rep. U.S. Fish Wildl. Serv.*, Fisheries No. 399. 22 pp.
- [7]. Mathur, D.S. (1962). Histological changes in the liver of certain fishes induced dieldrin. *Sci. Cult.*, 31: 258-259.
- [8]. Mercy, T.V.A., B. Madhusoodana Kurup and J.R. Nair (2004). Pesticide induced histological change in juveniles of *Channa marulius*. Fourth Ind. Fisheries Forum, pp. 96-101.
- [9]. Narayan, A.S. and B.B. Singh (1991). Histopathological lesion in *Heteropneustes fossilis* subjected to acute thiodon toxicity. *Acta Hydrochem. Hydrobiol.*, 19: 235-243.
- [10]. Nestle, H. and J. Budd (1975). Chronic oral exposure of rainbow trout (*Salmo gairdneri*) to a polychlorinated biphenyl (Aroclor 1254): pathological effects. *Can. J. Comp. Med.*, 39: 208-215.
- [11]. Waite, D.T, S.R. Joshi, H. Sommerstad, G. Wobeser and A.A. Gajadhar (1990). A toxicological examination of whitefish (*Coregonus clupeaformis*) and northern pike (*Esox lucius*) exposed to uranium mine tailings. *Arch. Environ. Contam. Toxicol.*, 19(4): 578-582.