

A Case of Multi-Ulcerative Abscess Due to *Brucella abortus* in Kerman, South East of Iran

Naser Shahabi Nejad¹, MD;
Nasim Eftekhari², PhD;
Shayan Shahabi Nejad³, MSc

¹Department of Infectious Diseases, Seyyed-al-Shohada Hospital, Kerman, Iran;

²Department of Microbiology, Kerman Branch, Islamic Azad University, Kerman, Iran;

³Faculty of Medicine, University of Debrecen, Hungary

Correspondence:

Nasim Eftekhari, PhD;
No: 5, 6th floor, Arad Building, Ferdowsi Blvd., Kerman, Iran
Tel: +98 913 248 3392
Fax: +98 34 32113978
Email: Nasim.eftekhari180@gmail.com
Received: 6 August 2017
Revised: 7 October 2017
Accepted: 15 October 2017

What's Known

- Brucellosis, still an endemic infection in Iran, has various clinical manifestations.
- Skin and soft tissue involvement is an unusual presenting feature of *Brucella* infection.

What's New

- Few studies have evaluated cutaneous lesions associated with brucellosis. Due to its nonspecific and rarity, brucellosis may be misdiagnosed with other pyogenic bacterial infections.
- We present an uncommon case, in which *Brucella abortus* was isolated from a multi-ulcerative abscess at the one-third proximal portion of the left leg of a young shepherd.

Abstract

Cutaneous involvement is an unusual complication in brucellosis that has been reported to range between 0.4% and 17%. We here introduce a 40-year-old shepherd, who presented with two ulcerative abscesses in his lower left leg. Cultivation of the abscess aspirate was positive for *Brucella abortus*. The first titer of his serological test was 1/160, which subsequently rose to 1/640. In countries like Iran where brucellosis is still endemic, it is important to take *Brucella* species into account among other pyogenic bacteria as a causative agent of cutaneous abscesses.

Please cite this article as: Shahabi Nejad N, Eftekhari N, Shahabi Nejad S. A Case of Multi-Ulcerative Abscess Due to *Brucella abortus* in Kerman, South East of Iran. Iran J Med Sci. 2018;43(5):546-549.

Keywords • *Brucella abortus* • Brucellosis • Ulcerative abscess • Iran

Introduction

Malta fever, caused by *Brucella* species, is a zoonotic infection. In some cases, it occurs as an occupational disease.^{1,2} Brucellosis is still known as endemic infection in the Persian Gulf countries and some other parts of the world.^{1,2} After entering the body, *Brucella* becomes sequestered within the cells of the reticuloendothelial system.^{1,3}

The clinical manifestation of brucellosis is highly variable,^{2,4} with atypical presentations or unusual complications due to brucellosis having been described in some investigations.⁵⁻⁸ The rate of cutaneous involvement is reported to range from 0.4% to 17.0%.^{3,9}

A variety of brucellosis skin lesions have been reported from rashes (25%); nodules, papules, and erythema nodosum (25%); eczematous lesions (12.5%); psoriasis forms (12.5%), petechiae; purpura; and others.^{4,10}

In this report, we present an uncommon case, in which *Brucella abortus* was isolated from a multi-ulcerative abscess in the lower leg of a young shepherd.

Case Presentation

A 40-year-old man was admitted to the private office of an infectious disease specialist. He complained of 2 ulcerative abscesses of 5 months' duration in his left lower leg. The abscesses were soft and painless with mild bleeding (figure 1). The patient was a shepherd in the suburbs of Kerman, in the southeast of Iran. Like his family, he usually consumed cheese prepared from raw milk. His sister had recovered from brucellosis 1 year previously. Four months before his first admission, the patient had noticed edema in the lower part of his leg. Since he did not suffer from any

inconvenient symptoms of brucellosis infection such as fever and muscle pain, he was not overconcerned. Initially, cutaneous involvement manifested itself as 2 small vesicles, which gradually grew into 2 large ulcerative abscesses. At the time of his first admission, the patient had no apparent brucellosis symptoms like fever and weakness, but he complained of low-grade fatigue and muscles discomfort. It was the first time he had visited a specialist doctor. The patient complained that the abscesses had become progressively painful. Both of the pictures, before and after treatment, were taken and enclosed in the present paper with his permission.

A medical laboratory analysis, conducted 5 days prior to his referral to our hospital (Seyyed-al-Shohada Hospital), showed a normal white blood cell count and an elevated erythrocyte sedimentation rate of 38 mm/h. The standard agglutination test (SAT) was positive at a titer of 1/160. He was, therefore, referred to us with a most probable diagnosis of brucellosis.

All clinical serological tests were repeated in our hospital. The SAT showed a rise to a titer of 1/640. Before making an incision in the abscesses, we sent 2 aspirates of the abscesses to a specialist medical microbiology laboratory for the isolation of *Brucella* and/or other infectious microorganisms.

The samples were mucoid and intensively purulent. For the enrichment process, the samples were first inoculated in the biphasic Thioglycollate Fluid (CONDA, Spain) and the BACTEC medium (Becton & Dickinson, Ireland) (figures 2 and 3). After 2 days, both enriched samples were subcultured on the sheep's blood agar (Biolife, Italy). No colony appeared after 48 hours. Six days later, *Brucella abortus* was isolated from both samples in the sheep's blood agar [35°C, 5–10% CO₂] (figure 4). The genus of the isolates was identified by Gram staining, catalase, oxidase, and urease (CONDA Spain) tests (figure 5).¹ The species was confirmed by the agglutination test against specific antisera (Bahar Afshan, Iran).

After incision and drainage, the patient was treated with streptomycin (750 mg/d) plus doxycycline (100 mg/12 h). Two weeks later, the medication was changed to rifampin and doxycycline for 12 weeks. The ulcerative pyogenic lesions were resolved in about 3 weeks (figure 6).

In the last admission of the patient to the lab, the importance of the disease was fully explained to him and written informed consent for this case report was obtained.

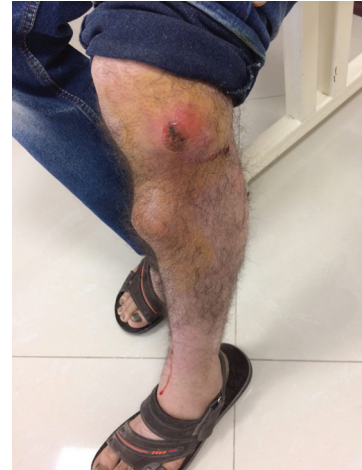

Figure 1: Two ulcerative abscesses in the lower part of the leg appeared 4 months after the appearance of the infection.




Figure 2: Positive culture result in the Thioglycollate Fluid appeared after 6 days.




Figure 3: Positive culture result in the BACTEC medium appeared with fine turbidity.

Discussion

Official statistics show that each year about half a million new cases of human brucellosis occur in the world.² This zoonotic disease is

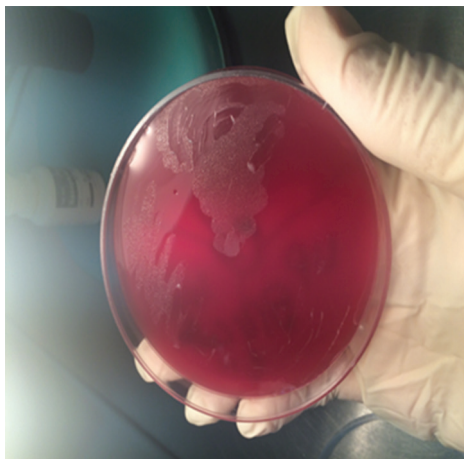


Figure 4: After 6 days, the first positive subculture result appeared on the sheep's blood agar with translucent pinpoint and non-hemolytic colonies.




Figure 5: Critical/identical test for *Brucella abortus* positive rapid (<30 min) urease test.

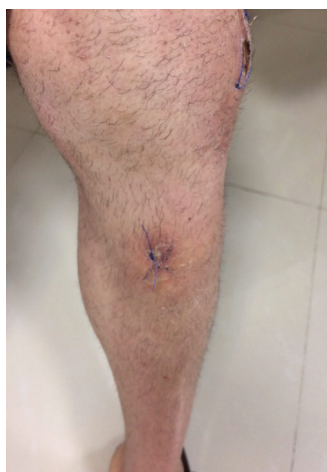

Figure 6: Relative resolution of the lesions 20 days after the incision and drainage of the abscesses together with therapeutic management.

predominantly transmitted to humans through the ingestion of unpasteurized milk and dairy.² It can also be transmitted by direct contact with fluids

and carcasses of infected animals.^{2,11} The clinical features of brucellosis are nonspecific; the most commonly reported symptoms are fever, fatigue, malaise, chills, sweats, headaches, anorexia, and weight loss.²

The cutaneous manifestation of brucellosis was first described in 1940.⁹ Skin and soft tissue involvement is an unusual presenting feature of *Brucella* infection, so there is a paucity of research evaluating cutaneous lesions associated with brucellosis.³ In a review article, Korkmaz (2016) reported that the rate of cutaneous brucellosis was 13.6% in the study by Akcali et al. (2007) and 5.7% in the study by Metin et al. (2001).³ Additionally, 7.14% of all the cutaneous manifestations of brucellosis in that review article were abscess formations.

Various kinds of cutaneous infections are caused by direct inoculation, hypersensitivity phenomenon, deposition of immune complex, and skin/soft tissue invasion via the hematogenous route.³ Because of its nonspecific and rarity, brucellosis may be misdiagnosed with other bacterial infections.³ Resendiz-Sanchez⁵ (2009) reported an unusual case of an abscess on the left foot of a 3-year-old infant due to *Brucella melitensis* and concluded that although the child had been drinking unpasteurized milk since 1 year old, the original lesion must have become contaminated by infected animal material. With respect to our patient, we have no conclusive evidence that the abscess was the result of drinking unpasteurized milk or direct inoculation of the *Brucella* bacterium.

As an unusual form of occupational (farmer) brucellosis, panniculitis as the initial manifestation was reported in a 38-year-old male shepherd by Tanyel et al.¹¹ in Turkey. Paton et al.¹² (2001) reported a visceral abscess due to *Brucella suis* in a 78-year-old retired pig farmer in Singapore. Leong et al.² (2015) in Malaysia reported that 2 out of their 63 patients with brucellosis were farmers. In our patient, the infection was localized into multi-ulcerative abscesses.

The most common infectious agents causing abscess formation are pyogenic bacteria such as *Staphylococci*, *Streptococcus pyogenes*, or rarely atypical mycobacteria.⁶ Place of residence, occupation, lifestyle and, to a great extent, a positive serological test can help the physician arrive at an exact diagnosis when confronting an unusual presentation of brucellosis.⁶

Balabanova-Stefanova et al.¹⁰ (2010) divided the manifestations of cutaneous brucellosis into 2 categories and placed ulcerative abscesses among the sporadic cases.

Apropos our patient, the positive result of the cultivation of the aspirates in a specialist medical

microbiology laboratory in a rather short time in conventional and BACTEC media was very helpful. However, the result had been reported negative earlier by 2 general laboratories.

Considering our patient's profession, he may have been infected by the consumption of unpasteurized dairy and/or through direct contact with infected animal products. This is our second documented case of *Brucella* foot abscesses in Kerman during the last 2 years. Unfortunately, we were unable to obtain any epidemiological data for this unusual presentation of brucellosis in Iran.

Conclusion

In areas where brucellosis is endemic, it is important to consider the *Brucella* species as a causative agent of cutaneous abscesses among other pyogenic microorganisms, not least among individuals who consume unpasteurized dairy products or those who are exposed to sources of *Brucella* through contact with animal tissues.

Cutaneous manifestations are generally not specific to brucellosis, but laboratory findings are useful for the diagnosis of the disease. Early diagnosis and timely initiation of proper treatment are of vital importance for the prevention of the later complications of the disease.

Conflict of Interest: None declared.

References

1. Tille PM. *Brucella*. Baily & scott's Diagnostic Microbiology. 14th ed. Missouri USA: Elsevier. 2017. p. 470-4.
2. Leong KN, Chow TS, Wong PS, Hamzah SH, Ahmad N, Ch'ng CC. Outbreak of Human Brucellosis from Consumption of Raw Goats' Milk in Penang, Malaysia. *Am J Trop Med Hyg.* 2015;93:539-41. doi: 10.4269/ajtmh.15-0246. PubMed PMID: 26055742; PubMed Central PMCID: PMC4559693.
3. Korkmaz P, Kartal ED. Skin manifestations associated with brucellosis. *EMJ Dermatol.* 2016;4:119-25.
4. Kudwah AJ. Cutaneous and soft tissue brucellosis. *Madkour's Brucellosis*. Berlin: Springer; 2001. p. 193-200.
5. Resendiz-Sanchez J, Contreras-Rodriguez A, Lopez-Merino A, Bravo-Guzman L, Valle-Valdez JG. Isolation of *Brucella melitensis* from an abscess on the left foot of a 3-year-old infant. *J Med Microbiol.* 2009;58:267-9. doi: 10.1099/jmm.0.004291-0. PubMed PMID: 19141748.
6. Sarrou S, Skoulakis C, Hajioannou J, Petinaki E, Bizakis I. *Brucella Melitensis* As Causative Agent for Neck Abscess in an Endemic Area. *Balkan Med J.* 2017;34:78-80. doi: 10.4274/balkanmedj.2015.1143. PubMed PMID: 28251029; PubMed Central PMCID: PMC5322519.
7. Sudulagunta SR, Kumbhat M, Sodalagunta MB, Settikere Nataraju A, Bangalore Raja SK. Isolated splenic abscess in brucellosis. *Oxf Med Case Reports.* 2017;2017:omx001. doi: 10.1093/omcr/omx001. PubMed PMID: 28473914; PubMed Central PMCID: PMC5410879.
8. Yilmaz M, Arslan F, Baskan O, Mert A. Splenic abscess due to brucellosis: a case report and a review of the literature. *Int J Infect Dis.* 2014;20:68-70. doi: 10.1016/j.ijid.2013.11.010. PubMed PMID: 24433982.
9. Karaali Z, Baysal B, Poturoglu S, Kendir M. Cutaneous manifestations in brucellosis. *Indian J Dermatol.* 2011;56:339-40. doi: 10.4103/0019-5154.82505. PubMed PMID: 21772606; PubMed Central PMCID: PMC3132922.
10. Balabanova-Stefanova M, Starova A, Arsovska-Bezhoska I. Cutaneous manifestations of brucellosis. *Macedonian Journal of Medical Sciences.* 2010;3:257-62. doi: 10.3889/MJMS.1857-5773.2010.0130.
11. Tanyel E, Tasdelen Fisgin N, Yildiz L, Leblebicioglu H, Doganci L, Tulek N. Panniculitis as the initial manifestation of brucellosis: a case report. *Am J Dermatopathol.* 2008;30:169-71. doi: 10.1097/DAD.0b013e31816563f5. PubMed PMID: 18360123.
12. Paton NI, Tee NW, Vu CK, Teo TP. Visceral abscesses due to *Brucella suis* infection in a retired pig farmer. *Clin Infect Dis.* 2001;32:E129-30. doi: 10.1086/319748. PubMed PMID: 11283821.