



RESEARCH

English Edition

eISSN 2069-7619 pISSN 2069-7597

ROMANIAN ASSOCIATION OF BALNEOLOGY

Methods and results – therapeutical rehabilitative approaches of a patient with a behaviour and psycho-cognitive status (minimally responsive state) after severe trauma brain injury (TBI) in a polytraumatic context – Case report

Ioniță Andreea¹, Doroteea Teoibaș-Șerban^{1,2}, Mihaela Mandu¹, Mihai Băilă¹, Cristian Badiu^{1,2}, Razvan-Laurentiu Oprea¹, Gelu Onose^{1,2}

Corresponding author: Ioniță Andreea, E-mail address: medic.umf@gmail.com



Balneo Research Journal

DOI: <http://dx.doi.org/10.12680/balneo.2018.205>

Vol.9, No.3, September 2018

p: 323–327

¹The Teaching Emergency Hospital “Bagdasar-Arseni” (TEHBA), Bucharest, Romania

²The University of Medicine and Pharmacy “Carol Davila” (UMPCD), Bucharest, Romania

Abstract

This case presentation was evaluated and endorsed by the hospital ethics committee, respecting the rights, safety and comfort of the patient. THEBA Bioethics Commission approval (9181 / 11.04.2018).

Key words: *Traumatic brain injuries, Polytraumatism*

Introduction

Traumatic brain injuries (TBIs) are a major cause, including for significant disabilities, currently with no cure.^[1]

TBI is the leading cause of death *in the first forty years of life*, and the number of years lost due to accidents is far greater from cardiovascular or neoplastic disease.^[2]

Brain and spinal cord, injuries (traumatic - TBI, respectively TSCI – or non-traumatic), generally entail lesions of the Central Nervous System (CNS), which, especially when severe, may result in impairments/ deficits - more or less marked and/or extended - mainly of:

motor/ neural-muscle (tone and/or trophicity), coordination, balance, sensitive (including pain) / – for TBI also *sensory(al)*, cognitive/ consciousness/ behavioural, and/o communication, endocrinological – ,sphincter(s) control, kind(s) – all not rarely within an altered general state.^[3]

”TBI is a non-degenerative, non-congenital insult to the brain, from an external mechanical force, possibly leading to permanent or temporary impairments of cognitive / diminished or altered state of consciousness, *physical*, and psycho-social functions”.^[4]

Case report

A 20 years old female was admitted in our Neuro-muscular clinic division presenting: minimally conscious state (SMC), bladder and bowel disorders, severe locomotor and selfcare impairments

Personal medical history

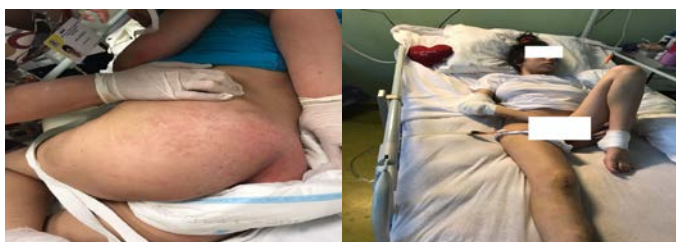The patient was involved in a traffic accident (24.01.2018) which caused:

Polytraumatism with: severe TBI : diffuse cerebral contusion, subarachnoid haemorrhage, bilateral frontal contusions, diffuse cerebral edema secondary, causing Deep coma (GCS = 3 points) ; Spine fractures or spinal cord fracture (?) fracture without displacement right lateral process C6 ; Bones fractures : right arm and forearm fracture, tibial fracture and right fibula ; with the fracture of the right fibula, left wing and left pubertal ram fracture; Haemorrhagic shock ; Thoraco-polmonar contusion with right basal pulmonary contusion of approx. 5 cm; Delabrant frontal wound;

The patient was transferred to the Department of Intensive Care in 24.01.2018 from a County Emergency Clinical Hospital. The patient is IOT + VM. Specific orthopedic interventions are practiced. (metal osteosynthesis of the humerus and tibia, forearm brows), left ilium-ischium-pubic fractures treated conservatively. February 1, 2018, the patient was extubated, hemodynamic and respiratory stable. February 19, 2018, the patient is transferred to the Emergency Clinical Hospital “Bagdasar Arseni” on the Neuromuscular Recovery Clinic section.

The patient was admitted for a complex rehabilitation program.

Clinical examination at admission : afebrile ; marked psychomotor agitation ; psycho-cognitive status (minimally responsive state) ; facies uncharacteristic ; skin and mucous membranes : palpebral bumps, pale teguments, first degree bed sore, fronto-parietal scalp suture wound, postoperative wounds in forearm healing and straight shoulder, wet mucous.



Clinical examination at admission :

- ❑ **Muscular System** : normotonic, normokinetic.
- ❑ **Osteoarticular System** : multiple cranial fractures, right limbs operated fractures , right fibula fracture (as a result of complex investigations, performed since hospitalization radiological / imagistic has been found : left wing and left pubertal ram fracture , massive articular fracture C3 right-treated conservatively.)
- ❑ **Cardiovascular system** : normal heart sound, no added sounds or murmur , BP: 120/65 mmHg; heart rate: 104 bpm
- ❑ **Respiratory system** : bilateral equal air entry, normal vesicular breathing ,peripheral oxygen saturation (SpO₂) 98 % .
- ❑ **Digestive system** : abdomen supple , painlessly spontaneous and palpable, *slow intestinal transit* , lower limb of the liver at the costal margin, spleen cannot be palpated
- ❑ **Urogenital system** : Giordano (-) ; permanent urinary catheter (S.U.F.)

NMAK EXAM


- ❑ **Minimally responsive state** , uncooperative.
- ❑ Agitated psychomotor in the bed plan
- ❑ Osteotendinous reflexes : O.T.R. cannot be tested on the right limbs ; O.T.R. Hyperactive upper an lower left limb ; apparently *without swallowing disorders*
- ❑ **Functional** : mentain bed decubitus .
- ❑ The patient has been clinically and functionally assessed according to the standardized protocols implemented in our clinic through the assessment scales / scales . There were improvement of the following evaluation scales: AIS, FIM, QoL : motor AIS-scale improved, , QoL not testable - admission, scale 76 point discharge , GOS improved with 2 point , FAC scale improved with 4 points , FIM scale , MRS improved with 3 points .

PARACLINIC TESTES

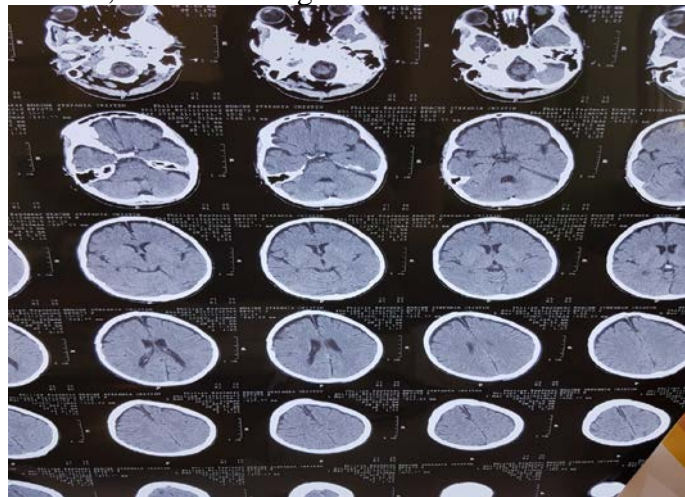
| | ↓ | ↑ | NORMAL |
|------------|-------|--------------------------|----------------|
| VSH | | 77 | 6-11 mm/h |
| HGB | 10.61 | 10.61 | 12-18 mg/dl |
| HCT | 32.23 | | 36-54% |
| Fibrinogen | | 789 | 169-515 mg/dl |
| WBC | | 17,48 | 4-11x 10000/uL |
| AST/GOT | | 42 Initially then normal | 15-37mg/dl |
| ALT/GPT | | 74 initially then normal | 14-9mg/dl |

Urinary tract infection with **Escherichia coli** treated with the help of the drug sensitivity test.

Cervical Spine CT Scan : Particle fracture at the upper anterior vertebral angle C4, fine fracture, without placement, at the level of the c3 process, anterolistezis c3-c4 `3 mm. Reversal of cervical physiological curves.



Brain CT scan : frontal centimetric anterior right anterior right fracture, right frontal-parietal fracture, bifrontal enlargement of bladder fluid.



EEG : activity based on normvoltaal alpha with a frequency of 10-13 cycles / second, organized in spindles in the posterior branches. Where the normal aspect beta in previous derivatives (F-T) .

Right humerus and forearm xray (AP view) : post fracture right humerus metal stem osteosynthesis. Radiolar centromedular thigh, normal forearm positioning.

Lower right limb x-ray (AP view) : post post fracture right tibial diaphysis, metal stem osteosynthesis. Post post fracture 1/3 proximal right fibula.

Interdisciplinary consultations

During the hospitalization the patient was evaluated by doctors from several specialties: Psychiatry , Orthopedics , Neurosurgery , Neurology , Infectious diseases: for the urinary tract infection mentioned in the paraclinic exam .

Psychiatric examinations :21.02.2018 : motor and vocal agitation , uncooperative.12.03.2018: **spectacular** improvement compared to previous examination .

Motor agitation is part of the natural evolution of brain recovery. 26.03.2018 : The same **spectacular** improvement compared to previous examination .

Multiple orthopedic examinations were requested to perform fracture analysis and to decide the patient's mobilization indication.

Following imaging investigations and orthopedic and neurosurgical consultations, it was recommended to mobilize it in the wheelchair, keeping the load on the right lower limb, this being possible as of 26.04.2018. March 7, 2018 suppresses the right elbow osteosynthesis material.

DIAGNOSTIC

Psycho-cognitive rough status in marked regression post-severe TBI (GCS = 4 at presentation in the emergency room) and Cervical SCI ? (Spinal Cord Injury) AIS / FRANKEL (D) with impairment from C3 level down , after a fracture of the right C3 articular massive, with unilateral rotational dislocation of C3-C4 (conservatively treated), multiple cranial fractures - frontal-parietal right - CT confirmed, hemorrhage under arachnoid - current CT : enlargement of pericerebral fluid spaces, diffuse cerebral ,the right front centimetric gap - all without neurosurgery indication, fronto-parietal scalp wound (sutured cured), limb fractures on the right side (osteosynthesis with humerus and tibia metal stems), right and left ilio-ischio-pubian fractures

(conservatively treated) .All after road car accident on 24.01.2018 (anamnesic - passenger-)

Rehabilitation program

General objectives

Fighting pain and regaining functionality that allows the patient self-care and locomotion :

1. Treating diseases and preventing complications
2. Improving the patient's psycho-cognitive status, mentally and emotionally
3. Socio-professional, family reintegration and improvement of quality of life

Means

1. Hygiene & diet:

Sleeping on a anti-pressure lesion mattress

Anti-pressure lesion pillow for the wheel chair, will not sit on the wheel chair longer than 2-4 hours interposed with a postural rest in decubitus of at least 30 minutes

Avoid carbonated juices, fermenting foods (beans, peas, cabbage, etc.)

Avoid alcohol, smoking

Avoid long viewing (≥ 2 hours / 24) on bright screens (TV, PC, tablet, etc.)

Avoid chocolate, coca-cola, pepsi, coffee, cocoa

It will avoid the intensely polluted environments, conflict situations

2. Pharmaceutical treatment with: Injectable anticoagulant type HGMM, antialgic, oral NSAID (Reumabloc) and topical, antibiotic (including aerosol), carbonic anhydrase inhibitor, hemostatic (etamsylate-single episod), iron supplement, tranquilizer / -hipnotic, anxiolytic, neurotrophic, beta-blocker, urinary antiseptic, hydro-electrolytic and supportive rebalancing.

3. Physiotherapy : in this particular case physiotherapy was not necessary

4. Kinetotherapy

Kinetic objectives

- Restoreing / maintaining joint mobility
- Promoting proximal and intermediar motor control
- Re-education of orthostatism
- Transfer training (from the wheel chair to bed and vice versa)
- Promote and train walking on a more physiological pattern
- Promoting the functionality and ability of the right limbs by designing a suitable occupational therapy program for the patient.

Evolution: spectacular from a functional point of view, the patient is mobilized in the wheelchair, maintains the orthostatism and performs the unilateral support on short distances, under the supervision of the physical therapist.

Prognosis:

Ad vitam – favorable

Ad functionem – mainly favorable

Complications

Urinary tract infection with **Escherichia coli** treated with the help of the drug sensitivity test.

The bedsore was healed .

Results

Following a complex neuro-recovery program developed by a multidisciplinary team made of doctors, kinesio-therapists, middle and allied health personnel, the patient had an extremely good evolution (during a short period of time) - attested on the scales and also - on a psycho-cognitive and behavioral level -.

From psychomotor agitation and unrecognizable words, she began to have a suitable behavior for a patient in this condition.

Conclusions

This case represents an exhaustive example of multidisciplinary and therapeutic neuro-rehabilitation approach, with both clinical and scientific impact.

Bibliography

1. Gelu Onose, Doroteea Teoibaş-Şerban, Cristina Popescu, Ioana Andone, Elena Brumă, Anca Mihăescu, Monica Haras, Ana Maria Bumbea, Aurelian Anghelescu, Tiberiu Spircu, Cristinel Badiu, Cristina Daia - New approaches regarding the use of actovegin® in subacute/ postacute/ subchronic traumatic brain injury patients, Farmacia, 2017, vol. 65, 5
2. Grintescu I, Tulbure D, Mirea L. Activated recombinant factor VII (Novoseven) in multiple trauma patients: an outcome analysis. Chirurgia (Bucur) 2006;101(6):615–624.)
3. “Tratat de Chirurgie” (Ediția a II-a) – sub red. Popescu I, Ciuce C (“Textbook of Surgery” - Coord. Eds. Popescu I, Ciuce C) - Vol. VI: Neurochirurgie (coord. Florian I Ş, Popeată I)/ Vol. VI: Neurosurgery (eds. Florian I Ş, Popeată I – Cap. 7.5.: ”Noțiuni sintetice de management neuroreabilitativ în statusuri post traumatisme cerebrale” (Chap. 7.5.: ”Synthetic notions of neurorehabilitative management in statuses after brain traumas”) – Onose G – Editura Academiei Române (the Publishing House of the Romanian Academy), București, 2014)
4. Dawodu ST Traumatic Brain Injury (TBI) - Definition, Epidemiology, Pathophysiology; <http://emedicine.medscape.com/article/326510-overview>