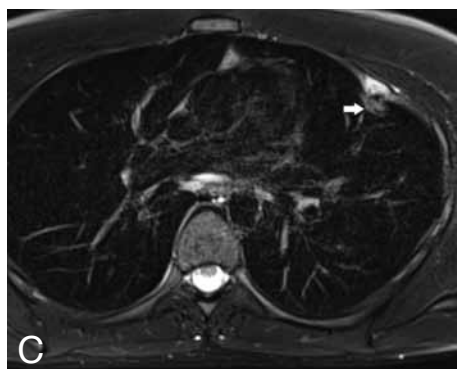
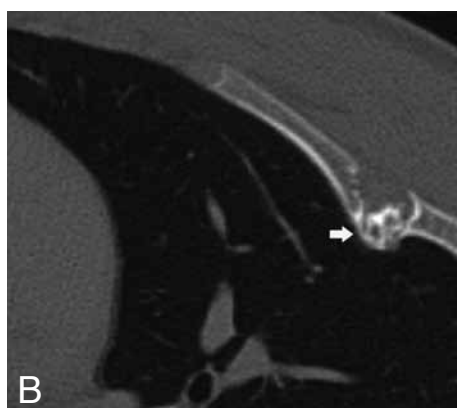
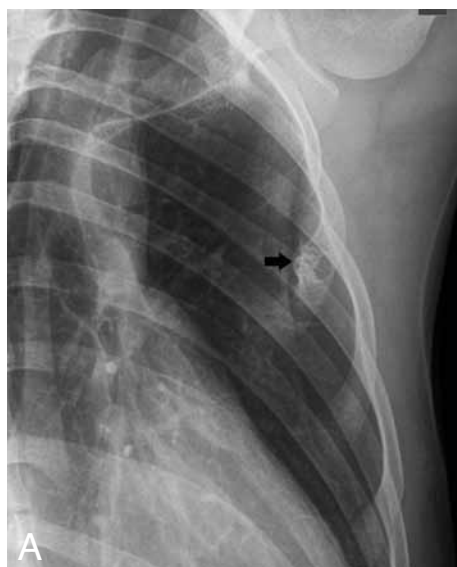

IMAGES IN CLINICAL RADIOLOGY



Enchondroma protuberans of the rib

L.J. Ceulemans¹, L. Verheyen¹, F.M. Vanhoenacker², R. De Wyngaert³, J. De Leersnyder¹

A 20-year-old man presented with a hard and painless swelling at the left chest wall. Plain radiographs showed an expansile lesion of the third rib. Most of the lesion was intramedullary located, well-defined and osteolytic, whereas the inner portion (black arrow) was partially calcified and protruding within the chest (Fig. A). The costochondral junction was not involved. Subsequent CT confirmed the eccentric location of the lesion. The inner part contained chondroid-like calcifications and showed intimate relationship with the left lung (white arrow). There was osseous expansion resulting in focal absence of the outer cortex. Sparing of a thin layer of fat adjacent to the outer cortex was indicative of absence of soft tissue extension (Fig. B). On MRI, the outer medullary part of the lesion was of high signal on T2-weighted images, in keeping with cartilaginous matrix. The exophytic inner part (white arrow) was of intermediate signal, with internal foci of low signal due to chondroid calcifications (Fig. C).

Based on the imaging findings, the diagnosis of a cartilaginous tumor was made. Because of the marked bone expansion and the central location in the ribs, a chondrosarcoma could not be excluded. Therefore, partial surgical resection of the rib was recommended and histology revealed the diagnosis of an enchondroma protuberans.

Comment

Enchondroma is a benign cartilage tumor, derived from displaced embryonic rests in the physis. The lesion typically develops centrally within the intramedullary cavity of the metadiaphysis of the short or long tubular bones. The ribs are only rarely involved. Enchondroma protuberans consists of a morphological variant caused by eccentric osseous expansion beyond the bone surface. This variant had been reported in the humerus, the phalanges of the hand and the ribs.

Radiographically, an enchondroma protuberans typically presents as a well-defined intramedullary osteolytic lesion associated with an exophytic component protruding through a focal defect of the cortical bone.

CT may better demonstrate lesion extension and the relationship with the adjacent pleura.

On MRI, the lesion is of low to intermediate signal on T1-weighted images, whereas T2-weighted images show a hyperintense mass with internal low-intensity septa or nodules, reflecting the cartilaginous matrix with chondroid calcifications.

The main differential diagnosis of an enchondroma protuberans of the rib includes a sessile osteochondroma or a chondrosarcoma. The intramedullary location of the cartilaginous matrix on MRI is in favour of a lesion arising from the medullary bone i.e. enchondroma, whereas a sessile osteochondroma is covered by a superficially located cartilage cap. In case of a cartilaginous lesion within the rib, a chondrosarcoma should always be considered, since malignant cartilage tumors are more frequent than benign within the ribs and axial skeleton.

Therefore, treatment of choice consists of partial rib resection, allowing accurate histopathological examination and preventing further tumor growth.

Reference

1. Keating R.B., Wright P.W., Staple T.W.: Enchondroma protuberans of the rib. *Skeletal Radiol*, 1985, 13: 55-58.

1. Department of Surgery, AZ Sint-Maarten, Duffel-Mechelen, Duffel, Belgium, 2. Department of Radiology, AZ Sint-Maarten, Duffel-Mechelen, University Hospital Antwerp and University of Ghent, Belgium, 3. Department of Radiology, Regionaal Ziekenhuis Heilig Hart, Leuven, Belgium.