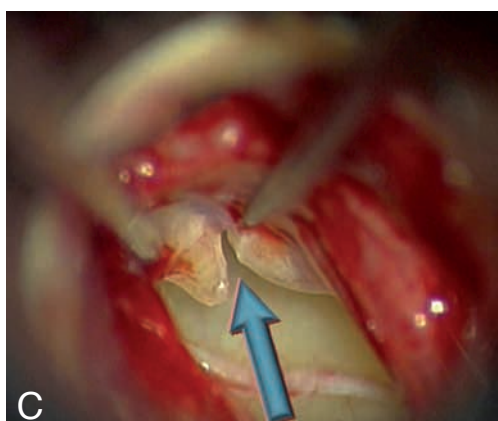
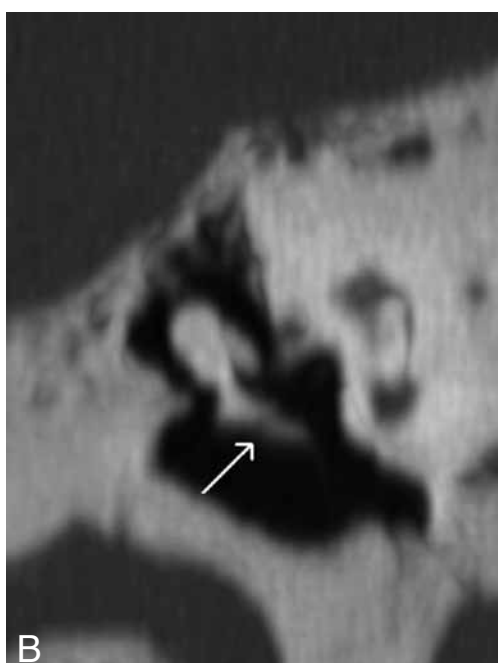
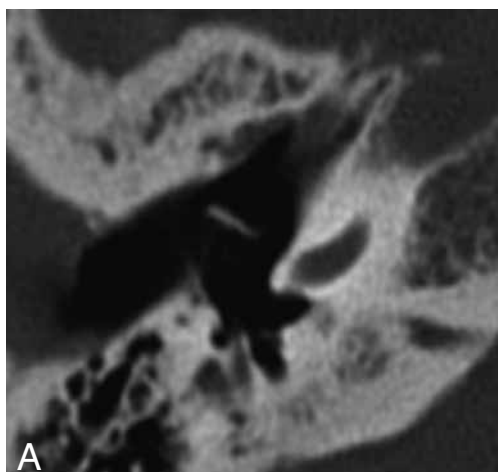


IMAGES IN CLINICAL RADIOLOGY



High resolution CT diagnosis of isolated fracture of the malleus handle

D. Volders¹, Th. Somers², J. Casselman^{1,3}

We report a case of a 48-year-old woman with a sudden-onset unexplained conductive unilateral hearing loss. There was no improvement after a trial with systemic corticosteroids. On otomicroscopy, the right tympanic membrane showed an abnormal outline of the malleus handle. Pneumatic otoscopy revealed excessive movement of the umbo compared with the lateral process. Audiometric testing showed a conductive hearing loss in the right ear, with an average pure-tone audiometry of air conduction of 40 dB and a maximum air-bone gap of 45 dB at 500 Hz. Tuning fork tests confirmed conductive hearing loss. Tympanometry showed increased compliance in the right ear and an absent ipsilateral stapedial reflex in response to a broad-band stimulus. High resolution computed tomography (CT) imaging of the temporal bone was performed by a high-definition CT system (Discovery CT750 HD[®], GE, Hounslow, England). MIP (Maximum Intensity Projection) coronal ultrafine (around 0.1 mm) reconstructions of the malleus revealed a small non-displaced isolated fracture of the malleus handle (Fig. A and B). On the left there was a continuous appearance of the middle ear ossicles. During surgery, the isolated fracture of the right malleus handle was visualised and an ossiculoplasty was performed using a hydroxylapatite bone cement (OtoMimix[®], Biomet, Jacksonville, Florida) (Fig. C). Postoperatively, average pure-tone audiometry of air condition improved to 30 dB, and maximum air-bone gap improved to 35 dB at 500 Hz.

Comment

Isolated fracture of the malleus handle is an extremely rare ossicular injury. Most cases described in literature present with sudden-onset conductive hearing loss after digital manipulation of the external auditory canal (1). Until now, the standard diagnosis was made on the basis of otomicroscopy, audiometry, tympanometry and laser-Doppler vibrometry (2). But thanks to the arrival of high resolution CT imaging, even small non-displaced fractures of the middle ear ossicles, can now be diagnosed for the first time.

References

1. Pedersen C.B.: Traumatic middle ear lesions. Fracture of the malleus handle, aetiology, diagnosis and treatment. *J Laryngol Otol*, 1989, 103: 901-903.
2. Chien W., McKenna M.J., Rosowski J.J., Merchant S.N.: Isolated fracture of the manubrium of the malleus. *J Laryngol Otol*, 2008, 122: 898-904.

1. Department of Radiology, A.Z. St.-Jan Hospital, Brugge, Belgium,
2. Department of Otolaryngology, A.Z. St.-Augustinus Hospital, Wilrijk, Belgium, 3. Department of Radiology, A.Z. St.-Augustinus Hospital, Wilrijk, Belgium.