

JBR–BTR, 2010, 93: 314-316.

## ANTENATAL DIAGNOSIS OF A SACROCOCYGEAL TERATOMA

B. Mbumba<sup>1</sup>, A. Masseur<sup>2</sup>, P. Lingier<sup>3</sup>, C. Donner<sup>4</sup>, D. Vermeulen<sup>5</sup>, J.R. Makulo<sup>1</sup>, F. Lepira<sup>1</sup>, M. Cassart<sup>2</sup>

**Although rare, sacrococcygeal teratoma is the most common congenital tumor. We report a case of a precociously diagnosed and rapidly growing cystic lesion. These tumors may be associated with hemodynamic and hemorrhagic complications. Therefore, affected fetuses should be carefully followed during the entire pregnancy by ultrasound and MR imaging in order to evaluate the evolution of the mass, its consequences on the fetal organs and to appreciate the wellbeing of the fetus. Delivery and post natal work up can therefore be optimized.**

**Key-word:** Teratoma.

### Case report

A cystic extra pelvic mass was diagnosed on the routine first trimester ultrasound of a 37 year-old woman. It demonstrated a cystic lesion of 9 mm arising from the perineum of the 13 weeks old fetus, presenting a mostly extra pelvic extension. At 18 weeks of GA, the mass increased to 37 mm diameter (Fig. 1). The US hemodynamic findings (signs of hydrops, middle cerebral artery velocity) were regularly followed and stayed in normal ranges. The MR imaging performed at 30 weeks of GA confirmed the cystic nature of the lesion which presented multiple septas. Its greater dimension at that age was around 160 mm. MR imaging also confirmed the extra pelvic extension with a small pararectal cyst but without any involvement of the abdominal or retroperitoneal compartments (Fig. 2). The liquid nature of the mass and its extra pelvic location in close contact with the coccygeal bone were highly suggestive of the diagnosis of sacrococcygeal teratoma (1). The sudden increase in size of the lesion prompted the decision of performing a cesarian section at 38 weeks. A transuterine needle drainage of the lesion under US guidance was performed to facilitate delivery. Neonatal MR imaging confirmed antenatal data. It also demonstrated the integrity of the lumbar and sacral vertebrae avoiding unnecessary radiation exposure (Fig. 3). At the second day after birth, a complete surgical resection of the mass was successfully performed. The histological data confirmed the

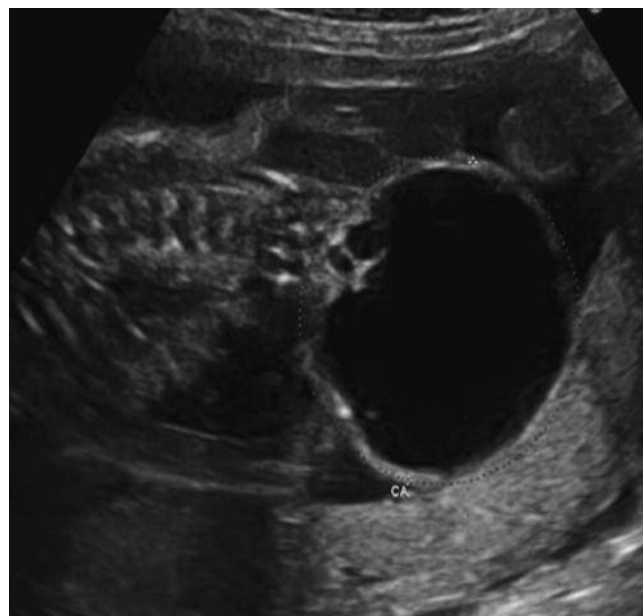

Fig. 1. — Coronal US scan of the fetus at 19 weeks of gestational age showing the cystic pelvic lesion.

diagnosis of mature teratoma with cells originating from the three germ cells layers. Fetal imaging has allowed to adopt an adequate obstetrical management and to optimize the neonatal work-up.

### Discussion

The sacrococcygeal teratoma, the most common congenital tumor, is associated, in its antenatal presentation with a lot of complications. In this context, an early diagnosis and frequent ultrasound follow-up are advised in order to appreciate the

fetal wellbeing, to decide about the best mode and period of delivery and to optimize the neonatal work-up. The diagnosis, the size and the evaluation of the extension of the mass constitute the most important contribution of antenatal diagnosis. The differential diagnoses of cystic pelvic lesions include preferentially the cystic teratomas and lymphangiomas. Other cystic pelvic lesions (ovarian cysts, mesenteric cyst, duplication cysts...) were significantly less probable in this context because of the extra-pelvic extension of the mass. The close contact of the lesion with the coccygeal bone was highly suggestive of a sacrococcygeal teratoma.

US can also depict potential associated anomalies classically encountered in 5 to 26% of cases. They mostly concern the urinary tract (bladder exstrophy), the spine (dysraphism) and associated clubbed feet which are accessible to

*From:* 1. University Clinics of Kinshasa, RD Congo, 2. Department of Medical Imaging, 3. Department of Pediatric Surgery, 4. Department of Fetal Medicine, 5. Department of Neonatal Intensive Care Unit, ULB, Erasme Hospital, Brussels, Belgium.

*Address for correspondence:* Dr M. Cassart, Service de Radiologie, Département d'Imagerie Pédiatrique et Gynéco-obstétricale, Hôpital Erasme, Université Libre de Bruxelles, Route de Lennik, 808, B-1070 Brussels, Belgique. E-mail: [mcassart@ulb.ac.be](mailto:mcassart@ulb.ac.be)

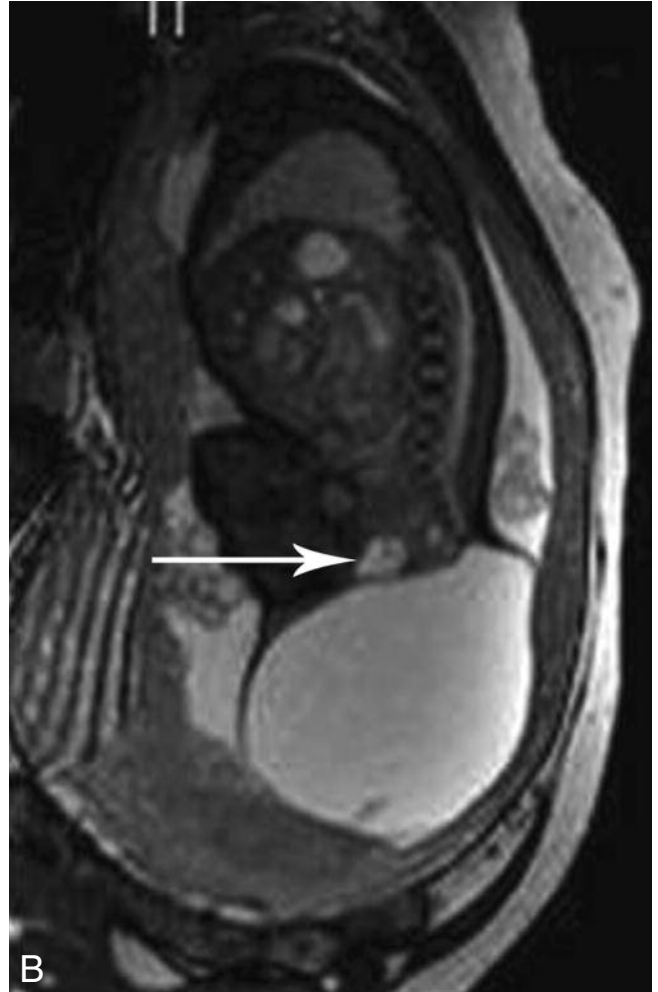
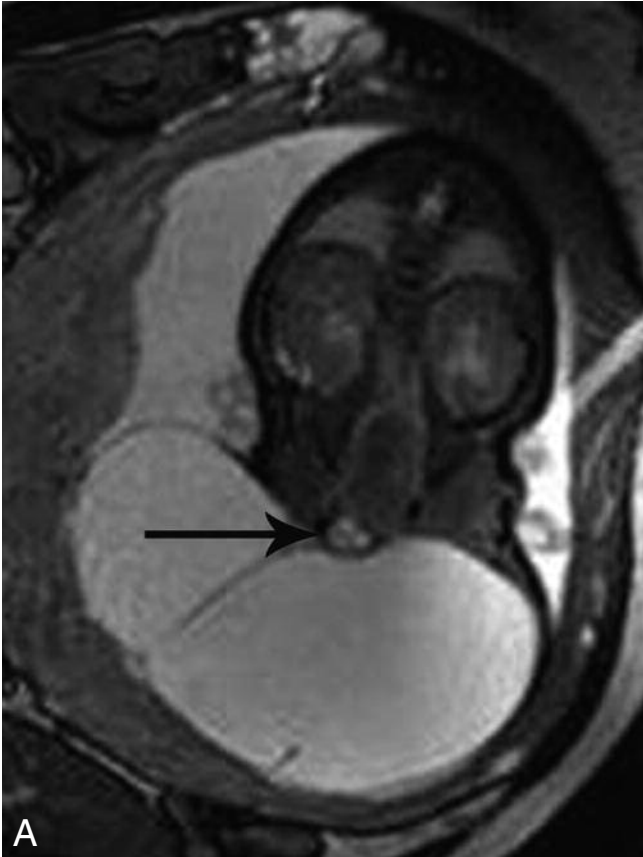


Fig. 2. — Prenatal MR imaging, coronal (A) and sagittal (B) T2 weighted images showing the liquid nature of the lesion and its expansive extra pelvic extension. The para rectal cyst is also well depicted (arrows).

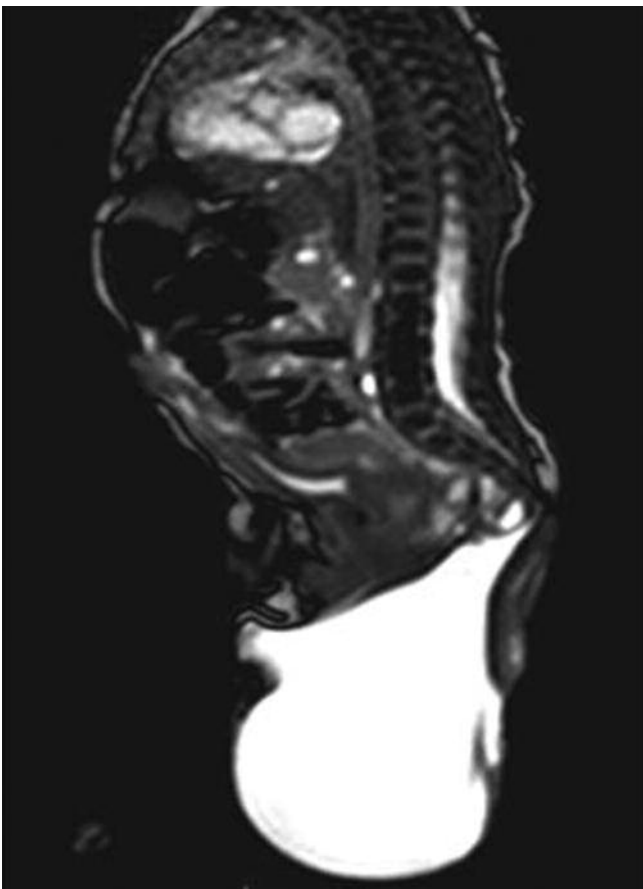


Fig. 3. — Post natal MR imaging showing the mass and the integrity of the sacrum.

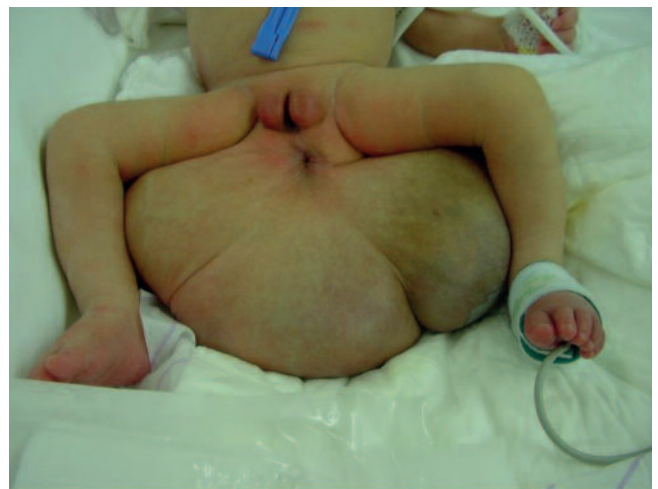

Fig. 4. — Neonatal aspect of the lesion

US diagnosis. The association with ano-rectal malformation is described in Currarino triad and is more difficult to diagnose by US. MR imaging may be helpful in this context. In the present case, the lesion was an isolated finding.

The fetal prognosis relies on the compressive mass effect that such huge lesions can exert on the abdominal visceral organs (i.e major hydronephrosis) but also on the potential development of hemodynamic anomalies (in cases with important solid components) (2). Increased blood flow in the mass may lead to blood shunting and fetal cardiac failure. Intra tumoral hemorrhage can also occur and induce severe secondary fetal anemia. All these complications can be detected by US (3). An intra tumoral hemorrhage presents as an acute enlargement of the mass which appears more heterogeneous. An increase in systolic velocity of the median cerebral artery signifies about fetal anemia. In the present case no associated malformations or hemodynamic complications have been encountered. The antenatal prediction capacity about potential malignant transformation of the lesion is poor. It mostly relies on the volume of the solid component of the mass; the more solid tissue, the higher risk of malignant transformation.

MR imaging is a complementary imaging technique to US performed in order to better characterize the tissular components of the mass (haemorrhage) and helps in precisely depicting the extension of the lesion particularly in very large lesions (4).

The delivery is therefore adapted, some authors advise cesarian section after a percutaneous drainage of the mass under US guidance (whenever the fetus presents a high risk of haemorrhage (solid tumor, tumor size > 10 cm)) (5). This attitude has been adopted in the present case because of the huge size of the lesion (Fig. 4). The necessity of neonatal surgical resection is presently admitted considering the mass effect of the lesion but also its potential malignant transformation (6). Tumoral markers ( foeto-protein, HCG...) are currently measured out after surgery to have a baseline value allowing biological follow-up. An increase after surgery is suggestive of possible recurrence and leads to imaging investigations.

#### Conclusion

The contribution of imaging techniques (US and MR imaging) is mandatory in the diagnosis and prognosis of sacrococcygeal teratomas. It allows a better

management of the fetus in utero, of the delivery and of the post natal work-up.

#### References

1. Altman R.P., Randolph J.G., Lilly J.R.: Sacrococcygeal teratoma: American Academy of Pediatrics Surgical Section Survey-1973. *J Pediatr Surg*, 1974, 9: 389-398.
2. Benachi A., Durin L., Maurer S.V., Aubry M.C., Parat S., Herlicoviez M., et al.: Prenatally diagnosed sacrococcygeal teratoma: a prognostic classification. *J Pediatr Surg*, 2006, 41: 1517-1521.
3. Westerburg B., Feldtein V.A., Sandberg P.L., Loppo J.B., Harisson M.R., Albanese C.T.: Sonographic prognostic factors in fetuses with sacrococcygeal teratoma. *J Pediatr Surg*, 2000, 35: 322-325.
4. Avni E.F., Guibaud L., Robert Y., Segers V., Zierysen F., Delaet M.H., Metens T. MR Imaging of fetal sacrococcygeal teratoma: diagnosis and assessment. *AJR*, 2002, 178: 179-183.
5. Lo Curto M., D'angelo A., Cechetto G., Klersy C., Dall'Igna P., Frederico A., et al.: Mature and immature teratoma: results of the first paediatric Italian study. *Pedriatr Surg Int*, 2007, 23: 315-322.
6. Mekki M., Jallouli M., Krichene I., Belghith M., Jouini R., Sahmoun L., et al.: Les tératomes sacro-coccygiens. Expérience d'un service de chirurgie nord-africain. *Oncologie*, 2007, 9: 864-868.