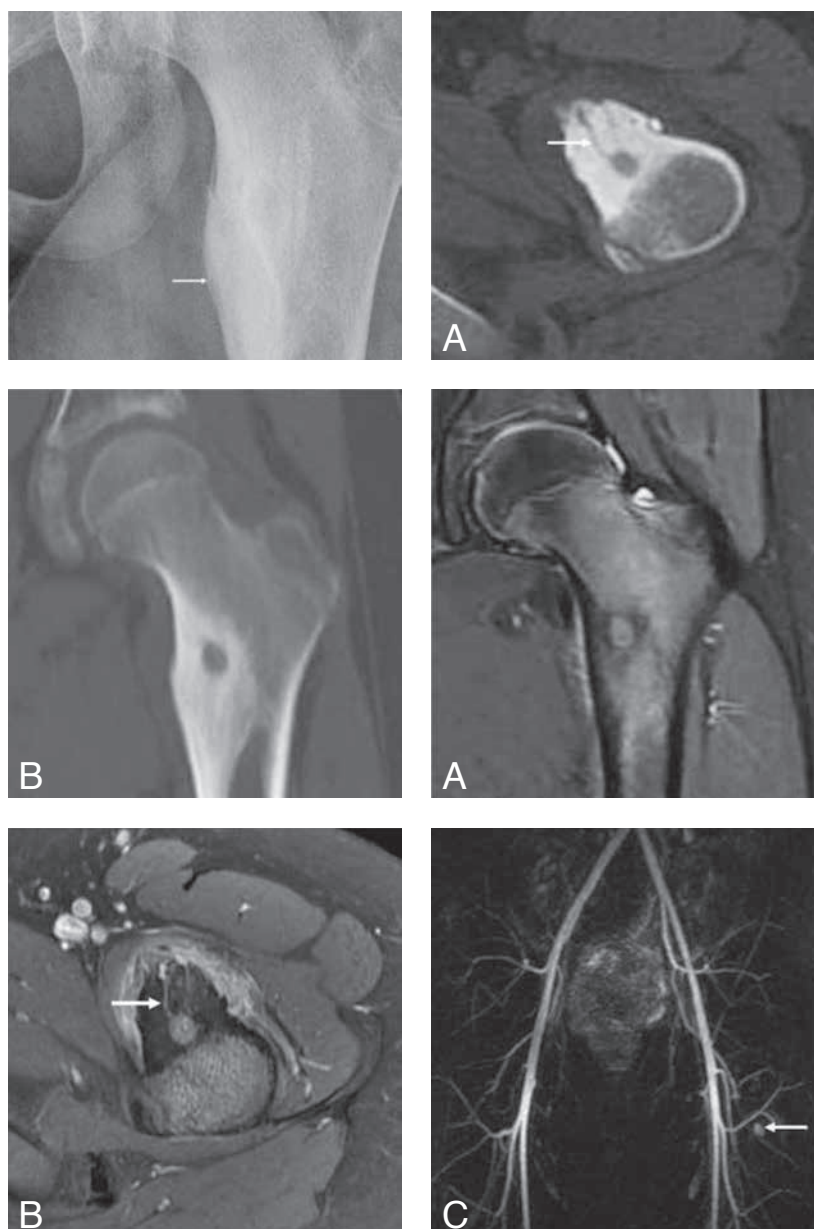


OSTEOID OSTEOMA

M. Keupers¹, J. Vandevenne^{1,2}, E. Gielen¹, M. Horvath^{1,2}, Y. Palmers^{1,2}, M. Vandersteen²

Key-word: Osteoma

Background: A 12-year-old boy presented with complaints of intermittent left hip pain for over one and a half year. The pain was worse at night and was relieved by taking non-steroidal anti-inflammatory drugs (NSAIDs), such as Aspegic. There was no history of previous trauma. Being a refugee, the patient was lost to follow-up. However, we managed to contact him and arranged a surgical treatment.



1. Department of Radiology, Ziekenhuizen Oost-Limburg, Genk, Belgium, 2. Department of Morphology, Hasselt University, Campus Diepenbeek, Diepenbeek, Belgium

	1	2A
Fig.	2B	3A
	3B	3C

Work-up

On conventional radiography of the left hip (AP view) (Fig. 1), cortical thickening and sclerosis near the lesser trochanter of the femur is observed.

CT scan of the left femur (Fig. 2, A: axial section, B: Reformatted image in the coronal plane) demonstrates a round radiolucent focus within the sclerotic area. This focus was connected to the bony surface by hypodense grooves (arrow).

MRI of the left hip was performed. Coronal proton density (PD) weighted-image with fat saturation (FS) (A) shows a round focus of intermediate signal intensity surrounded by hypo-intense sclerotic bony rim is seen. Diffuse bone marrow edema at the proximal femur is seen. Transverse Gadolinium-enhanced T1-weighted image (B) demonstrates contrast enhancement at the soft tissue surrounding the lesser trochanter. Pronounced enhancement is seen at a round focus, that is connected to an enhancing groove (arrow) traversing the hypo-intense sclerotic bone. MR angiography (C) shows a rapidly enhancing nodule in the arterial phase corresponding with the round focus (arrow).

Radiological diagnosis

Based on imaging findings the diagnosis of *osteoid osteoma* was made. The radiolucent contrast-enhancing round focus represents the nidus of the osteoid osteoma. Note the vascular grooves traversing the sclerotic bone, representing the feeding arterioles of the nidus.

Discussion

Osteoid osteoma is a benign osteoblastic neoplasm composed of osteoid and woven bone that is most commonly located in the cortex of long bones. It occurs most frequently in young boys. Osteoid osteoma is a painful lesion and the pain gets worse at night. NSAIDs, such as Aspirin often give drastic relief of the pain and can be used for conservative treatment. Osteoid osteoma can be successfully treated with surgical excision or CT-guided percutaneous radiofrequency ablation.

Radiographically, an osteoid osteoma classically appears as a sclerotic cortical thickening in the shaft of a long bone with usually a small radiolucent area within the center of the sclerosis. This radiolucent area is called the nidus of the osteoid osteoma and causes the pain. The nidus is often

obscured on plain radiographs by the surrounding sclerosis. CT scan and MR angiography, however, can provide a more precise anatomic location of the nidus to the surgeon.

On CT scan, the nidus of an osteoid osteoma appears as a round hypolucent area surrounded by curvilinear hypolucent grooves that appear to radiate through the thickened sclerotic surrounding bone.

These lucent grooves represent feeding arterioles that have become encased by the sclerotic bone reaction around the nidus. These vascular grooves on CT scan can help to distinguish osteoid osteomas from other bone neoplasms or inflammatory processes.

Because the osteoid osteoma nidus is hypervascular, gadolinium-enhanced MRI can be used to differentiate osteoid osteoma from other bone lesions. On the T1-weighted images with fat saturation after intravenous gadolinium injection, a contrast-enhancing nidus with enhancing grooves through hypointense sclerotic bone can be seen, representing the hypervascularity of the nidus. This was already demonstrated on digital subtraction angiography with arterial injection of contrast material for diagnosis and preoperative localisation of this benign tumor. MR angiography may equally well show the rapid enhancing nodule in the arterial phase corresponding with the nidus.

The patient underwent surgery and the nidus of the osteoid osteoma was successfully curetted. Histopathological examination confirmed the diagnosis of an osteoid osteoma. The osteosclerosis often regresses after surgical removal of the osteoid osteoma.

Bibliography

1. Liu P.T., Chivers F.S., Roberts C.C., et al.: Imaging of osteoid osteoma with dynamic gadolinium-enhanced MR imaging. *Radiology*, 2003, 227: 691-700.
2. Liu P.T., Kujak J.L., Roberts C.C., et al.: The vascular groove sign: A new CT finding associated with osteoid osteomas. *AJR*, 2011, 196: 168-173.
3. Kransdorf M.J., Stull M.A., Gilkey F.W., et al.: From the Archives of the AFIP Osteoid Osteoma. *RadioGraphics*, 1991, 11: 671-696.
4. Van Rompaey W., Vereycken H., De Schepper A.: Diagnosis of osteoid osteoma by digital subtraction angiography. *Fortschr Röntgenstr*, 1986, 145: 578-581.