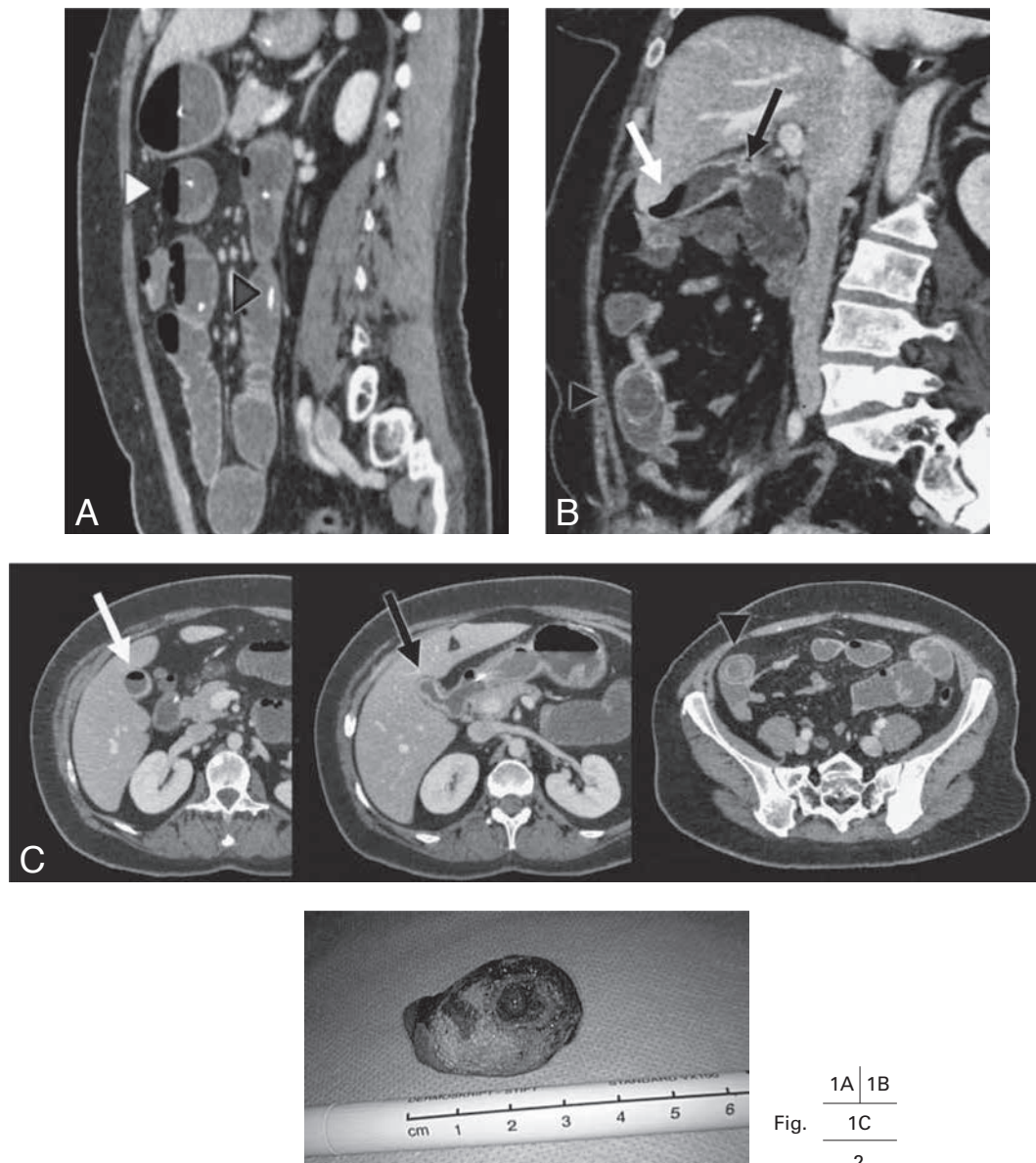


GALLSTONE ILEUS WITH A BILIODIGESTIVE FISTULA

L.J. Schijf¹, D. Van der Vlies², A.G. Aalbers³, A. Bruining⁴

Key-word: Gallbladder, calculi

Background: A 34-year-old woman with breast cancer, metastasized to bone and brain, was admitted to our hospital with abdominal discomfort, nausea and constipation. Physical examination revealed a diffuse tender abdomen without bowel sounds. On laboratory examination, slightly elevated gamma-GT levels were found; gastroscopy showed 2 liter of bilious fluid. A nasogastric tube was placed.



1. Department of Radiology, Academic Medical Center Amsterdam, Amsterdam, The Netherlands, 2. Department of Radiology, Gelre ziekenhuizen, Apeldoorn, The Netherlands, 3. Department of Surgery and 4. Department of Radiology, Nederlands Kanker Instituut – Antoni van Leeuwenhoek Ziekenhuis, Amsterdam, The Netherlands

Work-up

On contrast-enhanced CT scan of the abdomen (Fig. 1), reformatted image in the sagittal plane (A), some slightly dilated small bowel loops are visible, with multiple air-fluid levels (white arrowhead) and a duodenal tube (dark arrowhead). On reformatted image in the sagittal plane (B), a fistulous communication between gallbladder and duodenum (dark arrow) is visible, with the presence of gas in the gallbladder (white arrow). Obstruction at the level of the terminal ileum by a slightly calcified structure (dark arrowhead), consistent with ectopic gallstone. On axial images at different levels (C), the aerobilia (white arrow), bilio-digestive fistula (dark arrow) and obstructing gallstone (dark arrowhead) are demonstrated.

Figure 2 shows the impacted stone after enterolithotomy.

Radiological diagnosis

Based on the CT findings, the diagnosis of *gallstone ileus with a biliodigestive fistula* was made. The patient underwent a laparoscopic enterolithotomy, a calcified gallstone measuring more than 3 cm was removed.

Discussion

Cholelithiasis is a common disease with a 10% prevalence in the United States and Western Europe. Gallstone ileus is an unusual complication of cholelithiasis, occurring in less than 0.5% of the patients. It is responsible for approximately 1-3% of all mechanical intestinal obstructions. Nevertheless, it is a quite important disease, especially in elderly patients, as the disease causes 25% of non-strangulated small bowel obstructions in patients older than 65 years.

The pathogenesis of gallstone ileus is based on acute or chronic cholecystitis associated with chole-

lithiasis, spreading inflammation leading to adhesions with the alimentary tract and developing biliary-enteric fistula. Symptoms are commonly insidious at onset, with alternate phases of improvement and relapse, corresponding to the progression of the stone along the digestive tract. The diagnosis is often delayed since symptoms may be intermittent and investigations fail to identify the cause of the obstruction.

The radiographic criteria for the diagnosis of gallstone ileus were first described in 1941 by the Rigler's triad: pneumobilia, mechanical bowel obstruction and an ectopic gallstone.

Plain abdominal radiographs remain the single most important diagnostic test, but less than 15% of gallstones are visible on these radiographs.

Ultrasonography can reveal fistulas, impacted stones, and residual cholelithiasis.

Abdominal CT scan, though, demonstrates the biliary status, the cause and degree of intestinal obstruction (frequently the complete Rigler's triad) and often also the bilio-digestive fistula.

Surgical enterolithotomy is the traditional treatment and this allows for relief of the obstruction in the short term. Whether treatment of existing fistula is necessary remains unclear.

Bibliography

1. Abou-Saif A., Al-Kawas F.H.: Complications of gallstone disease: Mirizzi syndrome, cholecystocholedochal fistula, and gallstone ileus. *Am J Gastroenterol*, 2002, 97: 249-254.
2. Ayantunde A.A., Agrawal A.: Gallstone ileus: diagnosis and management. *World J Surg*, 2007, 31: 1292-1297.
3. Lassandro F., Gagliardi N., Scuderi M., et al.: Gallstone ileus analysis of radiological findings in 27 patients. *Eur J Radiol*, 2004, 50: 23.
4. Reisner R.M., Cohen J.R.: Gallstone ileus: a review of 1001 reported cases. *Am Surg*, 1994, 60: 441-446.