

This article is licensed under the Creative Commons Attribution-NonCommercial 4.0 International License (CC BY-NC) (<http://www.karger.com/Services/OpenAccessLicense>). Usage and distribution for commercial purposes requires written permission.

Single Case

Lethal Bleeding from a Duodenal Cancerous Ulcer Communicating with the Superior Mesenteric Artery in a Patient with Pancreatic Head Cancer

Yoshifumi Morita^a Takanori Sakaguchi^a Ryo Kitajima^a
Satoru Furuhashi^a Ryota Kiuchi^a Makoto Takeda^a Takanori Hiraide^a
Yasushi Shibasaki^a Hirotoshi Kikuchi^a Yuji Suzuki^b Kei Tsukamoto^c
Tomoharu Matsuura^d Hiroya Takeuchi^a

^aSecond Department of Surgery, Hamamatsu University School of Medicine, Hamamatsu, Japan; ^bDepartment of Anesthesiology and Intensive Care, Hamamatsu University School of Medicine, Hamamatsu, Japan; ^cDepartment of Radiology, Hamamatsu University School of Medicine, Hamamatsu, Japan; ^dFirst Department of Medicine, Hamamatsu University School of Medicine, Hamamatsu, Japan

Keywords

Pancreatic cancer · Lethal bleeding · Superior mesenteric artery · Intra-aortic balloon occlusion

Abstract

Pancreatic cancer often invades the duodenum and causes obstruction, but rarely causes massive duodenal bleeding. A 68-year-old male was admitted to our hospital because of vomiting. Enhanced abdominal CT showed a hypovascular tumor with air bubbles in the uncinate process of the pancreas. The tumor invaded the duodenum and metastasized to the liver and peritoneum. The main trunk of the superior mesenteric artery (SMA) was circumferentially involved. After admission, he had hematemesis and melena. Emergency gastroduodenoscopy revealed pulsating vessels in the third portion of the duodenum and he eventually experienced hemorrhagic shock. Severe bleeding occurred from his mouth and anus like a catastrophic flood. It was difficult to sustain blood pressure even with massive blood transfusion with pumping.

After insertion of an intra-aortic balloon occlusion catheter, the massive bleeding was eventually stopped. Although we attempted interventional radiography, aortography revealed direct communication between the main SMA trunk and the duodenal lumen. The tumor was considered anatomically and oncologically unresectable. Thus, we did not perform further intervention. The patient died 2 h after angiography. Herein, we report the case of pancreatic head cancer causing lethal bleeding associated with tumor-involved SMA. Duodenal bleeding associated with pancreatic cancer invasion should be considered as an oncogenic emergency.

© 2018 The Author(s)
Published by S. Karger AG, Basel

Introduction

Pancreatic cancer is highly malignant and it easily invades adjacent organs such as the stomach, duodenum, and bile duct. The main symptoms are abdominal pain, jaundice, nausea, and body weight loss. However, massive gastrointestinal bleeding associated with direct invasion to the duodenum is rare. Previously, Lee et al. [1] reported that only 2.6% of pancreatic cancer patients initially presented with gastrointestinal bleeding. Usually, hemostatic treatment including endoscopic, radiological, and surgical interventions can be successfully achieved. However, uncontrollable hemorrhage might lead to an oncological emergency in some cases.

Here we report a case of disastrous duodenal bleeding caused by direct communication between the main trunk of the superior mesenteric artery (SMA) and the duodenal lumen associated with pancreatic cancer.

Case Report

A 68-year-old male visited the primary hospital with complaints of body weight loss (20 kg/3 months) and vomiting. Abdominal ultrasonography revealed a pancreatic tumor and gastric dilatation. He was introduced to our hospital with suspicion of duodenal obstruction associated with pancreatic cancer. Blood examination revealed elevation of biliary tract enzymes such as ALP (481 U/L) and GGT (78 U/L), tumor markers such as CEA (6.8 ng/mL) and CA19-9 (987 U/mL) levels, and slight anemia (Hb level 13.1 g/dL). Enhanced CT showed a hypovascular tumor in the uncinate process of the pancreas with dilatation of the bile duct, pancreatic duct, and stomach (Fig. 1a). The pancreatic tumor had air bubbles presumably from direct invasion to the duodenum. The main trunk of the SMA was circumferentially involved in the collapsing tumor (Fig. 1b). The superior mesenteric vein and splenic vein were narrowed. Multiple low-density lesions highly suspected to be metastatic tumors were also detected in the bilateral lobe of the liver (Fig. 1c). Intra-abdominal nodules suspected to be peritoneal dissemination were also detected. The patient was admitted to our department and a nasogastric tube was inserted for decompression. Elective gastrojejunostomy was scheduled several days later. The day before surgery, the drain fluid from the nasogastric tube changed from clear gastric juice to dark blood. The amount of excreted fluid was 300 mL. Emergency gastroduodenoscopy was performed and a deep ulcer with pulsating vessels was shown in the third portion of the duodenum (Fig. 2). A hemostatic procedure was not performed because active bleeding from the ulcer was not observed. A few hours later, hemorrhagic shock occurred because of recurrent hematemesis and melena. The patient was transferred to the ICU and underwent resuscitative maneuver. Massive bleeding occurred from the

mouth and anus like a catastrophic flood. It was difficult to sustain blood pressure even with massive blood transfusion and pumping. The estimated blood loss was extended well beyond 10 L. In total, we administered 6,000 mL of 5% albumin, 5040 mL of red blood cells, and 3,360 mL of fresh frozen plasma. We performed angiography to identify the source of bleeding. After aortic occlusion with an intra-aortic balloon catheter above the bifurcation of the celiac artery (Fig. 3a), the massive bleeding stopped. Aortography revealed direct communication between the main SMA trunk and the duodenal lumen (Fig. 3b, c). We did not perform further intervention because peripheral flow of the SMA could not be observed and the pancreatic cancer appeared to be anatomically and oncologically unresectable. The patient died 2 h after angiography.

Discussion

Pancreatic cancer has highly invasive characteristics, and it can cause various clinical symptoms such as abdominal pain, anorexia, nausea, body weight loss, and jaundice. Pancreatic cancer easily invades adjacent organs and sometimes causes gastrointestinal obstruction. Although duodenal invasion frequently occurs in patients with pancreatic cancer, massive gastrointestinal bleeding is seldom encountered. Pancreatic cancer is responsible for only 0.35–1.9% of upper gastrointestinal bleeding cases [2]. Lee et al. [1] reported that 2.6% of patients with pancreatic cancer presented with gastrointestinal bleeding as the initial manifestation. On the other hand, few authors have reported serious hemorrhage as an initial manifestation of pancreatic cancer [3–6].

The types of bleeding associated with pancreatic cancer are divided into the following three categories: (1) rupture of esophageal or gastric varices caused by narrowing of the splenic or portal vein, (2) bleeding from the pancreatic duct orifice (hemorrhage or wirsungorrhagia), and (3) bleeding from direct invasion of the tumor into the stomach or duodenum [7].

Although endoscopic hemostasis is effective to stop bleeding and is considered the first choice of treatment, such a strategy is not always effective. Additionally, endoscopic clipping of exposed vessels often drastically changes the situation from a steady state to an uncontrollable state. In our case, active bleeding was not observed on gastroduodenoscopy. We did not treat the pulsating vessels located in the cancerous ulcer because the vascular diameter appeared to be oversized to manage endoscopically.

Transcatheter arterial embolization is useful for temporary hemostasis in cases with arterial bleeding as a second step. In cases of active bleeding, improvement of the general conditions has the highest priority. On the other hand, we should keep in mind that posttreatment ischemia can be caused by occlusion of the culprit vessels. Moreover, transcatheter arterial embolization is not always effective because of the presence of multiple collateral vessels from the celiac and superior mesenteric arterial communication. In our case, we did not perform radiological interventions because peripheral flow of the SMA could not be observed. As enhanced abdominal CT showed that the main trunk of the SMA was circumferentially involved in the collapsing tumor, prophylactic stent placement would be one of the choices of treatment. Previously, Nakai et al. [8] reported that a self-expanding bare metal stent and stent graft were successfully used to repair an SMA pseudoaneurysm and dissection after pancreaticoduodenectomy (PD). However, the possibility of graft infection should be considered even after successful hemostasis with stent placement [9].

Intra-aortic balloon occlusion (IABO) has been reported to be very useful in the case of hemorrhagic shock associated with abdominal or pelvic trauma [10]. IABO can block blood flow below the inflatable balloon and maintain central arterial pressure. In our case, after IABO above the bifurcation of the celiac artery, massive bleeding was effectively stopped. Few authors have reported the usefulness of IABO in temporary hemostasis for gastrointestinal bleeding [11–13]. We should keep in mind that long occlusion time is associated with abdominal organ ischemia and reperfusion injury.

Surgical hemostasis including PD is highly controversial. Z'graggen et al. [14] reported that emergency PD could be considered in the case of repetitive nontraumatic bleeding that required massive transfusion, unless the coagulation disorder showed progression. Lissidini et al. [15] suggested that emergency PD could be an effective life-saving operation for pancreaticoduodenal trauma, perforations, and bleeding. However, this approach should be performed in a high-volume center by surgeons with a high level of experience in hepatobiliary and pancreatic surgery. We did not perform emergency PD because the pancreatic cancer appeared to be anatomically and oncologically unresectable.

In conclusion, pancreatic cancer rarely causes disastrous bleeding. As the presence of air bubbles and vascular involvement may indicate an impending catastrophe, prophylactic stent placement can be considered as a treatment option. Additionally, IABO appeared to be useful for uncontrollable gastrointestinal bleeding.

Statement of Ethics

The authors have no ethical conflicts to disclose.

Disclosure Statement

The authors have no conflicts of interest to declare.

References

- Lee P, Sutherland D, Feller ER. Massive gastrointestinal bleeding as the initial manifestation of pancreatic carcinoma. *Int J Pancreatol*. 1994 Jun;15:223–7.
- Sharon P, Stalnikovic R, Rachmilewitz D. Endoscopic diagnosis of duodenal neoplasms causing upper gastrointestinal bleeding. *J Clin Gastroenterol*. 1982 Feb;4(1):35–8.
- Lin YH, Chen CY, Chen CP, Kuo TY, Chang FY, Lee SD. Hematemesis as the initial complication of pancreatic adenocarcinoma directly invading the duodenum: a case report. *World J Gastroenterol*. 2005 Feb;11(5):767–9.
- Tomita H, Osada S, Matsuo M, Shimokawa K. Pancreatic cancer presenting with hematemesis from directly invading the duodenum: report of an unusual manifestation and review. *Am Surg*. 2006 Apr;72(4):363–6.
- Takada R, Ioka T, Sueyoshi H, Ishida N, Yamai T, Fukutake N et al. Duodenal Hemorrhage from Pancreatic Cancer Infiltration Controlled through Combination Therapy with Gemcitabine and S-1. *Case Rep Gastroenterol*. 2014 Jun;8(2):221–6.
- Hoshimoto S, Aiura K, Shito M, Kakefuda T, Sugiura H. Successful resolution of a hemorrhagic pancreatic pseudocyst ruptured into the stomach complicating obstructive pancreatitis due to pancreatic cancer: a case report. *World J Surg Oncol*. 2016 Feb;14(1):46.
- Han B, Song ZF, Sun B. Hemosuccus pancreaticus: a rare cause of gastrointestinal bleeding. *Hepatobiliary Pancreat Dis Int*. 2012 Oct;11(5):479–88.
- Nakai M, Sato H, Sato M, Ikoma A, Sanda H, Nakata K et al. Endovascular stenting and stent-graft repair of a hemorrhagic superior mesenteric artery pseudoaneurysm and dissection associated with pancreaticoduodenectomy. *J Vasc Interv Radiol*. 2012 Oct;23(10):1381–4.

- 9 Suzuki K, Mori Y, Komada T, Matsushima M, Ota T, Naganawa S. Stent-graft treatment for bleeding superior mesenteric artery pseudoaneurysm after pancreaticoduodenectomy. *Cardiovasc Intervent Radiol*. 2009 Jul;32(4):762–6.
- 10 Martinelli T, Thony F, Decléty P, Sengel C, Broux C, Tonetti J et al. Intra-aortic balloon occlusion to salvage patients with life-threatening hemorrhagic shocks from pelvic fractures. *J Trauma*. 2010 Apr;68(4):942–8.
- 11 Karkos CD, Bruce IA, Lambert ME. Use of the intra-aortic balloon pump to stop gastrointestinal bleeding. *Ann Emerg Med*. 2001 Sep;38(3):328–31.
- 12 Hill SJ, Zarroug AE, Ricketts RR, Veeraswamy R. Bedside placement of an aortic occlusion balloon to control a ruptured aorto-esophageal fistula in a small child. *Ann Vasc Surg*. 2010 Aug;24(6):822.e7–9.
- 13 Shigesato S, Shimizu T, Kittaka T, Akimoto H. Intra-aortic balloon occlusion catheter for treating hemorrhagic shock after massive duodenal ulcer bleeding. *Am J Emerg Med*. 2015 Mar;33(3):473.e1–2.
- 14 Z'graggen K, Strobel O, Schmied BM, Zimmermann A, Büchler MW. Emergency pancreatoduodenectomy in nontrauma patients. *Pancreas*. 2002 Apr;24(3):258–63.
- 15 Lissidini G, Prete FP, Piccinni G, Gurrado A, Giungato S, Prete F, Testini M. Emergency pancreaticoduodenectomy: When is it needed? A dual non-trauma centre experience and literature review. *Int J Surg*. 2015 Sept;21(suppl 1):S83–8.

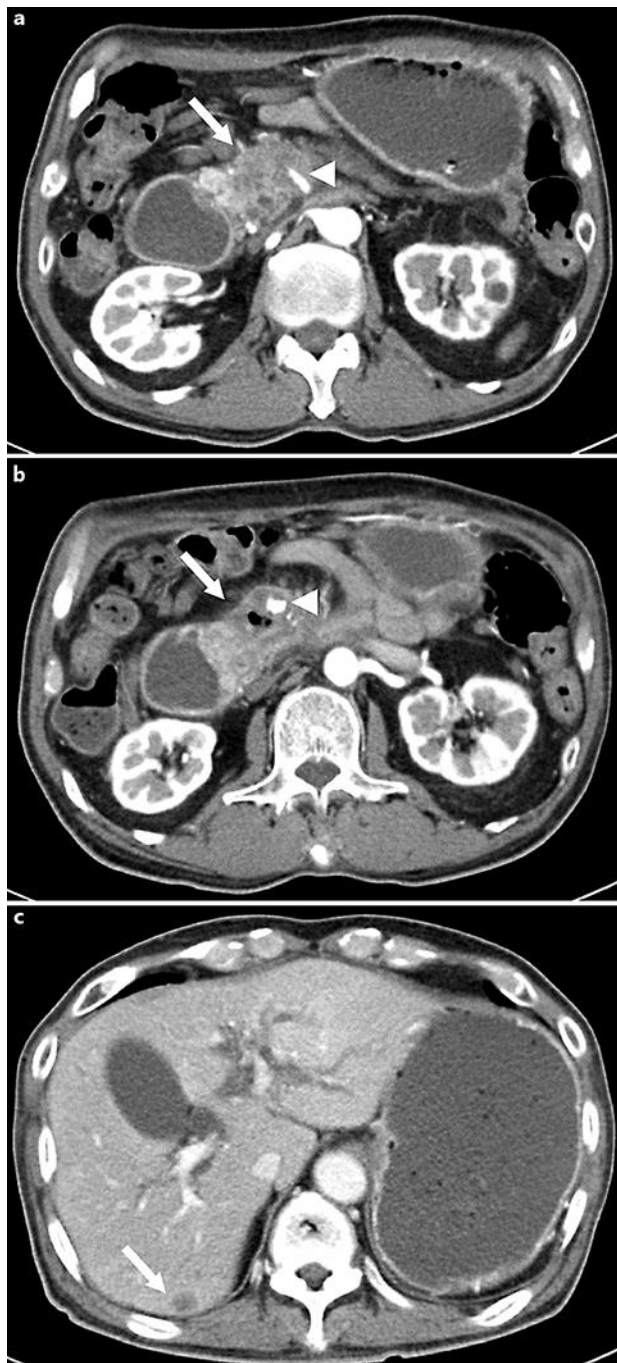


Fig. 1. **a** Enhanced CT shows the hypovascular tumor (arrow) in the uncinate process of the pancreas and dilatation of the stomach and duodenum. The main trunk of the superior mesenteric artery (SMA; arrowhead) is involved in the tumor. **b** The pancreatic tumor shows air bubbles (arrow). The main SMA trunk (arrowhead) is circumferentially involved in the collapsing tumor. **c** An intrahepatic low-density lesion, highly suspected to be a metastatic tumor (arrow), and dilatation of the intrahepatic bile ducts are seen.

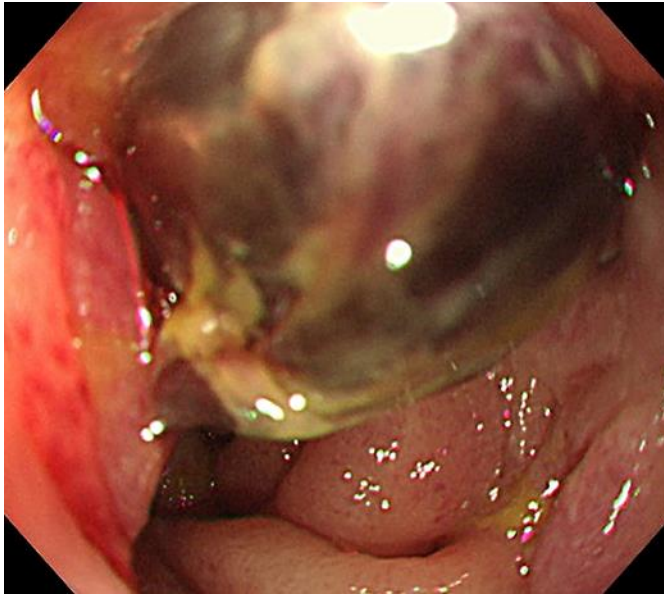


Fig. 2. Gastroduodenoscopy shows deep ulcer with pulsating vessels containing a clot in the third portion of the duodenum.

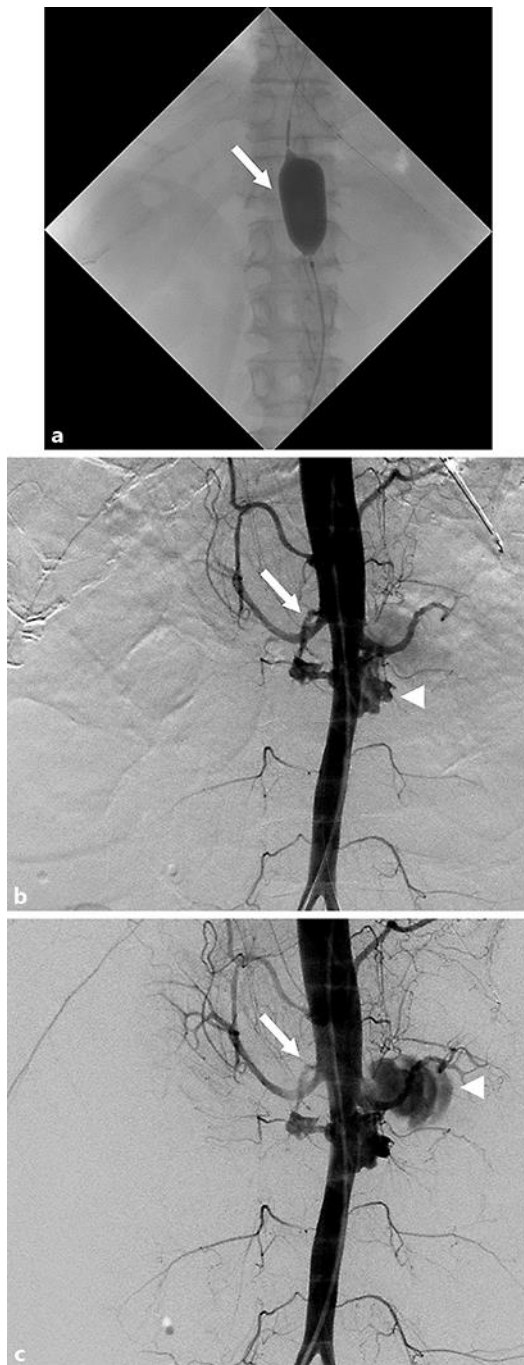


Fig. 3. **a** An intra-aortic balloon catheter is placed above the bifurcation of the celiac artery (arrow). A nasogastric tube is placed in the stomach. **b, c** Aortography shows direct communication between the main trunk of the SMA (arrow) and the inner cavity of the duodenum (arrowhead).