

This article is licensed under the Creative Commons Attribution-NonCommercial 4.0 International License (CC BY-NC) (<http://www.karger.com/Services/OpenAccessLicense>). Usage and distribution for commercial purposes requires written permission.

## Case and Review

# Ischemic Duodenal Ulceration after Transarterial Chemoembolization for Hepatocellular Carcinoma: A Case Report

Natascha Roehlen Richard F. Knoop Katharina Laubner  
Jochen Seufert Henning Schwacha Robert Thimme Andreas Fischer

Department of Medicine II, University Hospital of Freiburg, Faculty of Medicine, University of Freiburg, Freiburg, Germany

## Keywords

Hepatocellular carcinoma · Transarterial chemoembolization · Gastrointestinal ischemia · Duodenal ulceration · Esophagogastroduodenoscopy

## Abstract

Drug-eluting bead transarterial chemoembolization (DEB-TACE) is a well-established, minimally invasive interventional treatment for nonresectable hepatocellular carcinoma (HCC). Generally, TACE is regarded as safe and effective with a low complication rate. However, remote gastrointestinal ischemia due to the carryover of embolic material into visceral arteries is a rare but serious complication of TACE. In this report, we present a case of duodenal ulceration with contained perforation and severe necrotizing pancreatitis after TACE in a patient with nonresectable HCC and underlying hepatitis C virus associated with Child-Pugh stage B liver cirrhosis. This patient showed, for the first time, complete endoscopic and clinical recovery within 2 months of conservative treatment. Considering the high mortality rate from surgical intervention in all previously reported patients, the significant recovery potential demonstrated by our case suggests conservative treatment with antibiotics and parenteral nutrition combined with close clinical, radiological, and endoscopic monitoring should be considered in all clinically stable patients without signs of peritonism or septic sequelae.

© 2018 The Author(s)  
Published by S. Karger AG, Basel

## Introduction

Malignant primary tumors of the liver are the sixth most common type of cancer worldwide with hepatocellular carcinoma (HCC) being the most frequent histological identity [1]. Despite the availability of screening methods by ultrasound and  $\alpha$ -fetoprotein (AFP) measurements, most HCCs are diagnosed at stages ineligible for surgical resection or liver transplantation. Per the American Association for the Study of Liver Diseases (AASLD) and the European Association for the Study of the Liver (EASL) guidelines, the first-line treatment for unresectable, intermediate-stage HCC is transarterial chemoembolization (TACE) [2].

TACE mediates locoregional cytotoxic and ischemic effects on tumor tissue by selective arterial injection of chemotherapeutic agents followed by embolizing the respective arterial vessel. The obtained tumor tissue necrosis is reported to enable tumor downstaging and significantly improve patients' overall survival [3]. One of the latest methodological developments is drug-eluting bead transarterial chemoembolization (DEB-TACE), which enables controlled release of chemotherapeutic agents at the tumor site, minimizing systemic adverse effects [4]. Side effects of TACE are common in postembolic syndrome, with fever, abdominal pain, and nausea being the most common and occurring in up to 90% of cases [5]. However, major complications leading to prolonged inpatient stays, surgical interventions, or even death have a low incidence rate of approximately 2% [6].

In addition to liver abscess and rupture, remote gastrointestinal ischemia due to carryover of embolic material into the visceral arteries is a rare but serious complication of TACE. Thus, inadvertent gastrointestinal vessel embolization may lead to necrotizing pancreatitis and duodenal ulceration or perforation [7, 8]. To date, only 3 cases of duodenal perforations after DEB-TACE have been reported in the literature [8–10]. However, the application of surgical procedures in all reported cases as well as a mortality rate of 33% emphasize their clinical relevance [8–10]. This case report presents the first duodenal ulceration with contained juxtapapillary perforation after TACE with complete endoscopic and clinical recovery within 2 months of conservative treatment.

## Case Presentation

A 72-year-old woman was admitted to the hospital for a first TACE of an HCC (size 5 × 6 cm) in the right liver lobe and underlying hepatitis C virus-associated Child-Pugh stage B liver cirrhosis. DEB-TACE was performed via the right-sided transfemoral approach without signs of immediate periprocedural complications (embolization volume: 2 × 2 mL). Over the following days, the patient complained of mild abdominal pain that was first interpreted as a postembolic syndrome and treated symptomatically with intravenous analgesics. However, at day 4, the patient developed melena, and a subsequent esophagogastroduodenoscopy revealed severe ischemic duodenal ulcerations without objectives for endoscopic intervention (Fig. 1a). At this time, endoscopic examination could exclude duodenal perforation. Biopsies for histological verification of ischemic etiology were waived due to the high risk of iatrogenic perforation. Pre-existing duodenal ulceration seemed unlikely, since the esophagogastroduodenoscopy, performed only 4 weeks prior, showed unsuspecting upper gastrointestinal tract mucosa. Abdominal computed tomography (CT) further revealed severe necrotizing pancreatitis (Fig. 1b, c). CT-angiography displayed normally perfused visceral vessels, suggesting temporal arterial occlusion by inadvertent carryover embolization during TACE (Fig. 1d). The patient was subfebrile (37.7°C) and blood tests showed elevated inflammatory parameters

(C-reactive protein: 36 mg/dL; procalcitonin: 0.18 ng/mL), while serum pancreatic enzymes surprisingly remained normal (lipase: 32 U/L; amylase: 34 U/L). Intravenous fluid supplementation and antibiotic therapy (ciprofloxacin i.v. at 400 mg t.i.d.) was administered combined with close clinical monitoring. Fortunately, the melena stopped spontaneously 3 days after endoscopic diagnosis and hemoglobin remained stable at 12 g/dL.

However, 8 days after first diagnosis of ischemic duodenal ulceration, the patient complained of strong abdominal pain in the upper right quadrant. The immediately performed abdominal CT scan showed prominent air trapping between the necrotic head of the pancreas and the duodenum, indicating contained juxtapapillary perforation (Fig. 2). Due to the suspected risk of enlargement of the perforation size by air insufflation, we decided not to investigate the contained juxtapapillary perforation by esophagogastroduodenoscopy. After consultation with the attending surgeons, we decided to pursue a conservative approach in accordance with the patient's and her family's request. Otherwise the required surgical approach would have involved pancreaticoduodenectomy with a high perioperative risk in this patient with Child-Pugh class B liver cirrhosis. Thus, total parenteral nutrition was started and antibiotics were escalated to meropenem 1 g t.i.d. Over the following days, the patient's pain was well controlled by intravenous treatment with non-opioid and opioid analgesics and the patient remained stable. After 2 weeks, by the time inflammation markers slowly started falling, a stepwise progression to a normal oral diet could be started. Three weeks after TACE, the patient was discharged, and antibiotic therapy was deescalated to ciprofloxacin at 500 mg b.i.d. Six weeks later, esophagogastroduodenoscopy showed complete remission with only residual granulation tissue and scarring indicating the former ulceration (Fig. 3a). CT scan revealed complete morphological remission of pancreatitis signs (Fig. 3b). During 6 months of follow-up, the patient remained asymptomatic. Since the HCC decreased to a size <5 cm, the patient is currently under consideration for surgical resection.

## Discussion

HCC is a common malignancy worldwide. This carcinoma typically occurs in patients with chronic liver diseases and has a current incidence rate of >700,000 per year [11]. Based on tumor size, liver function (Child-Pugh score), and performance status, the Barcelona Clinic Liver Cancer (BCLC) classification allocates all HCCs into 5 stages with different recommendations for first-line treatment [12]. Per this classification, the patient's HCC in the presented case was categorized as a nonresectable HCC of BCLC stage B. TACE is the first-line therapy for nonresectable HCC. Thus, defined as a palliative therapeutic option, TACE has shown to significantly prolong overall survival [13]. Moreover, locoregional tumor therapy by TACE can be used to bridge or downstage patients awaiting liver transplantation [14]. If patient selection is appropriate, TACE is regarded as a safe and effective minimally invasive therapeutic option [4]. The incidence rate of severe complications is low and ranges from 0.5% [15] to 2.68% [10] per TACE.

Tu et al. [6] identified liver rupture, liver abscess, femoral arterial pseudoaneurysm, cholecystitis, biloma, and pulmonary embolism as the most common severe complications of TACE. Ischemic complications, encompassing spinal cord ischemia [16], esophageal ischemia [8], ischemic cholecystitis, and bile duct necrosis [17], as well as ischemia near the gastroduodenal arterial supply [7, 8], are rare but can be severe and accompanied by a high mortality rate. The dominating symptoms in all cases were abdominal pain and fever that mostly oc-

curred within 2 weeks after intervention [6]. Since these symptoms are present in most patients after TACE as part of the postembolic syndrome [5], close clinical monitoring is needed to differentiate them from the severe complications. Thus, any abdominal pain progress or deterioration in general condition should lead to further laboratory and radiological diagnostics to identify potential indications for intervening or escalating conservative therapy.

In the presented case, the increased abdominal pain and occurrence of melena led to an esophagogastroduodenoscopy and abdominal CT, which generated the diagnoses of ischemic duodenal ulceration and necrotic pancreatitis. Even if CT-angiography showed proper gastrointestinal vessel perfusion, gastroduodenal ulcers showed typical signs of ischemic etiology, and all affected parenchymal regions belonged to the area supplied by the gastroduodenal artery. The gastroduodenal artery arises from the common hepatic artery, close to the injection site of embolic material during TACE. Consequently, chemoembolic material that dislocated into the gastroduodenal artery may have caused transient ischemia of the pancreas and duodenum.

Acute ischemic pancreatitis after TACE is a relatively frequent complication with an incidence rate of 7.6% per procedure [18]. While some authors hypothesize that anatomic variations cause ischemic complications [7], focused analyses have only identified high embolization volumes (>2 mL), high procedural frequencies, and the non-supraselective method of TACE as risk factors for postinterventional acute ischemic pancreatitis [18, 19]. Our patient had none of these risk factors.

In line with the segregated affection of the pancreatic head in our case, the pancreaticoduodenal arteries that supply the pancreatic head originate from the gastroduodenal artery as terminal vessels, while the pancreatic body and tail are supplied by various gastrointestinal vessels [20]. These anatomic preconditions determine the pancreatic head as a region of susceptibility for ischemic changes.

Most cases of postinterventional ischemic pancreatitis are mild [7, 18]. However, the risk of complications such as partial necrosis [18], pseudocyst or abscess formation [21], and potentially fatal sepsis, especially when diagnosed at a late stage, underscores the importance of early diagnosis and differentiation from postembolic syndrome. Consequently, most authors recommend measuring lipase and/or amylase in all patients with postinterventional abdominal pain [16, 18, 19]. However, normal serum amylase and lipase levels in our patient with severe necrotizing pancreatitis indicate the need for radiological tools to exclude ischemic pancreatitis after TACE. Thus, according to the revised Atlanta classification, diagnosis of acute pancreatitis can be made if only 2 of the following 3 features are present: abdominal pain, consistent with acute pancreatitis; increase of serum lipase of at least 3 times greater than the upper limit of normal range; and/or characteristic radiological findings [22].

The therapeutic management is equivalent to treating nonischemic pancreatitis, which includes analgesia, intravenous fluid supplementation, antibiotic therapy in cases of necrosis, and rare interventions in cases of pseudocysts or walled-off necrosis [23]. In our case, conservative treatment led to rapidly decreased abdominal pain and clinical signs of pancreatic inflammation.

To our knowledge, duodenal ulceration after DEB-TACE has been reported only 6 times in the literature [8–10, 24–26]. In contrast to previous reports, our case found that esophagogastroduodenoscopy only 4 weeks before TACE excluded pre-existing duodenal mucosal defects, indicating its ischemic etiology, likely due to embolic material reflux into the supplying vessels. As demonstrated by our case and strengthened by the rate of 50% in the literature [8–10], ischemic duodenal ulcerations after TACE are at high risk of perforation. Considering the high mortality of perforated duodenal ulcers of other etiology, this may be the reason why

all patients, reported in the literature, underwent surgery. However, only recently, Kim et al. [8] reported an almost complete recovery of perforated ischemic duodenal ulceration after TACE within 11 days prior to surgical intervention.

Dual supply of the duodenal wall with blood from the gastroduodenal and pancreaticoduodenal arteries may be the reason for the high recovery potential in ischemic duodenal ulcers [8]. Consequently, CT-angiography, enabling visualization of the gastrointestinal arterial perfusion, should be considered in all patients with this rare complication to exclude anatomic variations or persistent arterial obliteration and to assess the spontaneous healing potential.

Based on the suggested high recovery potential in our patient with verified regained intestinal perfusion, we decided to pursue a conservative concept since surgical intervention would have been accompanied by an extremely high perioperative risk in our patient with Child-Pugh B liver cirrhosis and current poor general condition. Conservative treatment hereby involved total parenteral nutrition, antibiotics, intravenous opioid analgesics as well as frequent clinical and laboratory monitoring.

The patient's condition improved, and endoscopy showed complete recovery with only residual granulation 2 months later. To the best of our knowledge, this report is the first to describe a patient with TACE-associated duodenal perforation and necrotizing pancreatitis with complete clinical, endoscopic, and radiological recovery within 2 months of conservative treatment.

### Conclusions

This case demonstrates the potential for recovery from severe ischemic duodenal ulceration and necrotizing pancreatitis after TACE, suggesting that conservative treatment with antibiotics and parenteral nutrition combined with close clinical, radiological, and endoscopic monitoring should be considered in all clinically stable patients without signs of peritonism or septic sequelae.

### Statement of Ethics

The patient gave her written consent to publish this case report.

### Disclosure Statement

All authors declare no conflicts of interest.

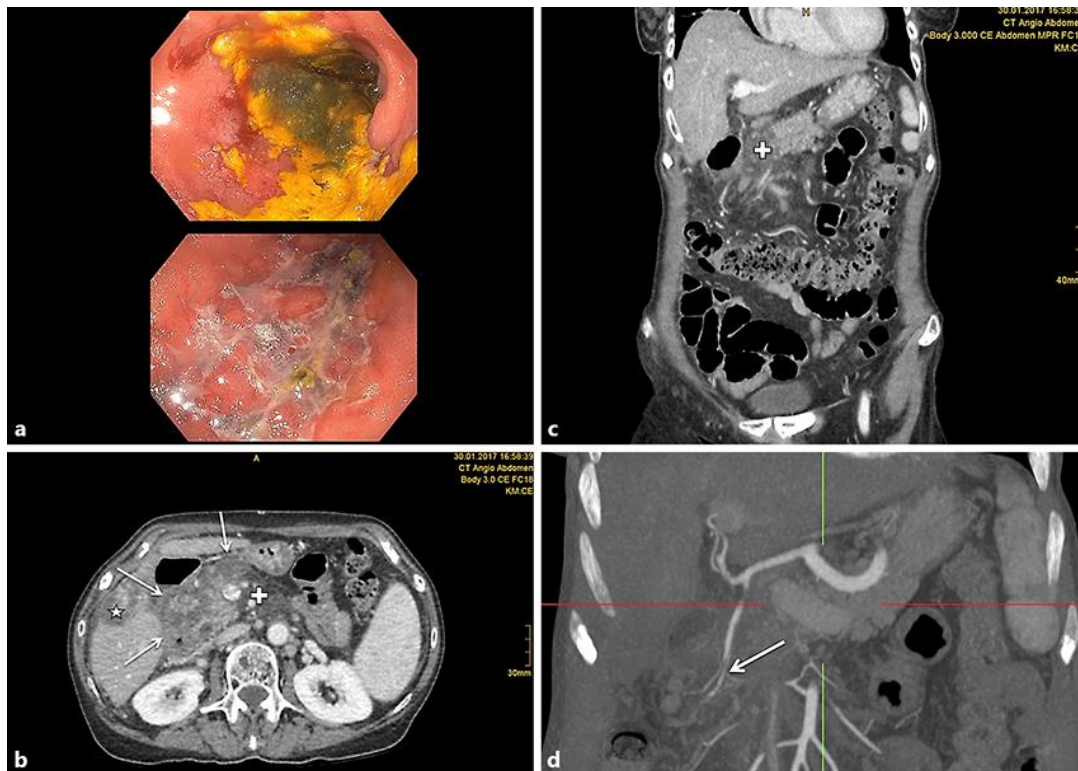### Funding Sources

This work was funded by the authors' institutions.

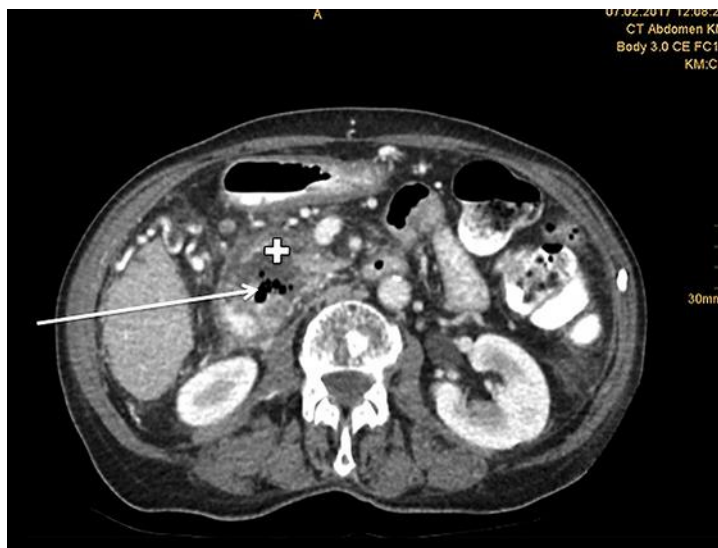## References

- Jemal A, Bray F, Center MM, Ferlay J, Ward E, Forman D. Global cancer statistics. *CA Cancer J Clin*. 2011 Mar-Apr;61(2):69–90.
- Bruix J, Sherman M; American Association for the Study of Liver Diseases. Management of hepatocellular carcinoma: an update. *Hepatology*. 2011 Mar;53(3):1020–2.
- Lo CM, Ngan H, Tso WK, Liu CL, Lam CM, Poon RT, et al. Randomized controlled trial of transarterial lipiodol chemoembolization for unresectable hepatocellular carcinoma. *Hepatology*. 2002 May;35(5):1164–71.
- Facciorusso A, Licinio R, Muscatiello N, Di Leo A, Barone M. Transarterial chemoembolization: evidences from the literature and applications in hepatocellular carcinoma patients. *World J Hepatol*. 2015 Aug;7(16):2009–19.
- Leung DA, Goin JE, Sickles C, Raskay BJ, Soulen MC. Determinants of postembolization syndrome after hepatic chemoembolization. *J Vasc Interv Radiol*. 2001 Mar;12(3):321–6.
- Tu J, Jia Z, Ying X, Zhang D, Li S, Tian F, et al. The incidence and outcome of major complication following conventional TAE/TACE for hepatocellular carcinoma. *Medicine (Baltimore)*. 2016 Dec;95(49):e5606.
- Krishnamurthy P, Brown M, Agrawal S, Short RF. Acute pancreatitis as a complication of trans-arterial chemoembolization of hepatocellular cancer—case report and review of literature. *J Gastrointest Oncol*. 2017 Feb;8(1):E26–30.
- Kim SI, Jin YJ, Cho SG, Shin WY, Kim JM, Lee JW. Duodenal perforation and esophageal ischemia following transarterial chemoembolization for hepatocellular carcinoma: A case report. *Medicine (Baltimore)*. 2016 Jul;95(27):e3987.
- Musumba C, Evans J, Richardson P. Persistent abdominal pain and pyrexia after combined radiofrequency ablation and TACE. *Gastroenterology*. 2011 Dec;141(6):1976, 2277.
- Xia J, Ren Z, Ye S, Sharma D, Lin Z, Gan Y, et al. Study of severe and rare complications of transarterial chemoembolization (TACE) for liver cancer. *Eur J Radiol*. 2006 Sep;59(3):407–12.
- Forner A, Llovet JM, Bruix J. Hepatocellular carcinoma. *Lancet*. 2012 Mar;379(9822):1245–55.
- Llovet JM, Brú C, Bruix J. Prognosis of hepatocellular carcinoma: the BCLC staging classification. *Semin Liver Dis*. 1999;19(3):329–38.
- Pecorelli A, Lenzi B, Gramenzi A, Garuti F, Farinati F, Giannini EG, et al.; Italian LiverCancer (ITA.LI.CA) group. Curative therapies are superior to standard of care (transarterial chemoembolization) for intermediate stage hepatocellular carcinoma. *Liver Int*. 2017 Mar;37(3):423–33.
- Kulik L, Heimbach JK, Zaiem F, Almasri J, Prokop LJ, Wang Z, et al. Therapies for patients with hepatocellular carcinoma awaiting liver transplantation: A systematic review and meta-analysis. *Hepatology*. 2018 Jan;67(1):381–400.
- Takayasu K, Arii S, Ikai I, Omata M, Okita K, Ichida T, et al.; Liver Cancer Study Group of Japan. Prospective cohort study of transarterial chemoembolization for unresectable hepatocellular carcinoma in 8510 patients. *Gastroenterology*. 2006 Aug;131(2):461–9.
- Bazine A, Fetohi M, Berri MA, Essaadi I, Elbakraoui K, Ichou M, et al. Spinal cord ischemia secondary to transcatheter arterial chemoembolization for hepatocellular carcinoma. *Case Rep Gastroenterol*. 2014 Sep;8(3):264–9.
- Tarazov PG, Polysalov VN, Prozorovskij KV, Grishchenkova IV, Rozengauz EV. Ischemic complications of transcatheter arterial chemoembolization in liver malignancies. *Acta Radiol*. 2000 Mar;41(2):156–60.
- López-Benítez R, Radeleff BA, Barragán-Campos HM, Noeldge G, Grenacher L, Richter GM, et al. Acute pancreatitis after embolization of liver tumors: frequency and associated risk factors. *Pancreatology*. 2007;7(1):53–62.
- Khan KN, Nakata K, Shima M, Kusumoto Y, Ishii N, Koji T, et al. Pancreatic tissue damage by transcatheter arterial embolization for hepatoma. *Dig Dis Sci*. 1993 Jan;38(1):65–70.
- Kimura W. [Anatomy of the head of the pancreas and various limited resection procedures for intraductal papillary-mucinous tumors of the pancreas]. *Nihon Geka Gakkai Zasshi*. 2003 Jun;104(6):460–70. Japanese.
- Bae SI, Yeon JE, Lee JM, Kim JH, Lee HJ, Lee SJ, et al. A case of necrotizing pancreatitis subsequent to transcatheter arterial chemoembolization in a patient with hepatocellular carcinoma. *Clin Mol Hepatol*. 2012 Sep;18(3):321–5.
- Banks PA, Bollen TL, Dervenis C, Gooszen HG, Johnson CD, Sarr MG, et al.; Acute Pancreatitis Classification Working Group. Classification of acute pancreatitis—2012: revision of the Atlanta classification and definitions by international consensus. *Gut*. 2013 Jan;62(1):102–11.
- Crockett SD, Wani S, Gardner TB, Falck-Ytter Y, Barkun AN, Crockett S, et al.; American Gastroenterological Association Institute Clinical Guidelines Committee. American Gastroenterological Association Institute Guideline on Initial Management of Acute Pancreatitis. *Gastroenterology*. 2018 Mar;154(4):1096–101.
- Chintalapati SP, Patel A, Conjeevaram H. Gastric and duodenal ischaemia after transarterial chemoembolisation for hepatocellular carcinoma: an unexpected but significant complication. *BMJ Case Rep*. 2018 Feb;2018:bcr-2017-223339.

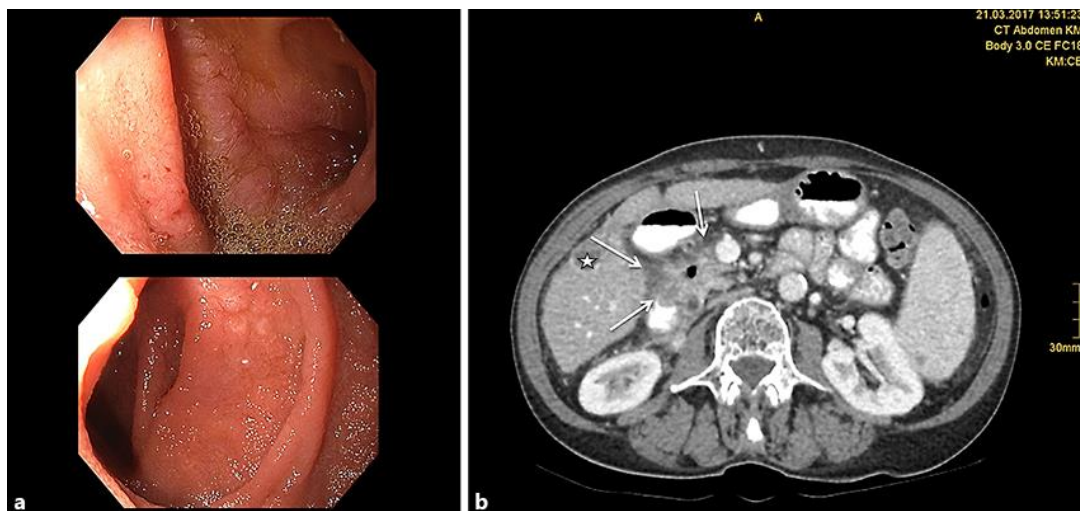
- 25 Kim YW, Kwon JH, Nam SW, Jang JW, Jung HS, Shin YR, et al. Sustained multiple organ ischaemia after transarterial chemoembolization with drug-eluting beads for hepatocellular carcinoma. *Exp Ther Med*. 2018 Feb;15(2):1479–83.
- 26 Jang ES, Jeong SH, Kim JW, Lee SH, Yoon CJ, Kang SG. A case of acute ischemic duodenal ulcer associated with superior mesenteric artery dissection after transarterial chemoembolization for hepatocellular carcinoma. *Cardiovasc Intervent Radiol*. 2009 Mar;32(2):367–70.



**Fig. 1.** **a** Esophagogastroduodenoscopy 4 days after DEB-TACE revealed severe duodenal ulceration particularly near the duodenal bulb. Endoscopy revealed no signs of acute bleeding. The localization and close temporal relation between the clinical symptoms and the intervention implied the ulceration was ischemic and caused by inadvertent carryover gastrointestinal vessel embolization during TACE. Due to the high risk of perforation, biopsies for histological verification of ischemic etiology were waived. **b** Contrast-enhanced abdominal CT-angiography was performed subsequent to the endoscopic diagnosis of severe duodenal ulceration. Apart from inflammatory alterations of the duodenal wall, the CT scan revealed severe necrotizing pancreatitis of the pancreatic head and at the transition to the pancreas corpus. There were no radiological signs of bacterial superinfection or perforation. Asterisk: necrotic HCC; arrows: ischemic duodenum after TACE; cross: necrotic pancreas after TACE. **c** Hypodense presentation of the pancreatic head by contrast-enhanced abdominal CT indicated necrotizing pancreatitis after TACE. Cross: necrotic pancreas after TACE. **d** Frontal section of abdominal CT-angiography with adequate perfusion of the superior and inferior pancreaticoduodenal arteries. Arrow: superior pancreaticoduodenal artery; red line: horizontal axis; green line: longitudinal axis.



**Fig. 2.** Eight days after first diagnosis of ischemic duodenal ulceration, the patient complained of strong abdominal pain in the upper right quadrant and a CT scan was performed immediately. Newly occurred prominent air trapping in the area between the pancreatic head and the duodenum indicated contained juxtapapillary perforation. Since the patient remained stable, the authors decided not to investigate the contained perforation endoscopically due to the suspected risk of enlargement of the perforation size by air insufflation during the examination. Cross: area between pancreatic head and duodenum; arrow: air trapping indicating juxtapapillary perforation.



**Fig. 3. a** After 6 weeks of medical treatment, including 2 weeks of total parenteral nutrition and 4 weeks of antibiotic therapy, elective esophagogastroduodenoscopy was performed to assess the therapeutic response. Endoscopic examination showed complete remission of the duodenal ulceration with residual granulation tissue and scarring. **b** Abdominal CT scan 6 weeks after TACE showed complete morphological remission of the pancreas and duodenal wall. Asterisk: necrotic HCC; cross: residuum of air after necrotizing pancreatitis; arrows: recovered duodenum after ischemia.