

UPPER LIMB REVASCULARIZATION WITH REVERSED VEIN GRAFT AND MICROVASCULAR ANASTOMOSES AFTER BRACHIAL ARTERY ANEURYSM RESECTION IN A CHILD WITH TUBEROUS SCLEROSIS

Ciro Paz Portinho¹, Joel Alex Longhi², Carlos Francisco Jungblut¹, Clara Belle Manfroí Galinatti², Sérgio Ventura Gomes Júnior², Adamastor Humberto Pereira², Marcus Vinícius Martins Collares¹, Amanda Prestes Valente³, Adriana Muradás Girardi³

ABSTRACT

The authors present an unusual case of a 3-year-old girl who was diagnosed with a fast-growing brachial aneurysm due to tuberous sclerosis. The patient underwent aneurysm resection and microsurgical reconstruction with reversed greater saphenous vein graft at the same time. She had a favorable outcome, without neuromuscular deficits. Doppler ultrasonography was performed for diagnosis, vein graft selection, and postoperative follow-up. The authors believe that such combined approach may be the routine for pediatric vascular reconstructions. Finally, this reconstruction has been rarely reported in tuberous sclerosis patients.

Keywords: *Tuberous sclerosis; upper limb aneurysm; microsurgery; vein graft*

The reconstruction of major arteries in small children is unusual and may be challenging^{1,2}. This is because the caliber of these arteries may not allow for conventional vascular interventions, which may lead to the need for microvascular anastomoses requiring a combined team approach.

The purpose of this article was to report the successful microsurgical reconstruction of brachial artery after aneurysm resection in a 3-year-old girl with tuberous sclerosis.

CASE REPORT

A 3-year-old girl presented to the vascular surgery team with a pulsatile mass in the left upper limb, in the transition between axilla and arm (figure 1). The mass had appeared a few months before that medical consultation and had grown rapidly. The patient had a previous diagnosis of tuberous sclerosis, with a history of seizures totally controlled with anticonvulsant therapy, and hypochromic spots through the trunk skin. Doppler ultrasonography was performed right at that first consultation (figure 2) and diagnosed an arterial aneurysm in the transition between left axillary and brachial arteries (predominantly affecting the latter), sizing 3.6 cm in diameter. Since the brachial artery had no more than 3 mm in diameter, conventional vascular reconstruction could be difficult or impossible to be performed. Thus, the vascular surgery team contacted the microsurgery team (plastic surgery) in order to arrange a combined surgery, including aneurysmectomy and artery reconstruction by microvascular anastomosis. On the scheduled day, the patient was anesthetized, and before starting surgery in the upper limb, a Doppler ultrasonography was made to select the donor vein. Right great saphenous vein was chosen because it was wider and longer than basilic, brachial or contralateral saphenous veins.

We used a combined approach in the upper limb. A lazy-S incision was made in the arm and a W-shaped incision was made in the axilla. The venous

Clin Biomed Res. 2015;35(2):116-119

1 Microsurgery Team, Plastic Surgery Department, Hospital de Clínicas de Porto Alegre. Porto Alegre, RS, Brazil.

2 Vascular Surgery Department, Hospital de Clínicas de Porto Alegre. Porto Alegre, RS, Brazil.

3 Medical School, Universidade Federal do Rio Grande do Sul (UFRGS). Porto Alegre, RS, Brazil.

Corresponding author:

Ciro Paz Portinho
E-mail: cportinho@hotmail.com
Hospital de Clínicas de Porto Alegre
Rua Ramiro Barcelos, 2350/600E.
90035-903, Porto Alegre, RS, Brazil.

plexus in the cubital region should be preserved, especially the basilic vein, which may be used as a graft. The brachial artery is in the next layer, just deep to the venous plexus. It is medial to the biceps tendon and lateral to the median nerve covered by lacertus fibrosus at the cubital region. The median nerve runs parallel and medial to the brachial artery in the arm and cubital region. In our patient, anatomy was distorted due to aneurysm growth. Therefore, we used a nerve stimulator to locate the nerves and prevent injury.

The brachial aneurysm was dissected from circumjacent structures. Reversed vein graft was placed over the aneurysm, so that we could estimate its necessary length. Systemic anticoagulation was initiated and soon after that clamps were placed, starting the ischemia period. Aneurysm was almost totally resected, and brachial artery ends were prepared for anastomosis.

The entire revascularization procedure was performed using an operating microscope with magnification ranging from $\times 8$ to $\times 20$. We performed end-to-end anastomosis with interrupted 9-0 nylon sutures in both extremities. Vascular spasm was controlled with topical application of papaverine (Dipaverine[®], 100 mg/2 mL, Geyer Lab., Porto Alegre, Brazil). Antibiotic prophylaxis was made with cefazolin 25 mg/kg (Kefazol[®], Eli Lilly Lab., São Paulo, Brazil). Heparin (Liquemine[®], Roche Lab., São Paulo, Brazil) was administered intraoperatively at a dose of 100 mL/kg and postoperatively as an intravenous continuous infusion of 10 IU/kg/h diluted in 0.6 to 24 mL of saline. Protamine was not used to reverse anticoagulation because of the risk of graft thrombosis.

Proximal anastomosis was performed firstly. Then, the proximal clamp was removed, in order to check for proximal anastomosis leakage and prevent vein twisting. Finally, reconstruction was completed with distal anastomosis. Reversed vein graft was repositioned in order to prevent kinking (figure 3). Total ischemia time was 72 minutes. Distal perfusion was satisfactory after clamp removal.

A suction drain was placed under the skin flaps, distant from the vascular reconstruction. Skin was closed loosely with absorbable sutures and a smooth gauze dressing was applied. Shoulder was immobilized with bandages in 60 degrees abduction. The surgical procedure lasted for about seven hours. A pathological examination of the dissected aneurysm of the left axillary artery wall showed degenerative and structural changes in blood vessel wall with the presence of hemorrhagic foci compatible with aneurysm formation.

The patient was transferred to the pediatric intensive care unit, where she stayed for five days. Mean

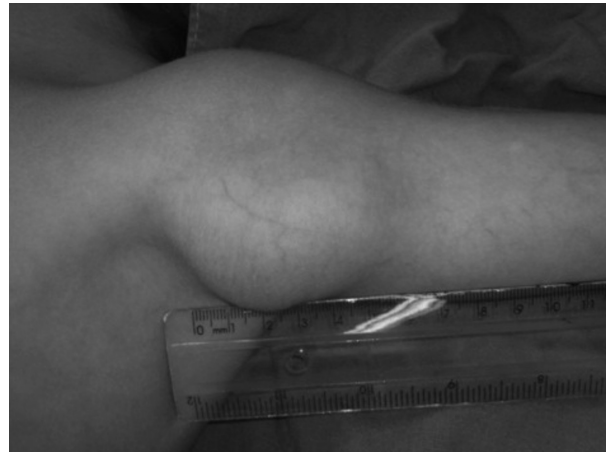


Figure 1: Preoperative picture of the left upper limb. The aneurysm presented more than five centimeters in length.

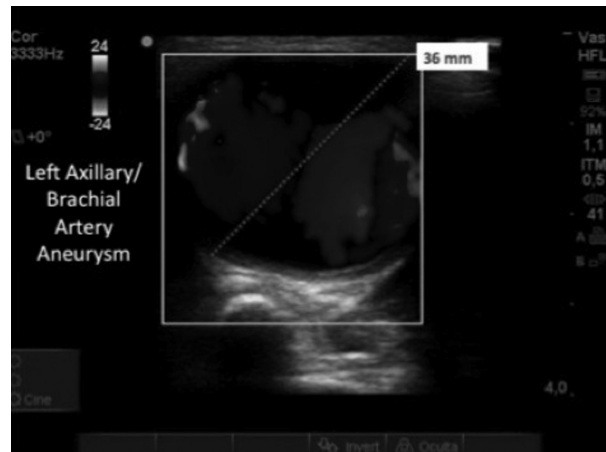


Figure 2: Preoperative Doppler ultrasonography showing an arterial aneurysm in the transition between left axillary and brachial arteries.




Figure 3: Intraoperative microscopic picture showing the anastomoses already finished. Vein graft (black arrows) was repositioned to prevent kinking.

arterial pressure was maintained above 60 mmHg. On the fourth postoperative day, immobilization was removed and shoulder was adducted. Another Doppler ultrasonography was performed before allowing the patient to move her operated limb, and no flow decrease was found in any position.

On the sixth postoperative day, the patient left the intensive care unit, and on the seventh day, she was discharged from hospital. She returned to the doctor's office weekly, and neither vascular nor healing problems were detected. During follow-up with the vascular surgery team, other Doppler examinations were performed, demonstrating an excellent blood flow two months after surgery.

The patient's parents signed an informed consent to authorize the surgical procedure. The patient identity was kept anonymous. The case has been included in a research protocol, which has been already approved by the ethics committee from our institution. This paper has no conflict of interest.

DISCUSSION

Tuberous sclerosis complex is a rare disorder of tissue growth and differentiation, with a prevalence of 7-12/100,000. It may occur sporadically or on a familial basis with autosomal dominant inheritance. Patients develop benign hamartomas in the brain and other organs³. Neurological presentation may involve seizures (more than 90% of cases) and progressive psychomotor retardation (more than 50% of cases). Associated abnormalities include retinal lesions and tumors, benign rhabdomyomas of the heart, lung cysts, benign tumors in the viscera, bone cysts, and aneurysms^{4,5}. Vascular manifestations are often extracranial, but intracranial aneurysms have been described⁶. Our patient had a fast-growing aneurysm that compromised both left axillary and brachial arteries and carried a moderate-to-high risk of rupture. As a consequence, severe hemorrhage, limb loss, and death could happen.

Publications about aneurysm reconstructions secondary to tuberous sclerosis are quite rare⁷. Brachial artery lesions are usually due to fractures, iatrogenesis, or tumors⁸. Artery reconstruction with the use of interposition grafts has rarely been undertaken in children because of the small size of

the involved vessels and the often severe underlying conditions¹. The goals of limb revascularization in the pediatric population include prevention of limb loss and preservation of long-term function².

Microsurgical reconstruction of brachial artery has been described in the treatment of injuries related to displaced supracondylar fracture humerus in children^{2,8}. Arteries as small as 0.5 mm in diameter have been successfully anastomosed during modern microsurgical reimplantation procedures or reconstruction procedures in children¹. We carefully prepared all the steps before the ischemia period in order to decrease its duration. We have also meticulously reviewed both anastomoses before opening the clamps, in order to prevent leakages.

Doppler ultrasonography has demonstrated to be useful in many ways. It diagnosed and allowed for the measurement of the aneurysm, demonstrated its growth, helped in selecting the larger vein graft, and was useful in the postoperative follow-up. Arteriography was used in the past but has the disadvantage of being invasive and not a dynamic test². Computer tomography is also an excellent option, but radiation exposure has been currently discussed, especially in the pediatric population. We highlight the use of Doppler ultrasonography in the surgical room to choose vein graft. Selecting the wider and longer vein may facilitate all the microsurgical steps and decrease discrepancy between native artery and vein graft.

The patient has presented no complications in a short follow-up. Nevertheless, such patients must be followed until adolescence, in order to look for limb-length discrepancies due to decreased limb growth¹. Additionally, tuberous sclerosis is a condition that predisposes to other aneurysm formations⁶.

CONCLUSION

Brachial artery reconstruction with reverse vein graft and microvascular anastomosis constitutes a feasible therapeutic option in the pediatric population. Especially for the presented case, it has been a successful choice for upper limb aneurysm due to tuberous sclerosis.

The partnership between vascular surgery and microsurgery teams may represent an important combination for pediatric vascular reconstructions.

REFERENCES

1. LaQuaglia MP, Upton J, May JW JR. Microvascular reconstruction of major arteries in neonates and small children. *J Pediatr Surg*. 1991;26(9):1136-40. [http://dx.doi.org/10.1016/0022-3468\(91\)90689-Q](http://dx.doi.org/10.1016/0022-3468(91)90689-Q). PMID:1941493.
2. Noaman HH. Microsurgical reconstruction of brachial artery injuries in displaced supracondylar fracture humerus in children. *Microsurgery*. 2006;26(7):498-505. <http://dx.doi.org/10.1002/micr.20277>. PMID:17001639.
3. Hunold A, Haueisen J, Ahtam B, Doshi C, Harini C, Camposano S, et al. Localization of the epileptogenic foci in tuberous sclerosis complex: a pediatric case report. *Front Human Neurosci*. 2014;8(175):1-12.

4. Ajay V, Singhal V, Venkateshwarlu V, Rajesh SM. Tuberos sclerotic with rhabdomyoma. *Indian J Hum Genet.* 2013;19(1):93-5. <http://dx.doi.org/10.4103/0971-6866.112912>. PMID:23901201.
5. Vergnani J, Graham JD. Renal angiomyolipomatosis in a patient with tuberous sclerosis complex. *J Am Osteopath Assoc.* 2013;113(1):104. PMID:23329808.
6. Yi JL, Galgano MA, Tovar-Spinoza Z, Deshaies EM. Coil embolization of an intracranial aneurysm in an infant with tuberous sclerosis complex: A case report and literature review. *Surg Neurol Int.* 2012;3(1):129. [cited 2012 Oct 27]. <http://dx.doi.org/10.4103/2152-7806.102944>. PMID:23227434.
7. Hite SH, Kuo JS, Cheng EY. Axillary artery aneurysm in tuberous sclerosis: cross-sectional imaging findings. *Pediatr Radiol.* 1998;28(7):554-6. <http://dx.doi.org/10.1007/s002470050412>. PMID:9662584.
8. Lewis HG, Morrison CM, Kennedy PT, Herbert KJ. Arterial reconstruction using the basilic vein from the zone of injury in pediatric supracondylar humeral fractures: a clinical and radiological series. *Plast Reconstr Surg.* 2003;111(3):1159-63, discussion 1164-6. <http://dx.doi.org/10.1097/01.PRS.0000046608.52722.89>. PMID:12621186.

Received: 02/19/2015

Accepted: 04/01/2015