

Case report



SNARE MANEUVER FOR MANAGEMENT OF LOW TAVI IMPLANTATION - CLINICAL CASE

Veselin Valkov¹, Dobrin Kalchev¹, Atanas Kostadinov¹, Yavor Kashlov², Branimir Kanazirev²

1) First Clinic of Cardiology, UMHAT St. Marina, Faculty of Medicine, Medical University, Varna, Bulgaria,

2) Department of Internal Medicine, UMHAT St. Marina, Faculty of Medicine, Medical University, Varna, Bulgaria.

ABSTRACT:

Even though TAVI is a relatively new procedure it managed to become the default method for treatment of aortic stenosis in patients with high surgical risk. It is minimally invasive but not entirely free of complications. One of those is a paravalvular leak following a low implantation. In this article we present the different courses of action in this situation and share our experience on one such occasion.

Keywords: Transcatheter aortic-valve implantation (TAVI), aortic stenosis, paravalvular leak (PVL), snare kit,

INTRODUCTION:

With the development of the technology the idea of interventional management of all valvular diseases becomes more possible all the time. Transcatheter aortic valve implantation is the only reasonable treatment for high grade degenerative aortic valve stenosis in inoperable patients and in patients with high surgical risk [1]. The recent studies show that the procedure is appropriate even for intermediate risk patients [2].

When a TAVI is implanted it is not held in place by any sutures. It has to become anchored at the level of the aortic annulus by the oversized stent frame. Malpositioning or incomplete circumferential opening of the prosthesis can lead to a paravalvular leak (PVL). According to some studies, PVL greater than mild grade, negatively affects the prognosis after TAVI, increasing both morbidity and mortality [3] and in presence of high grade paravalvular leak after the valve implantation, the next procedural goal should be to reduce this leak. The PVL is more frequently seen after transcatheter implantation than after surgical replacement. The first step in managing a high grade PVL due to low positioning of the valve is balloon post-dilatation. This method is not always effective. Next step is to choose between using a snare kit to pull the valve up or to implant another valve – valve-in-valve method. If all the methods fail, the patient should be referred for an operation. In rare cases snare maneuver can be successful although the precise positioning of the valve is very difficult and that's why the valve-

in-valve method is preferred by many operators. Normally the snaring can be performed with transfemoral approach, via the installed introducers during the procedure, but when unsuccessful, radial approach can be used. Sometimes both approaches are used simultaneously. The operator should be aware of the calcified annulus which is anchoring the valve. Embolization of calcium debris in the arterial system is a serious complication and can also involve a coronary artery. If traction is too great, the aorta can become traumatised. When a second valve is implanted higher than the original one, it seals the annulus and greatly reduces the PVL.

There is no consensus regarding the method of analysis, classification and grading of post-procedural PVL.

There are multiple studies reporting the frequency and severity of PVL after TAVI [4] including one of the largest from Kodali et al. [5]. In this study all the patients experience improvement of the systolic function and reduction of the left ventricular mass after TAVI. In the group of patients with severe PVL however, the rate of cardiac-related mortality and hospitalization rate are significantly higher.

CLINICAL CASE DESCRIPTION:

A female, aged 76, was admitted at the ICCU, complaining of dull retrosternal pain and exertional dyspnea and for the last couple of days - at rest. She suffers from ischemic heart disease. In 2014 she underwent coronary artery bypass grafting (LIMA - LAD). She had moderate degree aortic stenosis at the time. During her regular follow-up visits at a cardiologist's office, a progression of the valvular disease was detected. The patient is also suffering from clinical depression, duodenal ulcer and hypothyroidism. In the past she underwent total left mastectomy and radiotherapy because of a carcinoma, total hysterectomy and cholecystectomy.

She takes the following medication: Nebivolol 5mg o.d., Rosuvastatin 10mg o.d., Acetylsal 100mg o.d., Spironolactone 25mg o.d., Torasemide 5mg o.d., L-thyroxin 75mcg o.d.

The physical examination reveals systolic murmur 4/6 grade heard over the whole precordium and p. maximum at the second right intercostal space, RR- 120/80mmHg and rhythmic heart activity with HR= 65/min.

The laboratory findings (Blood count, ALAT, ASAT, CK, CK-MB, Total cholesterol, HDL, LDL, Creatinine, Na, K, Cl) were all within normal range. A small and clinically insignificant increase in troponin level after the interventional procedure was observed.

The transthoracic echocardiogram shows LVEF = 54%, hyperechoic walls of the aorta consistent with severe calcifications, aortic Vmax= 4.63m/s and PG = 85mmHg, moderate aortic regurgitation, trivial tricuspid and mitral regurgitations and an absence of pericardial effusion.

In order to determine that a patient is at high risk for surgery, the following calculations were made: EuroSCORE II – 12.18% (high risk > 6%), LogisticEuroSCORE = 37.95% (high risk > 20%), STS score = 14.69% (high risk > 10%). According to the VARC (Valve Academy Research Consortium) recommendations the patient is suitable for a TAVI procedure [6].

During a meeting of the Heart Team (consisting of a cardiac surgeon, cardiologist, interventional cardiologist, anaesthesiologist and radiologist) it was decided that the patient falls into the high risk group and that a reoperation in the presence of a working arterial graft and porcelain aorta is not recommended. Porcelain aorta is defined as extensive circumferential calcification of the thoracic aorta which makes its cross-clamping dangerous. During a repeat thoracotomy there is a real danger of damaging an intact LIMA to LAD graft. We recommended a TAVI procedure to the patient

Those are the steps we took in preparation for the procedure:

The coronary angiography revealed an intact LIMA-LAD graft, chronic ostial total occlusion of the right coronary artery with rich collateral network, 80% stenosis of distal RCx (circumflex artery). We stented the lesion on the RCx using a DES stent.

The invasive manometry (pull back method) showed 68 mmHg peak gradient across the aortic valve. We also did an aorto-arteriography which allowed us to do measurements of the aortic annulus, sinuses of Valsalva, STJ, ascending aorta and also the diameters of iliac and femoral arteries which met the minimum requirements of the delivery system.

Since it is the golden standard in the assessment of the aortic root, the Multi Slice Computer Tomography (MSCT) is the most important examination in the TAVI protocol. It allows us to measure the diameter of the aorta at different levels. This imaging modality is also used to assess the valve route and the eventual access site (femoral – left or right or left subclavian artery).

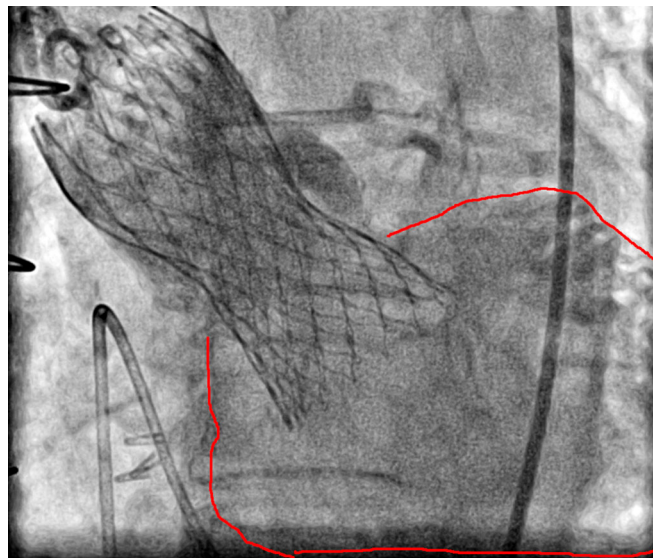
All the imaging methods showed that the patient meets the requirements for this procedure and after she gave her informed consent, she was planned for an implantation.

The transcatheter implantation of aortic valve was

performed under general intubation anaesthesia and followed the standard procedural steps.

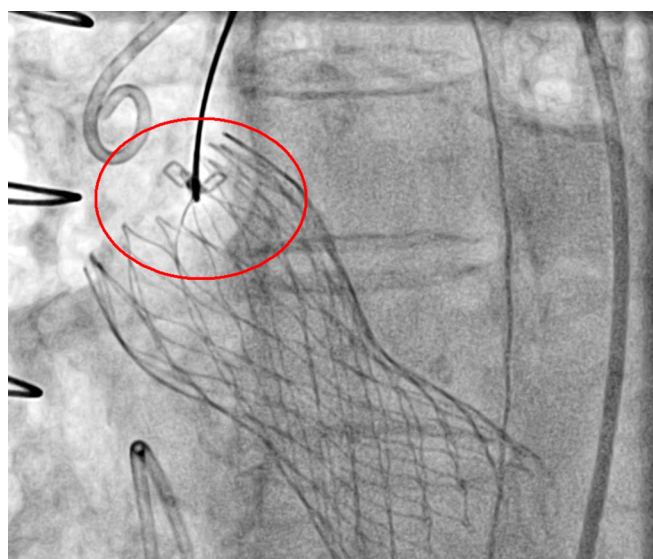
The CoreValve 29mm bioprosthesis was implanted at the place of the native valve. On aortography, a high grade paravalvular leak was detected, due to low position of the valve. (Fig. 1.).

Fig. 1. Aortography showing III degree paravalvular leak. The borders of the left ventricle are marked in red.



As the recommendations for management of PVL state, the operators decided not to do a balloon postdilatation [7]. Another step in the treatment of PLV is to implant another valve [8]. Instead of this step the team made a decision to attempt with snaring, using an Amplatz Goose NECK Snare Kit [9]. After the femoral attempt for snaring the valve was successfully repositioned and the PVL was reduced significantly (Fig. 2.).

Fig. 2. Angiographic view of the snare, catching onto the outflow portion of the valve



No complications were detected after the implantation. The patient was extubated 2 hours after the procedure. Dual antiplatelet therapy for 6 months was prescribed.

The echocardiography, performed 48 hours after the procedure showed normal function of the valve and I grade PVL.

The echocardiography at 1 month follow-up, revealed insignificant paravalvular leak. This finding is consistent with the nature of the valve – it self-expands during the first 30 days.

DISCUSSION:

Hemodynamically significant paravalvular leak is a complication, caused usually by one of the following:

- 1) Undersizing of the valve
- 2) Deep implantation
- 3) Incomplete expansion of the valve, due to annular eccentricity or massive calcifications

It seems that those three are the strongest predictors of PVL. According to the studies MSCT is the best method for evaluation of the proper size of the native aortic valve [10]. Multiple studies confirmed that the type and quantity of calcifications, anatomy of the native valve and annulus are at the base of a post-procedural PVL [11].

There is no accepted algorithm for the assessment of PVL. Although different imaging modalities can be used for visualization of what is essentially an aortic regurgitation, the intra-procedural aortic root angiography is the most commonly used one. It provides the operator immediately with valuable information so he can make a decision. There are four grades of PVL:

1) Mild regurgitation- when a small amount of contrast goes into the LV, but does not fill it entirely.

2) Moderate regurgitation – the whole LV is filled with contrast during diastole, but its density is lower than the ascending aorta.

3) Moderate to severe regurgitation - the whole LV is filled with contrast during diastole and its density is equal to the ascending aorta.

4) Severe regurgitation – it takes only a single beat to fill the whole LV with contrast, and its density is greater than the ascending aorta.

There is still no generally accepted consensus for treatment of PVL. The development of the transcatheter valve technologies shows rapid progression. The new valves have an additional sheet around the leaflets in an attempt to reduce the rate of PVL. Some of the new valves have the option for controlled deployment by repositioning, recapturing or removal of the valve. In combination with the improved flexibility of the delivery system it allows for much more precise implantation.

CONCLUSION:

A paravalvular leak following deep TAVI implantation is associated with increased mortality during the first year after the procedure. If such complication arises, the decision of the operator is complicated by the lack of official guidelines. Arguably the most successful (and also expensive) strategy is valve-in-valve. In some cases, a cheaper method such as using a snare kit can be equally effective and is worth at least a try.

REFERENCES:

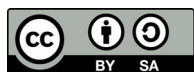1. Leon MB, Smith CR, Mack M, Miller DC, Moses JW, Svensson LG, et al. Transcatheter aortic-valve implantation for aortic stenosis in patients who cannot undergo surgery. *N Engl J Med*. 2010 Oct 21;363(17):1597-607. [[PubMed](#)] [[CrossRef](#)]
2. Leon MB, Craig SR, Mack MJ, Makkar RR, Svensson LG, Kodali SK, et al. Transcatheter or Surgical Aortic-Valve Replacement in Intermediate-Risk Patients. *N Engl J Med*. 2016 Apr 28;374(17):1609-20. [[PubMed](#)] [[CrossRef](#)]
3. Rodés-Cabau J. Transcatheter aortic valve implantation: current and future approaches. *Nat Rev Cardiol*. 2011 Nov 15;9(1):15-29. [[PubMed](#)] [[CrossRef](#)]
4. Généreux P, Head SJ, Van Mieghem NM, Kodali S, Kirtane AJ, Xu K, et al. Clinical outcomes after transcatheter aortic valve replacement using Valve Academic Research Consortium definitions: a weighted meta-analysis of 3,519 patients from 16 studies. *J Am Coll Cardiol*. 2012 Jun 19;59(25):2317-26. [[PubMed](#)] [[CrossRef](#)]
5. Kodali S, Pibarot P, Douglas PS, Williams M, Xu K, Thourani V, et al. Paravalvular regurgitation after transcatheter aortic valve replacement with the Edwards sapien valve in the PARTNER trial: characterizing patients and impact on outcomes. *Eur Heart J*. 2015 Feb 14;36(7):449-56. [[PubMed](#)] [[CrossRef](#)]
6. Holmes DR Jr, Mack MJ, Kaul S, Agnihotri A, Alexander KP, Bailey SR, et al. 2012 ACCF/AATS/SCAI/STS expert consensus document on transcatheter aortic valve replacement: developed in collaboration with the American Heart Association, American Society of Echocardiography, European Association for Cardio-Thoracic Surgery, Heart Failure Society of America, Mended Hearts, Society of Cardiovascular Anesthesiologists, Society of Cardiovascular Computed Tomography, and Society for Cardiovascular Magnetic Resonance. *Ann Thorac Surg*. 2012 Apr;93(4):1340-95. [[PubMed](#)] [[CrossRef](#)]
7. Eggebrecht H, Doss M, Schmermund A, Nowak B, Krissel J, Voigtlander T. Interventional options for severe aortic regurgitation after transcatheter aortic valve implantation: balloons, snares, valve-in-valve. *Clin Res Cardiol*. 2012 Jun;101(6):503-7. [[PubMed](#)] [[CrossRef](#)]
8. Gerckens U, Latsios G, Mueller R, Buellesfeld L, John D, Yuecel S, et al. Procedural and mid-term results in patients with aortic stenosis treated with implantation of 2 (in-series) CoreValve prostheses in 1 procedure. *JACC Cardiovasc Interv*. 2010 Feb;3(2):244-50. [[PubMed](#)] [[CrossRef](#)]

9. Majunke N, Doss M, Steinberg DH, Bargenda S, Plachky J, Rieck B, et al. How should I treat a misplaced self-expanding aortic bioprosthetic valve?. *EuroIntervention*. 2010 Sep; 6(4):537-42. [[PubMed](#)] [[CrossRef](#)]
10. Jilaihawi H, Kashif M, Fontana G, Furugen A, Shiota T, Friede G, et al. Cross-sectional computed tomographic assessment improves accuracy of aortic annular sizing for transcatheter aortic valve replacement and reduces the incidence of paravalvular aortic regurgitation. *J Am Coll Cardiol*. 2012 Apr 3;59(14):1275-86. [[PubMed](#)] [[CrossRef](#)]
11. Ewe SH, Ng AC, Schuijf JD, van der Kley F, Colli A, Palmieri M, et al. Location and severity of aortic valve calcium and implications for aortic regurgitation after transcatheter aortic valve implantation. *Am J Cardiol*. 2011 Nov 15;108(10):1470-7. [[PubMed](#)] [[CrossRef](#)]

Please cite this article as: Valkov V, Kalchev D, Kostadinov A, Kashlov Y, Kanazirev B. Snare maneuver for management of low TAVI implantation - clinical case. *J of IMAB*. 2018 Apr-Jun;24(2):2034-2037.

DOI: <https://doi.org/10.5272/jimab.2018242.2034>

Received: 27/04/2018; Published online: 14/06/2018



Address for correspondence:

Veselin Valkov,
First Clinic of Cardiology, Department of Internal Medicine, University Hospital
St. Marina, Varna.
1, Hr. Smirnensky blvd., Varna, Bulgaria.
Tel.: +359889232505
E-mail: vd.valkoff@abv.bg