

Case Report

Bowen's Disease of the Nipple

Miyuki Kitahara^a Yasuo Hozumi^a Akie Watanabe^a Tatsuo Iijima^b

^aDepartment of Breast Surgery, Ibaraki Prefectural Central Hospital and Cancer Center, Kasama, Japan; ^bDepartment of Pathology, Ibaraki Prefectural Central Hospital and Cancer Center, Kasama, Japan

Keywords

Bowen's disease · Squamous cell carcinoma · Nipple · Breast cancer

Abstract

Bowen's disease is a type of intraepidermal squamous cell carcinoma that commonly develops in areas of the skin exposed to sunlight, such as the scalp, trunk, and limbs. Although development of Bowen's disease in other sites, such as the nipple, is extremely rare, we herein report our experience with one such case. A 76-year-old female presented to our hospital with complaints of right nipple pruritus. We diagnosed Bowen's disease via nipple skin biopsy, and the patient underwent right nipple resection. The deep tissue margin was positive for malignancy; therefore, the patient subsequently underwent right partial mastectomy. Histopathology revealed tumor cells inside the lactiferous ducts, but the resection margin was negative for malignancy. Bowen's disease of the nipple may progress from the skin to the lactiferous ducts. Clinical findings can be used to evaluate lesion progression and determine the necessary extent of skin and mammary gland resection.

© 2018 The Author(s)
Published by S. Karger AG, Basel

Introduction

Bowen's disease is a type of intraepidermal squamous cell carcinoma [1]. Factors related to onset include exposure to ultraviolet radiation, human papilloma virus, or carcinogens, such as arsenic, genetic susceptibility, a history of visceral malignancies, immunosuppression,

and the presence of birthmarks [2]. While Bowen's disease commonly develops in areas of the skin exposed to sunlight, such as the scalp, trunk, and limbs, it can also develop in other sites. However, the development of Bowen's disease in the nipple is extremely rare [3]. Herein, we report the case of a patient with Bowen's disease that developed in the nipple.

Case Report

A 76-year-old female with a history of dementia presented to her local physician complaining of a 1-month history of right nipple pruritus. Topical steroids resulted in minimal improvement, and the patient consequently consulted the Department of Dermatology at our hospital. Upon examination, there was no evidence of a palpable breast mass or a swelling of the axillary lymph nodes. The right nipple appeared swollen and inflamed with occasional bleeding, but the right mammary areola was normal (Fig. 1). Mammography findings were normal, but ultrasonography revealed a swelling of the right nipple, an internal punctiform hyperechoic area, and rich blood flow.

Based on these clinical findings, inflammatory changes in the right nipple and Paget's disease of the breast were considered as differential diagnoses, and a punch biopsy of the right nipple skin was performed. Histopathology revealed the presence of proliferating, highly atypical squamous cells accompanied by occasional mitotic figures. We did not detect Paget cells or an invasion of atypical cells beyond the basement membrane into the ruptured interstitium. Therefore, the patient was diagnosed with Bowen's disease.

The patient desired a simple resection, and a surgical plan to resect and plicate the right nipple under local anesthesia was developed. A 5-mm horizontal margin was established beginning at the right nipple, which was resected down to the level of the areolar subcutaneous fat proximal to the lactiferous duct. Histopathological analysis of the resected tissue revealed tumor cells within the ductal epithelium, and the deep margin was positive for malignancy (Fig. 2, 3a, b). The patient was consequently referred to the Department of Breast Surgery of our hospital for additional resection.

MRI of the breast showed a relatively limited area of contrast in the operated site; however, we were unable to establish whether this signal resulted from postoperative changes or the presence of residual lesions. Nevertheless, it was highly likely that a progression of the lesion within the lactiferous duct was limited to the vicinity of the nipple, and a partial mastectomy was indicated. A fusiform skin incision was made around the areola and the previous surgical scar, and the mammary gland was dissected to the level of the pectoralis major. Histopathology revealed that intraductal tumor cells spanned 8 mm of the tissue, but all resection margins were negative for cancer (Fig. 3c, d).

The patient refused radiation therapy of the right residual breast because of treatment-related anxiety and her history of dementia. One year postoperatively, the patient shows no signs of recurrence and is undergoing follow-up on an outpatient basis.

Discussion

Bowen's disease is a type of intraepithelial squamous cell carcinoma in situ, first reported by J.T. Bowen in 1912 [1]. Typical clinical findings include a gradual enlargement of a well-demarcated erythematous epidermal lesion, hyperkeratosis, desquamation, pruritus, and the presence of inflammation or irregular brown papules [4]. Approximately 3% of all patients

with Bowen's disease will develop invasive squamous cell carcinoma, and progression is linked to a modulation of the patient's immune status [5].

Bowen's disease of the nipple is extremely rare, with only 7 cases reported to date [3, 4, 6–9]. One patient, a 41-year-old male with acquired immunodeficiency syndrome, presented with eczema-like changes to the papilla that had persisted for approximately 1 year. The remaining 6 patients were postmenopausal women aged 69–84 years, similar to the patient in the current report.

Pathological features of Bowen's disease include abnormal mitoses in the thickened epidermis, dyskeratosis, and the presence of proliferating atypical cells that do not exhibit evidence of dermal invasion [2]. In our patient, proliferating atypical cells with large nuclei were observed in the epidermis with occasional mitotic figures. Furthermore, inflammatory cell infiltration was noted that extended from the epidermis to the superficial dermis, and abscess formation was observed in the epidermis. Histopathologically, it was difficult to differentiate between inflammatory atypia and Bowen's disease. Additional sections were examined, which revealed the presence of proliferative, highly atypical, epidermal squamous cells in the absence of clear interstitial infiltration. Therefore, the patient was diagnosed with Bowen's disease.

Differential diagnoses for Bowen's disease of the nipple include Paget's disease of the breast, which is more common in this site, and the less prevalent superficial spreading melanoma [10]. In some cases, it is challenging to macroscopically and/or histologically differentiate Bowen's disease from Paget's disease or melanoma. Hence, immunohistochemical staining can be used to reach a definitive diagnosis in such cases [10]. Specifically, tissue from patients with Bowen's disease exhibits positivity for low- and high-molecular-weight cytokeratins [10] and/or epithelial membrane antigen, whereas melanoma tissue shows strong positivity for S-100 [11, 12].

There are many topical treatment options for Bowen's disease, including cryotherapy with liquid nitrogen, 5-fluorouracil, and photodynamic therapy [13]. At present, however, the standard treatment is surgical resection, which guarantees a negative margin. This practice may explain the low recurrence rates associated with this disease [14]. To date, 3 cases of extensive local resection and 2 cases of mastectomy have been reported for Bowen's disease of the nipple. Two cases in which tumor cells had progressed to the mammary ducts were treated with local resection or mastectomy [4, 8]. Two patients were also treated with photodynamic therapy and cryotherapy [3, 9]. As no cases of recurrence have been reported, the acquisition of negative margins is considered adequate treatment for this disease.

In our patient, we used various diagnostic imaging modalities to evaluate the progression of the lesion and determine the feasibility of local resection. We then performed a partial mastectomy and confirmed that negative surgical margins had been obtained. Ultimately, when selecting a treatment strategy for patients with Bowen's disease of the nipple, it is essential to use mammography, ultrasonography, and MRI, in accordance with the principles of breast cancer treatment, to evaluate the presence or absence and extent of tumor cell progression within the lactiferous ducts.

Statement of Ethics

Written informed consent was obtained from the patient for publication of this case report and accompanying images.

Disclosure Statement

The authors declare that they have no conflicts of interest.

Author Contributions

M.K. drafted the manuscript. M.K., Y.H., and A.W. performed the operation, and M.K. followed up the patient. T.I. diagnosed the disease as pathologist. All authors have read and approved the final manuscript.

References

- 1 Bowen JT. Precancerous dermatoses: a study of two cases of chronic atypical epithelial proliferation. *J Cutan Dis Syph.* 1912;30:241–55.
- 2 Arlette JP, Trotter MJ. Squamous cell carcinoma in situ of the skin: history, presentation, biology and treatment. *Australas J Dermatol.* 2004 Feb;45(1):1–9.
- 3 Brookes PT, Jhavar S, Hinton CP, Murdoch S, Usman T. Bowen's disease of the nipple—a new method of treatment. *Breast.* 2005 Feb;14(1):65–7.
- 4 Sharma R, Iyer M. Bowen's disease of the nipple in a young man with AIDS: a case report. *Clin Breast Cancer.* 2009 Feb;9(1):53–5.
- 5 Kao GF. Carcinoma arising in Bowen's disease. *Arch Dermatol.* 1986 Oct;122(10):1124–6.
- 6 Cremer H, Paulussen F. [Bowen's disease of the nipple]. *Geburtshilfe Frauenheilkd.* 1982 Aug;42(8):590–2. German
- 7 Hosaka N, Uesaka K, Takaki T, Zhang Y, Takasu K, Ikehara S. Poorly differentiated squamous cell carcinoma of the nipple: a unique case for marked exophytic growth, but little invasion with neuroendocrine differentiation. *Med Mol Morphol.* 2011 Sep;44(3):174–8.
- 8 Venkateshan VS, Budd DC, Un Kim D, Hutter RV. Intraepidermal squamous carcinoma (Bowen's disease) of the nipple. *Hum Pathol.* 1994 Dec;25(12):1371–4.
- 9 Yazicioglu MB, Tokyol C, Turel KS, Keskin AI, Aktepe F. A rare disease of the breast: bowen's disease. *Natl J Med Res.* 2014;4:168–9.
- 10 Shah KD, Tabibzadeh SS, Gerber MA. Immunohistochemical distinction of Paget's disease from Bowen's disease and superficial spreading melanoma with the use of monoclonal cytokeratin antibodies. *Am J Clin Pathol.* 1987 Dec;88(6):689–95.
- 11 Vanstapel MJ, Gatter KC, De Wolf-Peeters C, Millard PR, Desmet VJ, Mason DY. Immunohistochemical study of mammary and extra-mammary Paget's disease. *Histopathology.* 1984 Nov;8(6):1013–23.
- 12 Gillett CE, Bobrow LG, Millis RR. S100 protein in human mammary tissue—immunoreactivity in breast carcinoma, including Paget's disease of the nipple, and value as a marker of myoepithelial cells. *J Pathol.* 1990 Jan;160(1):19–24.
- 13 Cox NH, Eedy DJ, Morton CA; British Association of Dermatologists. Guidelines for management of Bowen's disease. *Br J Dermatol.* 1999 Oct;141(4):633–41.
- 14 Leibovitch I, Huilgol SC, Selva D, Richards S, Paver R. Cutaneous squamous carcinoma in situ (Bowen's disease): treatment with Mohs micrographic surgery. *J Am Acad Dermatol.* 2005 Jun;52(6):997–1002.

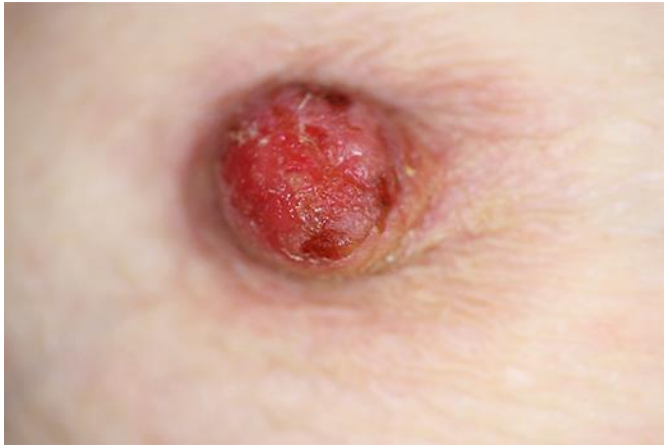

Fig. 1. The epidermis of the right nipple was inflamed and swollen with occasional bleeding.

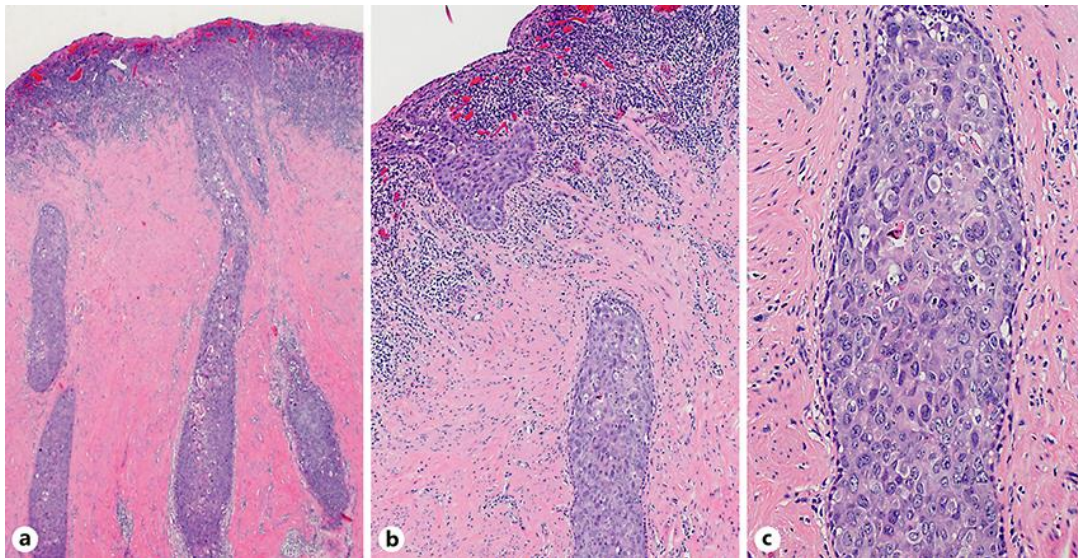


Fig. 2. Proliferative, highly atypical squamous cells were present within the epidermis, and exhibited progression toward the lactiferous duct lumen. Tumor cells were polygonal with weakly basic to slightly clear bodies, large irregular nuclei, and occasional mitotic figures. Dense inflammatory cell infiltration could be seen directly below the epidermis.

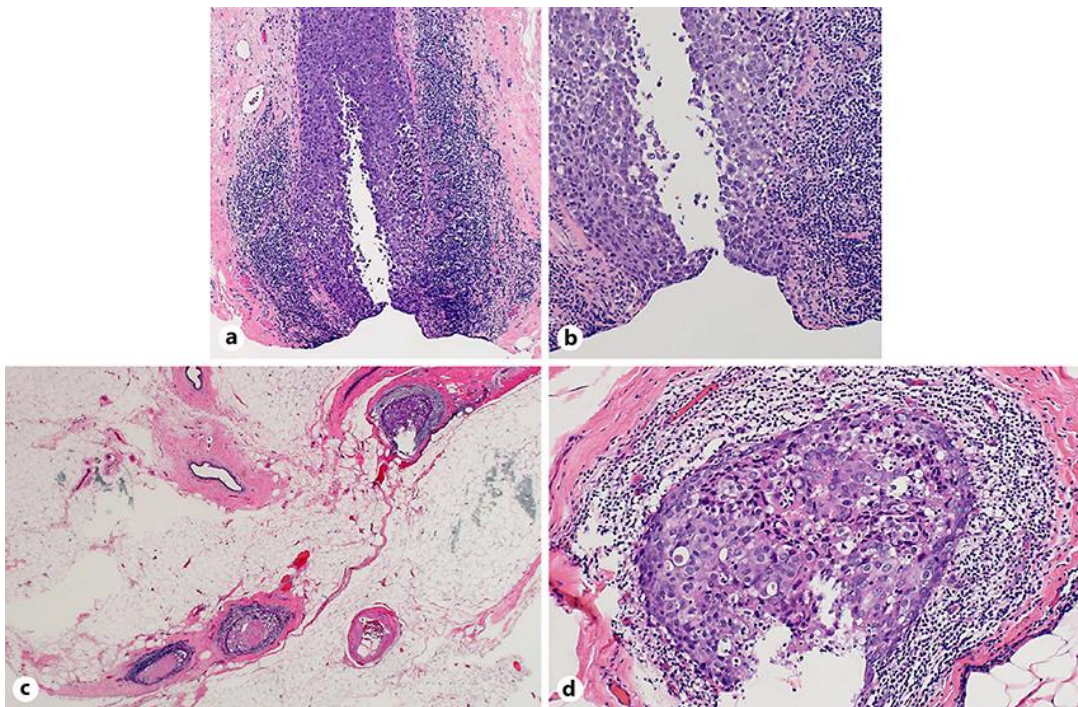


Fig. 3. **a, b** Tumor cells were present within the deep margins of the resected tissue. **c, d** Tumor cells filled the lactiferous ducts, but there was no evidence of further invasion.