

This article is licensed under the Creative Commons Attribution-NonCommercial 4.0 International License (CC BY-NC) (<http://www.karger.com/Services/OpenAccessLicense>). Usage and distribution for commercial purposes requires written permission.

Case Report

Primary Hyperoxaluria Type 1 with Thrombophilia in Pregnancy: A Case Report

Asma Hasan^a Sharon Maynard^a Dominick Santoriello^b
Henry Schairer^a

^aLehigh Valley Health Network, Allentown, PA, USA; ^bColumbia University, New York, NY, USA

Keywords

Primary hyperoxaluria · Pregnancy · Thrombophilia · Nephrolithotomy · Nephrolithiasis

Abstract

Background: Primary hyperoxaluria type 1 (PH1) is a rare autosomal recessive disease caused by a mutation in the *AGXT* gene, resulting in deficiency of the alanineglyoxylate:aminotransferase enzyme. It is characterized by accumulation of oxalate in the kidneys and other organs.

Case Presentation: A Syrian woman with a history of nephrolithiasis and heterozygosity for factor V Leiden and prothrombin gene mutations presented with postpartum renal failure. She required initiation of renal replacement therapy at 14 weeks postpartum. Kidney biopsy showed severe acute and chronic crystalline deposition consistent with oxalate nephropathy. Genetic testing revealed a Gly170Arg mutation in the *AGXT* gene, confirming the diagnosis of PH1. **Conclusions:** The diagnosis of PH should be considered in patients with severe, recurrent calcium oxalate nephrolithiasis. Early treatment with pyridoxine reduces urinary oxalate excretion and can delay progression to end-stage renal disease (ESRD). After ESRD, intensive dialysis is needed to prevent systemic oxalate accumulation and deposition. Combined liver and kidney transplantation is curative. In our patient, we anticipate that liver transplantation will cure both the hyperoxaluria and the hypercoagulable state.

© 2018 The Author(s)
Published by S. Karger AG, Basel

Introduction

Primary hyperoxaluria type 1 (PH1) is an autosomal recessive disease characterized by overproduction of oxalate leading to oxalate crystal aggregation, nephrocalcinosis, nephrolithiasis, and recurrent urinary tract infections. This leads to renal interstitial and tubular damage, fibrosis, and end-stage renal disease (ESRD). Once the glomerular filtration rate falls, renal excretion of oxalate declines, which causes systemic oxalosis with calcium oxalate deposition in the heart, vessel walls, skin, retina, bones, and joints.

Case Presentation

A 27-year-old woman who had recently immigrated from Syria was admitted to our center at 12 weeks postpartum with progressive renal failure and nephrolithiasis. She reported recurrent kidney stones and urinary tract infections since age 12. She had a family history of renal failure and recurrent nephrolithiasis in her sister and maternal uncle. Her family history was also notable for consanguinity (her parents were first cousins).

Pregnancy history was notable for four spontaneous pregnancy losses in her early twenties. A thrombophilia evaluation identified compound heterozygosity for factor V Leiden and prothrombin G20210A mutation. Imaging by contrast-enhanced computed tomography revealed numerous renal calculi up to 1.5 cm filling the calyces of both kidneys. Her next pregnancy at age 26 was treated with low-molecular-weight heparin, and she had a term delivery complicated by mild acute kidney injury. Renal function improved postpartum. During this pregnancy, she was again treated with low-molecular-weight heparin. A urine biochemical evaluation revealed moderate hyperoxaluria (55 mg/day, reference range 4–31) and profound hypocitraturia. She was prescribed a low-oxalate diet, potassium citrate, and high fluid intake. Her serum creatinine was 0.85–1.00 mg/dL until 34 weeks of gestation, when she presented with flank pain, acute kidney injury (creatinine 1.64 mg/dL), and a right obstructing proximal ureteral calculus. A percutaneous nephrostomy was placed. She was delivered 1 week later, at 35 weeks, by elective cesarean section for persistent bleeding from low-lying placenta. The right percutaneous nephrostomy remained in place and her serum creatinine improved to 1.2–1.4 mg/dL.

The patient was seen by Nephrology 1 week postpartum. At that time, she reported persistent right flank pain and dysuria, without fever. Blood pressure was 128/68 mm Hg and she appeared euvolemic. She reported maintaining fluid intake of approximately 3 L/day. Urinalysis shows proteinuria, hematuria, and pyuria (>100 WBC/hpf), but urine culture was negative. She was continued on high fluid intake, low-oxalate diet, and potassium citrate. She had persistent right flank pain, and her serum creatinine gradually increased from 1.5 to 2.5 mg/dL. At 7 weeks postpartum, a percutaneous nephrolithotomy was performed. The retrieved stone was found to be composed primarily of calcium oxalate monohydrate. Post-operatively, the patient developed fever and was treated empirically with vancomycin and cefepime. Her renal function did not improve. She presented for follow-up 1 month later with persistent flank pain, dysuria, subjective fever and chills, and decreased urine output. The serum creatinine was 6.82 mg/dL, her plasma oxalate level was 85.4 $\mu\text{mol/L}$ (reference range <1.9 $\mu\text{mol/L}$), and urine culture was positive for >100,000 colonies of extended-spectrum beta-lactamase producing *Escherichia coli*.

Kidney biopsy (Fig. 1, 2, 3, 4) revealed abundant (>90/hpf) optically clear intratubular crystalline inclusions which were accompanied by diffuse acute tubular injury, moderately

severe tubulointerstitial scarring, and patchy moderate chronic interstitial inflammation, consistent with a crystalline nephropathy. When viewed under polarized light, the crystalline deposits were strongly birefringent, typical of calcium oxalate crystals. Some calcium oxalate crystals in the interstitium were associated with foreign-body-type giant cells. Glomeruli showed mild secondary glomerulosclerosis. Arteries and arterioles were unremarkable. On genetic testing, she was found to be homozygous for G170R missense mutation in the *AGXT* gene, consistent with PH1. Pyridoxine was initiated.

At 14 weeks postpartum, the patient began intensive hemodialysis, and she was referred for combined liver and kidney transplantation. Predialysis plasma oxalate was 34.3 $\mu\text{mol/L}$ after 3 months of nocturnal dialysis (3 treatments/week, 8 h/treatment). She continued to have flank pain and dysuria. Urine culture was persistently positive for beta lactamase-resistant *E. coli* despite antibiotic treatment. Because of concern for the emergence of further antibiotic resistance, the inability to durably eradicate her infection with antibiotic treatment given her heavy stone burden, and the potential development of life-threatening sepsis with immunosuppression after transplantation, she underwent bilateral native nephrectomies. One year postpartum, she received a simultaneous liver and kidney transplant.

Discussion

PH is a rare autosomal recessive disease characterized by overproduction of oxalate, leading to calcium oxalate nephrolithiasis and oxalate accumulation in the kidneys and other organs. PH is caused by mutations in *AGXT*, *GRHPR*, or *HOGA1*, which cause PH1, PH2, or PH3, respectively [1]. PH1 is the most common and most severe type, accounting for approximately 80% of cases. It is caused by deficiency of the liver-specific lysosomal enzyme alanineglyoxylate:aminotransferase (AGT or AGXT), an enzyme which converts glyoxylate to glycine. With deficient AGT, accumulated glyoxylate is converted to oxalate. More than 150 *AGXT* mutations have been identified. G170R is the most common one, accounting for 25–40% of cases [2, 3]. Hyperoxaluria results in recurrent urolithiasis and nephrocalcinosis, with progressive loss of renal function and ESRD. Most patients present in infancy or childhood with calcium oxalate kidney stones, with a mean age at symptom onset of 9.5 ± 10.2 years [2]. The severity of disease is variable, ranging from infantile oxalosis with renal failure to occasional nephrolithiasis presenting in adulthood. However, late presentation does not necessarily imply mild disease: 70% of those diagnosed in adulthood have ESRD at the time of diagnosis [3]. There is a poor correlation between genotype and phenotype, as affected individuals within the same family may have markedly different clinical manifestations [4]. Occasionally, the disease may be asymptomatic, with diagnosis only after family screening [5]. Higher urinary oxalate excretion is predictive of poor renal outcomes [6].

Early diagnosis of PH1 is important, as measures such as pyridoxine and potassium citrate may delay progression to ESRD [7, 8]. However, clinical clues to the diagnosis may be scant. Hyperoxaluria is an important clinical finding, but it is nonspecific and common in all patients with nephrolithiasis. Plasma oxalate levels may remain in the normal range while kidney function is intact. Elevated levels of plasma oxalate are seen after the development of chronic kidney disease, as in our patient, reflecting diminished urinary oxalate excretion. Genetic testing establishes the diagnosis.

The management of PH1 includes increased fluid intake, magnesium oxide, and potassium citrate to improve the solubility of urinary calcium oxalate. Pyridoxine, a natural cofactor of *AGXT*, promotes conversion of glyoxylate to glycine rather than to oxalate. Pyridoxine de-

creases oxalate production in a substantial proportion of patients with PH1, particularly those with the G170R genotype [8]. However, not all patients respond to pyridoxine, hence it should be continued only if a beneficial effect on urinary oxalate excretion is confirmed [1]. In our patient, earlier diagnosis and treatment – particularly before the development of severe and extensive nephrolithiasis – may have prevented the development of severe nephrolithiasis, her accelerated loss of kidney function, and the need for native nephrectomies.

Extracorporeal shockwave lithotripsy, a common intervention for the treatment of nephrolithiasis, can cause renal injury and should be avoided in patients with PH [1]. Liver transplantation cures the disease by replacing the deficient AGXT enzyme. In patients with ESRD, combined liver and kidney transplant is appropriate [9, 10]. Kidney transplantation alone leads to recurrent ESRD in almost all cases [9].

Prior to transplantation, patients with ESRD require intensive dialysis to avoid systemic oxalosis. Conventional dialysis (4 h, three times a week) provides adequate oxalate clearance and can lead to systemic oxalate deposition in joints, retina, heart, skin, bone, and bone marrow [5, 10, 11]. There are few data to indicate the dialysis dose needed to prevent these complications. In one study of 14 hemodialysis patients with PH1, intensive dialysis (5–6 sessions/week) provided mean weekly oxalate removal of 11.13 ± 6.88 mmol/week, which the authors estimated was adequate, when combined with residual renal excretion, to remove daily oxalate production [11]. However, plasma oxalate levels remained markedly above normal (75.1 ± 33.4 $\mu\text{mol/L}$, normal <1.6 $\mu\text{mol/L}$). In our patient, nocturnal dialysis provided 24 h/week of dialysis while she awaited liver-kidney transplantation.

With regard to pregnancy in women with PH, Norby and Milliner [12] reported pregnancy and renal outcomes in 16 women (40 pregnancies) with PH1 and PH2 between 1961 and 1998. Over half of the pregnancies (21 of 40) occurred prior to the diagnosis of PH, as with our patient. Pregnancy was not associated with a deterioration in renal function in most women. However, 50% of pregnancies had complications including hypertension, urinary tract infection, and symptomatic urolithiasis. The live birth rate was 82.5%, and 75% of pregnancies were carried to term. In this series, women with PH1 progressed to ESRD at a mean of 17.5 years following the first pregnancy. Only 1 patient had rapid decline in kidney function during pregnancy, which was associated with severe hyperemesis gravidarum. The clinical course of our patient, who required renal replacement therapy within 4 months after delivery, appears to be unusually severe.

In addition to the AGXT mutation signifying PH1, our patient also carries two mutations for inherited thrombophilia: factor V Leiden and the prothrombin G20210A mutation. To our knowledge, there has been only one other such case reported in the literature [13]. That patient underwent combined liver-kidney transplantation, which cured both her PH1 and her inherited thrombophilia. Treatment of our patient's thrombophilia with heparin allowed two successful pregnancies. It is unknown whether her thrombophilia or its treatment contributed to her accelerated decline in kidney function postpartum.

In conclusion, we report a case of PH with rapid progression to ESRD in the postpartum period. This familial disorder should be suspected in patients presenting with childhood-onset calcium oxalate nephrolithiasis in the setting of a positive family history.

Statement of Ethics

Ethics approval is not applicable as this is a case report. The patient provided written consent (available upon request). No personally identifiable information is revealed.

Disclosure Statement

All authors declare that they have no competing interests and no conflict of interest regarding the publication of this article. This work received no funding.

References

- 1 Cochat P, Rumsby G. Primary hyperoxaluria. *N Engl J Med*. 2013 Aug;369(7):649–58.
- 2 Lieske JC, Monico CG, Holmes WS, Bergstralh EJ, Slezak JM, Rohlinger AL, et al. International registry for primary hyperoxaluria. *Am J Nephrol*. 2005 May–Jun;25(3):290–6.
- 3 Mandrile G, van Woerden CS, Berchiolla P, Beck BB, Acquaviva Bourdain C, Hulton SA, et al.; OxalEurope Consortium. Data from a large European study indicate that the outcome of primary hyperoxaluria type 1 correlates with the AGXT mutation type. *Kidney Int*. 2014 Dec;86(6):1197–204.
- 4 Frishberg Y, Rinat C, Shalata A, Khatib I, Feinstein S, Becker-Cohen R, et al. Intra-familial clinical heterogeneity: absence of genotype-phenotype correlation in primary hyperoxaluria type 1 in Israel. *Am J Nephrol*. 2005 May–Jun;25(3):269–75.
- 5 Leumann E, Hoppe B. The primary hyperoxalurias. *J Am Soc Nephrol*. 2001 Sep;12(9):1986–93.
- 6 Zhao F, Bergstralh EJ, Mehta RA, Vaughan LE, Olson JB, Seide BM, et al.; Investigators of Rare Kidney Stone Consortium. Predictors of Incident ESRD among Patients with Primary Hyperoxaluria Presenting Prior to Kidney Failure. *Clin J Am Soc Nephrol*. 2016 Jan;11(1):119–26.
- 7 Monico CG, Rossetti S, Olson JB, Milliner DS. Pyridoxine effect in type I primary hyperoxaluria is associated with the most common mutant allele. *Kidney Int*. 2005 May;67(5):1704–9.
- 8 Hoyer-Kuhn H, Kohbrok S, Volland R, Franklin J, Hero B, Beck BB, et al. Vitamin B6 in primary hyperoxaluria I: first prospective trial after 40 years of practice. *Clin J Am Soc Nephrol*. 2014 Mar;9(3):468–77.
- 9 Compagnon P, Metzler P, Samuel D, Camus C, Niaudet P, Durrbach A, et al. Long-term results of combined liver-kidney transplantation for primary hyperoxaluria type 1: the French experience. *Liver Transpl*. 2014 Dec;20(12):1475–85.
- 10 Jamieson NV; European PHI Transplantation Study Group. A 20-year experience of combined liver/kidney transplantation for primary hyperoxaluria (PH1): the European PH1 transplant registry experience 1984–2004. *Am J Nephrol*. 2005 May–Jun;25(3):282–9.
- 11 Tang X, Voskoboev NV, Wannarka SL, Olson JB, Milliner DS, Lieske JC. Oxalate quantification in hemodialysate to assess dialysis adequacy for primary hyperoxaluria. *Am J Nephrol*. 2014;39(5):376–82.
- 12 Norby SM, Milliner DS. Outcomes and complications of pregnancy in women with primary hyperoxaluria. *Am J Kidney Dis*. 2004 Feb;43(2):277–85.
- 13 Jeong W, Rothberg PG, Delaney V, Facciuto ME, Yalamanchili K, Nelson JC. Liver transplantation for type 1 primary hyperoxaluria as a cure for combined thrombophilia. *Thromb Haemost*. 2004 Nov;92(5):1157–8.

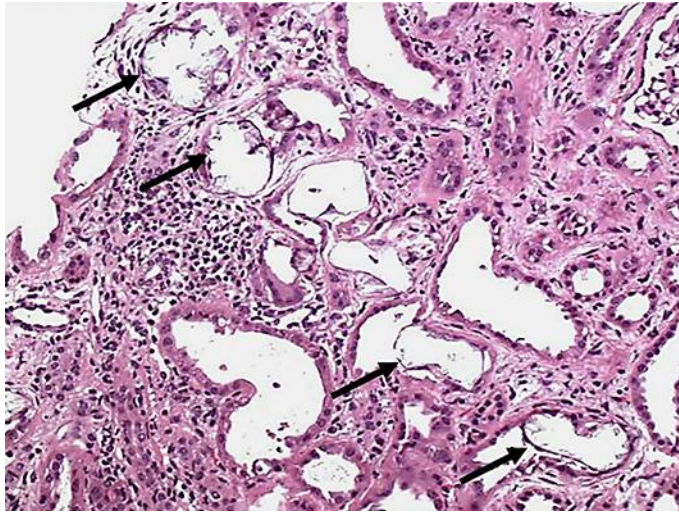


Fig. 1. A low-power view demonstrates diffuse tubular injury, including multiple tubules distended by intraluminal and intracytoplasmic optically clear crystals (arrows). H&E, ×200.

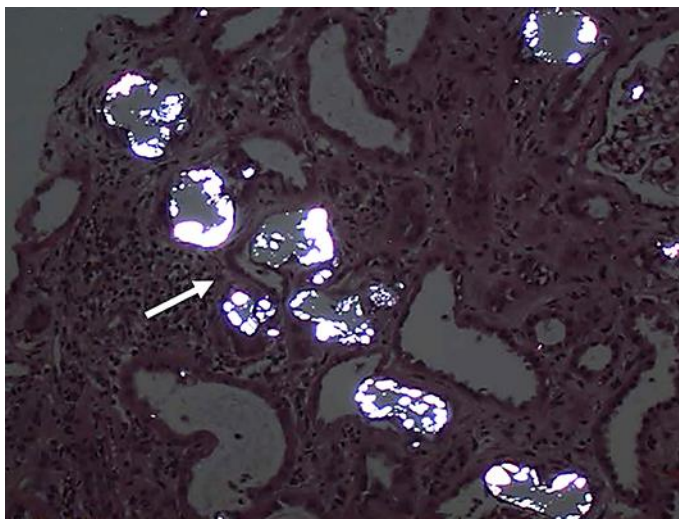


Fig. 2. Crystals are best viewed under polarized light, where they have a strongly birefringent appearance. H&E, ×200.

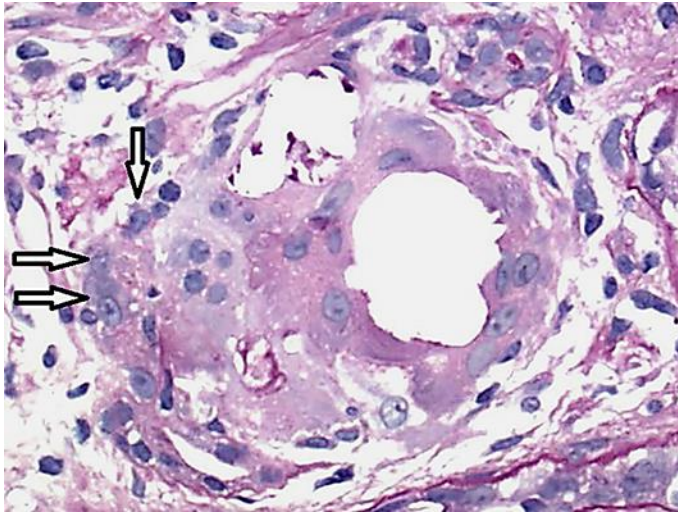


Fig. 3. A cluster of multinucleated giant cells, histiocytes, and lymphocytes forms an interstitial foreign body-type granuloma. H&E, $\times 400$.

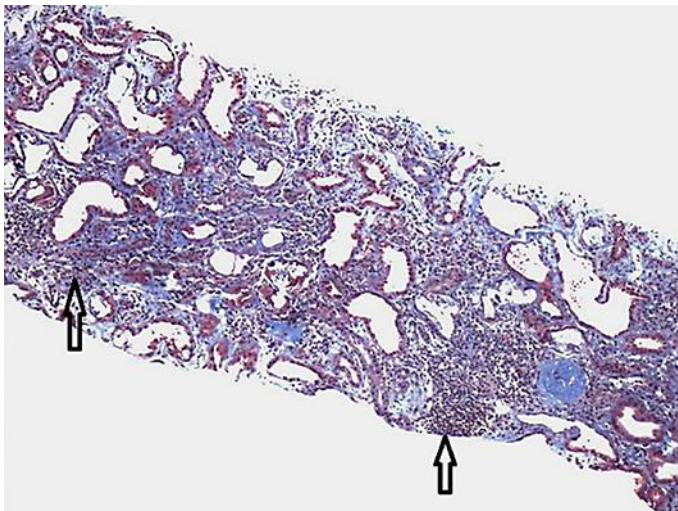


Fig. 4. Diffuse moderate to severe tubulointerstitial scarring accompanied by chronic inflammatory reaction composed of mainly lymphocytes. Trichrome, $\times 100$.