

SHORT ABSTRACT

Future of Interventional Radiology: Emerging Techniques

Marco Midulla*, Lorenzo Pescatori*[†], Olivier Chevallier*, M. Nakai*[‡], A. Ikoma[‡], Sophie Gehin*, Pierre Emmanuel Berthod*, Romaric Ne* and Romaric Loffroy*

Keywords: interventional radiology; emborrhoid; bariatric embolization; frozen shoulder; interventional immunooncology; percutaneous AVF; merged mixed virtual reality

Since the early years of the pioneers, interventional radiology (IR) has regularly changed its mind and façade, with new therapeutic concepts and innovative techniques emerging and gaining the attention of the scientific community through a wide range of applications. Innovation definitely has been the corner-stone of the progresses of this subspecialty; the purpose of this lecture's abstract is to review the more recent concepts of care that have emerged over the last years and will be developing in the future, according to the further evolution of IR.

The newest techniques concern either the unexplored field of applications and cutting-edge technologies, involving embolization therapy, interventional oncology (IO), and vascular interventions.

The transarterial treatment of hemorrhoidal disease by embolization of the superior rectal arteries (SRA) is certainly one of the new concepts that have gained major attention over the last 2–3 years. As it was nicely presented by Vincent Vidal and his team in Marseille under the name of “Emborrhoid Technique”, it was inspired by previous experiences in urgent cases of massive bleeding, when embolization was used as an alternative treatment to surgery. Early results of endovascular therapy demonstrated a significant regression of the hemorrhoidal bundles, absence of ischemic risk and a normal sphincteric function recovered after one month. The main target would be, of course, reducing the morbidity, especially hospitalization and recovery times, and the next trials will be focused on these outcomes.

A second emerging application of the embolization of the gastrointestinal tract is the so-called “bariatric embolization”, introduced through an in-animal study in 2007 by the group of the John Hopkins Institute in Baltimore. The new treatment involves the suppression of the ghrelin-producing cells located in the fundus of the stomach

by a selective injection of particles and coils placement in the left gastric artery (LGA). To date, there are three ongoing clinical trials focused on bariatric artery embolization (BAE): the GET LEAN (Gastric artery Embolization Trial for Lessening of Appetite Nonsurgically); the BEAT (Bariatric Embolization of Arteries for the Treatment of Obesity); the Chinese trial NCT02786108. No major complications were registered while minor events, such as superficial ulcer of the mucosa at the targeted zone, were encountered. Excess body weight loss varied from 9% at three months to 17.2% at six months (with mean body weight loss among 9.2 kg). In the future, this minimally invasive procedure could be combined with the other therapeutic resources in the management of severely or morbidly obese patients.

The transarterial treatment of resistant painful musculoskeletal conditions, such as osteoarthritis, frozen shoulder and overuse injuries such as tendinopathy and enthesopathy, seems to offer new frontiers of development. The target of these therapies is the inflammatory angiogenesis that can contribute to chronic pain by enabling growth of new unmyelinated sensory nerves along their path. Embolization is performed with both pharmacological agents, such as imipenem/cilastatin sodium and calibrated microspheres (**Figure 1**). Early outcomes seem promising.

In 2006 the new discipline interventional oncology (IO) was founded during the First World Conference of Interventional Oncology in Cernobbio, Italy. About 10 years later, we look forward to a new revolution of this field thanks to the promising progresses of a different clinical discipline, curiously reporting the same acronym, immunooncology (IO). Particular attention of the oncologic community is in fact reserved today to the possibility to maximize the effects of the percutaneous ablative therapies in different districts, for instance renal cryotherapy, radiofrequency, radioembolization of hepatic metastasis, through specific drugs modulating the immune response. The ablative techniques are targeted to the tumor destruction and eventually expose the tumor antigens to the immune system, thus acting as a sort of “anti-tumor vaccine” that can be enhanced by specific molecules (**Figure 2**). The combination of these new drugs targeting both the adaptive and innate immune system with

* Center for Mini-Invasive Interventional and Endovascular Therapies, Department of Diagnostic and Therapeutic Radiology, Centre Hospitalier Universitaire de Dijon, FR

[†] Radiology Residency, Università Statale di Milano, IT

[‡] Department of Radiology, Wakayama Medical University, 811-1 Kimiidera, Wakayamashi, Wakayama 641-8510, JP

Corresponding author: Marco Midulla
(marco.midulla@chu-dijon.fr)

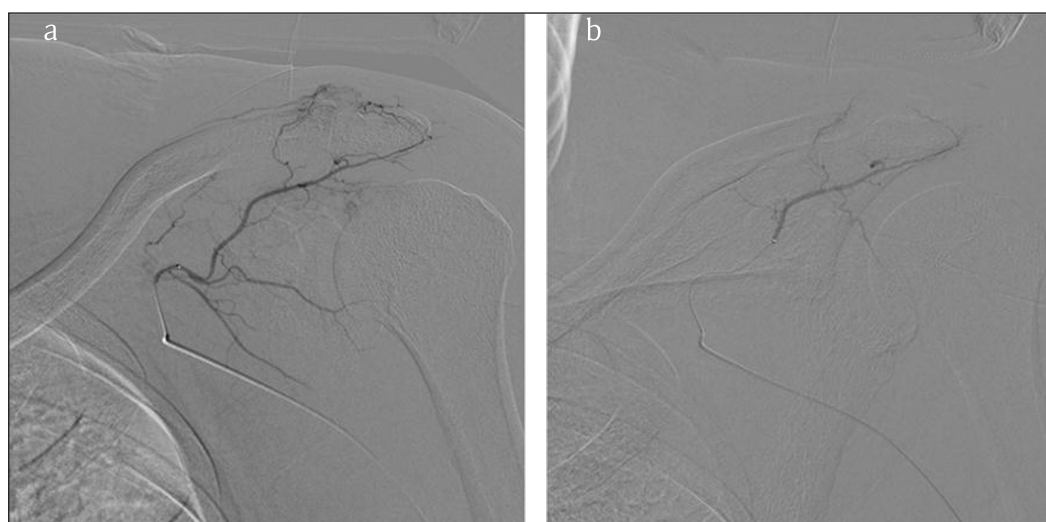

Figure 1: Transarterial treatment of frozen shoulder by particle embolization. **a)** Selective catheterization of thoracoacromial artery from the left subclavian. **b)** Control after superselective injection of 1.5 g of imipenem-cilastatin. Early results of this new therapeutic concept seem promising.

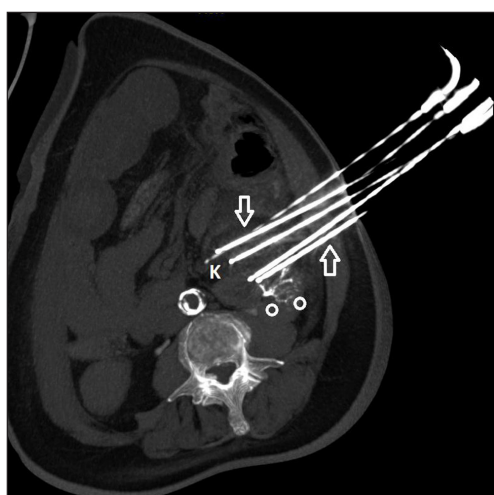


Figure 2: Cryotherapy of a renal mass in an inoperable patient. Combination of the percutaneous ablative therapies and the immune-modulating drugs in the so-called “Interventional Immunooncology” becomes an unexplored field of application with a tremendous potential to investigate in the future.

ablative treatments has been tested in in-animal model showing improvement of mean survival, cytolytic activity, tumor-specific T-cell activation, dendritic cell maturation. In the future, the progressive advancements in the comprehension of the interaction between the interventional therapies and the immune response will promote the clinical applications of interventional immunooncology offering a new exciting field of innovation for the interventional radiologists.

The concept of percutaneous arteriovenous fistula (AVF) creation has been developed during the last three years with two specific different devices. As is well known, AVF provides the best vascular access for hemodialysis in patients with end-stage renal disease, with low risk of infections and better cost-benefit ratio compared to catheters and grafts. The two systems available use a single

or double catheter approach, respectively, while using both an RF tool to create the fusion channel between the arterial and venous wall. The results of the prospective, multicenter trial NEAT (Novel Endovascular Access Trial) have been presented this year in 80 patients showing a success rate of 98%, a primary efficacy endpoint of 87%, a patency rate at 12 months of 69%. These results are in favor of a valuable new mini-invasive modality for creation of functional AVF with low complication rate.

New technological advancements have involved over the last decade the systems of guidance for the interventions. The Multimodality Image Fusion Guided Procedures are the new modern scenario of the Interventional Radiology. The use of the cone-beam CT (CBCT) in combination with preoperative imaging has become an invaluable tool to accomplish complex endovascular repair and improve embolization and interventional oncology practice. The potential introduction of the extended reality (from augmented reality to virtual reality) is a new horizon that can integrate the multimodality guidance and is gaining the attention of new start-ups and commercial companies. Merged (MeR) and Mixed Reality (MxR) are the most adapted concepts for medical applications as they allow interaction with digital objects while preserving contact with the real surrounding environment. Clinical applications include intraprocedural visualization of patients' data, 3D holographic reconstruction of organs' anatomy for virtual interactive assessments and training purposes, and patient and family preoperative information.

Technical and clinical innovations provide the undeniable evolution of IR; nevertheless, interventional radiologists need to concentrate on the clinical value of the specialty, seeing patients and being involved in the multidisciplinary management. Looking to the future and learning from the past.

Competing Interests

The authors have no competing interests to declare.

How to cite this article: Midulla, M, Pescatori, L, Chevallier, O, Nakai, M, Ikoma, A, Gehin, S, Berthod, PE, Ne, R and Loffroy, R. Future of Interventional Radiology: Emerging Techniques. *Journal of the Belgian Society of Radiology*. 2018; 102(S1): 12, 1–3. DOI: <https://doi.org/10.5334/jbsr.1649>

Submitted: 06 September 2018

Accepted: 26 September 2018

Published: 17 November 2018

Copyright: © 2018 The Author(s). This is an open-access article distributed under the terms of the Creative Commons Attribution 4.0 International License (CC-BY 4.0), which permits unrestricted use, distribution, and reproduction in any medium, provided the original author and source are credited. See <http://creativecommons.org/licenses/by/4.0/>.



Journal of the Belgian Society of Radiology is a peer-reviewed open access journal published by Ubiquity Press.

OPEN ACCESS 