

## LIVER HISTOPATHOLOGY AT MICE WITH INDUCED DIABETES TREATED WITH VEGETAL EXTRACT OF *SYLIBUM MARIANUM*

Monica Bucă <sup>1\*</sup>, Magdalena Cristina Zagardan <sup>1</sup>, Mădălina Elena Scarlat <sup>1</sup>,  
Monica Popescu <sup>1</sup>, Alina Păunescu <sup>1</sup>, Cristina Maria Ponopal <sup>1</sup>,  
Alexandru Gabriel Marinescu <sup>1</sup>

<sup>1</sup>University of Pitești, Faculty of Sciences, Târgu din Vale St. 1, 110040, Pitești Romania,

### Abstract

*In this study we have followed the liver's histopathologic changes at CD-line mice (mice rederived from a non-consanguineous stem) with alloxan-induced diabetes, treated with vegetal extract of Sylibum marianum. We have followed the liver's changes of weight following the removal and its histopathologic changes. Thus, mice with weight ranging from 20 to 25 g were divided into three experimental lots, a witness lot, a lot of mice with alloxan-induced diabetes, and another lot with diabetes treated with vegetal extract of Sylibum marianum. Diabetes was induced by administering two doses of Alloxan monohydrate 0,2 ml (130 mg/kg body dissolved in physiological saline), following which 0.2 ml of vegetal extract of milk thistle was administered by gavage during two weeks. The results obtained for the liver blades sampled from the mice with diabetes showed the presence of hepatic steatosis; following the administration of the vegetal extract to the mice with diabetes a decrease of the blisters full of neutral lipids (hepatic triglycerides) can be noticed, which reveals the beneficial action of the vegetal extract of milk thistle*

*Keywords: Alloxan monohydrate, diabetes, liver, milk thistle.*

### 1. INTRODUCTION

World Health Organization considers that diabetes has become a true global epidemic, due to the increased rate of sicknesses over the last 20 years. The rate of diabetes mellitus has increased 8 times globally, and the experts blame this especially on the alarming increase of the incidence of obesity and on the reduction of physical exercise and active lifestyle in modern man's life. The number of non-alcoholic hepatic steatosis has increased in parallel with the cases of obesity. It must be suspected at every overweight or obese person at whom accumulation of fat in the liver is noticed at an ultrasound, especially if it is accompanied by an increased value of the glycaemia, of the fats in the blood or of arterial hypertension. In some cases, the excessive accumulation of fats inside the hepatic cells leads to their destruction, revealed by the increase of transaminases, markers of a liver disorder. Therefore, simple hepatic steatosis has already evolved to the stage of non-alcoholic steato-hepatitis.

Data show that there is a close connection between non-alcoholic hepatic steatosis and type 2 diabetes mellitus: 70-80% of the patients with diabetes also present hepatic steatosis, and 20-50% of those with non-alcoholic steatosis also have type 2 diabetes mellitus. Non-alcoholic

steatosis is the most frequent cause of liver disorder in the developed countries, outnumbering, at present, the disorders associated with hepatitis viruses and alcohol consume.

Diabetes is characterized by high values of glucose in blood (hyperglycaemia) and metabolism disequilibrium. These dysfunctions provoke a disruption of fats distribution, leading to infiltrations of fats in the liver (steatosis) (Ionescu C., 2004). The accumulation of fat in the liver leads to inflammation, lesions, followed by evolutionary scars (fibrosis), with severe consequences: digestive haemorrhage or liver cancer. Unfortunately, the evolution towards fibrosis or cirrhosis lacks symptoms.

Hepatic steatosis represents the accumulation of lipids (fatty acids, triglycerides) in the liver, inside the hepatic cells. It may appear as a consequence of alcohol consumption (alcoholic hepatic steatosis), but it also accompanies obesity/ the metabolic syndrome, in which case it is called non-alcoholic hepatic steatosis.

In the absence of a life-style change, followed by a loss of weight and in the absence of a proper treatment, steatohepatitis can evolve towards the fibrosation of the hepatic tissue, probably even towards hepatic cirrhosis (Harrison, 2014).

## 2. MATERIALS AND METHODS

In this study we have used alloxan monohydrate to induce diabetes to the mice exposed to testing. It is well known the fact that the alloxan is a toxic analogous for glucoses, selectively destroying the cells in the pancreas that produce insulin when it is administered at rodents and other laboratory species, which leads to the appearance of insulin dependent diabetes mellitus (called 'alloxan diabetes') with characteristics similar to those of type 1 diabetes mellitus in human beings. Methods used to induce alloxan diabetes have been described for mice, rats, rabbits and dogs (Nitz de Carvalho et al., 2003). Inducing non-insulin-dependent diabetes mellitus, alloxan diabetes, has been carried out by administering two doses of 130 mg/ kg body alloxan; 48 hours later, glycaemia was established by means of an Accutrend GCT device. The blood was collected from the tail veins by puncture. After the diabetes was installed, vegetal extract of milk thistle was administered by gavage (Popescu, 2014).

*Silybum marianum* commonly known as milk thistle, is an invasive weed, which spreads rapidly in dry, deserted areas. Its seeds contain silymarin (silybin, silychristin and silydianin), bioflavonoids, amino acids (glycerin, leucine, cysteine, tyramine), glutamic acid, fumaric acid, saponin, sterols, tocopherols (Ciulei, 1993). People suffering from diabetes can benefit a lot from milk thistle: a study whose results were published in *Phytotherapy Research* has revealed that silymarin determines an improvement of the glycaemic profile of diabetic patients by significantly decreasing the level of glycosylated haemoglobin, fasting glycaemia (à jeun), as well as LDL-cholesterol and triglycerides, in comparison with patients who have been administered placebo. In addition, milk thistle would also ensure a more efficient control of the glycaemia level at people suffering from diabetes, according to the prestigious Mayo Clinic.

In order to carry out the test we have used CD1 line mice, which were rederived from a non-consanguineous stem and were acquired from 'Cantacuzino' National Research Institute of Bucharest. The animals were acclimatised for a week; they were kept in aquaterrariums, with natural light, complying with the diurnal/nocturne cycles, at adequate temperatures (19 - 25 °C), optimal conditions of noise and humidity (60%), they were properly fed, with free access to food and water while the experiments were carried out (Ciudin, 1996). The experimental lots also contain a witness group for each experiment, made out of a number of minimum 5 animals.

The vegetal extract of *Silybum marianum* was obtained by a series of primary and advanced processing stages through which extractive alcoholic and hydra-alcoholic solutions are obtained out of the vegetal material, using as solvent the ethyl alcohol of different concentrations (Drăgănescu, 2014).

*The experimental lots were divided as follows:*

- A witness group, made out of a minimum number of 5 adult animals, with average weight of 22.2 g, that were not treated with anything and that received just laboratory diet and water ad libitum;
- A group treated with Alloxan, made out of 5 adult mice who were injected intraperitoneally with 0,2 ml solution (130 mg/ kg body weight);
- A group treated with alloxan, who after the diabetes was installed, has received 0.2 ml of vegetal extract of milk thistle by gavage for 2 weeks.

At the end, the animals were anesthetised with chloroform, they were sacrificed by cervical beheading and they were dissected in order to remove the pancreas, which was fixed in aqueous solution of formaldehyde 37%, washed in ethyl alcohol, moved into paraffin, and then cut into sections of 5 $\mu$  and coloured Hematoxyline- Eosin (HE)<sup>16</sup>.

*Statistical analysis.* All values were expressed as mean  $\pm$  SD. Statistical analysis was carried out by one-way ANOVA, LSD test.

### 3. RESULTS AND DISCUSSIONS

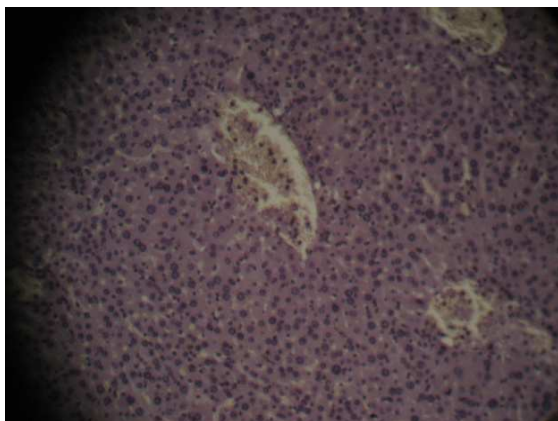
The anti-diabetic activity of the vegetal extract *Silybum marianum* was investigated by determining the physiological index, as well as by highlighting the changes which appear in the liver. Changes of the liver weight in comparison with the body weight are presented in the table below:

**Table 1. Changes of the liver weight in comparison with the body weight**

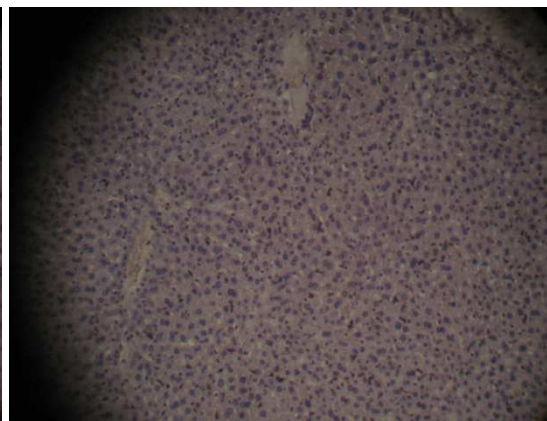<b>Treatment</b>	<b>Body weight (grams)</b>	<b>Liver weight (grams)</b>
<b>Control</b>	<b>22.2<math>\pm</math> 2.01</b>	<b>0.09<math>\pm</math> 0.01</b>
<b>Diabetic</b>	<b>19.8<math>\pm</math> 1.68</b>	<b>0.16<math>\pm</math> 0.06</b>
<b>Vegetal extract of milk thistle</b>	<b>22.2<math>\pm</math> 3.05</b>	<b>0.11<math>\pm</math> 0.02</b>

It is well known the fact that in case of diabetes, the body weight suffers from some changes, consequently in our experiment we have registered a slight decrease of this physiological index along with the injection of alloxan 130 mg/kg body, but, following the administration of the vegetal extract of milk thistle 0.2 ml, during two weeks, a gradual comeback to the initial weight was registered.

A similar aspect was discovered in the case of the liver removed from mice with alloxan diabetes where we have noticed an increase by 70% of the liver weight in comparison with the witness. Following the administration of the vegetal extract of *Silybum marianum*, a decrease by 50% of the liver weight was registered in comparison with the diabetes lot. The same result has also been obtained by Shilpee Chaudhary et al. (2014) and Chung- Hwa Park et al. (2017) when measuring the weight of the liver with hepatic steatosis.



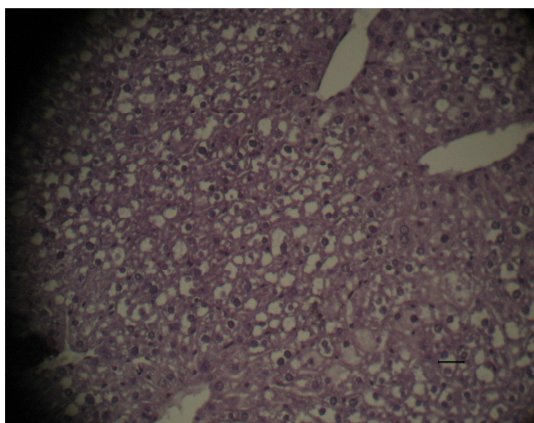
*Figure 1. Section through the liver of the witness group HE, 100X*



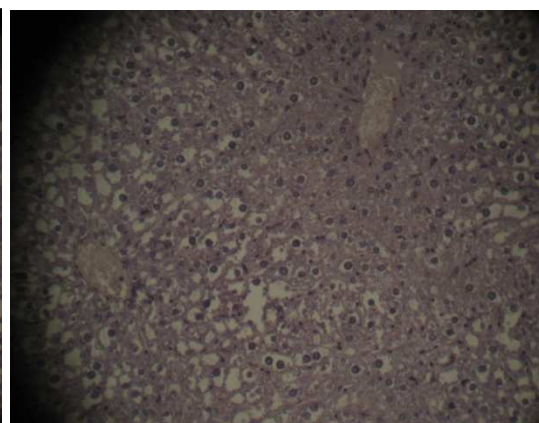
*Figure 2. Section of the liver for the control group HE, 100X*

The liver sections for the mice within the witness group, with no treatment and with normal diet, have presented a normal morphological aspect with healthy hepatocytes and normally positioned nuclei.

It is known that the liver is an efficient buffer-organ which, in those cases in which the plasma lipids overcome the oxidative capacity, intervenes in order to impede the accumulation of circulating lipids and it starts to take over the lipid in TG plasma; this can be also noticed in the case of injecting the toxic alloxan.



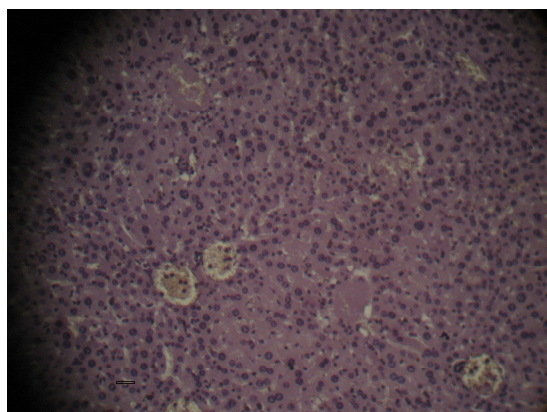
*Figure 3. Section through the liver of the lot with diabetes HE, 100X*



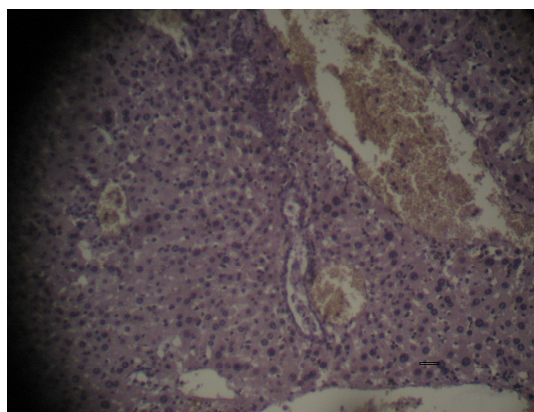
*Figure 4. Section of the liver for the diabetic group HE, 100X*

The histopathologic examination of the liver at mice with diabetes induced by alloxan has revealed a multitude of blisters charged with neutral lipids (hepatic triglycerides), bloated hepatocyte which demonstrates the presence of the hepatic steatosis ranging from moderate to severe. Similar results were registered by Xunjun Ni and Haiyan Wang (2016) and Shilpee Chaudhary et al. (1014) for induced steatosis NAFDL.





*Figure 5. Section of the liver for the diabetic group treated with vegetal extract of milk thistle HE, 100X*



*Figure 6. Section through the liver of the lot with diabetes treated with vegetal extract of milk thistle HE, 100X*

Regarding the sections through the liver of the mice treated with vegetal extract of *Silybum marianum*, it was noticed a significant reduction of hepatic lipids (triglycerides) vacuolisation, of the hepatocyte balloon and, therefore, of the hepatic steatosis. The reduction of the hepatic steatosis under treatment with silymarin was also obtained by Xunjun Ni and Haiyan Wang (2016) and Zhu Sy et al. (2018), and under treatment with antociani by Chung- Hwa Park et al. (2017).

The sizes and number of the steatosis blisters are presented in the table below:

*Table 2. The sizes and number of the steatosis blisters*

<i>Treatment</i>	<i>Number (mg/dL)</i>	<i>Size of adipose cell (nm)</i>
<i>Diabetic</i>	<i>310</i>	<i>60</i>
<i>Vegetal extract of milk thistle</i>	<i>245</i>	<i>45</i>

#### 4. CONCLUSIONS

The liver ensures the transport of fats in the blood, but it is also a good buffer in order to avoid their accumulation in the blood plasma, which was also demonstrated in the case of injecting the toxic alloxan.

Inducing alloxan diabetes by administering two doses of Alloxan monohydrate 0,2 ml (130 mg/kg body dissolved in physiological saline) has led to a body weight decrease by 20% in comparison to the witness, but, once the vegetal extract 0.2 ml was administered by gavage, for two weeks, it was noticed that the body weight has returned to its normal status.

As far as the liver weight is concerned, following the administration of two doses of Alloxan monohydrate 0,2 ml (130 mg/kg body dissolved in physiological saline) we have recorded an increase of 70% in comparison with the witness group and a decrease of 50% of its weight following the treatment with milk thistle 0,2 ml.

The liver's histopathologic changes for the two lots of mice present the following results: accumulations of lipid vacuoles and flatulence of hepatocytes appeared as a consequence of hepatic

steatosis following the administration of alloxan monohydrate, whereas for the lot treated with vegetal extract of *Silybum marianum*, a significant reduction of the degree of hepatic steatosis and of the blisters loaded with neutral lipids (triglycerides) was noticed.

According to the results obtained, the vegetal extract of *Silybum marianum* has a beneficial and restructuring effect over the body weight, the liver's weight, as well as in the case of hepatic steatosis.

## 6. REFERENCES

- Ciudin, E., Marinescu, D. (1996). *Animale de laborator [Laboratory animals]*, Vol. I. Ed. All, București.
- Ciulei, I., Stănescu, U., Grigorescu, E. (1993). *Plantele medicinale - fitochimie și fitoterapie [Medicinal plants- phytochemistry and phytotherapy]*, Vol. I, II. Ed. Medicală, București.
- Constantin, I.T. (2004). *Tratat de Diabet Paulescu [Treated with Diabetes Paulescu]*, Ed. Academiei Române, București.
- Drăgănescu, D. (2014). *Extracția și caracterizarea unor compuși bioactivi din materiile vegetale, utilizați în domeniul farmaceutic sau cosmetic [Extraction and characterization of bioactive compounds from vegetable matter, used in the pharmaceutical or cosmetic field]*, Iași.
- Clapper, J.R., Hendricks, M.D., Gu, G., Wittmer, C., Dolman, C.S., Herich, J., Athanacio, J., Villescaz, C., Ghosh, S.S., Heilig, J.S. (2013). Diet-induced mouse model of fatty liver disease and nonalcoholic steatohepatitis reflecting clinical disease progression and methods of assessment. *Am J Physiol Gastrointest Liver Physiol.* 305(7), G483–G495.
- Flora, K., Hahn, M., Rosen, H., Benner, K. (1988). Milk thistle (*Silybum marianum*) for the therapy of liver disease. *Am J Gastroenterol*, 93, 139–143.
- Harrison, (2014). *Manual de Medicină [ Handbook of Medicine]*, Editura ALL.
- Hermenean, A., Stan, M., Ardelean, A., Pilat, L., Mihali, C.V., Popescu, C., Nagy, L., Deák, G., Zsuga, M., Kéki, S. (2015). Antioxidant and hepatoprotective activity of milk thistle (*Silybum marianum* L. Gaertn.) seed oil. *Open Life Sciences.* 10.
- Hoe- Yune Jung, Yu- Hee Kim, Ju Seong Jeong, Jung- Han Lee, Myoung- Sool Do, Seung- Pil Jung, Kwang- Soo Kim, Kyong- Tai Kim and Jong- Bae Kim. (2013). The Korean Mistletoe (*Viscum album coloratum*) Extract Has an Antiobesity Effect and Protects against Hepatic Steatosis in Mice with High-Fat Diet-Induced Obesity. *Evidence- Based Complementary and Alternative Medicine.*
- Jun, Shirakawa, Hideki, Fujii, Kei, Ohnuma, Koichiro, Sato, Yuzuru, Ito, Mitsuyo, Kaji, Eri, Sakamoto, Megumi, Koganei, Hajime, Sasaki, Yoji, Nagashima, Kikuko, Amo, Kazutaka, Aoki, Chikao, Morimoto, Eiji, Takeda and Yasuo, Terauchi. (2011). Diabet- Induced Adipose Tissue, Inflammation and Liver Steatosis Are Prevented by DPP- 4 Inhibition in Diabetic Mice. US National Library of Medicine. National Institutes of Health, *Diabetes*, Apr 60 (4), 1246-57
- Lee, H.Y., Birkenfeld, A.L., Jornayvaz, F.R., Jurczak, M.J., Kanda, S., Popov, V., Frederick, D.W., Zhang, D., Guigni, B., Bharadwaj, K.G., Choi, C.S., Goldberg, I.J., Park, J.H., Petersen, K.F., Samuel, V.T., Shulman, G.I. (2011). Apolipoprotein CIII overexpressing mice are predisposed to diet-induced hepatic steatosis and hepatic insulin resistance. US National Library of Medicine. National Institutes of Health, *Hepatology*; 54(5), 1650-1660.
- Yaligar J., Gopalan V., Kiat O.W., Sugii S., Shui G., Lam B.D., Henry C.J., Wenk M.R., Velan S.S. (2014). Evaluation of dietary effects on hepatic lipids in high fat and placebo diet fed rats by in vivo MRS and LC-MS techniques. US National Library of Medicine. National Institutes of Health, *Plos One*; 17, 9 (3), e91436.
- Nitz de Carvalho, Ferreira, L.M. (2003). Experimental model of induction of diabetes mellitus in rats. *Acta Cir Bras*, Vol 18 Special Edition.
- Park, C.H., Kim, J.H., Lee, E.B., Hur, W., Kwon, O.J., Park, H.J., Yoon, S.K. (2017). Aronia melanocarpa Extract Ameliorates Hepatic Lipid Metabolism through PPAR $\gamma$ 2 Downregulation. US National Library of Medicine. National Institutes of Health. *PLoS One.* 12 (1)e0169685.
- Parmar, M., Gandhi, T. (2008). Hepatoprotective herbal drug, silymarin from experimental pharmacology to clinical medicine-A review. *Pharmacognosy Reviews*, 2, 102.
- Popescu, R.M., Berbecatu – Iovan, A., Mogoșanu, G. D. (2014). Evaluation of hypoglycemic and hypolipidemic effect of some vegetal extracts, using mice whit streptozotocin- experimentally induced diabetes. *Curent Health Sciences Journal*, 2, 52-58.
- Shiplee, Chaudhary, Soumita, De, Vijayaraj, Devisingh, Mallikarajun, S. Jaji, Jayanarayan, Kulathingal, Nagaraj, M. Kulkarni, Vinitha, P. Lakshmi, Jeyamurugan, Mookkan, Shridhar, Narayanan, Navin, B. Rajesh, Pranasha

- Shetty. (2014). Combination of vildagliptin and rosiglitazone ameliorates nonalcoholic fatty liver disease in C57BL/6 mice. *Indian Journal of Pharmacology*, 46(1), 45- 50.
- Xunjun, Ni and Haiyan, Wang ( 2016). Silymarin attenuated hepatic steatosis through regulation of lipid metabolism and oxidative stress in a mouse model of nonalcoholic fatty liver disease (NAFLD). US National Library of Medicine. National Institutes of Health. *Am J Transl Res*, 8 (2), 1073- 1081;
- Zhu, S.Y., Jiang, N., Yang, J., Tu, J., Zhou, Y., Xiao, X., Dong, Y. (2018). Silybum marianum oli attenuates hepatic steatosis and oxidative stress in high fat diet- fed mice. US National Library of Medicine. National Institutes of Health. *Biomed Pharmacother.* 100, 191-197.
- Wuescher, L., Angevine, K., Patel, P. R., & Mensah-Osman, E. (2012). Menin liver-specific hemizygous mice challenged with high fat diet show increased weight gain and markers of metabolic impairment. *Nutrition & diabetes*, 2(5), e34.