

---

## GYNAECOLOGY

---

# Evaluation of Adnexal Masses by Three-Dimensional Ultrasound Multi-slice View: Do we really need it?

Ahmed Mohamed Abbas MD,  
Kamal M. Zahran MD,  
Ahmed Nasr MD,  
Hassan Salah Kamel MD.

*Woman's Health Center, Assiut University, Assiut, Egypt.*

### ABSTRACT

**Objective:** The purpose of this study is to evaluate the benefit of use of three-dimensional ultrasound multi-slice view in detailed assessment of adnexal masses morphology.

**Methods:** Two-hundred thirty one patients with adnexal masses elected for surgery at Woman's Health Center, Assiut, Egypt between October 2012 and October 2013 were recruited for the study. Each patient had 2D ultrasound and detailed morphological evaluation was reported. Then, 3D ultrasound volumes were obtained. The stored 3D volumes were then digitally analyzed using 3D ultrasound multi-slice view. The results of 2D, 3D ultrasound multi-slice were compared to the postoperative histopathological findings.

**Results:** The mean age of included patients was  $30.2 \pm 12.7$  years. Overall, 189 patients (81.8%) confirmed to have benign masses, and 42 patients (18.2%) with malignant masses according to their final histopathological analysis. Subjective assessment by 2D ultrasound correctly classified 95.6% of benign masses and 87% of malignant masses. On detailed assessment of the masses by 3D ultrasound multi-slice view, there was agreement in morphological assessment of all masses except in 3 cases in which 3D ultrasound multi-slice view permitted better description of their morphological criteria and hence changing the presumed diagnosis and management.

**Conclusions:** The ability of detailed analysis of the volumes taken during 3D ultrasound using multi-slice view can aid in better morphological assessment of adnexal masses especially in detection of papillary projections in adnexal cysts. This information is valuable in deciding the optimal management of adnexal masses in some cases.

**Keywords:** adnexal mass, 3D ultrasound, multi-slice view, tomographic ultrasound

**Correspondence to:** *Ahmed Mohamed Abbas, MD, Women's Health Hospital, Assiut University, Assiut, Egypt.  
Business telephone number: +20882414616, Cellular phone number: +2 01003385183,  
Postal code: 71111, E-mail: bmr90@hotmail.com*

## Introduction

We live in a three dimensional world. Thanks to our binocular vision, a third dimension to otherwise two dimensional pictures is added. So it is natural that ultrasound technology started to look at the possibility of displaying ultrasound images in a perceivable 3D reconstruction of an ultrasound image<sup>(1)</sup>. In spite of 3D ultrasound cannot replace 2D ultrasound, many additional benefits will be identified and its use will continue to grow<sup>(2)</sup>.

Although an experienced sonographer can develop a three dimensional image in his mind by a "mental processing" of a sequence of two dimensional images, certain planes of the pelvic organs are difficult to be acquired<sup>(3)</sup>. 3D ultrasound is an easy method for the differential diagnosis of various pathological conditions of the ovary. Advances in 3D ultrasound technology allow the application of higher-frequency probes in the analysis of morphological anatomy and in volume measurement of the ovaries<sup>(4)</sup>.

The multi-slice view (MSV) mode or Tomographic ultrasound imaging (TUI) permits concurrent display of multiple chronological parallel views of a reference (sagittal, transverse or coronal) plane of an object. The reference plane, the number of multislice images displayed within the screen ( $1 \times 1$ ,  $2 \times 1$ ,  $3 \times 2$ ,  $4 \times 3$  or  $6 \times 4$ ), the orientation and rotation of an image, the magnitude of magnification and slice depth and interval (0.5 to 5 mm) can be adjusted according to the region of interest<sup>(5)</sup>.

The MSV mode allows parallel slices of a region of interest to be specifically displayed on a screen. Alternatively, the sonographer could navigate through the same volume dataset, using a series of images, by the more conventional multiplanar technique<sup>(6)</sup>.

3D ultrasound MSV combines the advantages of ultrasound, e.g. safety, simplicity of application and inexpensiveness (in contrast to MRI and CT), with the advantage of the third dimension<sup>(7)</sup>.

Many studies have been published aiming to determine if 3D ultrasound is better than 2D ultrasound in evaluation of adnexal masses<sup>(8,9)</sup>. All of them used similar 3D ultrasound approach for assessing ovarian

tumors: multiplanar display and surface rendering mode to show the morphological features of the mass such as internal wall surface and presence of septations<sup>(10)</sup>. To the best of our knowledge, no reports in the published literature related to the use of 3D ultrasound MSV in the evaluation of adnexal masses. The aim of the study was to show if there is any additional information could be obtained from detailed morphological assessment of adnexal masses by 3D ultrasound MSV after careful evaluation by the conventional 2D ultrasound.

## Materials and Methods

The study period was one year starting from the 1<sup>st</sup> of October 2012 till the 30<sup>th</sup> of September 2013, 231 patients diagnosed as having an adnexal mass and scheduled for surgical management at Woman's Health Center, Assiut, Egypt, were included in this prospective study.

The study was approved by the Ethical Review Board of Assiut faculty of medicine and all patients gave written informed consent. Diagnostic work-up included a complete medical history, physical examination, and then initial 2D ultrasound evaluation of the mass was done followed by obtaining the 3D ultrasound volumes.

The acquired volumetric data were stored on a hard disk to enable full evaluation without loss of information at any time, subsequently all recordings were reviewed systematically. All masses were evaluated within 24 hours by 3D ultrasound MSV.

Ultrasonographic evaluation was done using a Sono-Ace X8 machine (Medison, Korea) with multifrequency transabdominal and transvaginal volumetric probes by the same sonographer (level II experience).

All patients were subsequently managed according to their clinical and ultrasound features. Surgical removal of the mass by laparoscopy or laparotomy was done followed by histopathological examination to confirm their nature, as the histopathological diagnosis was considered the gold standard to define the outcome, being classified as; benign or malignant.

## Results

The mean ( $\pm$ SD) age of patients included in the study was  $30.2 \pm 12.7$  years (range 12-70 years). One-hundred ninety eight patients (85.7%) were in the reproductive age, 26 were postmenopausal (11.3%), and 7 of them (3%) were in the premenarche period. Ninety five patients (41.1%) were nulliparous.

Overall, 189 patients (81.8%) confirmed to have benign masses, and 42 patients (18.2%) with malignant masses according to their final histopathological analysis. Number of the evaluated masses was 251 masses (due to bilaterality of masses in 20 patients); 205 proved to be benign and 46 malignant. The final histopathological results were shown in (Table 1).

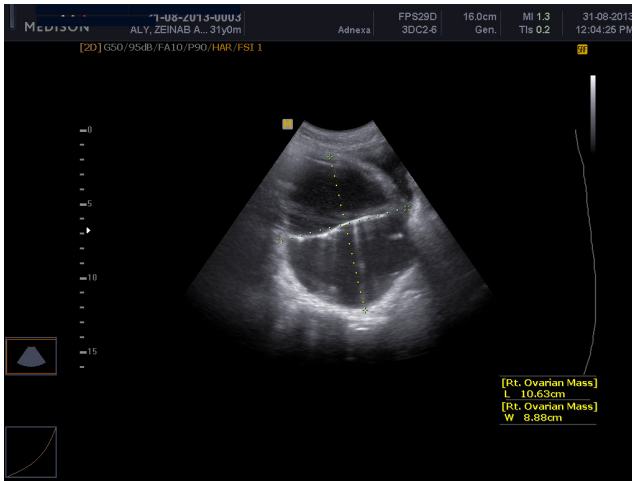
**Table 1.** Distribution of the final pathological diagnosis of the adnexal masses

Diagnosis	number	%
<b>Benign masses</b>		
Endometriotic cyst	69	27.5
Simple serous cyst	41	16.3
Dermoid cyst	29	11.6
Hemorrhagic corpus luteum cyst	18	7.2
Mucinous cystadenoma	13	5.2
Tuboovarian abscess	10	4.0
Fibroma/thecoma	6	2.4
Leiomyoma	4	1.6
Serous cystadenoma	3	1.2
Others	12	4.8
<b>Borderline malignant masses</b>		
Borderline serous cystadenoma	4	1.6
Borderline mucinous cystadenoma	4	1.6
<b>Malignant masses</b>		
Mucinous cystadenocarcinoma	11	4.4
Serous cystadenocarcinoma	6	2.4
Granulosa cell tumor	6	2.4
Metastatic adenocarcinoma	5	2.0
Immature teratoma	3	1.2
Others	7	2.8
<b>Total</b>	<b>251</b>	<b>100</b>

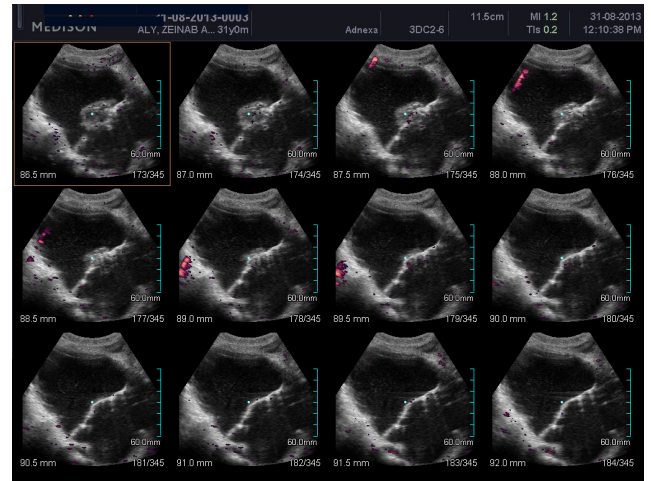
Of the 205 benign masses, 196 masses (95.6%) were correctly classified as benign, and of the 46 malignant masses, 40 masses (87%) were correctly classified as malignant. Borderline malignant masses were classified and considered as malignant on ultrasound evaluation. Fifteen masses out of the whole 251 masses (6%) were incorrectly classified as benign or malignant using subjective assessment by 2D ultrasound examination. The difference was statistically

significant ( $p < 0.001$ ).

On evaluation of the masses by 3D ultrasound MSV, criteria of morphological assessment were different only in 3 cases. The first was labeled by 2D ultrasound as a benign mass, on examination by 3D ultrasound MSV, a solid papillary projection  $> 3$  mm was shown arising from one of the septae changing the possibility of the mass to malignant one. Histopathological evaluation confirmed its malignant nature (Fig. 1).



**A**

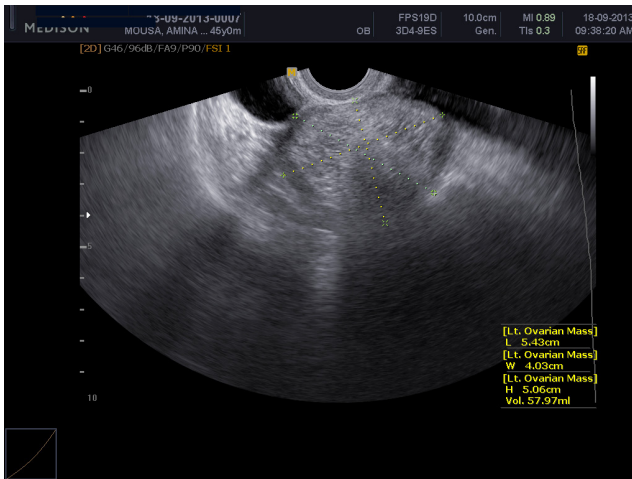


**B**

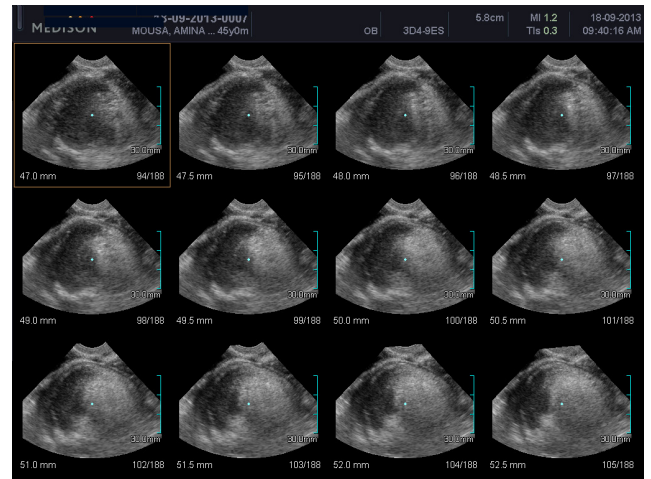
**Fig. 1.** Mucinous cystadenocarcinoma of the right ovary. A, 2D ultrasound scan shows Multilocular ovarian cyst. Thin septum with no papillary projections was seen inside the mass suggestive of its benign nature. B, 3D ultrasound multislice view of the same mass shows solid papillary projection > 3 mm arising from the septum.

The second was labeled by 2D ultrasound as a solid mass with suspicion of malignancy but on 3D ultrasound MSV, it appeared as a cystic on many axial

views with high echogenic contents (thick sebaceous material). The mass was proved to be dermoid cyst (Fig. 2).



**A**

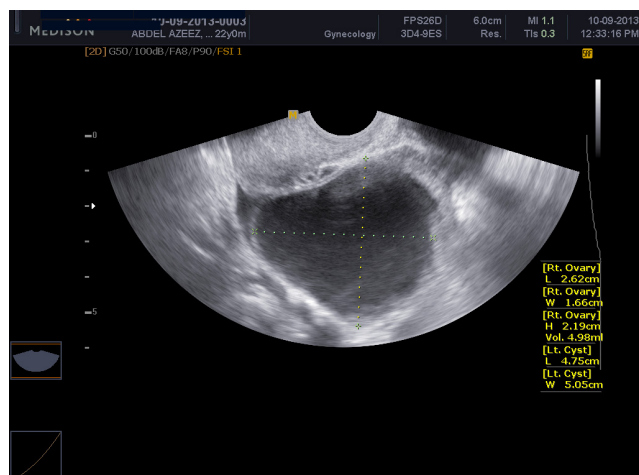


**B**

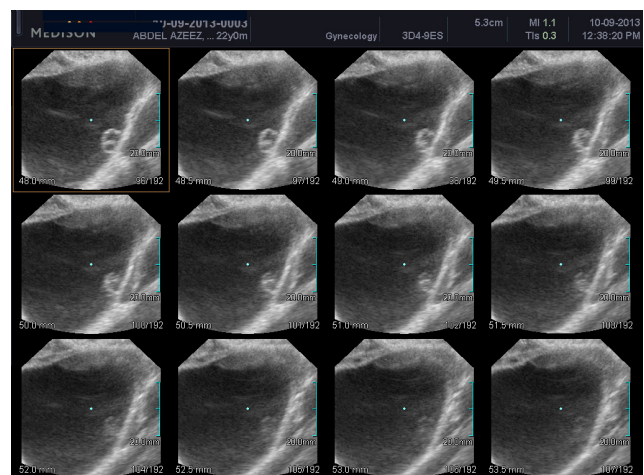
**Fig. 2.** Dermoid cyst of the left ovary in 62 year-old woman. A, 2D ultrasound scan shows solid ovarian mass with suspicion of malignancy. B, 3D ultrasound multislice view of the same mass shows its cystic nature with echogenic contents.

The last one appeared by 2D ultrasound as a unilocular small cyst and labeled as benign cyst for conservative management. On 3D ultrasound MSV a small papillary projection appeared in its wall changing

the decision of management. Surgical interference was done and the histopathological report revealed borderline serous cystadenoma (Fig. 3).



A



B

**Fig. 3.** Borderline serous cystadenoma of the left ovary. A, 2D ultrasound scan shows benign looking small unilocular cyst. B, 3D ultrasound multislice view of the same mass shows small papillary projection in the wall.

## Discussion

The results of our study show that 3D ultrasound MSV is useful for morphological assessment of adnexal masses as a supplement to 2D ultrasound especially in assessment of the internal structure of adnexal cysts. This was clear in the additional 3 cases accurately diagnosed when detailed morphological assessment of the masses was done using 3D ultrasound MSV.

The differential diagnosis of adnexal masses still represents a challenge in spite of the marvelous efforts that have been made to improve the sonographically based diagnosis. The last years has seen rapid technological advances in the field of ultrasonography, with the recent development of three-dimensional gray-scale volume imaging and 3D power Doppler imaging. Initial studies had suggested that these new technologies may improve the diagnostic accuracy of 2D ultrasound in the discrimination between benign and malignant adnexal masses<sup>(11)</sup>.

No previous studies were published in the literature had analyzed the role of 3D multi-slice

ultrasound in discriminating malignant and benign adnexal masses. All masses in our study were examined by 3D ultrasound MSV in which serial axial views of the mass were obtained to allow detailed examination of the masses. The results obtained on evaluation of the masses were superior only in 3 cases on 2D ultrasound.

Computed tomography and magnetic resonance imaging use the same approach (display of several slices on the same screen to be compared). Magnetic resonance imaging is frequently used as an additive technique for the evaluation of adnexal masses<sup>(12)</sup>.

Previous studies concluded that papillary projections can be missed on 2D ultrasound<sup>(13)</sup> and MRI<sup>(14)</sup>, mainly because of their small size (< 5 mm). In our study, 3D ultrasound MSV could diagnose 2 missed cases by conventional 2D ultrasound as stated before.

No more information obtained from MSV evaluation of the morphology of masses to prove its routine application in adnexal masses assessment.



Besides, the quality of the third plane obtained in 3D ultrasound MSV is usually worse than that of the other parallel and perpendicular planes to the probe. This was consistent with Leung et al conclusions<sup>(5)</sup>.

One limitation was seen in our study that was the absence of an overview image, which for practical referencing should be displayed on the same screen. Changing the mass position and orientation during interpretation of the series of parallel slices could have been easier if there is anatomical orientation of the exact level had been automated as slicing was performed.

In conclusion, 3D ultrasound MSV can be helpful in the morphological assessment of adnexal masses especially in detection of papillary projections in adnexal cysts. So, it could add a benefit to patients who presented with suspicious cysts especially in postmenopausal women. This may change the decision of the optimal management of adnexal masses in those patients; otherwise it was not superior on the routine 2D ultrasound evaluation of adnexal masses.

## Acknowledgement

We would like to thank all members of "Ultrasound unit" in Woman's Health Center.

## References

1. Mertz E. 3-D ultrasound in prenatal diagnosis. In: Mertz E, ed. *Ultrasound in Obstetrics*. Stuttgart: Thieme Verlag; 2004.
2. Pretorius DH, Borok NN, Coffer MS, Nelson TR. Three-dimensional ultrasound in obstetrics and gynecology. *Radiol Clin North Am* 2001;39:499-521.
3. Pederson MH and Larsen T. Three-dimensional ultrasonography in obstetrics and gynecology. *Ugeskr Laeger* 2001;163:594-9.
4. Coyne L, Jayaprakasan K, Raine-Fenning N. 3D ultrasound in gynecology and reproductive medicine. *Womens Health (Lond Engl)* 4:501e16; 2008.
5. Leung KY, Ngai CS, Chan BC, Leung WC, Lee CP, Tang MH. Three-dimensional extended imaging: a new display modality for three-dimensional ultrasound examination. *Ultrasound Obstet Gynecol* 2005;26:244-51.
6. Timor-Tritsch IE and Platt LD. Three-dimensional ultrasound experience in obstetrics. *Curr Opin Obstet Gynecol*. 2002;14:569-75.
7. Baba K. *Obstetrics and Gynecology*. Nippon Rindsho. 2004;62:807-14.
8. Alcázar JL, Galán MJ, García-Manero M, Guerriero S. Three-dimensional ultrasound morphologic assessment in complex adnexal masses a preliminary experience. *J Ultrasound Med* 2003;22:249-54.
9. Laban M, Metawee H, Elyan A, Kamal M, Kamel M, Mansour G. Three-dimensional ultrasound and three-dimensional power Doppler in the assessment of ovarian tumors. *Int J Gynecol Obst* 2007;99,201-5.
10. Alcázar JL, Jurado M. Three-dimensional ultrasound for assessing women with gynecological cancer: a systematic review. *Gynecol Oncol* 2011;120:340-6.
11. Zoorob R, Anderson R, Cefalu C, Sidani M. Cancer screening guidelines. *Am Fam Phys* 2001;15; 63:1039-43.
12. Outwater EK and Mitchell DG. MRI techniques in the pelvis. *Magn Reson Imaging Clin Am*. 1994;2:161-88.
13. Ekerhovd E, Wienerroith H, Staudach A, Granberg S. Preoperative assessment of unilocular adnexal cysts by transvaginal ultrasonography: A comparison between ultrasonographic morphologic imaging and histopathologic diagnosis. *Am J Obstet Gynecol* 2001;184:48-54.
14. Outwater EK, Huang AB, Dunton CJ, Talerman A, Capuzzi DM. Papillary projections in ovarian neoplasms: appearance on MRI. *J Magn Reson Imaging* 1997;7:689-95.