

Single Case

A Highly Advanced Gastric Cancer Maintaining a Clinical Complete Response after Chemoradiotherapy Comprising S-1 and Cisplatin

Masahiro Yura^a Tsunehiro Takahashi^a Kazumasa Fukuda^a
Rieko Nakamura^a Norihito Wada^a Junichi Fukada^b
Hirofumi Kawakubo^a Hiroya Takeuchi^c Naoyuki Shigematsu^b
Yuko Kitagawa^a

^aDepartment of Surgery, Keio University School of Medicine, Tokyo, Japan; ^bDepartment of Radiology, Keio University School of Medicine, Tokyo, Japan; ^cDepartment of Surgery, Hamamatsu University School of Medicine, Hamamatsu-shi, Japan

Keywords

Advanced gastric cancer · Chemoradiotherapy · Clinical complete response · Long survival · Para-aortic lymph node metastasis

Abstract

We report a patient with highly advanced gastric carcinoma who was treated successfully with chemoradiotherapy (CRT) comprising S-1 and cisplatin. The patient was a 71-year-old male who was diagnosed with advanced gastric carcinoma by esophagogastroduodenoscopy (EGD) by medical examination. EGD demonstrated type 3 advanced gastric carcinoma in the posterior wall of the upper gastric body. An abdominal computed tomography (CT) scan showed that the gastric wall was thickened due to gastric primary tumor, and large lymph nodes (LNs) including the lesser curvature LN, anterosuperior LN along the common hepatic artery and some para-aortic LNs were detected. The patient was diagnosed with stage IV advanced gastric carcinoma according to the Japanese classification of gastric carcinoma (cT4a, cN3, cM1 [para-aortic LN], cStage IV). Preoperative CRT was carried out in an attempt to downstage the disease. Remarkable reduction of the primary tumor and metastatic LNs was observed after initial

CRT, and radiological examination determined that a partial response had been achieved. Adverse effects included grade 2 anorexia and grade 3 ALP elevation (919 U/ml). No grade 4 or more severe adverse event was observed. After CRT, although we recommended curative surgery, the patient refused surgical treatment and opted for conservative treatment. Thus, we continued S-1 oral administration for 1 year. Five months after beginning CRT, upper endoscopy showed that the tumor had maintained regression and scar formation, in which no cancer cells were detected by endoscopic biopsy. The patient is doing well and has maintained a clinical complete response for more than 42 months without curative surgery. CRT could be considered as an option for treatment of patients with locally advanced gastric carcinoma diagnosed as unresectable, or for those who refuse surgical treatment.

© 2018 The Author(s)
Published by S. Karger AG, Basel

Introduction

At present, patients diagnosed with early gastric cancer show a remarkable 5-year overall survival rate of >90%. Conversely, the locoregional and distant recurrence rates are high with advanced stage disease. Patients diagnosed with stage IV gastric cancer (based on the Japanese classification of gastric carcinoma) have a poor 5-year survival rate (16.6%) even if they undergo gastrectomy plus extended D2 lymph node (LN) dissection [1]. In addition, it was reported that the median survival duration of patients with unresectable highly advanced gastric cancer was 13 months [2]. To establish a more effective multidisciplinary treatment for these patients, adjuvant chemotherapy and chemoradiotherapy (CRT) have been considered.

In the US and Europe, the efficacy of perioperative CRT for gastric cancer has been reported in several trials. Macdonald et al. [3] reported that the median overall survival duration in a surgery-only group was 27 months, compared with 36 months in a postoperative CRT group. Lee et al. [4] showed that CRT led to a significant prolongation of postoperative disease-free survival in gastric cancer patients with LN metastasis in the ARTIST trial. Because of higher compliance than with adjuvant treatment, neoadjuvant treatment for advanced gastric cancer has been reported to be more beneficial [5]. Ajani et al. [6, 7] showed that neoadjuvant CRT might prolong postoperative survival. Recently, Stahl et al. [8] suggested a benefit in progression-free survival when radiotherapy was added to preoperative chemotherapy in patients with locally advanced adenocarcinoma of the esophagogastric junction. In Japan, CRT has not been established as a standard treatment. Its indications are limited, and it is often performed as palliative care. In recent years, technological improvement of radiation therapy has enabled accurate treatment of primary gastric cancer lesions and regional LNs. Therefore, we previously reported a phase I study of neoadjuvant CRT with S-1 plus cisplatin (KOGC-04) to improve the prognosis of advanced cases [9]. We here describe a patient with highly advanced gastric carcinoma who was treated successfully with CRT comprising a combination of S-1 and cisplatin.

In this case, a clinically complete response was achieved and had been maintained for >42 months after initial CRT. Prolonged survival of patients whose initial diagnosis was stage IV advanced gastric cancer treated only with CRT, without curative surgery, has not been reported previously.

Case Presentation

Staging and Classification

The tumors were classified in accordance with the Japanese classification of gastric carcinoma, 3rd English edition [10]. The toxicity of S-1 and cisplatin was also classified using the Common Terminology Criteria for Adverse Events (CTCAE), ver. 3.0.

Pretreatment Diagnosis

The patient was a 71-year-old male diagnosed with advanced gastric cancer by esophagogastroduodenoscopy (EGD) and medical examination. The serum carcinoembryonic antigen and carbohydrate antigen 19-9 levels were 3.0 U/ml and 10 U/ml, respectively. EGD demonstrated type 3 advanced gastric carcinoma in the posterior wall of the upper gastric body. A biopsy specimen indicated that this was a well to moderately differentiated tubular adenocarcinoma. An abdominal computed tomography (CT) scan showed that the gastric wall was thickened due to gastric primary tumor, and large LNs including the lesser curvature LN (9.1 × 7 mm), anterosuperior LN along the common hepatic artery (12.3 × 10.3 mm), and some para-aortic LNs (the biggest one: 21.1 × 13.7 mm) were detected. The patient was diagnosed with stage IV advanced gastric carcinoma according to the Japanese classification of gastric carcinoma (cT4a, cN3, cM1 [para-aortic LN], cStage IV). Preoperative CRT was carried out in an attempt to downstage the disease. CRT was performed with the patient's informed consent in accordance with the advanced gastric carcinoma treatment protocols of KOGC-04, which had been reported in a prior phase I study.

Chemoradiotherapy

The CRT consisted of the administration of S-1 plus biweekly cisplatin and radiation. The initial CRT schedule was for 6 weeks: S-1 was orally administered every day on days 1–15, and the S-1 dose was 100 mg/day based on the patient's body surface area. Cisplatin was administered by infusion over 1 h on days 1 and 15 without infusional hydration. The dose of cisplatin was 20 mg/m².

Radiotherapy was conducted using photons from a linear accelerator, and three-dimensional planning was performed. The clinical target volume included the primary tumor with a 3-cm margin and metastatic lymph nodes with a 1-cm margin. The planning target volume contained the clinical target volume with a 2-cm margin to account for setup and organ motion (Fig. 1). A total dose of 40 Gy was delivered in 2-Gy fractions at a rate of 5 fractions per week. After the initial CRT, 1 cycle of combination chemotherapy with S-1 plus biweekly cisplatin was delivered. Regarding antiemetic medication, we routinely used 5-HT₃ antagonists and dexamethasone before each cisplatin infusion.

Radiological Evaluation and Toxicities

After CRT, EGD showed remarkable tumor regression and scar formation. A CT scan showed marked reduction of the primary tumor and metastatic LNs (Fig. 2) (the LN of the lesser curvature could not be detected, the anterosuperior LN along the common hepatic artery became smaller [12.3 × 10.3 mm → 6.7 × 3.8 mm], and the para-aortic LN also became smaller [21.1 × 13.7 mm → 8.8 × 6.7 mm]). Radiological examination determined that a partial response had been achieved by the initial therapy. With this regimen, grade 2 anorexia and grade 3 ALP elevation were observed according to the CTCAE ver. 3.0., and no grade 4 or more severe adverse event was detected.

Post-CRT Course

After evaluation of the response to CRT, we recommended curative surgery (total gastrectomy with extended D2 LN dissection). However, the patient refused surgical treatment and opted for conservative treatment. Thus, we continued S-1 oral administration for 1 year. At 5 months after the first treatment, EGD showed that the tumor lesion had maintained scar formation (Fig. 3) and no cancer cells were detected by endoscopic biopsy (Fig. 4). A clinically complete response was achieved and has been maintained. No recurrence has been detected in this patient for >42 months since initial CRT.

Discussion

Several clinical trials for unresectable gastric cancer that compared CRT with chemotherapy and radiotherapy alone have been reported since the late 1960s.

Childs et al. [11] showed that survival duration with radiotherapy alone was 5.7 months, compared to 11 months with CRT. Ajani et al. [6] in 2004 showed that neoadjuvant CRT might prolong postoperative survival. The CRT comprised 2 cycles of 5-FU, LV and cisplatin following CRT with 5-FU with 45 Gy radiation therapy. Thirty-three patients diagnosed with resectable gastric cancer were registered, 28 of whom were treated with gastrectomy. R0 resection was achieved in 70% of the patients and 30% of those who underwent gastrectomy exhibited a histopathological complete response (pCR). The median survival time of the patients was 33.7 months – 63.9 months for responders and 12.6 months for nonresponders; the difference was significant. The RTOG 9904 study of neoadjuvant CRT for gastric cancer was reported in 2006 [7] and involved 2 courses of 5-FU, LV and CDDP following CRT with 5-FU and paclitaxel. Of the 49 cases, 43 were evaluable; 77% were treated with R0 excision and 26% achieved a pCR. The 1-year survival rate was 82% for pCR cases and 69% for non-pCR cases. Similarly, in a recent Dutch phase I/II study, patients with locally advanced gastric cancer had an R0 resection rate of 72% and a pCR rate of 16% following neoadjuvant therapy with carboplatin and paclitaxel and concurrent radiotherapy [12]. These results indicate a pathological treatment response and R0 excision as surrogate markers of survival duration. In Japan, Inoue et al. [13] reported a study of preoperative CRT involving 50 Gy with S-1 single agent for other organ infiltrations or local progression of gastric cancer of the bulky N2. R0 resection was performed in 11 of 12 cases and histopathological effects of more than grade Ib were observed in 10 cases. Complications occurred in 2 cases: one pancreatic fistula and one anastomotic leakage. The safety of D2 LN dissection after CRT was demonstrated. Therefore, CRT provides a high local curative effect in some advanced gastric cancer patients.

In the present patient, S-1 and biweekly cisplatin were administered together with radiation. This combined treatment resulted in clinical complete responses in both the primary lesion and the LNs. Side effects of the therapy included the development of grade 3 nonhematological adverse events. Although the prognosis of patients who achieve a postoperative pathological complete response has been reported, there have been no reports of cases who have maintained a long-term clinical complete response after CRT. In recent years, patients with advanced gastric carcinomas, with a clinical complete response determined by radiological examination in response to several regimens, have been reported. However, these cases showed progression less than 1 year after treatment. This said, whether the prognosis of these clinical complete response patients is excellent remains unclear; in contrast, our patient has maintained a clinical complete response for >42 months. Although there were no apparent predictors for the patients who could get good response to CRT, some study showed that CRT

seems beneficial in patients with node-positive disease or higher LN ratio and intestinal-type gastric carcinoma [14, 15]. This case presentation showed that N3 LNs were detected and the histological type was a well differentiated tubular adenocarcinoma according to the WHO classification which was classified as intestinal-type according to the Lauren classification. These factors could have some relation with the complete response in this patient.

In conclusion, we think that CRT could be considered as an option for treatment of patients with locally advanced gastric carcinoma diagnosed as unresectable, or for those who refuse surgical treatment.

Statement of Ethics

This study was approved by the Keio University School of Medicine Ethics Committee (No. 20150044).

Disclosure Statement

All authors declare no conflicts of interest.

Author Contributions

Masahiro Yura and Tsunehiro Takahashi wrote this paper; all other members equally contributed to medical treatment.

References

- 1 Japanese Gastric Cancer Society. Guidelines for Diagnosis and Treatment of Carcinoma of the Stomach. Tokyo: Kanehara & Co. Ltd.; 2004.
- 2 Koizumi W, Narahara H, Hara T, Takagane A, Akiya T, Takagi M, et al. S-1 plus cisplatin versus S-1 alone for first-line treatment of advanced gastric cancer (SPIRITS trial): a phase III trial. *Lancet Oncol*. 2008 Mar;9(3):215–21.
- 3 Macdonald JS, Smalley SR, Benedetti J, Hundahl SA, Estes NC, Stemmermann GN, et al. Chemoradiotherapy after surgery compared with surgery alone for adenocarcinoma of the stomach or gastroesophageal junction. *N Engl J Med*. 2001 Sep;345(10):725–30.
- 4 Lee J, Lim DH, Kim S, Park SH, Park JO, Park YS, et al. Phase III trial comparing capecitabine plus cisplatin versus capecitabine plus cisplatin with concurrent capecitabine radiotherapy in completely resected gastric cancer with D2 lymph node dissection: the ARTIST trial. *J Clin Oncol*. 2012 Jan;30(3):268–73.
- 5 Yoshikawa T, Sasako M, Yamamoto S, Sano T, Imamura H, Fujitani K, et al. Phase II study of neoadjuvant chemotherapy and extended surgery for locally advanced gastric cancer. *Br J Surg*. 2009 Sep;96(9):1015–22.
- 6 Ajani JA, Mansfield PF, Janjan N, Morris J, Pisters PW, Lynch PM, et al. Multi-institutional trial of preoperative chemoradiotherapy in patients with potentially resectable gastric carcinoma. *J Clin Oncol*. 2004 Jul;22(14):2774–80.
- 7 Ajani JA, Winter K, Okawara GS, Donohue JH, Pisters PW, Crane CH, et al. Phase II trial of preoperative chemoradiation in patients with localized gastric adenocarcinoma (RTOG 9904): quality of combined modality therapy and pathologic response. *J Clin Oncol*. 2006 Aug;24(24):3953–8.
- 8 Stahl M, Walz MK, Riera-Knorrenschild J, Stuschke M, Sandermann A, Bitzer M, Wilke H, Budach W: Preoperative chemotherapy versus chemoradiotherapy in locally advanced adenocarcinomas of oesophagogastric junction (POET): Long-term results of a controlled randomized trial. *Eur J Cancer*. 2017;81:183–90.

- 9 Matsuda S, Takahashi T, Fukada J, Fukuda K, Kawakubo H, Saikawa Y, et al. Phase I study of neoadjuvant chemoradiotherapy with S-1 plus biweekly cisplatin for advanced gastric cancer patients with lymph node metastasis: -KOGC04-. *Radiat Oncol*. 2014 Jan;9(1):9.
- 10 Japanese Gastric Cancer Association. Japanese classification of gastric carcinoma: 3rd English edition. *Gastric Cancer*. 2011 Jun; 14(2):101–12.
- 11 Childs DS Jr, Moertel CG, Holbrook MA, Reitemeier RJ, Colby M Jr. Treatment of unresectable adenocarcinomas of the stomach with a combination of 5-fluorouracil and radiation. *Am J Roentgenol Radium Ther Nucl Med*. 1968;102(3):541–4.
- 12 Trip AK, Poppema BJ, van Berge Henegouwen MI, Siemerink E, Beukema JC, Verheij M, et al. Preoperative chemoradiotherapy in locally advanced gastric cancer, a phase I/II feasibility and efficacy study. *Radiother Oncol*. 2014 Aug;112(2):284–8.
- 13 Inoue T, Yachida S, Usuki H, Kimura T, Hagiike M, Okano K, et al. Pilot feasibility study of neoadjuvant chemoradiotherapy with S-1 in patients with locally advanced gastric cancer featuring adjacent tissue invasion or JGCA bulky N2 lymph node metastases. *Ann Surg Oncol*. 2012 Sep;19(9):2937–45.
- 14 Park SH, Sohn TS, Lee J, Lim DH, Hong ME, Kim KM, et al. Phase III Trial to Compare Adjuvant Chemotherapy With Capecitabine and Cisplatin Versus Concurrent Chemoradiotherapy in Gastric Cancer: Final Report of the Adjuvant Chemoradiotherapy in Stomach Tumors Trial, Including Survival and Subset Analyses. *J Clin Oncol*. 2015 Oct;33(28):3130–6.
- 15 Smalley SR, Benedetti JK, Haller DG, Hundahl SA, Estes NC, Ajani JA, et al. Updated analysis of SWOG-directed intergroup study 0116: a phase III trial of adjuvant radiochemotherapy versus observation after curative gastric cancer resection. *J Clin Oncol*. 2012 Jul;30(19):2327–33.

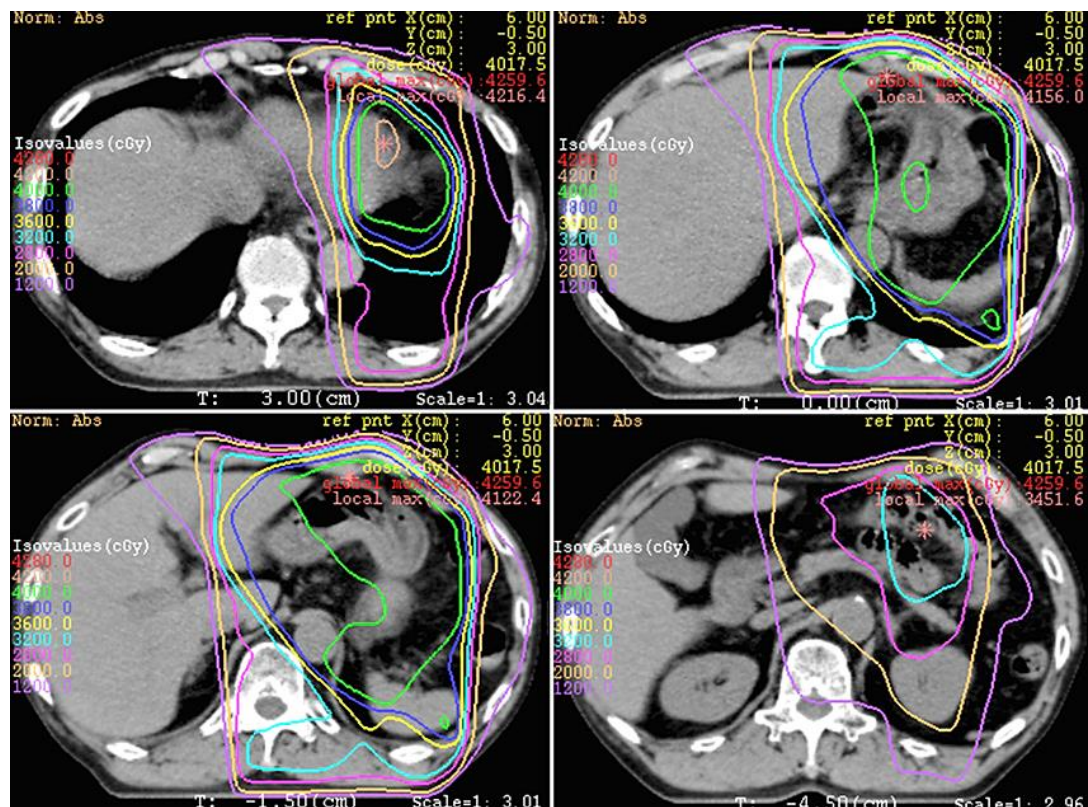


Fig. 1. Chemoradiation planning. The clinical target volume (CTV) included the primary tumor with a 3-cm margin and metastatic lymph nodes with a 1-cm margin. The planning target volume contained the CTV with a 2-cm margin to account for setup and organ motion.

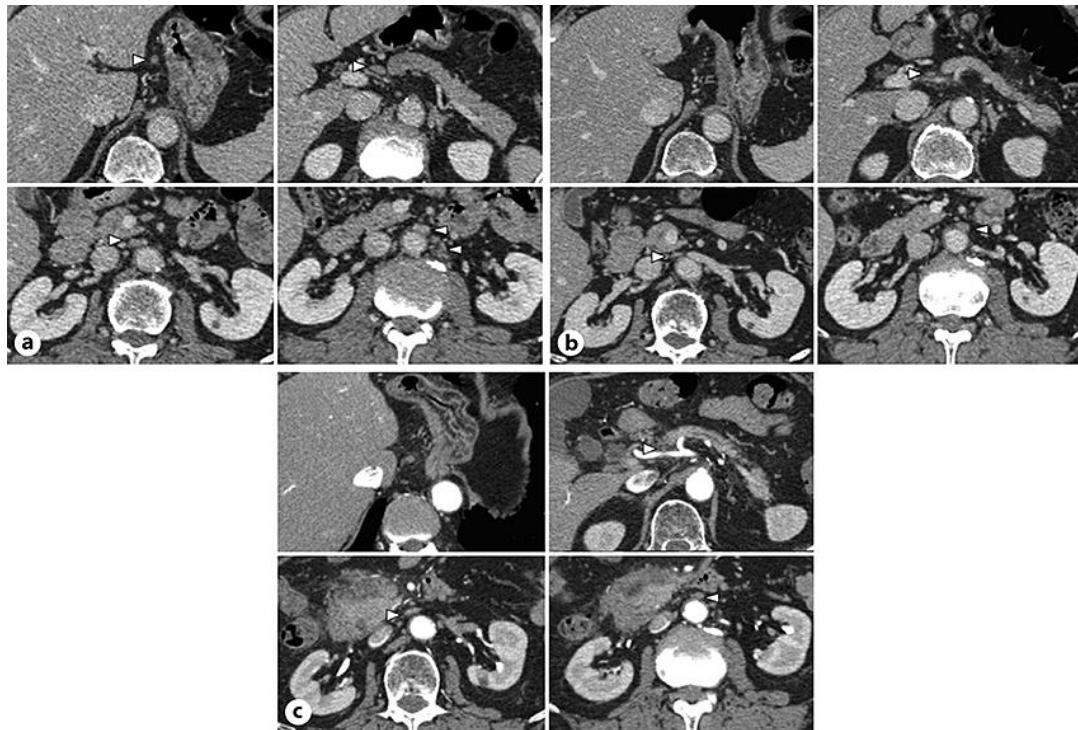


Fig. 2. CT scan findings. **a** CT scan before treatment showed that lymph node (LN) swelling was detected in the lesser curvature LN, anterosuperior LN along the common hepatic artery, and para-aortic LN (white arrow). **b** After CRT, abdominal CT demonstrated marked reduction in LN size (white arrow), and LN of lesser curvature was not detected. **c** LNs have maintained the small size and showed no recurrences (37 months after first CT).

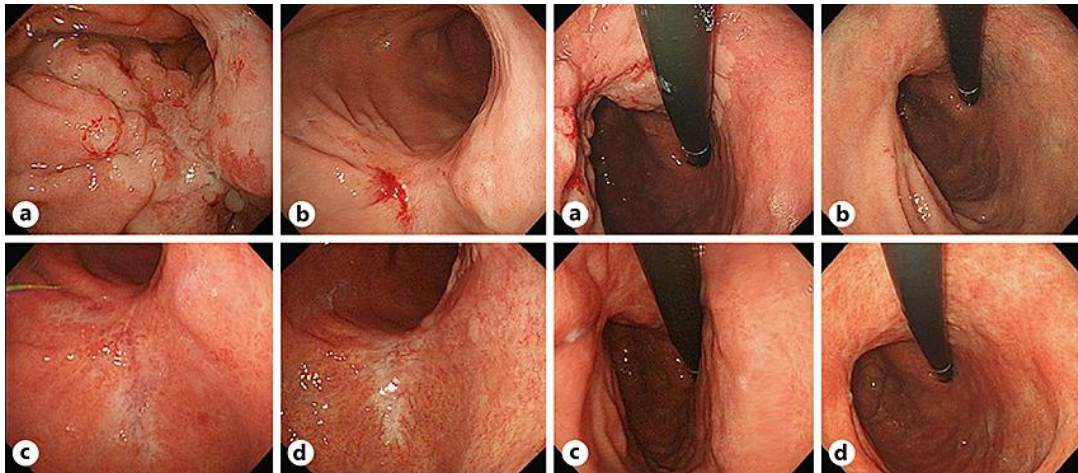


Fig. 3. Endoscopic findings (left: down angle, right: up angle). **a** Esophagogastroduodenoscopy (EGD) before chemotherapy showed an invasive type 3 tumor in the posterior wall of the upper gastric body. **b** EGD after chemoradiotherapy showed that scar formation on the tumor lesion had been maintained, and no cancer cells were detected by endoscopic biopsy. **c, d** EGD showed that scar formation had been maintained with no recurrence.

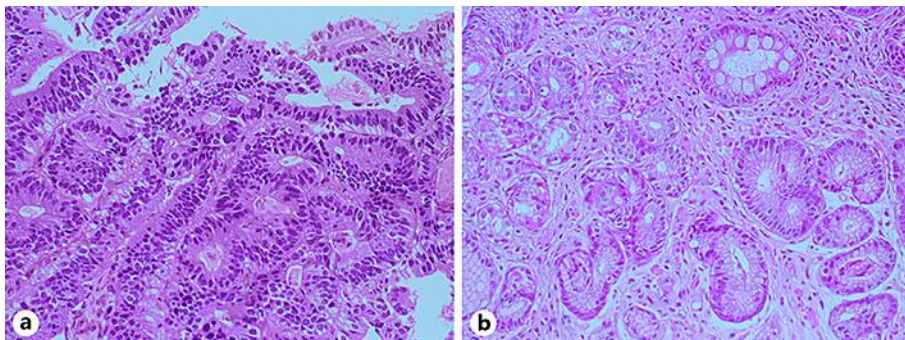


Fig. 4. Pathological findings. **a** A biopsy specimen indicated that this was a well to moderately differentiated tubular adenocarcinoma at the time of initial diagnosis. HE. $\times 200$. **b** A biopsy specimen from the lesion after chemoradiotherapy indicated that no cancer cells were detected. HE. $\times 200$.