



Songklanakarin J. Sci. Technol.
40 (1), 155-161, Jan. - Feb. 2018



<http://www.sjst.psu.ac.th>

Original Article

Periostin staining within renal tissues from IgA nephropathy patients

Peepattra Wantanasiri¹, Bancha Satirapoj², Mongkon Charoenpitakchai³,
and Pornanong Aramwit^{1*}

¹ *Bioactive Resources for Innovative Clinical Applications Research Unit, Department of Pharmacy Practice, Faculty of Pharmaceutical Sciences, Chulalongkorn University, Pathum Wan, Bangkok, 10330 Thailand*

² *Division of Nephrology, Department of Medicine, Phramongkutklo Hospital, College of Medicine, Ratchathewi, Bangkok, 10400 Thailand*

³ *Department of Pathology, Phramongkutklo Hospital, College of Medicine, Ratchathewi, Bangkok, 10400 Thailand*

Received: 31 August 2016; Revised: 31 October 2016; Revised: 8 November 2016

Abstract

Periostin is a novel biomarker related to kidney disease progression. The aim of this study was to examine the level of periostin staining within renal tissue from IgA nephropathy patients. Immunohistochemistry for periostin was performed. The score of periostin staining and the correlation of periostin staining score with each pathological feature were evaluated. Positive periostin staining was found in renal tissue from IgA nephropathy patients including glomerular, interstitial, vascular and tubular areas. Tubular epithelial cell staining, tubular cell cast staining and periglomerular staining were common histologic features positive for periostin. Periglomerular staining were correlated with interstitial fibrosis as well as with tubular epithelial cell staining. In addition, tubular cell cast staining were correlated with tubular epithelial cell staining as well as with tubular atrophy staining. We concluded that periostin may be a promising biomarker in IgA nephropathy patients.

Keywords: Periostin staining, IgA nephropathy, periglomerular staining, tubular cell cast staining, tubular epithelial cell staining

1. Introduction

IgA nephropathy is the most common primary glomerulonephritis around the world. It is an autoimmune disease involved in immune complex deposition in kidney. A galactose-deficient IgA1, contained in an immune complex was believed to be an important part in the pathogenesis of disease (Novak *et al.*, 2008). The abnormal structure of IgA can be recognized by autoantibody from immune system leading to the formation of immune complexes in

both circulation and in situ formation in glomerular (Wyatt *et al.*, 2013). The activation of mesangial cells from immune complexes deposition leads to local inflammation, proliferation and extracellular matrix accumulation, and finally deterioration of kidney function (Zhang *et al.*, 2015). The clinical presentation from IgA nephropathy was different from isolated hematuria to rapidly progressive glomerulonephritis. Recurrent macroscopic hematuria and asymptomatic persistent microscopic hematuria are the most common finding in most IgA nephropathy patients (Satirapoj, 2009). In clinical practice, renal biopsy is a procedure for definite diagnosis of IgA nephropathy. Four pathological features from the Oxford classification that can predict outcome should be reported including mesangial

*Corresponding author
Email address: aramwit@gmail.com

hypercellularity, segmental glomerulosclerosis, endocapillary hypercellularity and tubular atrophy/interstitial fibrosis (Cattran *et al.*, 2009; Coppo *et al.*, 2014). However, these cannot be used for detection of kidney disease progression. Specific biomarker related is the development of kidney disease progression, especially in the fibrosis process, should be investigated.

Renal fibrosis is a common pathway to end-stage renal failure, irrespective of the cause of kidney disease. Epithelial to mesenchymal transition (EMT) was considered as an important process activated by transforming growth factor beta (TGF- β). The accumulation of extracellular matrix, produced from myofibroblasts, leads to the impairment of renal function (Boor *et al.*, 2010). Periostin, osteoblastic specific factor-2, was initially expressed in bone as an adhesion molecule for bone formation (Takeshita *et al.*, 1993). In renal tissue, periostin was not detected control kidney. In contrast, there was periostin expression at both mRNA and protein level from both animal and human with kidney injury (Sen *et al.*, 2011; Guerrot *et al.*, 2012; Satirapoj *et al.*, 2012). In animal study, co-expression of periostin and EMT marker was also observed. Disappearance of epithelial marker together with co-staining of mesenchymal marker was reported from injured kidney (Satirapoj *et al.*, 2012). Moreover, there was an increment of periostin mRNA expression induced by TGF- β , suggesting the relevance of periostin in the fibrosis process (Sen *et al.*, 2011). In human disease, there was a detection of periostin in both renal tissue and urine samples. Periostin in renal tissue and urine was also correlated with renal function (Sen *et al.*, 2011; Satirapoj *et al.*, 2014; Satirapoj *et al.*, 2015; Wantanasiri *et al.*, 2015). However, the study of periostin within renal tissue from IgA nephropathy is scant. The objective of this study was to evaluate the expression of periostin within renal tissue from IgA nephropathy patients to provide more data about the potential of periostin as a biomarker for renal disease progression in IgA nephropathy patients.

2. Materials and Methods

2.1 Human renal tissues

The study was approved by the institutional review boards and ethics review committees of the Royal Thai Army Medical Department, Phramongkutklao Hospital and College of Medicine, Bangkok, Thailand (No. 1168/2556). This study was also registered at ClinicalTrials.gov (Clinical Trial Registration number NCT02493101). This study was a cross-sectional study which conducted from April 2013 to February 2015 at Phramongkutklao Hospital, Bangkok, Thailand. Informed consent was obtained from all patients who participated in this study. The patients included in this study had to confirm diagnosed with IgA nephropathy, aged over or equal to 18 years and at least three glomeruli should have been obtained at biopsy. Patients with urinary tract obstruction, urinary tract infection, kidney transplant, cancer diseases, asthma, advanced heart disease, pregnancy and lactation were excluded from this study. All participants were interviewed for collecting demographic data and laboratory

testing was reviewed from patient's record. Renal tissues were collected at the time of biopsy. Normal renal tissue sections from renal cell carcinoma patients, which were confirmed by a renal pathologist, were used as control tissues. Series micrometer-thick sections of paraffin-embedded kidneys were stained with hematoxylin and eosin (H&E), Masson's trichrome solution and immunohistochemistry for periostin, which were thereafter scanned with a Panoramic MIDI Slide Scanner (3DHISTECH, Hungary) for the further evaluation of histology.

2.2 Immunohistochemistry for periostin

Immunohistochemistry for periostin was performed using the Bench Mark XT automated slide preparation system (Ventana, USA). Three-micrometer-thick sections of paraffin-embedded kidneys were de-paraffinized and rehydrated. The antigens were retrieved by Protease 2 (Ventana, USA). The primary rabbit polyclonal antibody to periostin (Abcam, Cambridge, UK) was added at a dilution of 1:1000. Horseradish peroxidase was used as a secondary antibody. Reactivity was detected using diaminobenzidine (DAB) reagent. The tissues were then counterstained with modified Mayer's hematoxylin. Positive staining was detected as a brown coloration area within the tissue. For internal controls, the uterus and ovary were used as positive and negative controls, respectively.

2.3 Renal histology evaluation

Periostin staining score. The periostin staining was evaluated from the brown area of coloration within the glomerular, interstitial, tubular and vascular tissue. The pathological features were evaluated including periglomerular staining, mesangial staining, fibrocellular crescent, fibrous crescent, segmental sclerosis, global sclerosis, interstitial fibrosis, vascular fibrosis, tubular epithelial cell staining, tubular atrophy and tubular cell cast. As described from previous study (Wantanasiri *et al.*, 2015), periostin positive scores were graded from 0 to 5 as the percent positive area as 0 (absent), 1 (1% positive area), 2 (2% to 10% positive area), 3 (11% to 33% positive area), 4 (34% to 66% positive area), or 5 (67% to 100% positive area). For each feature, intensity was graded from 0 to 3+ and then multiplied by periostin positive scores as total score for each pathological feature. Total periostin staining scores were computed from the summation of all individual pathological feature scores. The higher score represented higher periostin staining.

2.4 Statistical analysis

Statistical analysis was performed using SPSS, version 18.0. Experimental data are given as mean \pm SD or median with interquartile ranges depending on normality test. Spearman correlation coefficients were used to test correlations between periostin staining score in each pathological feature and between periostin staining score and variables related to renal disease progression. *P*-values < 0.05 were considered statistically significant.

3. Results

3.1 Characteristic data

Total of 4 controls and 13 IgA nephropathy patients were included in this study. Overall clinical characteristics data are shown in Table 1. The average age of patients was 38 years. Hypertension was the most common comorbid diseases found in both controls and patients group. From Oxford classification, endocapillary hypercellularity and segmental sclerosis were the most common features reported in 85% and 62% of patients. Renal function impairment was also observed in patients from the increment of serum creatinine and urine protein to creatinine ratio together with reduction of eGFR.

Table 1. Clinical characteristics data

Characteristics	Mean \pm SD	
	Controls (n=4)	IgAN Patients (n=13)
Female/Male	2/2	7/6
Age (years)	66 \pm 9	38 \pm 14
Body weight (kg)	58.35 \pm 9.24	63.23 \pm 11.93
Height (cm)	163.50 \pm 9.54	162.31 \pm 8.72
Body mass index (kg/m ²)	21.89 \pm 3.61	23.89 \pm 3.25
Comorbid diseases (n,%)		
Hypertension	3 (75%)	7 (54%)
Diabetes mellitus	1 (25%)	0 (0%)
Dyslipidemia	2 (50%)	4 (31%)
Oxford classification (n,%)		
Mesangial hypercellularity		
M0	-	8 (62%)
M1	-	5 (38%)
Segmental sclerosis		
S0	-	5 (38%)
S1	-	8 (62%)
Endocapillary hypercellularity		
E0	-	2 (15%)
E1	-	11 (85%)
Tubular/interstitial fibrosis	-	11 (85%)
T0	-	8 (62%)
T1	-	2 (15%)
T2	-	3 (23%)
Systolic blood pressure (mmHg)	128.3 \pm 5.1	133.1 \pm 16.3
Diastolic blood pressure (mmHg)	74.8 \pm 4.8	79.4 \pm 16.6
Renal parameters		
Serum creatinine (mg/dl)*	1.0 (1.0, 1.0)	1.5 (0.8, 2.3)
Blood urea nitrogen (mg/dl)*	12.1 (9.2, 13.3)	16.9 (13.1, 24.4)
Serum albumin (g/dl)	4.3 \pm 0.6	3.7 \pm 0.7
Urine protein to creatinine ratio*	-	1.37 (1.16, 2.30)
eGFR (ml/min/1.73 m ²)	64.13 \pm 19.45	62.78 \pm 31.55

* Data was reported as median (Q1, Q3)

eGFR: estimated glomerular filtration rate.

3.2 Periostin staining in renal tissue

Periostin staining in renal tissue from both patients and controls was assessed by a renal pathologist. Immunostaining for periostin was shown in Figure 1. Periostin staining was not observed in control renal tissue. In contrast, positive periostin staining was detected in periglomerular fibrosis area and fibrous crescent. In addition, there was a periostin positive in the cytoplasm of both atrophic and non-

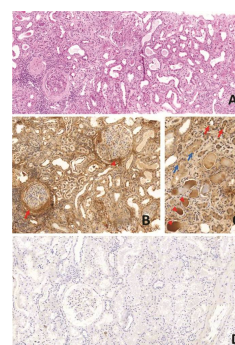


Figure 1. Kidney sample tissue from patient with IgA nephropathy and control renal tissue. Figure 1A (H&E, original magnification x100) shows extensive interstitial fibrosis with tubular atrophy, glomerulus with periglomerular fibrosis and glomerulus with fibrous crescent. Figure 1B (periostin immunostain, original magnification x100) shows positive periostin staining in areas of periglomerular fibrosis (arrow) and fibrous crescent (arrow head). Figure 1C (periostin immunostain, original magnification x200) shows positive periostin staining in areas of non-atrophic and atrophic tubular epithelial cytoplasm (blue and red arrows, respectively) as well as intratubular casts (arrow heads). Figure 1D shows no periostin staining observed from control renal tissue (periostin immunostain, original magnification x100).

atrophic tubular epithelial cell and intratubular casts. Tubular epithelial cell staining and tubular cell cast staining were reported in 77% and 69% of patients with median of total periostin score 5 (2, 6) and 5 (0, 6), respectively. There were 55% of patients with pathological casts showing positive periostin staining in all pathological casts. In addition, there were 27% of patients with pathological casts with positive periostin staining in some part of the pathological casts, as shown in Figure 2. No periostin staining was found in 18% of patients with pathological casts. Periglomerular staining was also a common feature found in 62% of patients with median of total periostin score 6 (0, 9). In addition, positive periostin staining was found in fibrosis area including glomeruli, interstitium and vessels with median of total periostin score 2 (0, 3), 2 (0, 4) and 4 (0, 5), respectively. Tubular atrophy was also positive for periostin in 46% of patients. The median of total periostin staining score was 22 (13, 33). Periostin staining score in each pathological feature was shown in Table 2.

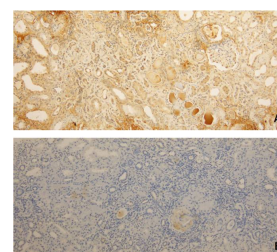


Figure 2. Kidney tissue sample from IgA nephropathy patients with positive periostin staining in all pathological casts (A) and in some part of pathological casts (B) (original magnification x100).

Table 2. Periostin staining score in each pathological feature

Periostin staining	IgAN Patients (n=13)				
	N ^a (%)	% ^b Median (Q1, Q3)	Score Median (Q1, Q3)	Intensity Median (Q1, Q3)	Total Score Median (Q1, Q3)
Periglomerular staining	8 (62)	18 (0, 50)	3 (0,4)	2 (0,3)	6 (0, 9)
Mesangial staining	2 (15)	0 (0, 0)	0 (0, 0)	0 (0, 0)	0 (0, 0)
Fibrocellular crescent staining	3 (23)	0 (0, 0)	0 (0, 0)	0 (0, 0)	0 (0, 0)
Fibrous crescent staining	3 (23)	0 (0, 0)	0 (0, 0)	0 (0, 0)	0 (0, 0)
Segmental sclerosis staining	5 (39)	0 (0, 8)	0 (0, 2)	0 (0, 1)	0 (0, 3)
Global sclerosis staining	7 (54)	6 (0, 9)	2 (0,2)	1 (0,1)	2 (0, 3)
Interstitial fibrosis staining	8 (62)	3 (0, 9)	2 (0,2)	1 (0,2)	2 (0, 4)
Vascular fibrosis staining	7 (54)	20 (0, 80)	3 (0,5)	1 (0,1)	4 (0, 5)
Tubular epithelial cell staining	10 (77)	90 (5, 100)	5 (2,5)	1 (1,1)	5 (2,6)
Tubular atrophy staining	6 (46)	5 (0, 10)	2 (0,2)	0 (0,1)	0 (0, 2)
Tubular cell cast staining	9 (69)	90 (0, 100)	5 (0,5)	1 (0,1)	5 (0, 6)
Total periostin staining score					22 (13, 33)

^aNumber of patients with abnormal pathological features positive for periostin.

^bPercentage of each abnormal pathological features positive for periostin

3.3 Correlation of periostin staining in each pathological feature

The correlation of periostin staining in each pathological feature from IgA nephropathy patients was also examined. Periglomerular staining were correlated with interstitial fibrosis ($r = 0.612$, p -value = 0.026). Tubular epithelial cell staining was correlated with periglomerular staining ($r = 0.617$, p -value = 0.025). Fibrocellular crescent staining was correlated with fibrous crescent staining ($r = 0.650$, p -value = 0.016) as well as with tubular cell cast staining ($r = 0.605$, p -value = 0.029). In addition, tubular cell cast staining were correlated with tubular epithelial cell staining ($r = 0.567$, p -value = 0.043) as well as tubular atrophy staining and ($r = 0.717$, p -value = 0.006). Overall results are shown in Table 3.

3.4 Correlation of periostin staining and variables related to renal disease progression

The correlation of periostin staining and variables related to renal disease progression was evaluated. The correlation periostin staining with eGFR ($r = -0.006$, p -value = 0.986), urine protein to creatinine ratio ($r = 0.292$, p -value = 0.334) and systolic blood pressure ($r = -0.047$, p -value = 0.879) were not statistically significant.

4. Discussion

IgA nephropathy is one of the common causes of primary glomerulonephritis. In clinical practice, renal biopsy is the common procedure to definite diagnosis of kidney disease. However, only some histologic features are normally evaluated by the pathologist, no specific biomarker involved

in the development of kidney disease progression was investigated. In this study, we determined the expression of periostin within renal tissues from patients with IgA nephropathy. Normal renal tissue section from renal cell carcinoma patients were used as controls. No periostin was detected in control renal tissues including glomerular, interstitial, tubular and vascular. The same results were reported in both animal and human studies (Guerrot *et al.*, 2012; Satirapoj *et al.*, 2012; Mael-Ainin *et al.*, 2014; Satirapoj *et al.*, 2014). In contrast, positive periostin staining was found in many kinds of kidney injury (Sen *et al.*, 2011; Guerrot *et al.*, 2012; Satirapoj *et al.*, 2012; Satirapoj *et al.*, 2014). From the previous study, periostin can be detected in both glomerular and interstitial area of IgA nephropathy patients. However, no periostin was evaluated in the tubular area. (Sen *et al.*, 2011). In our study, the most common area for positive periostin staining was found in the tubular epithelial cell, tubular cell cast and periglomerular with median of total periostin score 5 (2, 6), 5 (0, 6) and 6 (0, 9). Moreover, more than half of the patients reported that there was a positive periostin staining in fibrosis area including glomeruli, interstitium and vessels with median of total periostin score 2 (0, 3), 2 (0, 4) and 4 (0, 5), respectively.

Renal fibrosis is a common pathway leading to end-stage renal disease, regardless of etiology. The initiation of kidney injury can be presented in glomerular, interstitial, tubular and also vascular areas. However, the final pathological characteristics within renal tissue are the same including tubulointerstitial inflammation, glomerular sclerosis, interstitial fibrosis and tubular atrophy (Satirapoj *et al.*, 2012). Epithelial-mesenchymal transition is considered as major process to renal fibrosis mainly induced by transforming growth factor beta (TGF- β) (Fan *et al.*, 1999).

Table 3. Spearman rank correlation coefficient between total score of periostin staining in each pathological feature

	Total score of periostin staining in each pathological feature											
	Periglomerular staining		Mesangial staining		Fibrocellular crescent staining		Fibrous crescent staining		Segmental sclerosis staining		Global sclerosis staining	
	r	p-value	r	p-value	r	p-value	r	p-value	r	p-value	r	p-value
Periglomerular staining	1.000	-	0.088	0.775	0.518	0.070	0.237	0.435	0.123	0.689	0.041	0.895
Mesangial staining	0.088	0.775	1.000	-	-0.232	0.446	0.193	0.528	0.553	0.050	-0.091	0.767
Fibrocellular crescent staining	0.518	0.070	-0.232	0.446	1.000	-	0.650	0.016*	0.357	0.231	-0.113	0.713
Fibrous crescent staining	0.237	0.435	0.193	0.528	0.650	0.016*	1.000	-	0.405	0.169	-0.093	0.763
Segmental sclerosis staining	0.123	0.689	0.553	0.050	0.375	0.231	0.405	0.169	1.000	-	-0.319	0.288
Global sclerosis staining	0.041	0.895	-0.091	0.767	-0.113	0.713	-0.093	0.763	-0.319	0.288	1.000	-
Interstitial fibrosis staining	0.612	0.026*	-0.089	0.773	0.499	0.083	0.052	0.866	0.365	0.220	-0.395	0.182
Vascular fibrosis staining	0.193	0.527	-0.423	0.150	0.545	0.054	0.274	0.366	-0.055	0.859	0.488	0.090
Tubular epithelial cell staining	0.617	0.025*	-0.115	0.708	0.485	0.093	0.366	0.219	0.089	0.773	-0.321	0.286
Tubular atrophy staining	0.394	0.183	0.094	0.761	0.208	0.495	0.073	0.812	-0.206	0.499	0.184	0.547
Tubular cell cast staining	0.373	0.210	-0.029	0.925	0.605	0.029*	0.526	0.065	0.095	0.759	0.241	0.429

*p-value < 0.05

Table 3. Continued

	Total score of periostin staining in each pathological feature									
	Interstitial fibrosis staining		Vascular fibrosis staining		Tubular epithelial cell staining		Tubular atrophy staining		Tubular cell cast staining	
	r	p-value	r	p-value	r	p-value	r	p-value	r	p-value
Periglomerular staining	0.612	0.026*	0.193	0.527	0.617	0.025*	0.394	0.183	0.373	0.210
Mesangial staining	-0.089	0.773	-0.423	0.150	-0.115	0.708	0.094	0.761	-0.029	0.925
Fibrocellular crescent staining	0.499	0.083	0.545	0.054	0.485	0.093	0.208	0.495	0.605	0.029*
Fibrous crescent staining	0.052	0.866	0.274	0.366	0.366	0.219	0.073	0.812	0.526	0.065
Segmental sclerosis staining	0.365	0.220	-0.055	0.859	0.089	0.773	-0.206	0.499	0.095	0.759
Global sclerosis staining	-0.395	0.182	0.488	0.090	-0.321	0.286	0.184	0.547	0.241	0.429
Interstitial fibrosis staining	1.000	-	0.147	0.633	0.335	0.263	-0.192	0.529	-0.041	0.895
Vascular fibrosis staining	0.147	0.633	1.000	-	0.015	0.962	-0.005	0.988	0.419	0.154
Tubular epithelial cell staining	0.335	0.263	0.015	0.962	1.000	-	0.417	0.157	0.567	0.043*
Tubular atrophy staining	-0.192	0.529	-0.005	0.988	0.417	0.157	1.000	-	0.717	0.006*
Tubular cell cast staining	-0.041	0.895	0.419	0.154	0.567	0.043*	0.717	0.006*	1.000	-

*p-value < 0.05

There was a conversion of tubular epithelial cell from epithelial phenotype to mesenchymal phenotype followed by migration and invasion of myofibroblasts through tubular basement membrane disruption. (Liu, 2004). The overproduction of extracellular matrix protein together with the imbalance of its degradation lead to renal fibrosis and finally reduced renal function. The results previous studies, suggest that periostin may be involved in this process. In the human study, periostin was the strongest mRNA expression of gene encoding matricellular protein found in glomeruli

(Sen *et al.*, 2011). Mesangial cells are believed to be a source of periostin production in glomerulus. In addition, dose-dependent of periostin mRNA expression was observed after mesangial cells were induced by TGF- β (Sen *et al.*, 2011). There was also a positive correlation of TGF- β mRNA expression and periostin mRNA expression in human glomeruli and tubulointerstitial area (Sen *et al.*, 2011). From our results, we found that periostin was observed in both glomeruli and tubulointerstitial area. There was also a correlation between periostin staining in periglomerular and

interstitial fibrosis area as well as tubular epithelial cells. We supposed that the production of periostin may be activated by TGF- β after kidney injury in both glomerular and tubulointerstitial area. From previous study, TGF- β mRNA expression from renal tissue of IgA nephropathy patients was higher level than in healthy controls. Glomerular TGF- β positivity was also observed in 46% of kidney samples (Meng *et al.*, 2014). Not only glomerular, but also tubular epithelial cells and interstitium area were positive for TGF- β (Stasikowska *et al.*, 2008). Moreover, the increment of TGF- β mRNA expression and TGF- β staining in renal tissues were related to severity of pathologic class (Meng *et al.*, 2014). In our study, positive periostin was also found in area with fibrosis including glomerular, interstitial and vascular areas. To support the role of periostin and fibrosis process, a genetic deletion of periostin was performed in an animal study. The results showed that genetic deletion of periostin in animals with kidney injury represented the lower fibrosis and fibrillar collagen together with less collagen III mRNA expression in renal tissue (Mael-Ainin *et al.*, 2014). An increment of collagen III mRNA expression was also found in animals with hypertensive nephropathy (Guerrot *et al.*, 2012).

In our study, the most common area for positive periostin staining was observed in the tubular epithelial cell and tubular cell cast. Periostin was not detected in tubular from normal control tissue, as reported from previous studies (Sen *et al.*, 2011; Wantanasiri *et al.*, 2015). The same results were also observed in both animal and human studies (Satirapoj *et al.*, 2012; Satirapoj *et al.*, 2014; Satirapoj *et al.*, 2015). Greater diffusion and intensity of periostin staining was found in both tubular epithelial cell and tubular cell cast which related to chronic kidney injury (Satirapoj *et al.*, 2012). Moreover, loss of epithelial marker in distal tubule together with co-staining with mesenchymal marker was also observed in both animal and human studies, suggesting the role of periostin and renal fibrosis process (Guerrot *et al.*, 2012; Satirapoj *et al.*, 2012). From our results, we found that tubular cell cast staining was also positive correlated with the tubular epithelial cell staining as well as with tubular atrophy staining. This suggested that periostin may be involved in the fibrosis process at the initial kidney injury from tubular epithelial cell staining and until loss of renal function from tubular atrophy staining. Periostin may excreted from the affected tubular epithelial cells and tubular atrophy. Additionally, we supposed that these findings may be a source of periostin secretion in urine. To support our hypothesis, urine periostin was detected from both animal and human with kidney injury. In animal study, an increment of urine periostin was observed relative to chronic of kidney injury. No urine periostin was detected before kidney injury (Satirapoj *et al.*, 2012). Urine periostin levels from human samples were also statistically significantly higher than in healthy controls. The best cutoff level with high sensitivity and specificity of urine periostin have been reported depending on different types of kidney disease (Satirapoj *et al.*, 2012; Satirapoj *et al.*, 2014; Satirapoj *et al.*, 2015). The limitation in our study was the number of sample sizes. Further study should focus on the large population to investigate the expression of periostin in both gene and protein level within renal tissue and also the level of urine periostin from IgA nephropathy patients. The correlation between urine periostin and periostin expression within renal tissue should be further evaluated to find out the possibility of

using periostin as a biomarker related to the kidney disease progression within renal tissue.

5. Conclusions

In conclusion, this study demonstrated that there was periostin staining in renal tissue from IgA nephropathy patients, most common in tubular epithelial cell, tubular cell cast and periglomerular. Correlation of periglomerular staining with interstitial fibrosis as well as with tubular epithelial cell staining was found. There was also a correlation of tubular cell cast staining with tubular epithelial cell staining as well as, with tubular atrophy staining, suggesting that periostin may be a promising biomarker involved in the progression of kidney disease. However, further study is needed to verify this.

Acknowledgements

The authors gratefully acknowledge all supports from the Faculty of Pharmaceutical Sciences, Chulalongkorn University, Bangkok, Thailand.

References

- Boor, P., Ostendorf, T., & Floege, J. (2010). Renal fibrosis: Novel insights into mechanisms and therapeutic targets. *Nature Reviews Nephrology*, 6(11), 643-656.
- Catran, D. C., Coppo, R., Cook, H. T., Feehally, J., Roberts, I. S., Troyanov, S., . . . Emancipator, S. (2009). The Oxford classification of IgA nephropathy: Rationale, clinicopathological correlations, and classification. *Kidney International*, 76(5), 534-545.
- Coppo, R., Troyanov, S., Bellur, S., Catran, D., Cook, H. T., Feehally, J., . . . Amore, A. (2014). Validation of the Oxford classification of IgA nephropathy in cohorts with different presentations and treatments. *Kidney International*, 86(4), 828-836.
- Fan, J. M., Ng, Y. Y., Hill, P. A., Nikolic-Paterson, D. J., Mu, W., Atkins, R.C., & Lan, H. Y. (1999). Transforming growth factor-beta regulates tubular epithelial-myofibroblast transdifferentiation in vitro. *Kidney International*, 56(4), 1455-1467.
- Guerrot, D., Dussaule, J. C., Mael-Ainin, M., Xu-Dubois, Y. C., Rondeau, E., Chatziantoniou, C., . . . Placier, S. (2012). Identification of periostin as a critical marker of progression/reversal of hypertensive nephropathy. *PloS One*, 7(3), e31974.
- Liu, Y. (2004). Epithelial to mesenchymal transition in renal fibrogenesis: pathologic significance, molecular mechanism, and therapeutic intervention. *Journal of the American Society of Nephrology*, 15(1), 1-12.
- Mael-Ainin, M., Abed, A., Conway, S. J., Dussaule, J. C., . . . Chatziantoniou, C. (2014). Inhibition of periostin expression protects against the development of renal inflammation and fibrosis. *Journal of the American Society of Nephrology*, 25(8), 1724-1736.
- Meng, H., Zhang, L., E, X., Ye, F., Li, H., Han, C., . . . Jin, X. (2014). Application of Oxford classification, and overexpression of transforming growth factor- β 1 and immunoglobulins in immunoglobulin a nephro-

- pathy in a Chinese patient cohort. *Translational Research*, 163(1), 8-18.
- Novak, J., Julian, B. A., Tomana, M., & Mestecky, J. (2008). IgA glycosylation and IgA immune complexes in the pathogenesis of IgA nephropathy. *Seminars in Nephrology*, 28(1), 78-87.
- Satirapoj, B. (2009). IgA nephropathy: A clinical perspective. *Royal Thai Army Medical Journal*, 62(2), 77-86.
- Satirapoj, B., Nast, C. C., & Adler, S. G. (2012). Novel insights into the relationship between glomerular pathology and progressive kidney disease. *Advances in Chronic Kidney Disease*, 19(2), 93-100.
- Satirapoj, B., Tassanasorn, S., Charoenpitakchai, M., & Supasyndh, O. (2015). Periostin as a tissue and urinary biomarker of renal injury in type 2 diabetes mellitus. *PloS One*, 10(4), e0124055.
- Satirapoj, B., Wang, Y., Chamberlin, M. P., Dai, T., LaPage, J., Phillips, L., . . . Adler, S. G. (2012). Periostin: Novel tissue and urinary biomarker of progressive renal injury induces a coordinated mesenchymal phenotype in tubular cells. *Nephrology Dialysis Transplantation*, 27(7), 2702-2711.
- Satirapoj, B., Witoon, R., Ruangchanasetr, P., Wantanasiri, P., Charoenpitakchai, M., & Choovichian, P. (2014). Urine periostin as a bio-marker of renal injury in chronic allograft nephropathy. *Transplantation Proceedings*, 46(1), 135-140.
- Sen, K., Lindenmeyer, M. T., Gaspert, A., Eichinger, F., Neusser, M. A., Kretzler, M., . . . Cohen, C. D. (2011). Periostin is induced in glomerular injury and expressed de novo in interstitial renal fibrosis. *American Journal of Pathology*, 179(4), 1756-1767.
- Stasikowska, O., Danilewicz, M., & Wagrowska-Danilewicz, M. (2008). Monocyte chemoattractant protein-1, but not RANTES plays a crucial role in the interstitial renal injury in IgA nephropathy. *Periodicum Biologorum*, 110(1), 85-90.
- Takeshita, S., Kikuno, R., Tezuka, K., & Amann, E. (1993). Osteoblast-specific factor 2: Cloning of a putative bone adhesion protein with homology with the insect protein fasciclin I. *Biochemical Journal*, 294(Pt 1), 271-278.
- Wantanasiri, P., Satirapoj, B., Charoenpitakchai, M., & Aramwit, P. (2015). Periostin: a novel tissue biomarker correlates with chronicity index and renal function in lupus nephritis patients. *Lupus*, 24(8), 835-845.
- Wyatt, R. J., & Julian, B. A. (2013). IgA Nephropathy. *New England Journal of Medicine*, 368(25), 2402-2414.
- Zhang, C., Zeng, X., Li, Z., Wang, Z., & Li, S. (2015). Immunoglobulin a nephropathy: Current progress and future directions. *Translational Research*, 166(2), 134-144.