

SHORT ABSTRACT

State of the Art of Image Guidance in Interventional Radiology

Vania Tacher and Hicham Kobeiter

Keywords: Image guidance; CBCT based-image guidance; Image fusion guidance; multimodality image; x-ray exposure

Abstract

Nowadays complex interventions are made possible because of improved materials including catheters, micro-catheters, introducers and imaging modalities. Image guidance is the center of each intervention in interventional radiology (IR). Image guidance helps to ‘see’ the lesion, to ‘reach’, to ‘treat’ and to ‘assess’, both the procedure success and the absence of complication. This image guidance is improving, along with various imaging techniques, and is used more and more for complex interventions. Three types of image guidance techniques are distinguished: 1) X-ray-related image guidance based on computed tomography (CT), fluoroscopy, 2D angiography, 3D angiography and cone-beam CT (CBCT); 2) non-X-ray image guidance based on ultrasound (US), magnetic resonance imaging (MRI) and electromagnetic guidance; and

3) multimodality image guidance based on image fusion using pre-procedural 3D imaging overlaid with intra-procedural imaging as CBCT or US.

X-ray-related image guidance is the most commonly used and is adapted for endovascular or percutaneous intervention with limited angulation (i.e., lung biopsy).

Non-X-ray-related imaging is usually adapted for percutaneous interventions such as biopsy, drainage and ablation in solid organs like kidney or liver; MRI intervention is used in limited number of centers for various percutaneous interventions (i.e., mammary, bone or kidney), and electromagnetic image guidance enables navigation on pre-procedural CT scan imaging for percutaneous interventions with larger angle accesses.

With multimodality image guidance, the combination from two 3D image sets improve pre-procedural images

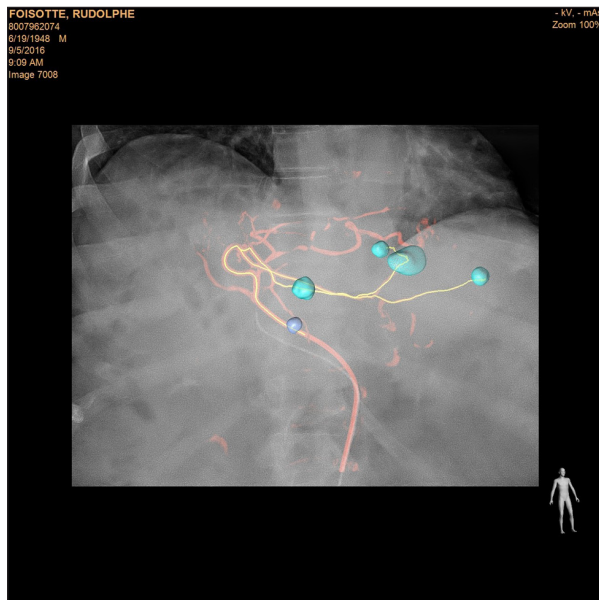


Figure 1: 3D Angiography after a double phase CBCT with tumor segmentation and automatic feeding vessel detection during a transcatheter arterial chemoembolization procedure.

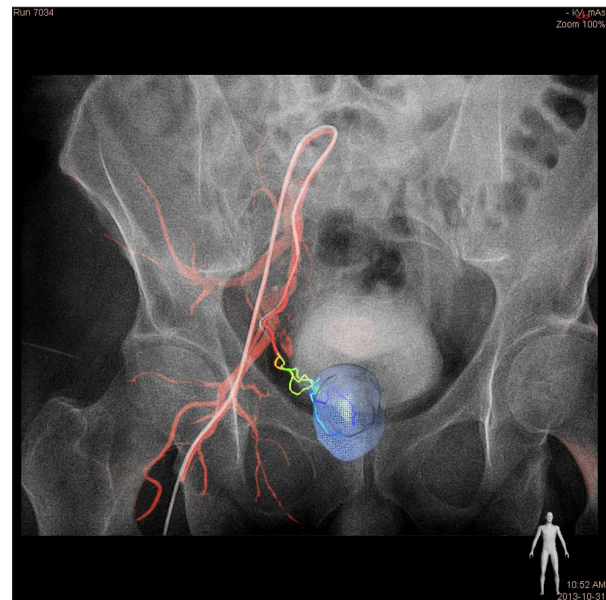


Figure 2: 3D Angiography after a double phase CBCT with prostate segmentation and automatic feeding vessel detection during a pelvic artery embolization.

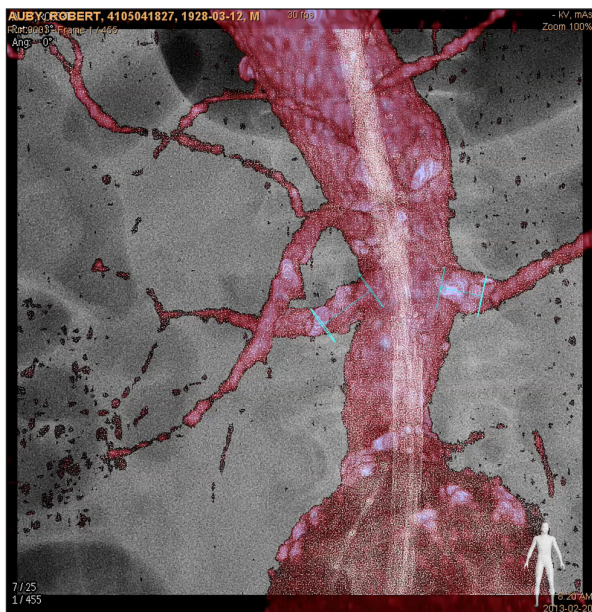

Figure 3: 3D overlay with a CTA during deployment of an aortic stentgraft without contrast injection.

and guidance possibilities. Image fusion with CBCT particularly helps endovascular procedures such as transarterial chemoembolization (**Figure 1**), prostate artery embolization (**Figure 2**), endovascular abdominal aortic repair (EVAR) and complex EVAR (**Figure 3**), and also percutaneous organs access with acute angles ($<45^\circ$). Multimodality image guidance based on US-guided intervention overlays pre-intervention CT or MRI imaging, particularly for liver or kidney interventions.

For any intervention, the choice of radiologist includes the image guidance type that will facilitate the procedure at each step and both reduce X-ray exposure and the need for iodinated contrast. The knowledge of all the image guidance possibilities is key in this choice. Moreover, image guidance is constantly improving by the development of more and more precise and informative diagnostic imaging and the development of various automatic and semi-automatic software (e.g., virtual perfusion in chemoembolization using CBCT).

Competing Interests

The authors have no competing interests to declare.

How to cite this article: Tacher, V and Kobeiter, H. State of the Art of Image Guidance in Interventional Radiology. *Journal of the Belgian Society of Radiology*. 2018; 102(S1): 7, 1–2. DOI: <https://doi.org/10.5334/jbsr.1641>

Submitted: 03 September 2018

Accepted: 26 September 2018

Published: 17 November 2018

Copyright: © 2018 The Author(s). This is an open-access article distributed under the terms of the Creative Commons Attribution 4.0 International License (CC-BY 4.0), which permits unrestricted use, distribution, and reproduction in any medium, provided the original author and source are credited. See <http://creativecommons.org/licenses/by/4.0/>.



Journal of the Belgian Society of Radiology is a peer-reviewed open access journal published by Ubiquity Press.

OPEN ACCESS