
GYNAECOLOGY

Three-Dimensional Power Doppler Evaluation of Adnexal Masses. Which Parameter Performs Best?

Ahmed Mohamed Abbas MSc,
Kamal M. Zahran MD,
Ahmed Nasr MD,
Hassan S. Kamel MD.

Woman's Health Center, Assiut University, Assiut, Egypt

ABSTRACT

Objective: To evaluate the role of 3D power Doppler in assessment of adnexal masses vascularity, its ability to discriminate benign from malignant adnexal masses. Then, to determine which one of the 3D power Doppler parameters has the highest reliability for detection of adnexal malignancy.

Materials and Methods: A cross sectional prospective study was conducted on patients scheduled for surgery due to presence of adnexal masses at Woman's Health Center, Assiut University, Egypt between October 2012 and October 2013. All patients were evaluated by 3-DPD ultrasound for assessment of tumor vascularization with calculation of vascular indices using Virtual organ computer-aided analysis program. A definitive histopathological diagnosis was obtained in every case to be used as a gold standard.

Results: One hundred sixty-one patients were recruited, 115 with benign masses, 46 with malignant masses. The mean vascularization index (16.36 versus 10.98; $p < 0.05$), and the mean vascularization-flow index (3.91 versus 2.13; $p < 0.01$) were significantly higher in malignant tumors. No significant difference was found in the mean flow index. Chaotic architecture of vessels was significantly associated with malignancy (80.4% versus 6.1%; $p < 0.001$) than benign possibility of masses. Also, complex branching pattern of vessels was more significantly present in malignant masses than benign ones (47.8% versus 4.3%; $p < 0.001$). 3D power Doppler had a sensitivity of 80%, specificity of 94%, PPV of 84% and NPV of 92% in detection of malignant adnexal masses.

Conclusion: Careful evaluation of the architecture of vessels was the best parameter in evaluation of the masses with 3D power Doppler. Evaluation of branching pattern had a low sensitivity and specificity in detection of malignancy. In spite of no clear cut-off values for vascular indices to be accurate in differentiation of adnexal masses, higher values of vascularization index and vascularization-flow index were strongly associated with adnexal malignancy.

Keywords: adnexal mass, 3D power Doppler, ovarian cancer.

Correspondence to: Ahmed M. Abbas, Business telephone number: +20882414616.
Cellular phone number: +2 01003385183. Postal code: 71111. E-mail: bmr90@hotmail.com

Introduction

The differential diagnosis of adnexal masses still represents a challenge in spite of the marvelous efforts that have been made to improve the sonographically based diagnosis. The last decade has seen rapid technological advances in diagnostic ultrasonography, with the recent development of three-dimensional gray-scale volume imaging and three-dimensional power Doppler imaging⁽¹⁾.

Ovarian cancer, a disease of no screening or prevention approaches up till now, which is still a silent killer of many patients due to its late presentation, does not need an extra delay in management caused by misleading preoperative data or suboptimal surgical intervention⁽²⁾.

Assessment of tumor vascularization by conventional color and pulsed Doppler have been introduced trying to improve the diagnostic accuracy of gray-scale morphological ultrasonography but the results show that it is of limited value despite neoangiogenesis being known to play an important role in the growth of tumors⁽³⁾.

The introduction of Three-dimensional power Doppler (3-DPD) has opened the possibility to characterize microvasculature of the adnexal masses and objectively assess tumor vascularization⁽⁴⁾.

Vessels architecture was classified into chaotic and non-chaotic patterns. A chaotic pattern predicts malignancy, and a non-chaotic pattern predicts a benign nature of the mass. Branching pattern of the vessels was classified into simple and complex, where simple pattern predicts benignity of the mass and complex pattern predicts malignancy⁽⁵⁾.

3-DPD allows also an objective measurement of vascularity of a given region of interest by estimating 3 vascular indices (vascularization index [VI], flow index [FI], and vascularization-flow index [VFI]) within such region⁽⁶⁾.

The purpose of this prospective study was to evaluate the role of 3-DPD in assessment of adnexal masses vascularity, its ability to discriminate benign from malignant adnexal masses. Then, to determine which one of the 3-DPD parameters has the highest

reliability for detection of adnexal malignancy.

Materials and Methods

This prospective study was conducted at Woman's Health Center, Assiut University, Egypt for 1 year between the first of October 2012 till the 30th of September 2013. One hundred sixty-one women, proved to have an adnexal mass by B-mode ultrasonography and referred for surgical management, were recruited for the study.

The study was approved by the Ethical Review Board of Assiut faculty of medicine and all women gave written informed consent. Diagnostic work-up included a complete medical history, physical examination and 3-DPD evaluation of tumor vessels.

All women were evaluated with a SonoAce X8 machine (Medison, Korea) and equipped with multifrequency transabdominal and transvaginal volumetric probes.

3-DPD was done for every patient, where, once the Region of interest was identified, power Doppler was set, the 3D volume box was superimposed, the ultrasound probe was kept steady, and the patient was asked to lie static on the bed. The volume box had the shape of a truncated cone, which was manipulated to minimize the acquisition time while ensuring that the whole adnexal mass was included in the volume sampling.

For each patient, the following 3-DPD parameters were recorded: Architecture of vessels, branching pattern, vascularization index, flow index, and vascularization-flow index. The architecture of vessels was interpreted as avascular, linear, encircling mass, or chaotic. The branching pattern of vessels is either simple or complex.

The scoring system⁽²⁾ used for prediction of malignancy depending on the vessels architecture was as follows:

0 (avascular) - 1 (linear or encircling mass) - 2 (chaotic pattern)

While the scoring for prediction of malignancy depending on the vessels branching pattern, was as follows

0 (simple) - 2 (complex)

3-DPD cut-off score greater or equal to 2 was associated with high risk of malignancy. All the stored volumes were analyzed using the VOCAL imaging program. The stored volume obtained using 3-DPD is defined by voxels. Once the contour was defined, the VOCAL program automatically calculated indices for gray-scale and color-scale voxels. According to these values three indices were calculated: VI, FI, and VFI. Evaluation of the stored volumes took between 5 and 10 minutes, using the VOCAL imaging program.

All surgically removed specimens were examined histopathologically to assess their nature as the final diagnosis was based on histopathological reports.

Analysis of data was done using SPSS Inc., Chicago, IL, USA, version 21. Qualitative variables were expressed as percentages and compared by Fisher's exact test. Quantitative variables were presented in terms of mean, standard deviation and range, compared by "Mann-Whitney test" for non-parametric data and "Student's T-test" for parametric data.

Sensitivity, specificity, positive and negative predictive values were calculated for 3-DPD evaluation. A ($p < 0.05$) was considered as statistically significant.

Results

The mean (\pm SD) age of patients included in the study was 35.2 ± 13.9 years (range 12-70 years). One-hundred thirty-six patients (84.5%) were in the reproductive age, 21 were postmenopausal (13%), and 4 of them (2.5%) were in the premenarche period. Fifty five patients (34.2%) were nulliparous.

Overall, 115 patients (71.4%) confirmed to have benign masses, and 46 patients (28.6%) with malignant masses according to the final histopathological reports. Malignant masses were commonly shown chaotic architecture and complex branching of vessels while most of benign masses shown linear vessels with simple branching pattern. (Fig. 1) The mean values of VI and VFI were significantly higher in malignant masses while there was no difference in the mean value of FI (Table 1).

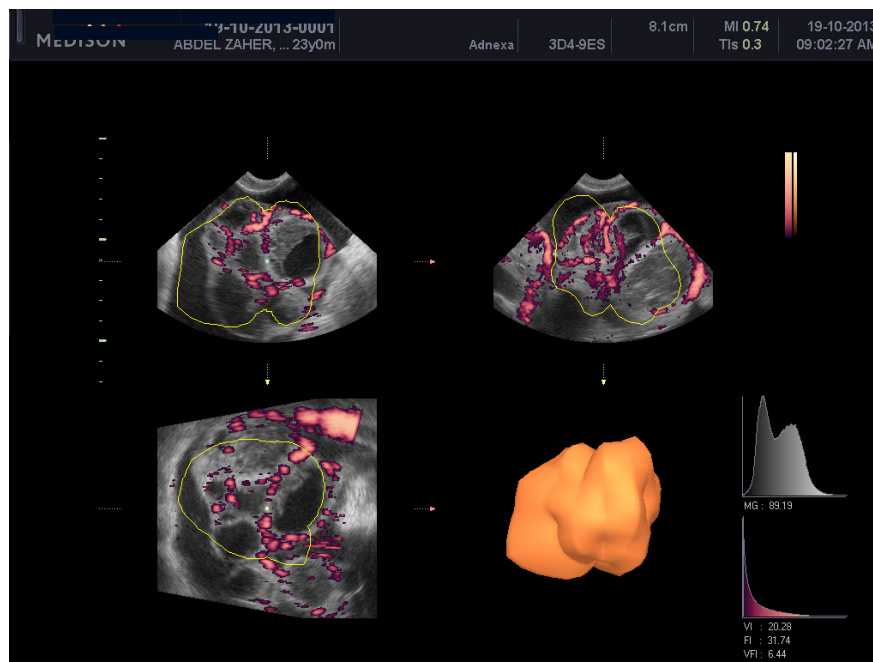


Fig. 1. 3-DPD application on multilocular ovarian cyst. It shows chaotic vascular architecture with complex branching pattern of blood vessels. High VI, FI, VFI suggestive of its malignant nature, proved to be mucinous cystadenocarcinoma by histopathology.

Table 1. 3-DPD criteria of the benign and malignant adnexal masses in the surgically managed group.

	Benign Masses (n = 115)	Malignant Masses (n = 46)	P
Vessels Architecture			
- Avascular	9 (7.8%)	1 (2.2%)	< 0.001
- Linear / encircling	99 (86.1%)	8 (17.4%)	
- Chaotic	7 (6.1%)	37 (80.4%)	
Branching Pattern			
- Simple	110 (95.7%)	24 (52.2%)	< 0.001
- Complex	5 (4.3%)	22 (47.8%)	
VI (Mean ± SD)	10.98 ± 9.17	16.36 ± 15.18	< 0.05
FI (Mean ± SD)	20.15 ± 9.81	20.16 ± 12.01	> 0.05
VFI (Mean ± SD)	2.13 ± 2.01	3.91 ± 3.83	< 0.01
Total Score			
- 0	9 (7.8%)	1 (2.2%)	< 0.001
- 1	99 (86.1%)	8 (17.4%)	
- 2	2 (1.7%)	15 (32.6%)	
- 4	5 (4.3%)	22 (47.8%)	

SD, standard deviation; VI, Vascularization index; FI, Flow index; VFI, Vascularization flow index

There were 115 benign masses in the study; According to the mentioned scoring system, 108 masses scored 0 or 1 (predicting benign nature), all of them confirmed histopathologically to be benign, while only 7 masses with score ≥ 2 revealed their benign nature (False positive results). On the other hand, there were 46 malignant masses; 37 scored ≥ 2 (predicting malignant nature) confirmed histopathologically to be malignant. The remaining 9 masses scored 0 or 1 were false negative results.

Our results showed that 3-DPD has a sensitivity of 80%, specificity of 94%, PPV of 84% and NPV of 92% in detection of malignant adnexal masses.

Discussion

Although ovarian cancer is the second most common female genital cancer, preceded only by cancer body of the uterus, more women die from ovarian cancers. It is the most lethal of all the gynecologic cancers, killing more women each year than both of cervical and endometrial cancers⁽¹⁾.

Good preoperative discrimination between

benign and malignant ovarian tumors results in more women being correctly referred for gynecologic oncology care and more women with benign masses undergoing conservative surgical treatment⁽⁷⁾.

The introduction of 3-DPD ultrasound has opened up the possibility of objectively assessing vascularization in a whole tumor. Three-dimensional display allows the sonographer to visualize many overlapping vessels easily and quickly, as well as to assess their relationship to other surrounding tissues. For that, 3-DPD was superior on routine color and power Doppler in assessment of adnexal mass vascularity⁽⁸⁾.

As regards to our results, 80.4% of malignant masses had chaotic pattern which was consistent with their nature, while 17.4% of masses had linear or encircling vascular pattern and one mass was avascular; histopathologically it was borderline malignant mucinous cystadenoma. Regarding the vascular branching pattern, surprisingly it was found that, 52.2% of malignant masses had simple pattern and complex pattern only in 47.8% of masses. Mansour, et al⁽²⁾ found that a chaotic pattern had a sensitivity of 88.2% in

predicting malignancy, and a nonchaotic pattern had a sensitivity of 89.9% in predicting a benign mass. Our results were nearly similar to these results.

The results of our study proved that avascular pattern is an excellent tool for excluding malignancy. Only one case with avascular pattern revealed malignancy, all other masses were benign. The same found with Mansour, et al⁽²⁾. The chaotic pattern was over predictive of malignancy but not missing malignant cases; the over prediction was caused by the cases of tubo-ovarian abscess and torsion of some masses, in which the blood clots had a heterogeneous consistency by ultrasound and the engorged vessels had a bizarre appearance by 3-DPD, and these enhance the role of the clinical evaluation before predicting malignancy in chaotic pattern cases.

In the present study, vascular indices (VI, FI and VFI) were calculated for all adnexal masses except avascular ones. The mean values for VI was 16.98 versus 10.98 for benign masses. Also, the mean value of VFI was 3.91 versus 2.13 for benign masses. The p-value was statistically significant with VI and VFI. While the mean value of FI was not differed between malignant and benign masses (20.16 versus 20.15) respectively.

On the contrary, Geomini, et al⁽⁹⁾ found that FI was significantly higher in malignant tumors while they did not find differences in VI and VFI. Jokubkiene, et al⁽¹⁰⁾ reported that all of the three vascular indices were significantly higher in malignant tumors. The same results were obtained by Alcazar and Rodriguez⁽⁶⁾.

Unfortunately, there is much confusing information in the literature regarding the cut-off values of vascular indices for the differentiation between benign and malignant adnexal masses, with no settled values till now. It appears from our study that these values tend to increase with malignancy, but with no definite cut-off values. This was coincided with the results of Testa, et al⁽¹¹⁾ who concluded that the 3DPD indices were significantly higher in malignant tumors. The only study that has not shown differences in 3DPD indices between benign and malignant ovarian tumors was reported by Ohel, et al⁽¹²⁾.

Regarding the target population under study, we think that this technique is not to be used in a general ovarian tumor population but in a selected one. Most ovarian tumors can be correctly classified by B-mode ultrasonography. However, there is a subset of ovarian lesions that are very difficult to classify⁽¹³⁾.

Careful evaluation of the architecture of vessels was the best parameter in evaluation of the masses with 3-DPD. Evaluation of branching pattern had a low sensitivity and specificity in detection of malignancy, while no clear cut-off values for vascular indices to be accurate in differentiation of adnexal masses. In conclusion, analysis of the vascular architecture, branching pattern, and calculation of vascular indices for adnexal masses by 3-DPD were a useful tools in excluding the possibility of malignancy with a high specificity, but still further studies are needed to define diagnostic cut-off values for prediction of malignancy in various adnexal masses.

Even though histopathological examination of the adnexal mass is the gold standard for diagnosis or exclusion of malignancy, new ultrasound modalities as 3DPD is reasonably accurate, helpful and non-invasive tool for assessing adnexal lesions, although it is more expensive, more time-consuming and has a longer learning curve than 2DUS scanning.

Conflict of Interest

The authors declare that they have no conflict of interest.

Acknowledgement

We would like to thank all members of "Ultrasound unit" in Woman's Health Center

References

1. Zoorob R, Anderson R, Cefalu C, Sidani M. Cancer screening guidelines. *Am Fam Phys* 2001;63:1039–43.
2. Mansour G M, El-Lamie I K, El-Sayed H M, Ibrahim A M, Laban M, Abou-Louz S K, et al. Adnexal mass vascularity assessed by 3-dimensional power Doppler: Does it add to the risk of malignancy index in prediction of ovarian malignancy?: Four hundred-case study.

- International 2009;19:867-72.
3. Sladkevicius P, Valentin L, Marsal, K. Transvaginal Doppler examination for the differential diagnosis of solid pelvic tumors. *J Ultrasound Med* 1995;14:377-80.
 4. Pairleitner H, Steiner H, Hasenoehrt G, Staudach A. Three-dimensional color histogram using three-dimensional power Doppler. In: Kurjak A, Ed., *Three-dimensional power Doppler in obstetrics and gynecology*. Carnforth Parthenon Publishing 1999;35-9.
 5. Kurjak A, Kupesic S, Sparae V, Kosuta D. Three-dimensional ultrasonographic and power characterization of ovarian lesions. *Ultrasound Obstet Gynecol* 2000;16:365-71.
 6. Alcázar J L, Rodríguez D. Three-dimensional power Doppler vascular sonographic sampling for predicting ovarian cancer in cystic-solid and solid vascularized masses. *J Ultrasound Med* 2009;28:275-81.
 7. Yazbek J., Raju S K, Ben-Nagi J, Holland T K, Hillaby K, Jurkovic D. Effect of quality of gynaecological ultrasonography on management of patients with suspected ovarian cancer: a randomised controlled trial. *Lancet Oncol* 2008;9:124-31.
 8. Kurjak A, Kupesic S. Three dimensional ultrasound and power Doppler in assessment of uterine and ovarian angiogenesis: a prospective study, *Croat Med J* 1999;40:413-20.
 9. Geomini P M, Kluivers K B, Moret E, Bremer G L, Kruitwagen R F, Mol B W. Evaluation of adnexal masses with three-dimensional ultrasonography. *Obstet Gynecol* 2006;108:1167-75.
 10. Jokubkiene L, Sladkevicius P, Valentin L. Does three dimensional power Doppler ultrasound help in discrimination between benign and malignant ovarian masses? *Ultrasound Obstet Gynecol* 2007;29:215-25.
 11. Testa A C, Ajossa S, Ferrandina G, Fruscella E, Ludovisi M, Malaggesi M, et al. Does quantitative analysis of three-dimensional power Doppler angiography have a role in the diagnosis of malignant pelvic solid tumors? A preliminary study, *Ultrasound Obstet Gynecol* 2005; 26:67-72.
 12. Ohel I, Sheiner E, Aricha-Tamir B, Piura B, Meirovitz M, Silberstein T, et al. Three dimensional power Doppler ultrasound in ovarian cancer and its correlation with histology, *Arch Gynecol Obstet* 2010;281:919-25.
 13. Valentin L, Ameye L, Jurkovic D, Metzger U, Lecuru F, Van Huffel S, et al. Which extrauterine pelvic masses are difficult to correctly classify as benign or malignant on the basis of ultrasound findings, and is there a way of making a correct diagnosis? *Ultrasound Obstet Gynecol* 2006;27:438-44.