



2018; 13(3): 287–292  
ISSN-1452-662X

DOI: 10.24125/sanamed.v13i3.245

UDK: 616.5-006.04

ID: 271673356

Original article

## RARE MALIGNANT SKIN TUMOURS OF THE HEAD AND NECK

Oroz Aleksandar,<sup>1</sup> Bokun Zorana,<sup>2</sup> Lazović Biljana,<sup>3</sup> Čukić Ognjen,<sup>1</sup> Valjarević Svetlana<sup>1</sup>

<sup>1</sup> Department of otorhinolaryngology and maxillofacial surgery,  
University clinical hospital center Zemun, Belgrade, Serbia

<sup>2</sup> Department of clinical pathology, University clinical hospital center Zemun, Belgrade, Serbia

<sup>3</sup> Clinic for internal medicine, University clinical hospital center Zemun, Belgrade, Serbia

Primljen/Received 27. 07. 2018. god.

Prihvaćen/Accepted 01. 09. 2018. god.

**Abstract: Introduction:** Malignant skin tumors in the majority of cases arise from the squamous epithelium, although they may occur in other accompanying skin structures, such as skin adnexa (hair follicle, sweat and sebaceous glands), as well as soft tissues participating in the building of skin structure, such as muscles, fibrous, fatty tissue and cartilage. Those tumors may also have a neuroendocrine origin or may arise from a premalignant lesion (solar keratosis and lentigo maligna). Regardless of their origin, they usually present as a nodule or longstanding, non-healing ulceration. Their early recognition enhances the treatment results and decreases the possibility of complications (invasion of deeper tissue structures and occurrence of regional and distant metastases).

**Material and methods:** Our retrospective study included 100 patients of both sexes surgically treated for skin malignancy in the Department for Otorhinolaryngology and Maxillofacial surgery of the Clinical Hospital Centre “Zemun”, Belgrade, Serbia.

**The goal** of this paper is to highlight the frequency of rare malignant tumors compared to the more frequent ones and consider the most appropriate clinical-diagnostic approach as well as the treatment modality for the patient.

**Conclusion:** Our study has shown that the most frequent tumor of the head and neck skin is basal cell carcinoma.

**Key words:** rare malignant skin tumor, skin tumor frequency, metastases, surgery, therapy.

### INTRODUCTION

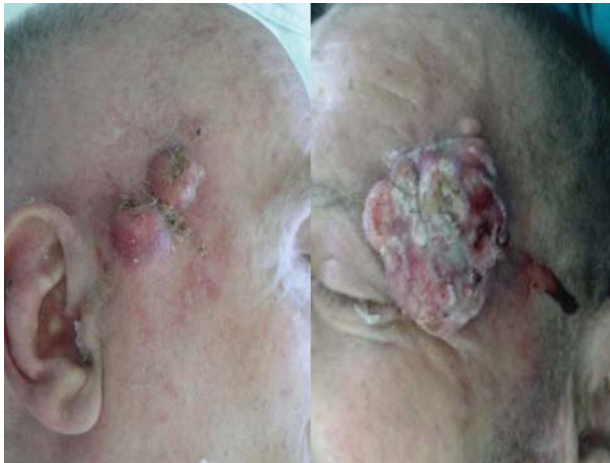Malignant skin tumors are the most frequent tumors in humans, with the constant tendency of increase in number. Their incidence is higher than other groups of tumors altogether, such as lung, breast, large bowel

and prostate malignancy (1). It is estimated that more than 80% of all skin tumors is the result of excessive skin exposure to ultraviolet (UV) effect of sunlight which contribute to oncogenesis, DNA impairment, usually with in individuals with fair tan as well as the people with professional sunlight exposure, such as farmers, construction workers, fishermen, etc., although some other factors may contribute significantly to occurrence of this tumor (ionization, chemical agents, immunodeficiency, genetic factors) (2).

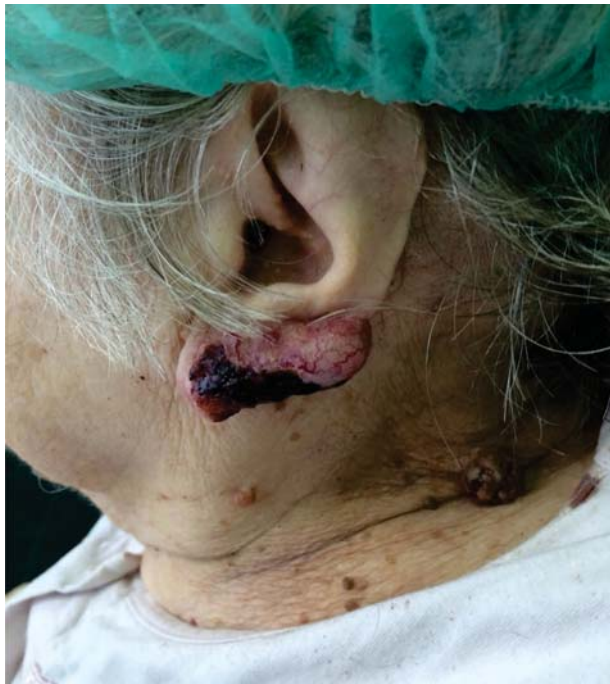It was noticed that in individuals with acquired immunodeficiency, those at immunosuppressive therapy as well as patients with lymphoma, the incidence of skin cancer, especially melanoma, is increased (3). Malignant tumor classification is nowadays a generally accepted principle and it is based on histogenesis, i.e. type of tissue that it is developed from (4, 5, 6).

The most frequent malignant tumors are basal cell carcinomas, squamous cell carcinoma (which are frequently called non-melanoma skin tumors), melanomas, somewhat less frequent neuroendocrine tumor Merkel cell carcinoma as well as apocrine tumors of sweat and sebaceous glands, which occur considerably less frequently (7).

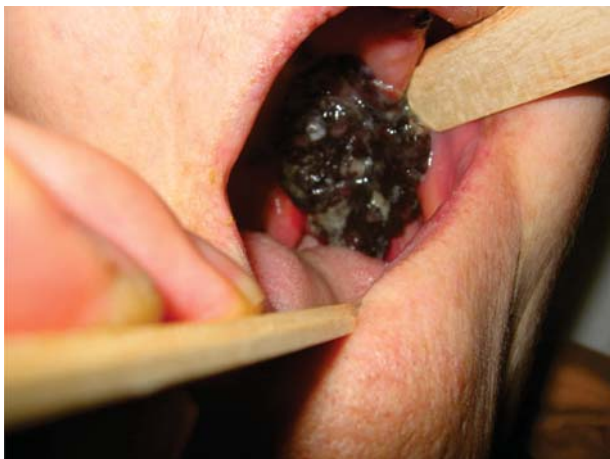However, basal cell carcinoma (BCC) is a malignant epithelial neoplasm that originates from the pluripotential cells in the epidermis and hair follicles and it represents 50–75% (according to some authors, even more than 80%) of all skin tumors (Figure 1) (8). It is the most common skin cancer seen in human population (9). It is often slow growing and may take years to enlarge significantly (10), but it can cause extensive local tissue destruction and death if inadequately treated or left untreated (Figure 1). The mortality rates associated with this cancer are low. However, it causes considerable functional and cosmetic deformity and



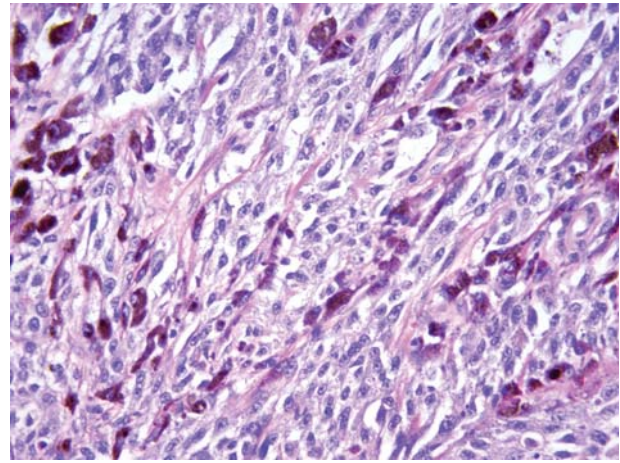
**Figure 1.** Nodular basocellular carcinoma localized on the right side of forehead and on the right supraorbital region



**Figure 2.** Squamous cell carcinoma of earlobe



**Figure 3.** Melanoma of oral cavity



**Figure 4.** Histopathological features of melanoma (H&E, x200)

cost of treatment is significant. In aggressive forms such as *Ulcus rodens* or *Ulcus terebrans*, there is severe mutilation and extensive destruction of adjacent soft tissues and underlying bone (11).

Squamous cell carcinoma (SCC) is an invasive epidermal tumor occurring on skin and on mucous membrane. It is composed of a modified spinous layer of epidermis which infiltrates the surrounding structures. In more than 90% cases, it develops at sun-exposed skin, at first like unobtrusive node or lightly infiltrated lesion, with rapid growth and signs of infiltration into the surrounding tissue. Regardless of its appearance SCC is prone to metastases, considering the fact that SCC at actinic keratosis metastasize more slowly and in a smaller percent than SCC at the scars (2, 12). More than 70% of these tumors occur in the auricle and in the lower third of the face (12).

Melanoma usually arises from melanocytes at the dermoepidermal junction. Beside the skin type and exposure to sunlight, preexisting dysplastic nevus, family history and immunologic dysfunction increase the risk of melanoma (13). Almost half of all melanoma arise from normal skin, and the remaining ones come from pre-existing nevus. Change of size or appearance of the existing nevus, itchiness, ulceration and bleeding require urgent examination and excision sample biopsy (Figure 2). Melanomas are typically present as irregular pigmented lesions with macular or papular appearance, usually pigmented, but can also be amelanotic (14, 15) (Figure 3, 4).

## MATERIAL AND METHODS

Our retrospective study included 100 patients of both sexes surgically treated for skin malignancy in the Department for Otorhinolaryngology and Maxillofacial surgery of the Clinical Hospital Centre "Zemun" from May 2015 to May 2017. Before hospitalization,

all patients had a presumptive diagnosis of skin malignancy based on clinical examination performed by an experienced maxillofacial surgeon, otolaryngologist or dermatologist. Criteria for participation in the study were: age of 18 or older and postoperatively histopathological verified malignant lesion of head, face, and jaw and neck skin. The patients who did not respond to follow up were excluded from the study.

All patients gave a written consent for surgery as the most optimal treatment modality. Based on clinical finding and local tumor extent, complete tumor removal using wide surgical excision was performed in all patients. The resulting defects were closed by means of direct suture, local flaps or free skin grafts, depending on the tumor size and extent of resection. All of the pathology specimens were examined and reported by the Department of Pathology at our center. Patients were regularly checked by attending surgeon on a monthly basis during at least 12 months. Patients with verified lymphomas were treated by the hematologists.

**Diagnosics**

Although histopathological analysis of the removed lesion is a golden standard for setting the diagnosis of each lesion individually, nowadays dermatoscopy as the auxiliary diagnostic method is used -it is a non-invasive technique, simple to perform and significantly improves the precision during differentiation of various pigmented skin lesions (16).

Generally, it is considered that the risk for malignant alteration with melanocytic nevus is very low,

compared to atypical and gigantic congenital nevus, which are recommended to be monitored regularly. Preventive surgical removal for large congenital lesions and avoidance of exposure to UV radiation (photo protection) are the most significant preventive ways to lower the risk factors for melanoma occurrence (17).

**RESULTS**

In the period from May 2015 until May 2017, 100 patients with head and neck skin malignancy were analyzed. The study included 64 men and 36 women. The average age of the patients was 60 years (59.80), and average age by category was 61.57 years (men) and 52.96 (women). The youngest patient was 20 years old, and the oldest patient was 92 years old. No patient had intraoperative and postoperative complications (allergy to anesthetic, heavy bleeding, wound infection, cardiological intraoperative complications). Malignant tumours had the following distribution: 80 basal cell

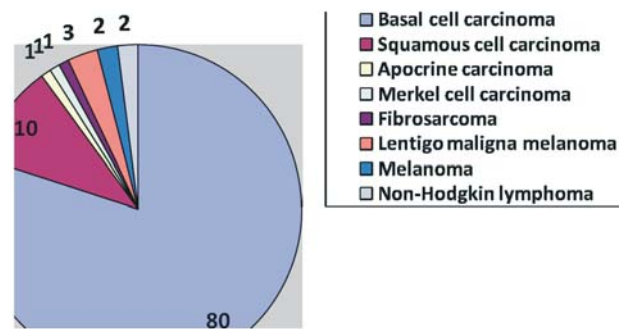


Figure 5. Distribution of patients by pathology finding expressed in percentage

Table 1. Distribution of patients surgically treated for skin malignancy at Department of Otorhinolaryngology with Maxillofacial Surgery of CHC "Zemun" from May 2015 to May 2017

	Total cases by PH type	Gender		Primary location									
		M	F	Scalp	Forehead	Temple	Eyelid	Cheek	Nose	Lips	Chin	Neck	Ear
Basal cell carcinoma	80	50	30	5	7	10	6	16	12	6	4	9	5
Squamous cell carcinoma	10	6	4	1	/	2	1	1	1	3	/	/	1
Apocrine carcinoma	1	1	/	/	/	/	/	/	/	/	/	1	/
Merkel cell carcinoma	1	1	/	/	/	/	/	/	/	/	/	1	/
Fibrosarcoma	1	1	/	/	/	/	/	/	1	/	/	/	/
Lentigo maligna melanoma	3	2	1	1	/	/	/	2	/	/	/	/	/
Melanoma	2	1	1	/	/	/	/	/	/	/	/	2	/
Non-Hodgkin lymphoma	2	2	/	/	/	1	/	/	/	/	/	1	/

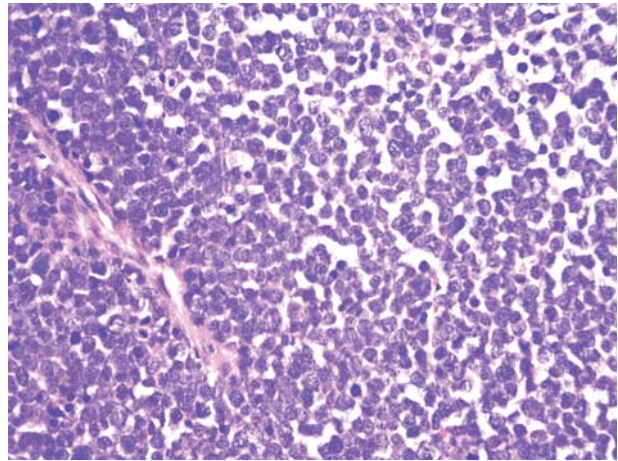
carcinomas, 10 squamous cell carcinomas, 3 lentigo maligna melanomas, 2 melanomas, 2 non-Hodgkin lymphomas, 1 apocrine carcinoma, 1 Merkel cell carcinoma and 1 fibrosarcoma each (Figure 5, Table 1).

## DISCUSSION

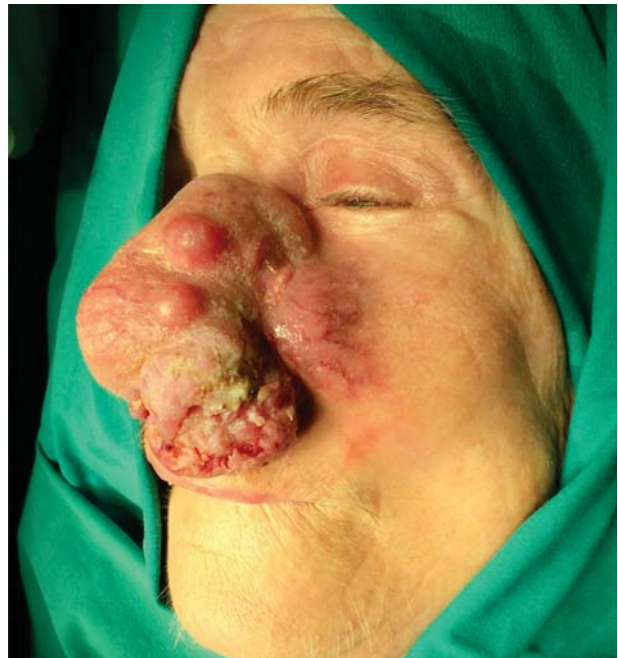The majority of all malignant tumor of face, neck, jaw belonged to BCCs and occur mostly in men. It is accordance with previous data that BCC is the most common tumor in this part (18) (Figure 1). The higher incidence in men is probably due to increased recreational and occupational exposure to the sun. However, the incidence in women is increasing because of changing fashions in lifestyle. The likelihood of developing BCC increases with age, and it is rarely found in patients younger than 40 years (18). The mean age of our patients is 65.6. In our study, there are no significant difference between sex in BCC; even men had 1,7 times more incidence of BCC. The exact cause of BCC is unknown. Several factors are believed to predispose the patient to basal cell carcinoma. Exposure to sunlight is the most frequent association. Cumulative exposure to sunlight over years is necessary for tumor development (17, 18). There are three types of UV radiation: UV-A (320–400 nm), UV-B (290–320 nm), and UV-C (200–280 nm). UV-B rays are the most carcinogenic, triggering skin cancer via photochemical damage to DNA, injury to DNA repair mechanisms, and partial suppression of cell-mediated immunity (15, 16, 17). Patients often have a history of chronic sun exposure. Excisional biopsy is the biopsy type that we usually prefer. We advise excisional biopsy for small lesions that enable primary closure afterwards that does not cause distortion of the environmental tissues. Otherwise, an incisional biopsy may be done before the definitive treatment. Once the pathologic diagnosis of BCC is confirmed, the next step is to plan for tumor eradication by correlating tumor characteristics with patient's age, skin history, medical history, social history, and cosmetic expectations. Treatment options include standard surgical excision, Mohs micrographic surgery, nonsurgical ablation, and topical chemotherapy. Surgical excision is the preferred method in our center. We generally perform excision under local anesthesia or in the outpatient surgery settings.

In our study, the second frequent tumor was squamous cell carcinoma. More than 70% of SCC occur in the ear lobe area (Figure 2) and in the lower third of the face (15, 18). Our study partially confirmed that finding, but it should take into account that we found only 10 SCC for two years of follow up (small sample).

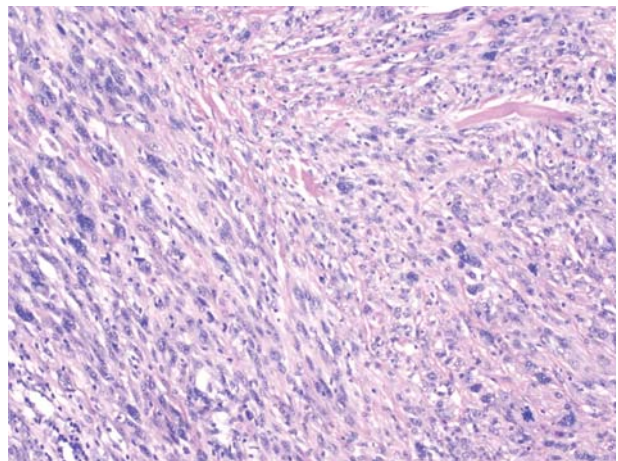
The other malignant tumor of the head and neck were sporadic, and we could call them rare tumors (Figures 6, 7, 8). We came to the very interesting finding



**Figure 6.** Histopathological features of Merkel cell carcinoma (H&E, x200)



**Figure 7.** Dermatofibrosarcoma localized in the nasal region of an elderly patient



**Figure 8.** Histopathological pattern of leiomyosarcoma (H&E, x100)

of only two melanomas for 2 years of following. Rare tumors were one up to three in the observed period. Three lentigo maligna melanoma and two non-Hodgkin lymphomas were observed, while Merkel cell carcinoma, apocrine carcinoma and fibrosarcoma were found only in one patient each.

## CONCLUSION

Our study has shown that the most frequent tumor of the head and neck skin is basal cell carcinoma, while the second one was squamous cell carcinoma. All the patients were surgically treated and are still alive, with no signs of recurrence and are regularly seen by attending physician. Although there is relatively low attributable mortality, the morbidity and cost of treatment are significant. A large body of information serves as a foundation for oncologic principles, diagnosis methods,

surgical excisions, follow-up protocols, and reconstructive methodologies that are currently in use.

## Abbreviations

**BCC** — basal cell carcinoma  
**SCC** — squamous cell carcinoma  
**UV** — ultraviolet

## DECLARATION OF INTEREST

The authors declare that there are no conflicts of interests.

## Licensing

This work is licensed under a Creative Commons Attribution 4.0 International (CC BY 4.0) License.

## Sažetak

# RETKI MALIGNI TUMORI KOŽE GLAVE I VRATA

**Oroz Aleksandar**,<sup>1</sup> **Bokun Zorana**,<sup>2</sup> **Lazović Biljana**,<sup>3</sup> **Čukić Ognjen**,<sup>1</sup> **Valjarević Svetlana**<sup>1</sup>

<sup>1</sup> Department of otorhinolaryngology and maxillofacial surgery, University clinical hospital center Zemun, Belgrade, Serbia

<sup>2</sup> Department of clinical pathology, University clinical hospital center Zemun, Belgrade, Serbia

<sup>3</sup> Clinic for internal medicine, University clinical hospital center Zemun, Belgrade, Serbia

**Uvod:** Maligni tumori kože u većini slučajeva potiču od skvamoznog epitela, mada se mogu javiti u drugim strukturama pridruženim koži, poput adneksa (folikuli dlake, znojne i lojne žlezde), kao i drugih tkiva koja učestvuju u izgradnji kože, poput mišićnog, fibroznog i masnog tkiva i hrskavice. Ovi tumori mogu imati i neuroendokrino poreklo, a mogu poticati i od premalignih dermatoza (solarna keratoza, lentigo maligna). Bez obzira na poreklo, uglavnom se javljaju u vidu nodulusa ili dugotrajnih ulceracija koje ne zarastaju. Njihovo rano prepoznavanje svakako poboljšava rezultate lečenja i smanjuje mogućnost komplikacija (infiltracija dubljih struktura, regionalne i udaljene metastaze).

**Materijal i metode:** Naša retrospektivna studija je uključila 100 pacijenata oba pola hirurški lečenih od kutanih maligniteta u Službi za otorinolaringologiju sa maksilofacijalnom hirurgijom Kliničko-bolničkog centra „Zemun“ u Beogradu, Srbija.

**Cilj** ovog rada je da prikaže učestalost retkih maligniteta kože u poređenju sa nešto češćima, kao i da razmotri za pacijenta najoptimalniji kliničko-dijagnostički i terapijski pristup.

**Zaključak:** Naša studija je pokazala da je najčešći tumor kože glave i vrata bazocelularni karcinom.

**Glavne reči:** retki maligni tumori kože, učestalost tumora kože, metastaze, hirurgija, terapija.

## REFERENCES

1. Zhang S, Ma Y, Ma T, Wang Z. Low-grade myofibroblastic sarcoma of the orbit: A case report and literature review. *Medicine (Baltimore)*. 2017; 96 (51): e9172.
2. Rat C, Hild S, Rault Sérandour J, Gaultier A, Quereux G, Dreno B, et al. Use of smartphones for early detection of melanoma: systematic review. *J Med Internet Res*. 2018; 20(4): e135.
3. Capone E, Giansanti F, Ponziani S, Lamolinara A, Iezzi M, Cimini A, et al. EV20-Sap, a novel anti-HER-3 antibody-drug conjugate, displays promising antitumor activity in melanoma. *Oncotarget*. 2017; 8(56): 95412-24.
4. Haskins CP, Nurkic S, Fredenburg KM, Dziegielewski PT, Mendenhall WM. Primary orbital melanoma treated with

orbital exenteration and postoperative radiotherapy: A case report and review of the literature. *Head Neck*. 2018; 40(3): E17-20.

5. Amin SM, Cooper C, Yélamos O, Lee CY, Sholl LM, de la Fouchardiere A, et al. Combined cutaneous tumors with a melanoma component: a clinical, histologic, and molecular study. *J Am Acad Dermatol*. 2015; 73(3): 451-6.

6. Matutes E. The 2017 WHO update on mature T- and natural killer (NK) cell neoplasms. *Int J LabHematol*. 2018; 40(suppl 1): 97-103.

7. Furdová A, Horkovičová K, Babál P, Kobzová D, Ondrušová M. Non-melanotic Tumors of the Eyelids Skin and Inner Corner - Basocellular Carcinoma. *Cesk Slov Oftalmol*. 2015; 71(6): 293-301.

8. Ugwu DI, Okoro UC, Ukoha PO, Gupta A, Okafor SN. Novel anti-inflammatory and analgesic agents: synthesis, molecular docking and in vivo studies. *J Enzyme Inhib Med Chem.* 2018; 33(1): 405-15.
9. Raj A, Ramesh G, Pathak S. Assessment of hospital based prevalence of oral cancer among population of Kanpur, Uttar Pradesh. *J Exp Ther Oncol.* 2018; 12(3): 193-9.
10. Cohen PR. Basal cell carcinoma with myoepithelial differentiation: case report and literature review. *Cureus.* 2018; 10(1): e2081.
11. Dhir G, Makkar M, Suri V, Dubey V. Familial dermal eccrine cylindromatosis with emphasis on histology and genetic mapping. *Ann Med Health Sci Res.* 2013; 3 (suppl 1): S3-6.
12. Russell L, Ugalde A, Milne D, Krishnasamy M, O SeungChul E, Austin DW et al. Feasibility of an online mindfulness-based program for patients with melanoma: study protocol for a randomised controlled trial. *Trials.* 2018; 19(1): 223.
13. Ahlgrimm-Siess V, Laimer M, Rabinovitz HS, Oliviero M, Hofmann-Wellenhof R, Marghoob AA, et al. Confocal microscopy in skin cancer. *Curr Dermatol Rep.* 2018; 7(2): 105-18.
14. Giantini Larsen A, Grannan BL, Lee CK, Koch MJ, Williams EA, Frosch MP, et al. Malignant melanoma metastatic to oligodendroglioma: case report and literature review of tumor-to-tumor metastasis to gliomas. *J Neuropathol Exp Neurol.* 2018; 77(7): 549-54.
15. Taylor L, Hood K, Reisch L, Elmore J, Piepkorn M, Barnhill R, et al. Influence of variability in assessment of Breslow thickness, mitotic rate and ulceration among U.S. pathologists interpreting invasive melanoma, for the purpose of AJCC staging. *J Cutan Pathol.* 2018; 45(8): 588-96.
16. de Castro MS, Reis BSA, Nogueira DA, de Carli ML, Hanemann JAC, Pereira AAC, et al. Primary oral melanoma: a clinicopathologic review and case presentation. *Quintessence Int.* 2017; 48(10): 815-27.
17. Novotná K, Arenbergerová M, Miletín J, Kníže J, Šandera V, Schwarzmannová K, et al. Surgical treatment of melanoma. *Acta Chir Plast.* 2018 Spring; 59(3-4): 149-55.
18. Gloster HM, Brodland DG. The epidemiology of skin cancer. *Dermatol Surg.* 1996; 22(3): 217-26.

### **Correspondence to/Autor za korespondenciju**

Aleksandar Oroz

Department for Otorhinolaryngology and Maxillofacial Surgery,  
University Clinical Hospital Center Zemun,

Vukova 9, Belgrade

E mail: acaoroz967@gmail.com