

Extensive epidermoid cyst of the submental region

Estevam Rubens Utumi^a, Juliane Piráquine Araujo^b, Irineu Gregnanin Pedron^a, Frederico Yonezaki^c, Gustavo Grothe Machado^c, André Caroli Rocha^c

Utumi ER, Araujo JP, Pedron IG, Yonezaki F, Machado GG, Rocha AC. Extensive epidermoid cyst of the submental region. *Autopsy Case Rep* [Internet]. 2016;6(2):51-54. <http://dx.doi.org/10.4322/acr.2016.031>

ABSTRACT

Epidermoid cysts are malformations that are rarely observed in the submental region. Imaging has an important role in surgical planning according to the size and location of the cyst in relation to geniohyoid and mylohyoid muscles. This article reports the case of a 15-year-old female patient complaining of submental swelling. The differential diagnosis included infection, tumor, ranula, and abnormalities during embryonic development. The lesion was surgically excised using an extra-oral approach. The histopathological examination revealed a cyst wall lined with stratified squamous epithelium with the presence of several horny scales consistent with the diagnosis of an epidermoid cyst. No recurrences were found after 1 year of follow-up.

Keywords

Epidermal cyst; Pathology, Oral; Cysts

INTRODUCTION

Epidermoid cysts represent 1.6-6.9% of the cysts affecting the head and neck, and less than 0.01% of cases of oral cysts.^{1,2} Oral epidermoid cysts occur most commonly in the midline of the mouth floor, above or below the geniohyoid muscle, although they can be found laterally as well. Lowry et al.³ classified dermoid and epidermoid cysts in the mouth floor anatomically as sublingual, geniohyoid, or lateral. Epidermoid cysts are usually asymptomatic and may reach extensive sizes before diagnosis.^{4,5} Symptoms caused by oral cysts depend on their location and include dysphagia, dysarthria, and breathing difficulty.⁴⁻⁷

Cysts are classified histologically as: (i) epidermoid (lined with epithelium and derived from epidermal and

connective tissue); (ii) dermoid (with a cavity lined with a similar epithelium and containing structures such as sebaceous and sweat glands as well as hair follicles in the underlying connective tissue); and (iii) teratoma (with a cavity lined by epithelium and containing derivatives of the endoderm and mesoderm, such as muscle, intestinal mucosa, respiratory mucosa, bone, blood vessels, and appendages, which are typical of a dermal dermoid cyst).^{3,8} Overall, epidermoid cysts are the most frequently found type.^{1,3,5,8}

Complete surgical excision is the treatment of choice, and recurrence is uncommon. The location and size of the oral lesions determine the indication for intra- or extra-oral access.^{6,9,10} The aim of this study

^a Division of Dentistry - Oral and Maxillofacial Clinical Surgery - Brazilian Air Force Hospital, São Paulo/SP – Brazil.

^b Stomatology Department - School of Dentistry - Universidade de São Paulo, São Paulo/SP – Brazil.

^c Department of Oral and Maxillofacial Surgery - Hospital das Clínicas - Universidade de São Paulo, São Paulo/SP – Brazil.



is to present the case of an extensive epidermoid cyst located in the mouth floor, expanding to the submental area, which was surgically removed. Clinical, radiographic, histopathological, and therapeutic modalities are also discussed.

CASE REPORT

A 15-year-old Caucasian female presented with the chief complaint of swelling in the submental region that had developed over the last 6 months. Extra-oral examination showed a bulging mass in the submental region causing facial asymmetry. On palpation, the lesion was painless, mobile, and with a resilient

consistency. The overlying skin was intact and normal (Figure 1A). The regional lymph nodes were not involved. Intra-oral examination revealed the presence of all teeth, as well as intact mucosa without any signs of change in the mouth floor.

Computed tomography (CT) showed a well-defined and low-attenuation lesion that contained granular hyperattenuating images in the submental region, which was consistent with a cystic lesion (Figure 1B).

Surgical excision with extra-oral access was carried out (Figure 2A) without disruption of the tumor's capsule. The lesion measured approximately 45 mm at its longest axis, and contained a whitish fluid with the presence of tiny yellowish granules (Figure 2B). The histology showed a cystic lesion, the wall of which

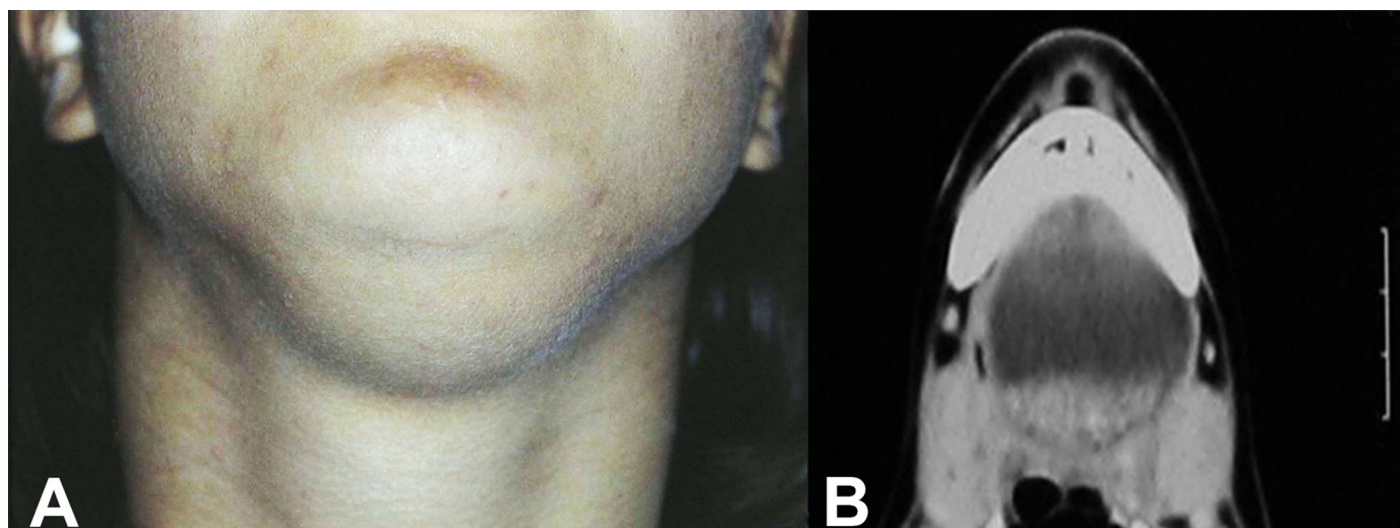


Figure 1. A - Preoperative frontal view showing swelling of the submental region; **B** - Computed tomography of the neck showing a cystic lesion filled with contents of different attenuations.

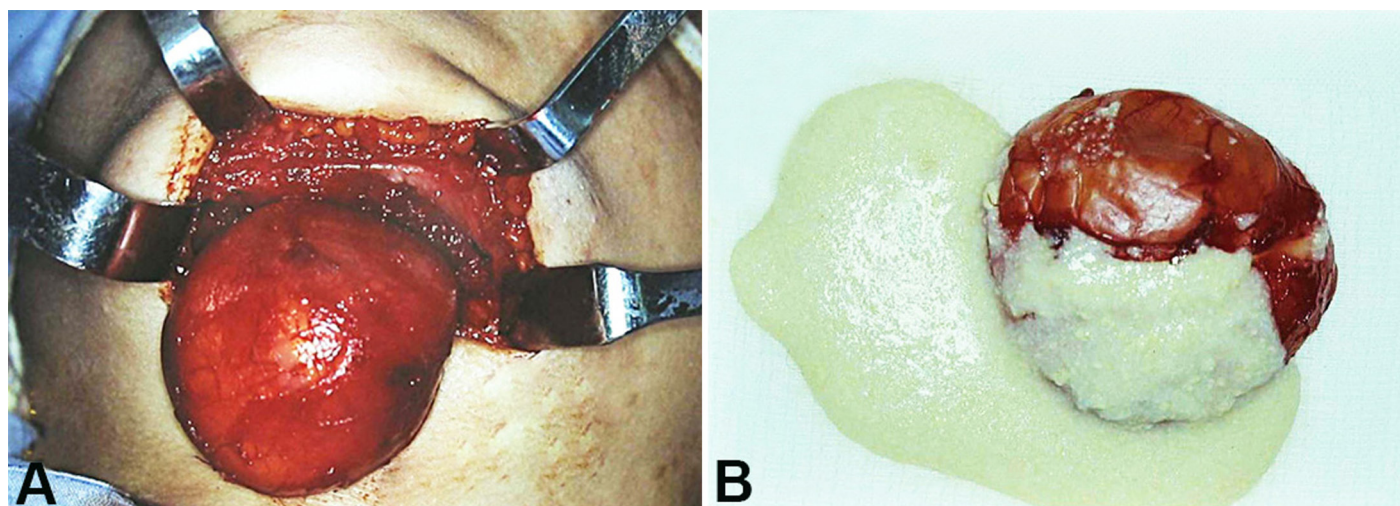


Figure 2. A - Intraoperative panoramic view of the tumor; **B** - Gross examination of the tumor after incision of the capsule, showing drainage of a granular, yellowish fluid.

was lined by a squamous epithelium with the presence of several horny scales, supported by a fibrous wall of dense connective tissue consistent with the diagnosis of an epidermoid cyst (Figure 3).

The outcome was uneventful and no signs of recurrence during the 1 year follow-up was observed. The facial contours became aesthetically normal.

DISCUSSION

Epidermoid cysts are rare in the mouth floor and their etiology is still unknown.^{1,4,6,8,11,12} Many hypotheses have tried to explain their development; the most accepted one is that they result from ectodermal tissue sequestration of the first and second branchial arches during fetal development.^{1,6,8}

Males are more commonly affected by oral epidermal cysts than females (ratio of 3:1).¹³ Usually, the lesion is located above the mylohyoid muscle.^{4,8} However, in the current report, the lesion presented below this muscle as evidenced by clinical and imaging findings as well as surgical findings. The submental location caused swelling, giving the clinical appearance of a "double chin".⁴ Impaired speech and troublesome eating are also common complaints in cases of cysts in the same location.^{4,5,7}

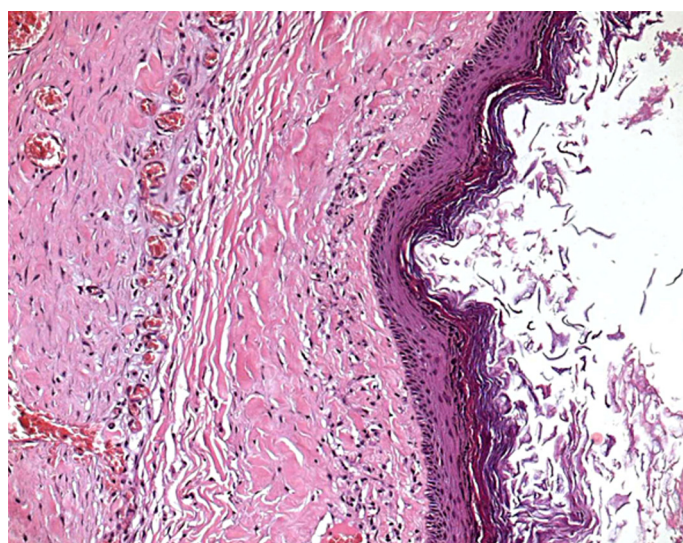


Figure 3. Photomicrograph of the cyst wall showing a stratified squamous epithelium with the presence of several horny scales, supported by a fibrous wall of dense connective tissue, associated with nonspecific chronic inflammatory processes (H&E, 200X).

The differential diagnosis included infection (odontogenic abscess), tumor (lipoma), mucus extravasation, and abnormal anatomical growth during embryonic development.^{1,6,7} In this case, infection was ruled out because of the lack of pain, inflammatory signs, and intra-oral infectious focus. A neoplastic hypothesis was not considered because of the clinical and radiographic findings. The keratinized material found in the cystic fluid aspirated in this case eliminated the possibility of ranula, as reported in the literature, with these characteristics.^{6,12}

Although the diagnosis of these lesions requires histopathological examination, imaging exams are useful as a complementary tool providing the tumor's precise location and its relation with adjacent structures, thereby aiding the surgical planning.¹⁴ In our case, the CT showed an apparently homogeneous unilocular cystic lesion, which was different from a ranula that radiates pain, and may cross the midline.¹⁵

Cysts located below the geniohyoid muscle, as in the current case, are usually treated by excision with extra-oral access.^{6,8} In cases located above this muscle, intra-oral access under local anesthesia is sufficient, and provides esthetic and functional results.^{7,13,16} Marsupialization has been proposed as an alternative treatment in cases of extensive cysts.¹⁵ The prognosis after surgical excision is good and recurrence is uncommon. Malignant transformation of epidermoid cysts is rare, but has been reported.^{1,4,17} In the present case, the patient had no recurrence after 1 year of postoperative follow-up.

Epidermoid cysts, although rare, do occur in the mouth floor; when their presentation form is typical, the diagnostic suspicion is based on clinical features and imaging exams, which are sufficient for the appropriate therapeutic approach.

REFERENCES

1. Ozan F, Polat HB, Ay S, Goze F. Epidermoid cyst of the buccal mucosa: a case report. *J Contemp Dent Pract.* 2007;8(3):90-6. PMID:17351686.
2. De Ponte FS, Brunelli A, Marchetti E, Bottini DJ. Sublingual epidermoid cyst. *J Craniofac Surg.* 2002;13(2):308-10. <http://dx.doi.org/10.1097/00001665-200203000-00024>. PMID:12000893.

3. Lowry RE, Tempero RM, Davis LF. Epidermoid cyst of the floor of the mouth. *J Oral Surg.* 1979;37(4):271-3. PMID:285233.
4. Waldron CA. Cistos do desenvolvimento. In: Neville BW, Damm DD, Allen CM, Boutquot JE. *Patologia oral e maxilofacial.* 2nd ed. Rio de Janeiro: Guanabara Koogan; 2004. p. 24-36.
5. Jham BC, Duraes GV, Jham AC, Santos CR. Epidermoid cyst of the floor of the mouth: a case report. *J Can Dent Assoc.* 2007;73(6):525-8. PMID:17672959.
6. Akao I, Nobukiyo S, Kobayashi T, Kikuchi H, Koizuka I. A case of large dermoid cyst in the floor of the mouth. *Auris Nasus Larynx.* 2003;30(Suppl):S137-9. [http://dx.doi.org/10.1016/S0385-8146\(02\)00121-9](http://dx.doi.org/10.1016/S0385-8146(02)00121-9). PMID:12543180.
7. Louis PJ, Hudson C, Reddi S. Lesion of the floor of the mouth. *J Oral Maxillofac Surg.* 2002;60(7):804-7. <http://dx.doi.org/10.1053/joms.2002.33250>. PMID:12089697.
8. Calderon S, Kaplan I. Concomitant sublingual and submental epidermoid cysts: a case report. *J Oral Maxillofac Surg.* 1993;51(7):790-2. [http://dx.doi.org/10.1016/S0278-2391\(10\)80425-2](http://dx.doi.org/10.1016/S0278-2391(10)80425-2). PMID:8509922.
9. Lima SM Jr, Chrcanovic BR, Paula AM, Freire-Maia B, Souza LN. Dermoid cyst of the floor of the mouth. *ScientificWorldJournal.* 2003;3:156-62. <http://dx.doi.org/10.1100/tsw.2003.04>. PMID:12806127.
10. Santiago Juan C, Pellicer Soria M, Ramos Asensio R, et al. Dermoid cyst of the floor of the mouth: a case report. *An Otorrinolaringol Ibero Am.* 2002;29(2):181-6. PMID:12053513.
11. Koca H, Seckin T, Sipahi A, Kazanc A. Epidermoid cyst on the floor of the mouth: report of a case. *Quintessence Int.* 2007;38(6):473-7. PMID:17625630.
12. Seah TE, Sufyan W, Singh B. Case report of a dermoid cyst at the floor of the mouth. *Ann Acad Med Singapore.* 2004;33(4, Suppl):S77-9. PMID:15389314.
13. Longo F, Maremonti P, Mangone GM, De Maria G, Califano L. Midline (dermoid) cysts of the floor of the mouth: report of 16 cases and review of surgical techniques. *Plast Reconstr Surg.* 2003;112(6):1560-5. <http://dx.doi.org/10.1097/01.PRS.0000086735.56187.22>. PMID:14578785.
14. Mirza S, Fadi S, Napaki S, Abualruz A. Case report of complicated epidermoid cyst of the floor of the mouth: radiology-histopathology correlation. *Qatar Medical Journal.* 2014:12-6.
15. Souza RP, Paes AJOP Jr, Volpato R. O espaço sublingual. *Rev Radiol Bras.* 2003;36(1):35-40. <http://dx.doi.org/10.1590/S0100-39842003000100009>.
16. Verma S, Kushwaha JK, Sonkar AA, Kumar R, Gupta R. Giant sublingual epidermoid cyst resembling plunging ranula. *Natl J Maxillofac Surg.* 2012;3(2):211-3. <http://dx.doi.org/10.4103/0975-5950.111386>. PMID:23833501.
17. Yalmaz I, Yilmazer C, Yavuz H, Bal N, Ozluoglu LN. Giant sublingual epidermoid cyst: a case report of two cases. *J Laryngol Otol.* 2006;120(3):E19. <http://dx.doi.org/10.1017/S0022215106009194>. PMID:16917995.

Conflict of interest: None

Submitted on: December 9th, 2015

Accepted on: April 14th, 2016

Correspondence

André Caroli Rocha

Department of Oral and Maxillofacial Surgery - Hospital das Clínicas - Universidade de São Paulo (USP)

Av. Dr. Enéas de Carvalho Aguiar, 255 – Cerqueira César – São Paulo/SP – Brazil

CEP: 05403-001

Phone: +55 (11) 2661-6393

E-mail: andcaroli@uol.com.br